

Complications
during
Ridge Expansion

During the Procedure

- Difficulties in Starting Ridge Expansion
- Narrow Crest of Ridge
- Fracture of Crest of Ridge
- Fractured Scalpel Blade

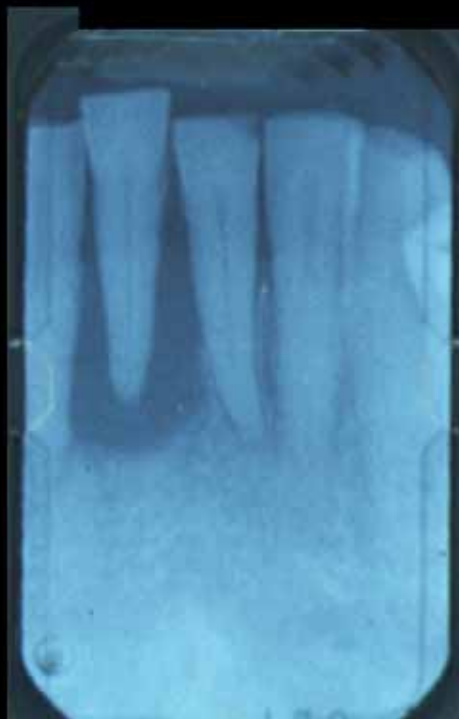Complications during Ridge Expansion

- Fracture of Buccal/Labial Plate
- Fracture of Lingual/Palatal Plate
- Perforation of Lingual/Palatal Plate
- Hole in Side of Socket
- Hole Apically

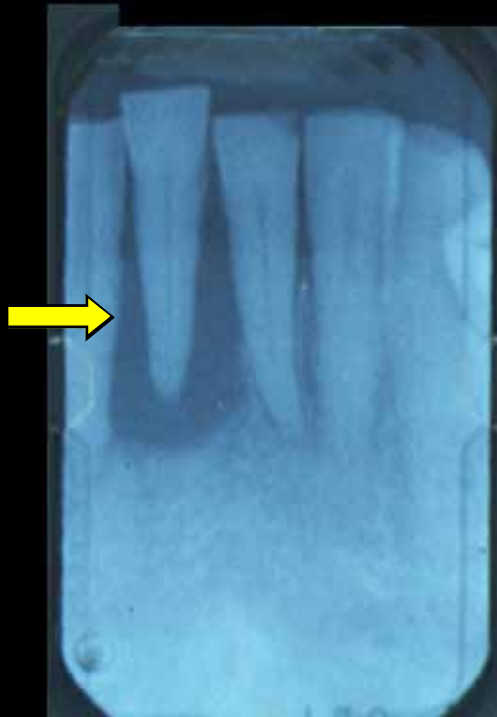Complications during Ridge Expansion

- Expansion Palatally
- Implant Head too far Buccally
- Implant Head too Far Palatally

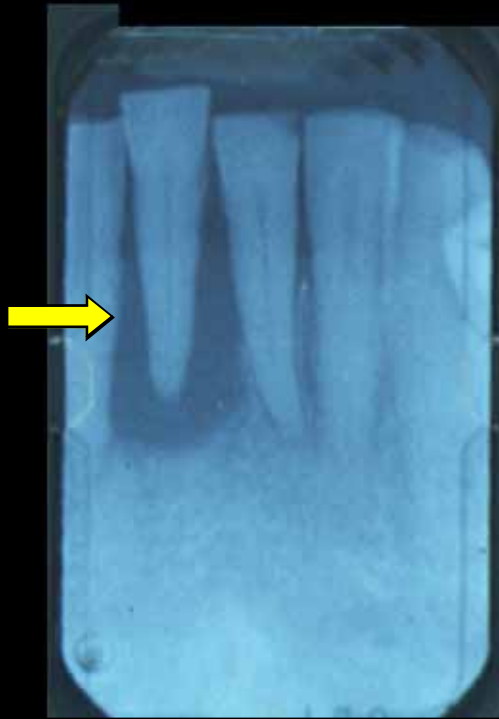Postoperative Pain Case



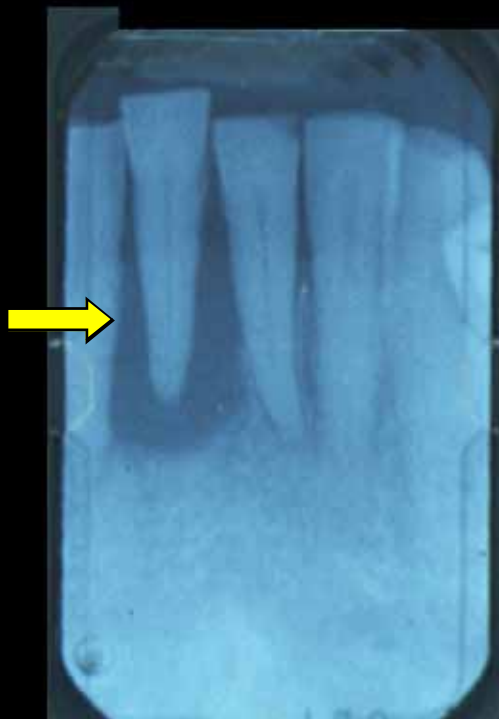Excessively Loose Tooth



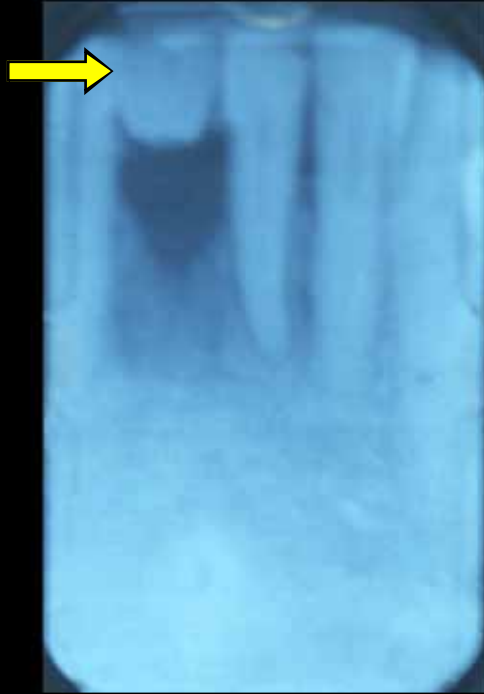
Tooth removed



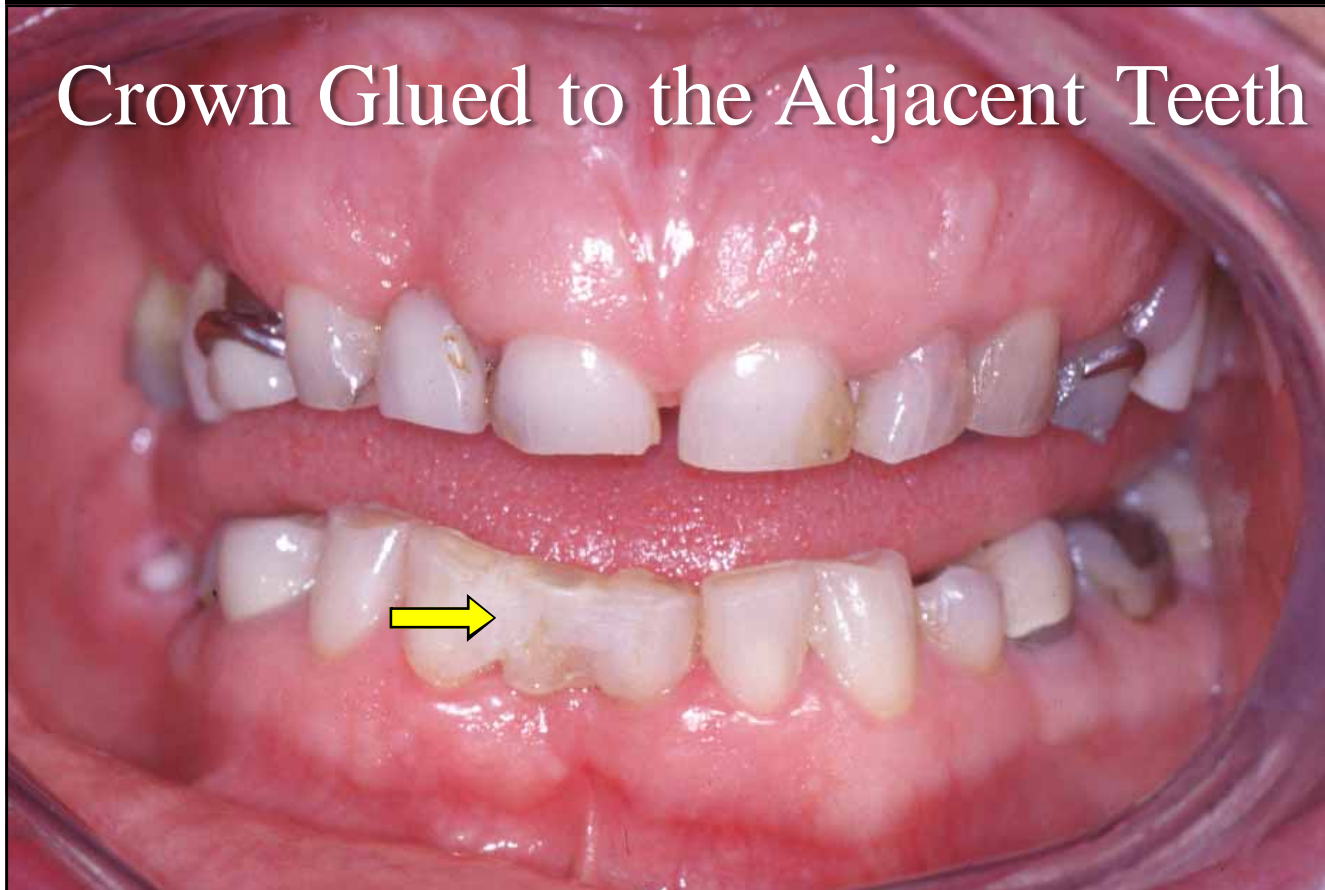Root cut off



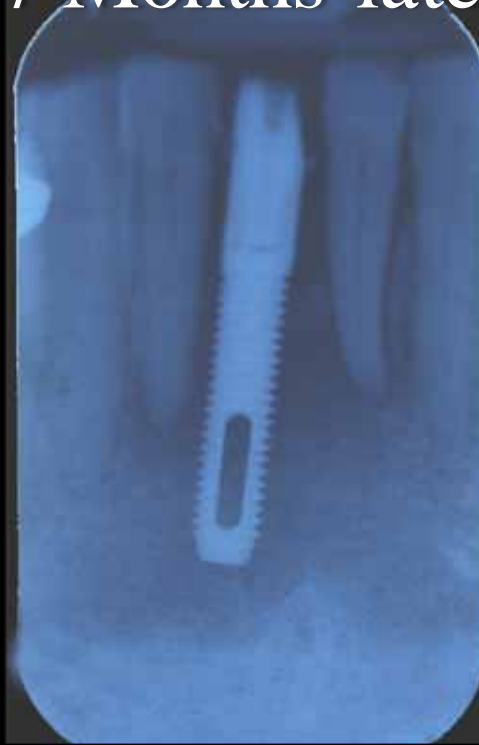Crown glued in place



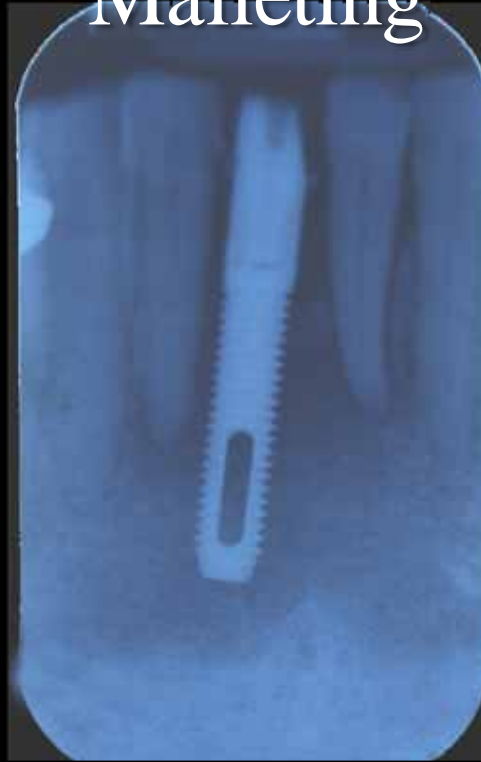Crown Glued to the Adjacent Teeth



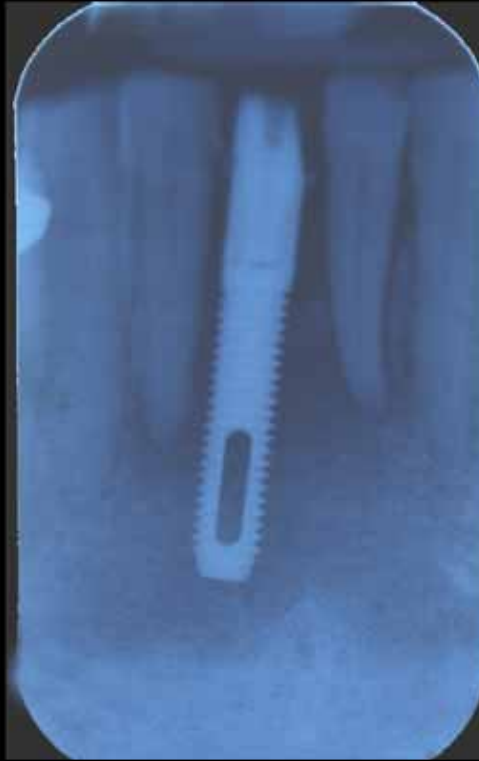Implant placed
7 Months later



Placed with Ridge Expansion and
Malleting



Severe Pain for 10 days



2 Weeks Later

- Had a Better Night
- Only hurting Slightly
- Is getting Better

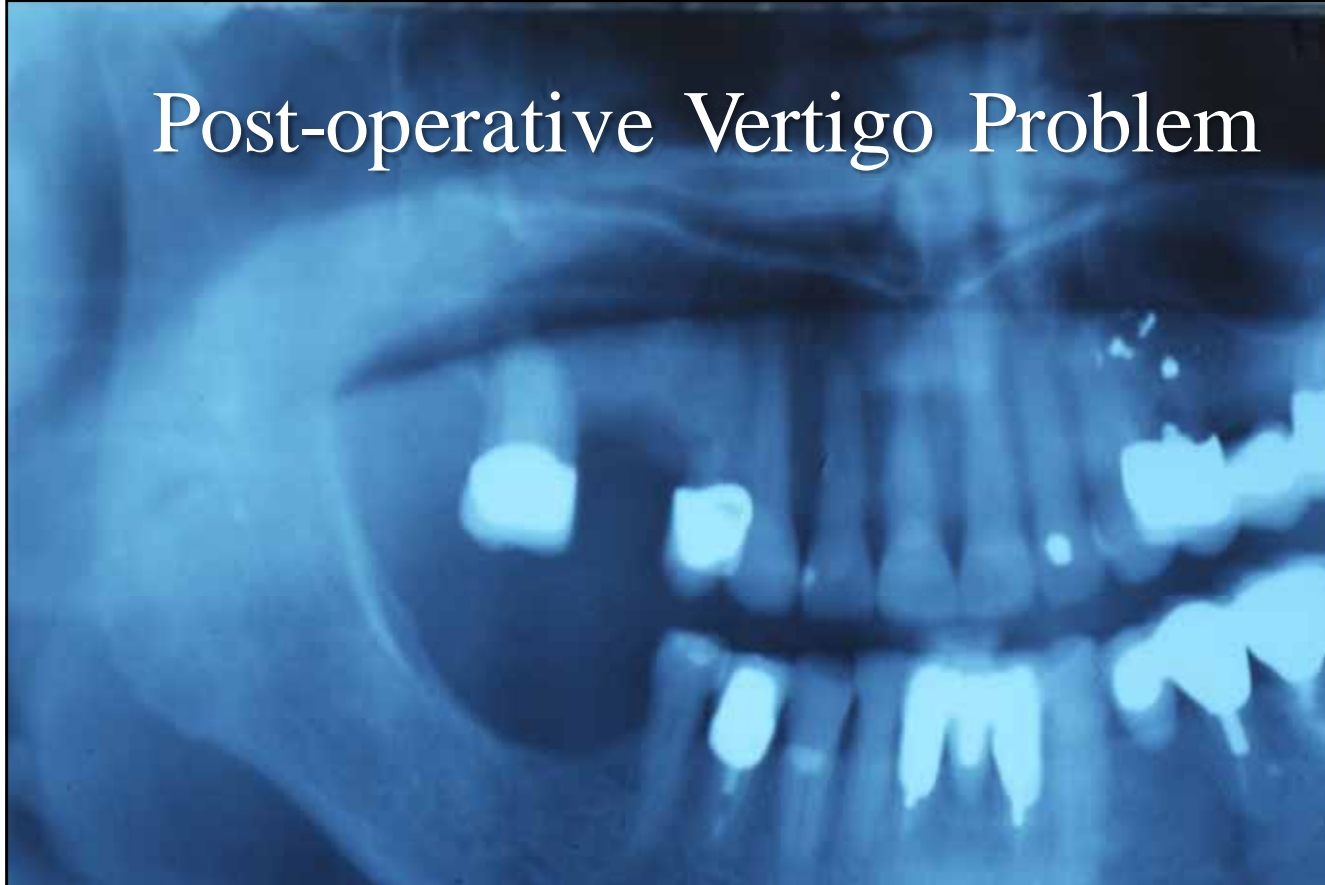October 28th 2003

- Not in Pain
- Knows It is There
- Still taking Antibiotics

Inner Ear Problems

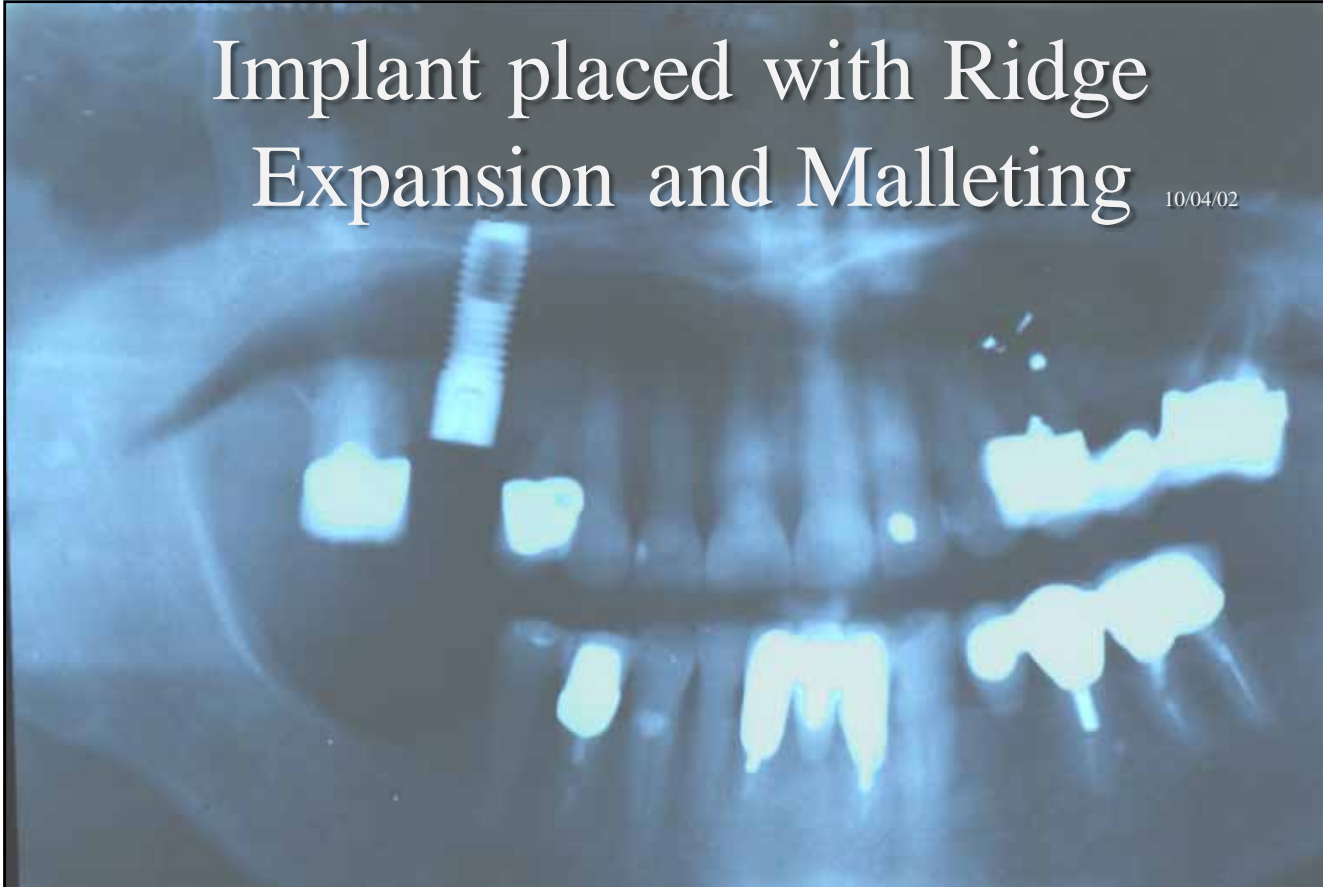
- Due to the Shaking up of the Crystals in the Inner Ear
- Loss of Balance
- Dizziness

Post-operative Vertigo Problem



Implant placed with Ridge Expansion and Malleting

10/04/02



5 days Post-operatively 15/04/02

Patient reported Dizzy Spells
Prescribed Cinnarazine

Cinnarazine used for Vestibular disorders such as

- Vertigo Tinnitus, Nausea and Vomiting in Ménière's disease
- Motion sickness

1 Month Later 08/05/02

- Dizziness returned
- Prescribed Serc 16
- Betahistidine dihydrochloride 16mg
Tablets

Dosage

- 16mg 3 Times a Day
- Withdraw Gradually

Cautions

- Asthma
- History of Peptic Ulcers
- Pregnancy
- Breast Feeding
- Pheochromocytoma

Side-effects

- Gastro-intestinal Disturbances
- Headaches
- Rashes
- Itching

17 days Later 25/05/02

Still Problems but much better

3 Months Later 03/07/02

- Everything spins for 5 seconds when Patient moves her Head at a Precise Angle
- But much better

Duration of Symptoms

Over 3 months

Vertigo Case after Screw placement with Ridge Expansion Dadswell Case

- When Patient was sat up
- Terrible Vertigo
- Room swimming around

A Vertigo Case

- Patient with a History of Vertigo
- Implants placed in the Upper
Posterior Region
using Ridge Expansion
- No Sedation

A Vertigo Case

- When the Patient sat she experienced Severe Vertigo
- Nausea and Vomiting
- Felt Awful
- Could not Stand up

A Vertigo Case

- Patient given Stematil by a Doctor
- Had to crawl Backwards down stair from the Practice/Office

A Vertigo Case

- Carried to the Car
- Vomited in the Car on the Way Home
- Put to Bed

Next Day

- Given Serc
- No Improvement
- Saw Own Doctor
- Did not go to Work for a Week

A Vertigo Case

- I week Later Reasonably OK
- Almost Cleared up
- Turning Head when drive resulted in Dizziness

A Vertigo Case

- Symptoms started Again
- Referred to ENT Surgeon
- Referred to an Audiologist
- Lay on a Table and was Manipulated
- Stopped Symptoms

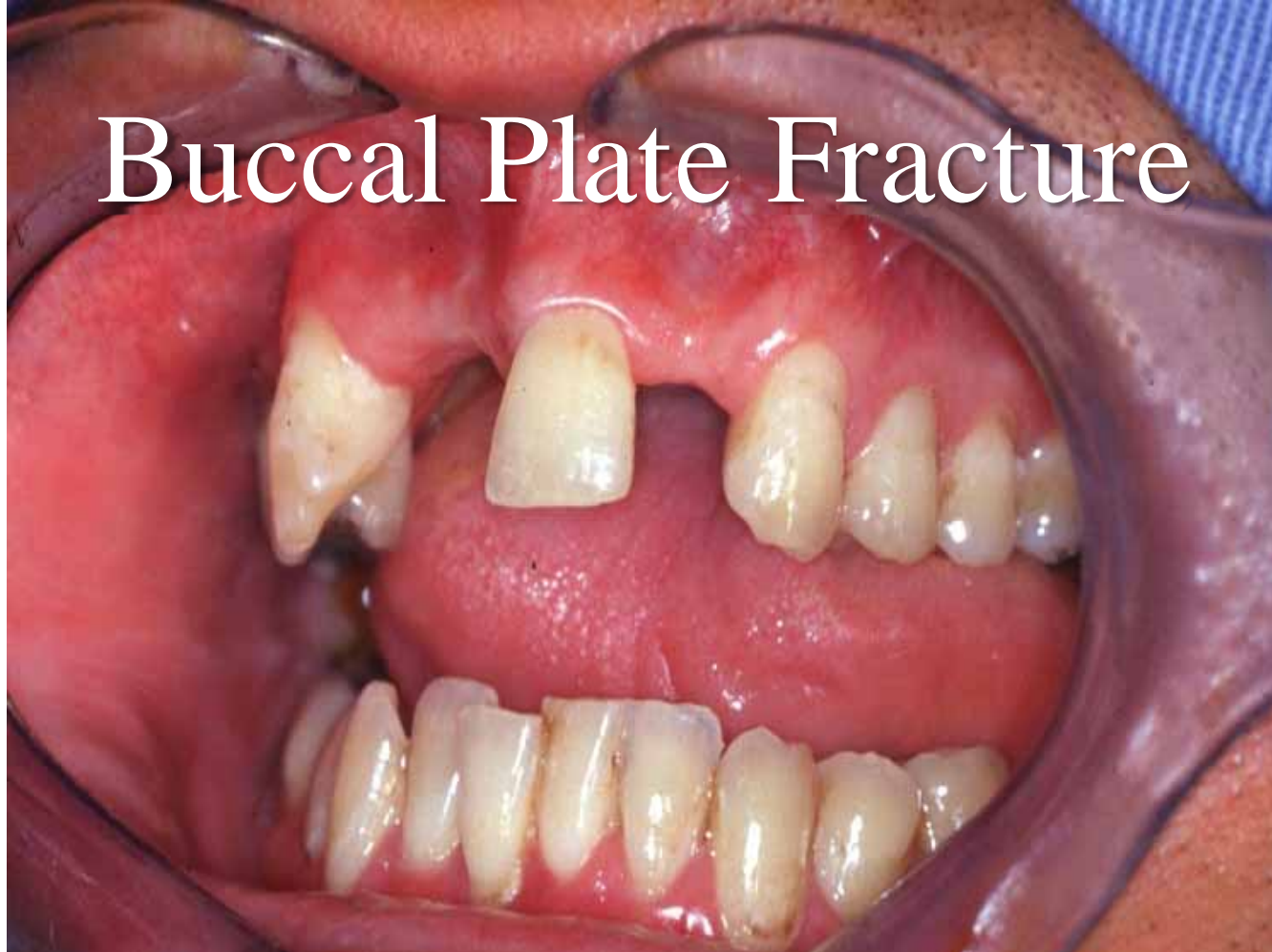
A Vertigo Case

- Symptoms started Again
- Referred to ENT Surgeon
- Referred to an Audiologist
- Lay on a Table and was Manipulated
- Stopped Symptoms

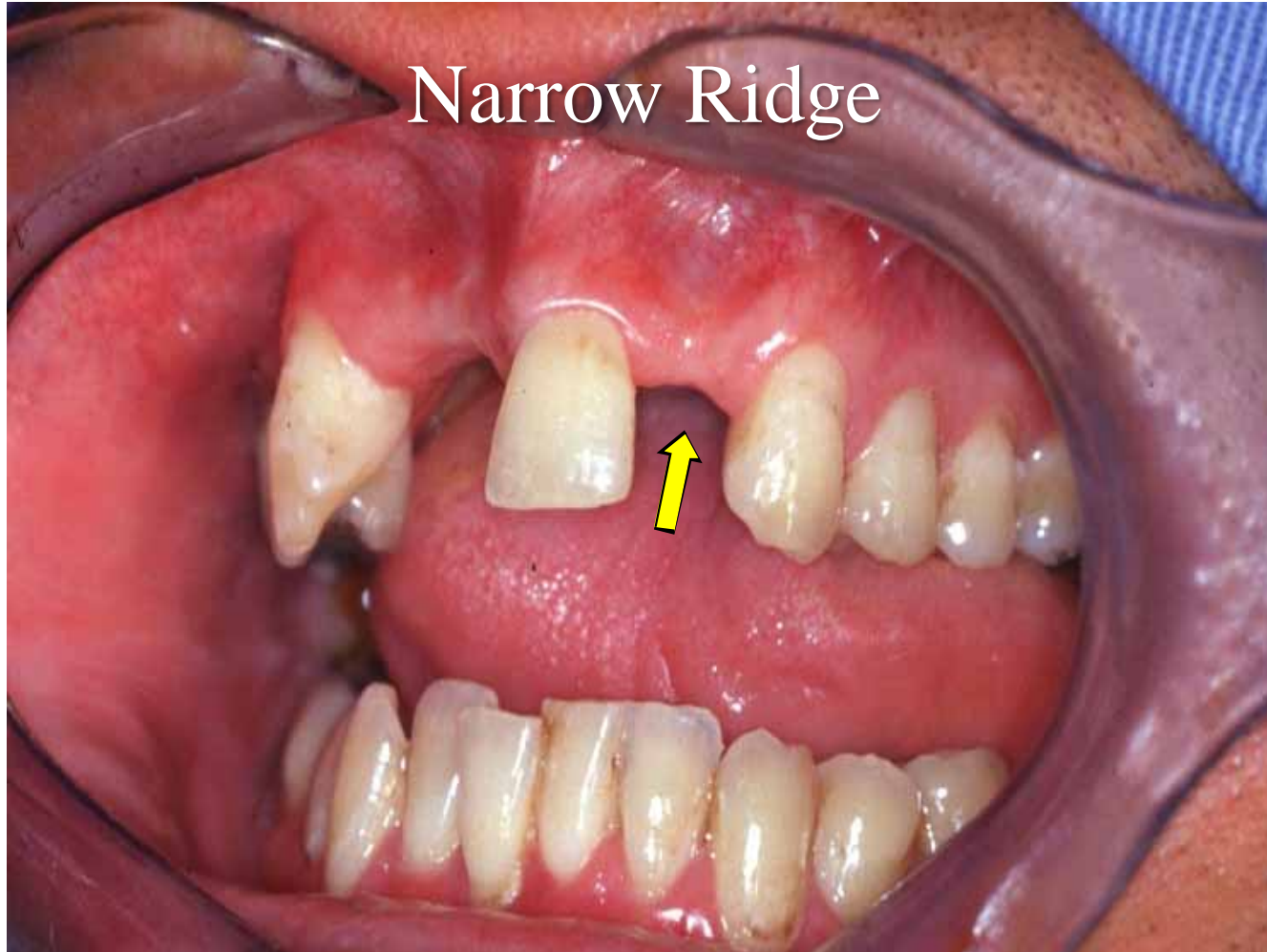
A Vertigo Case

- Symptoms reoccurred Several Times
- Returned to Audiologist

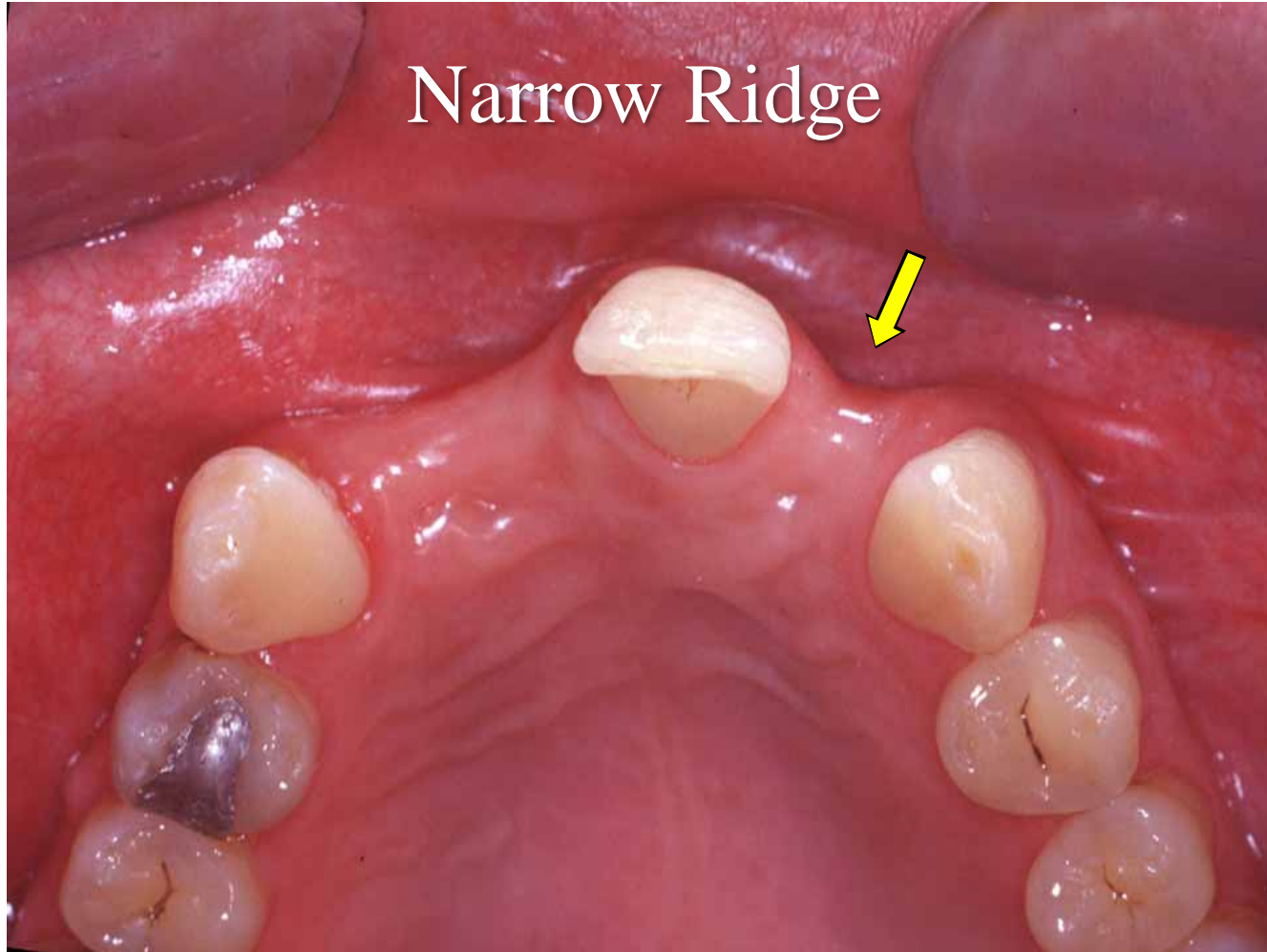
Buccal Plate Fracture



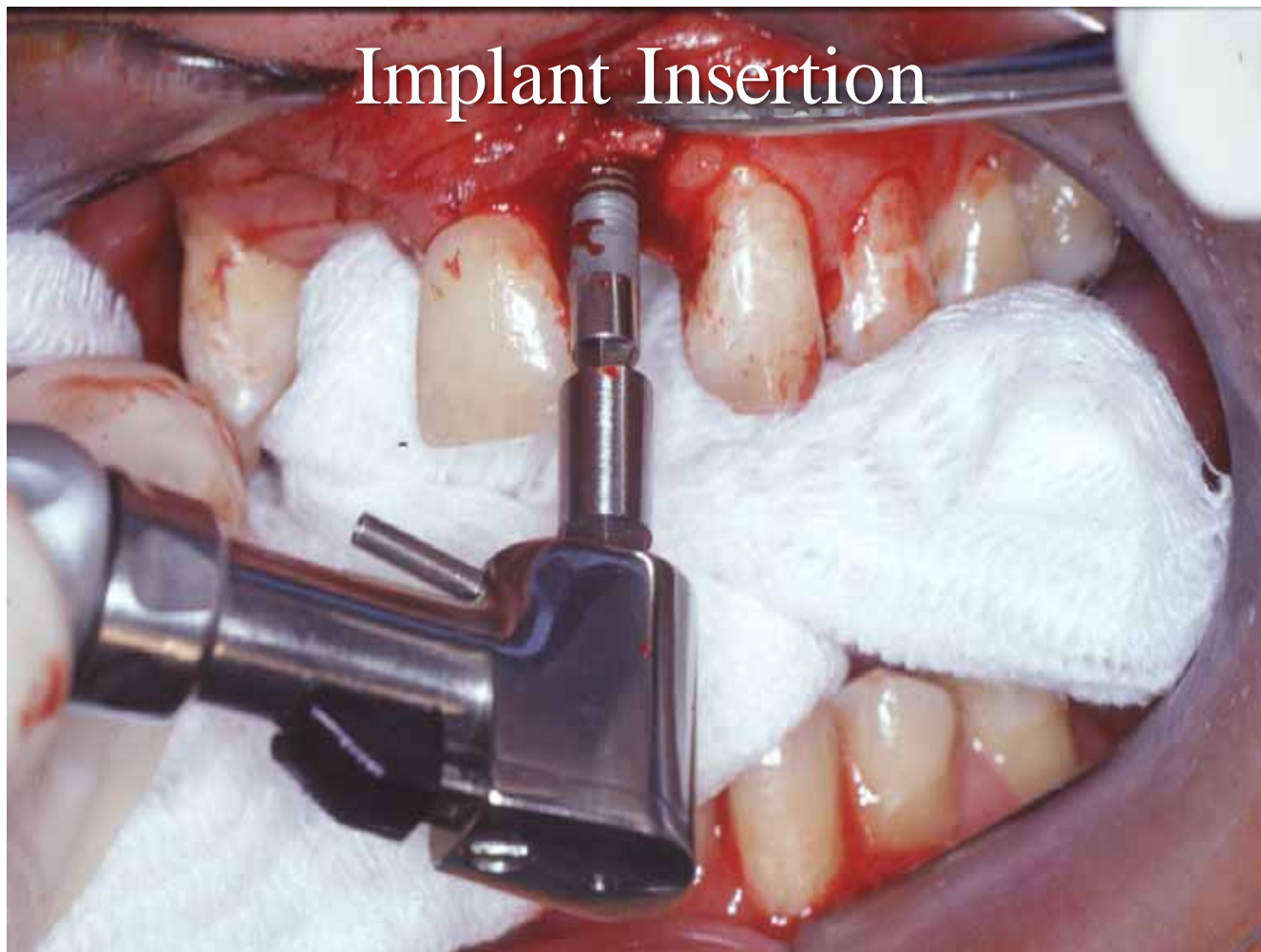
Narrow Ridge

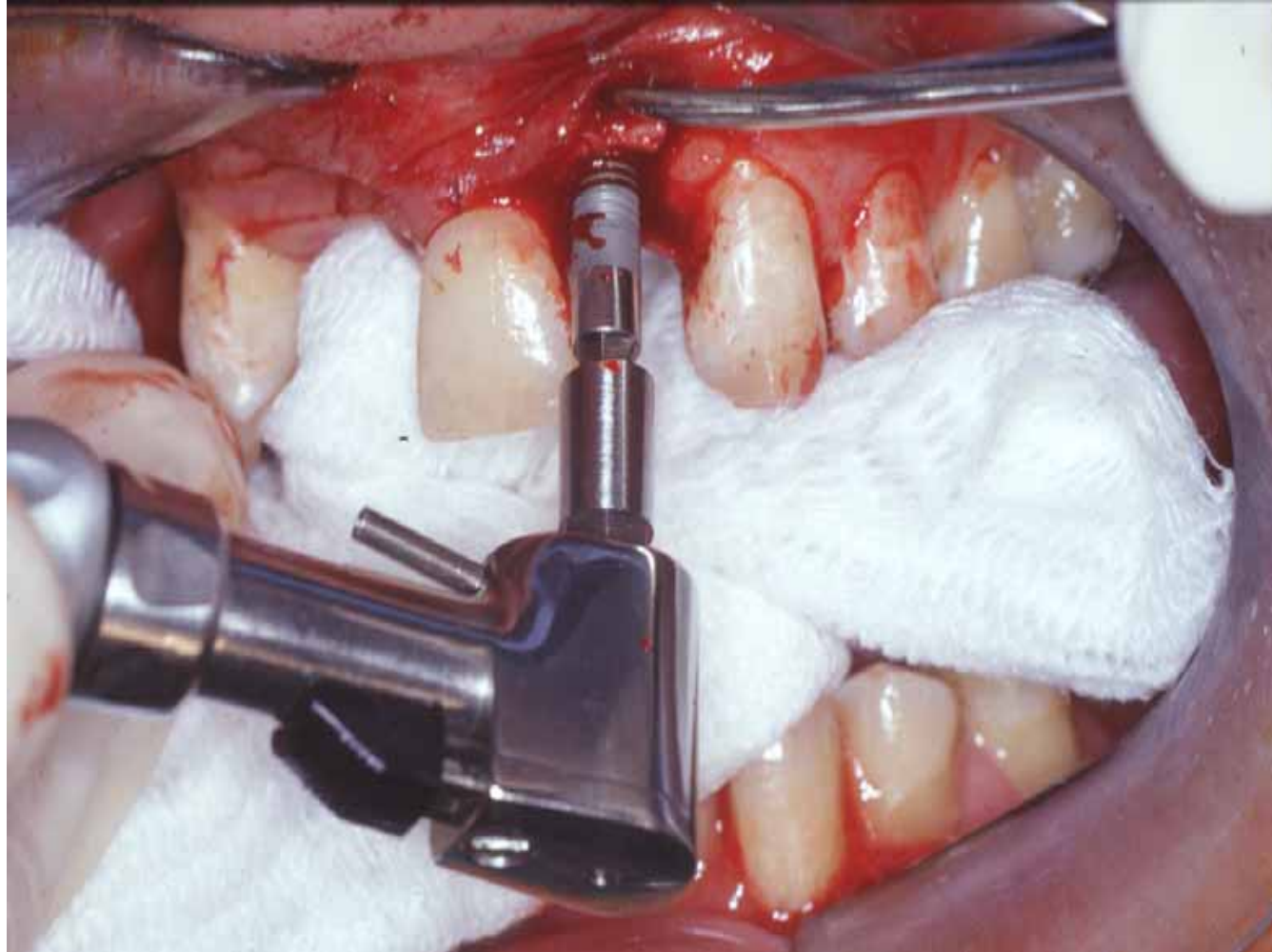


Narrow Ridge

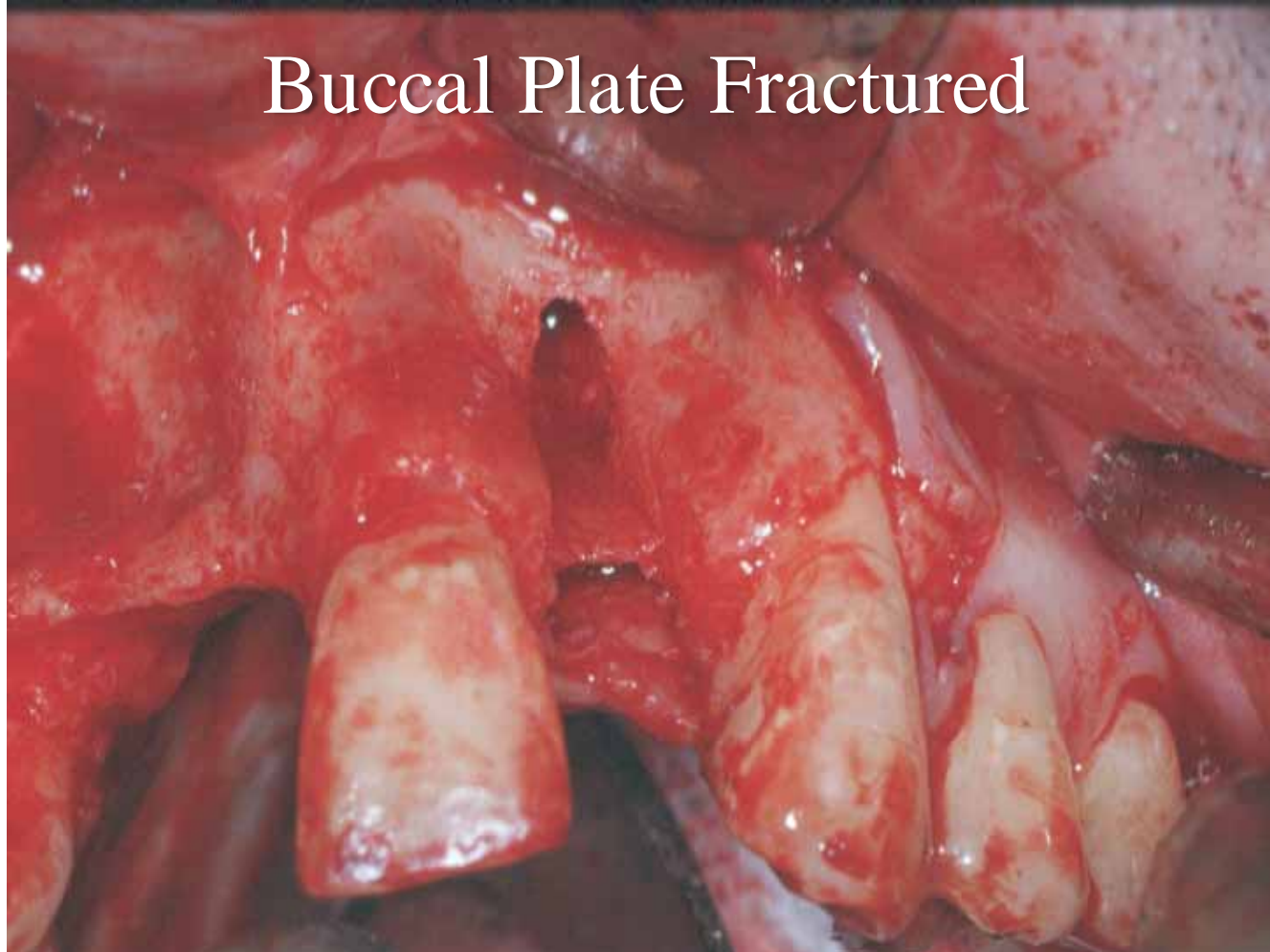


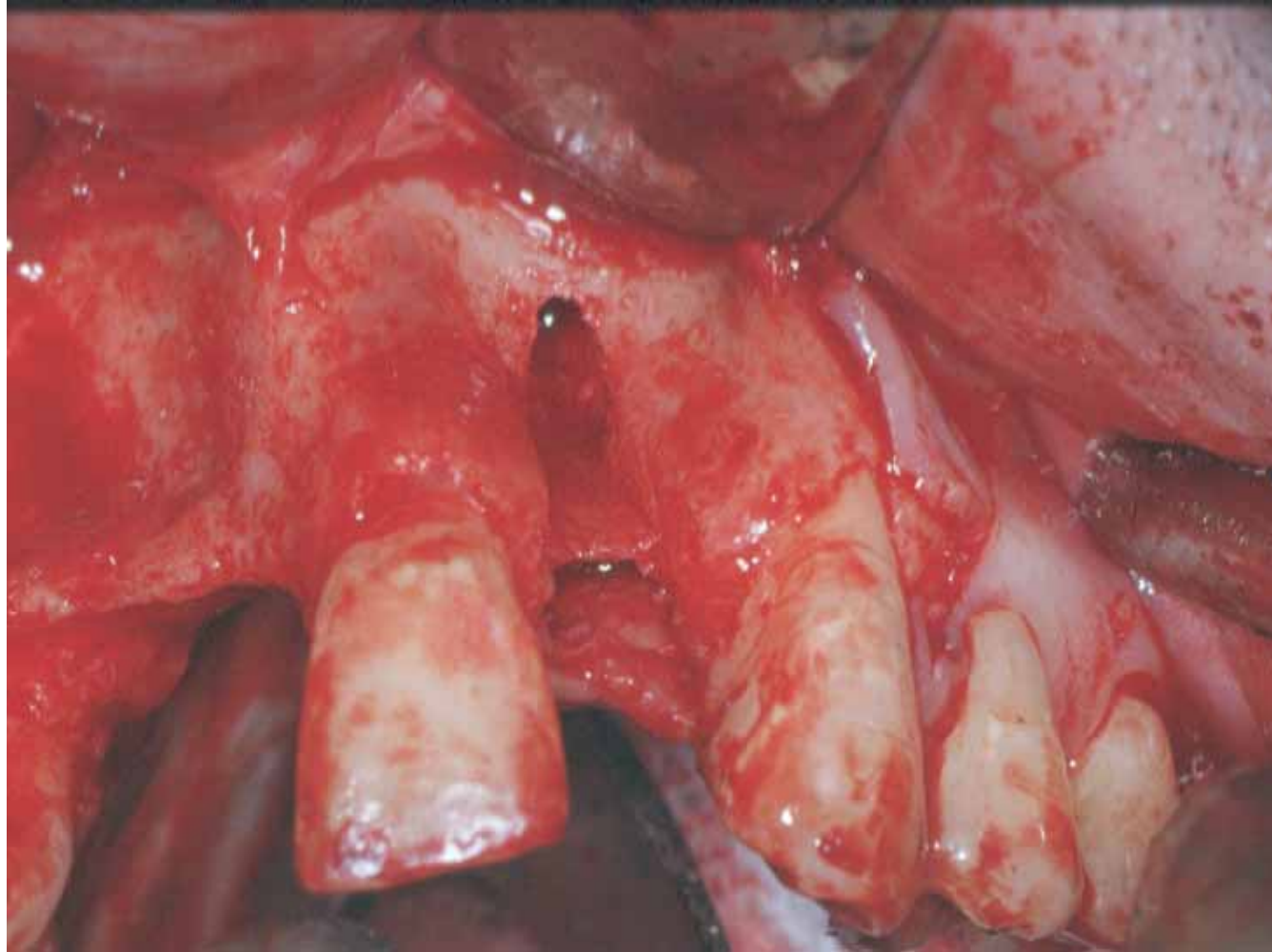
Implant Insertion



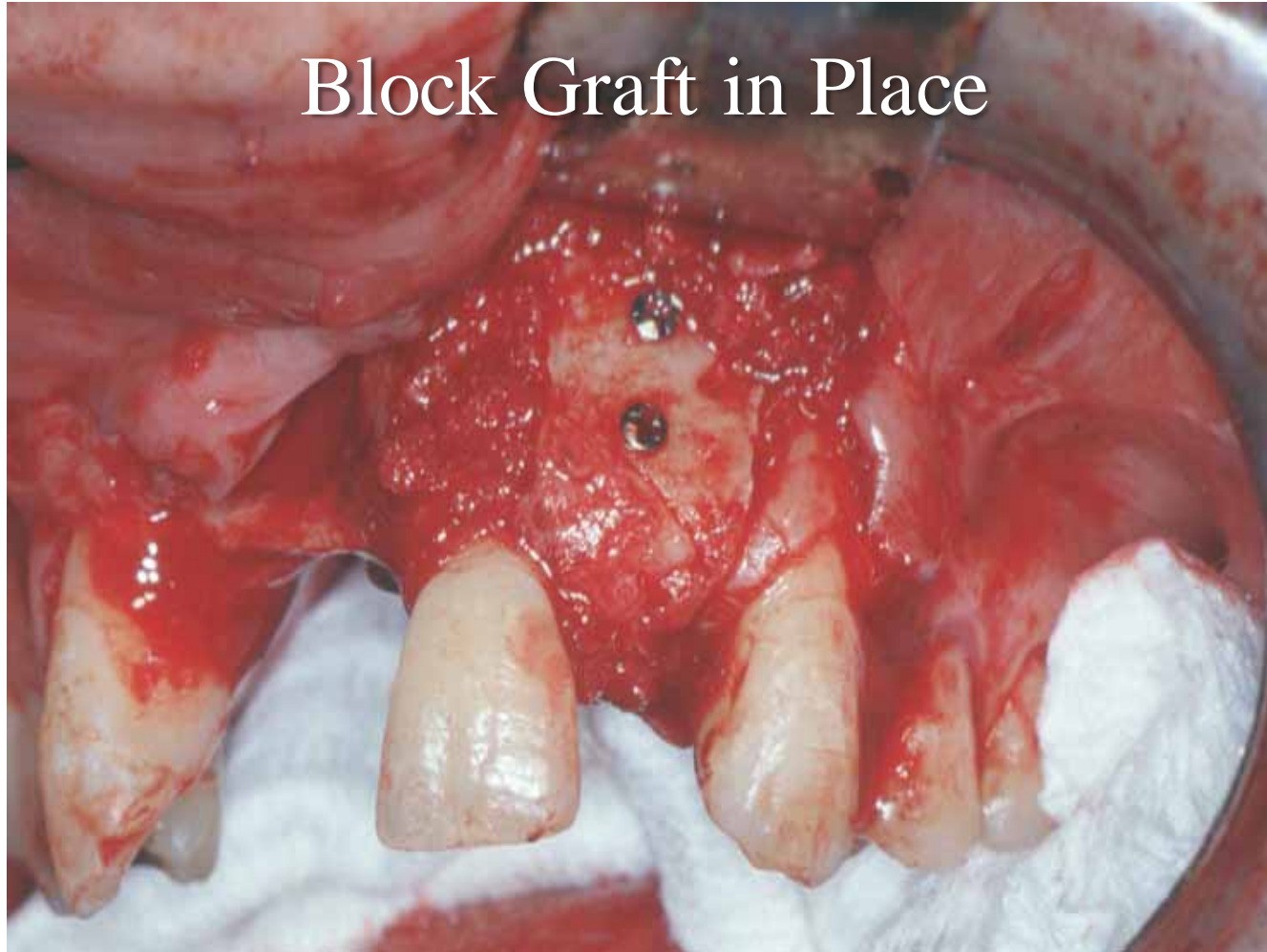

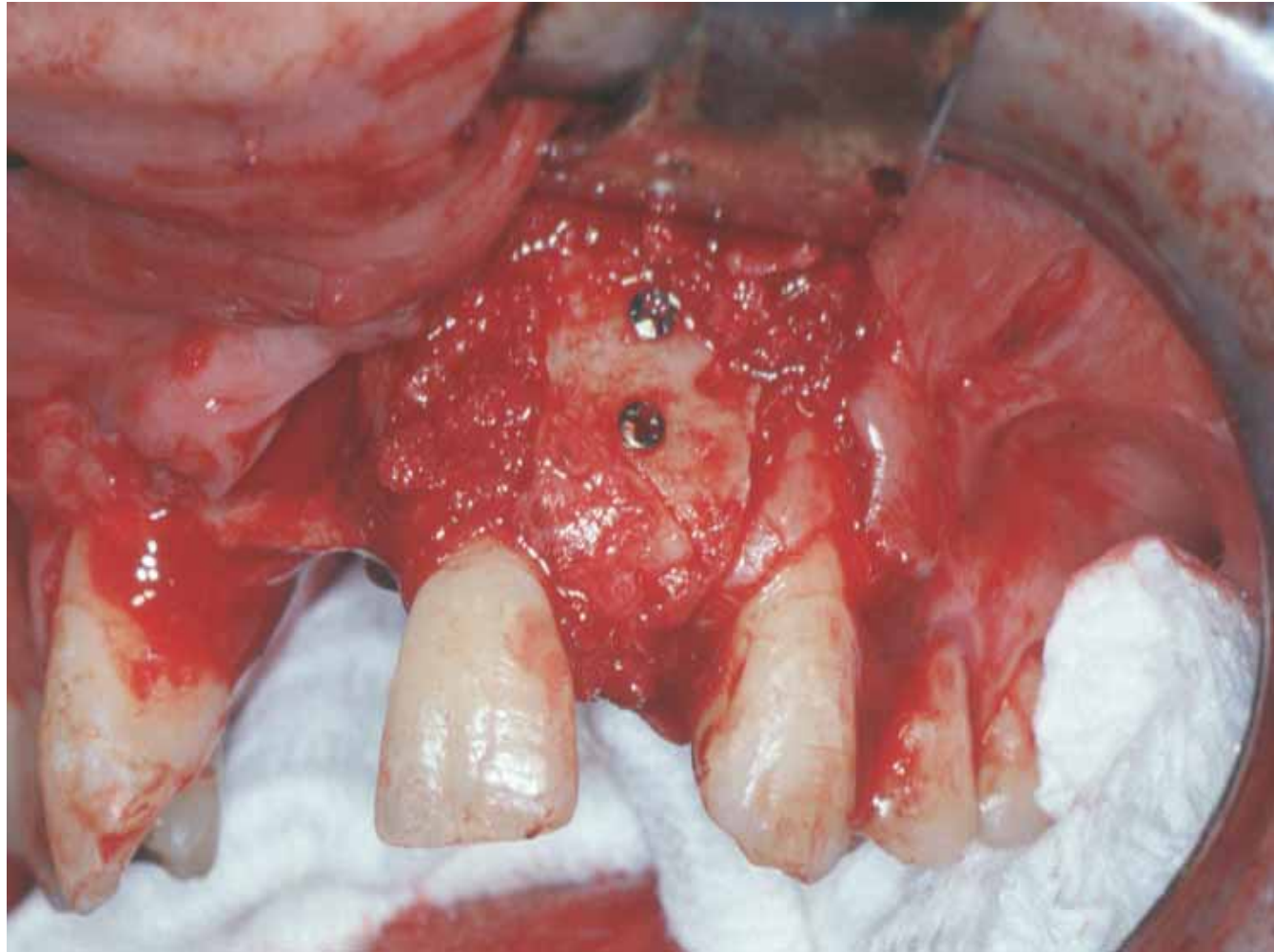Buccal Plate Fractured





Block Graft in Place





The End