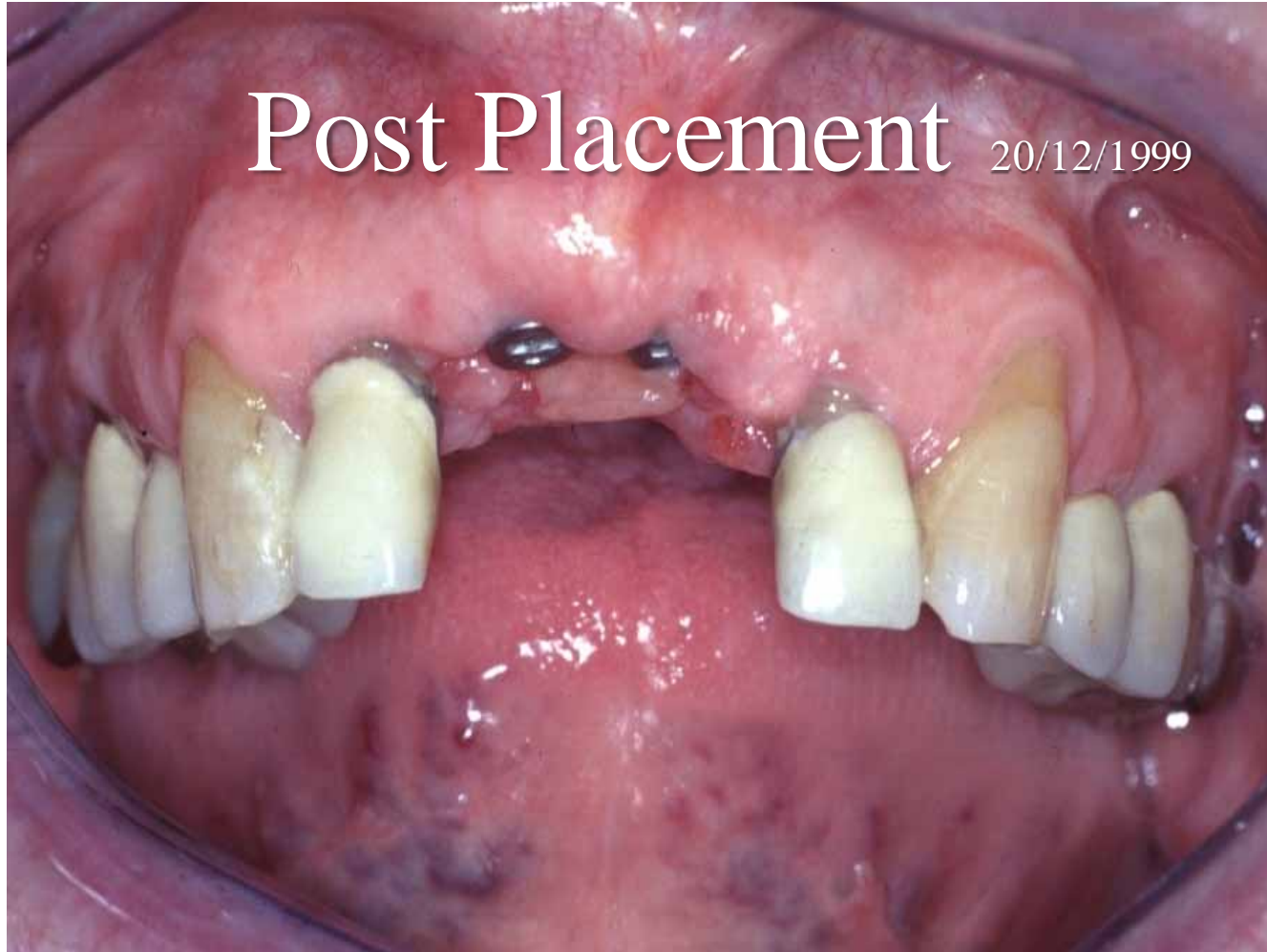


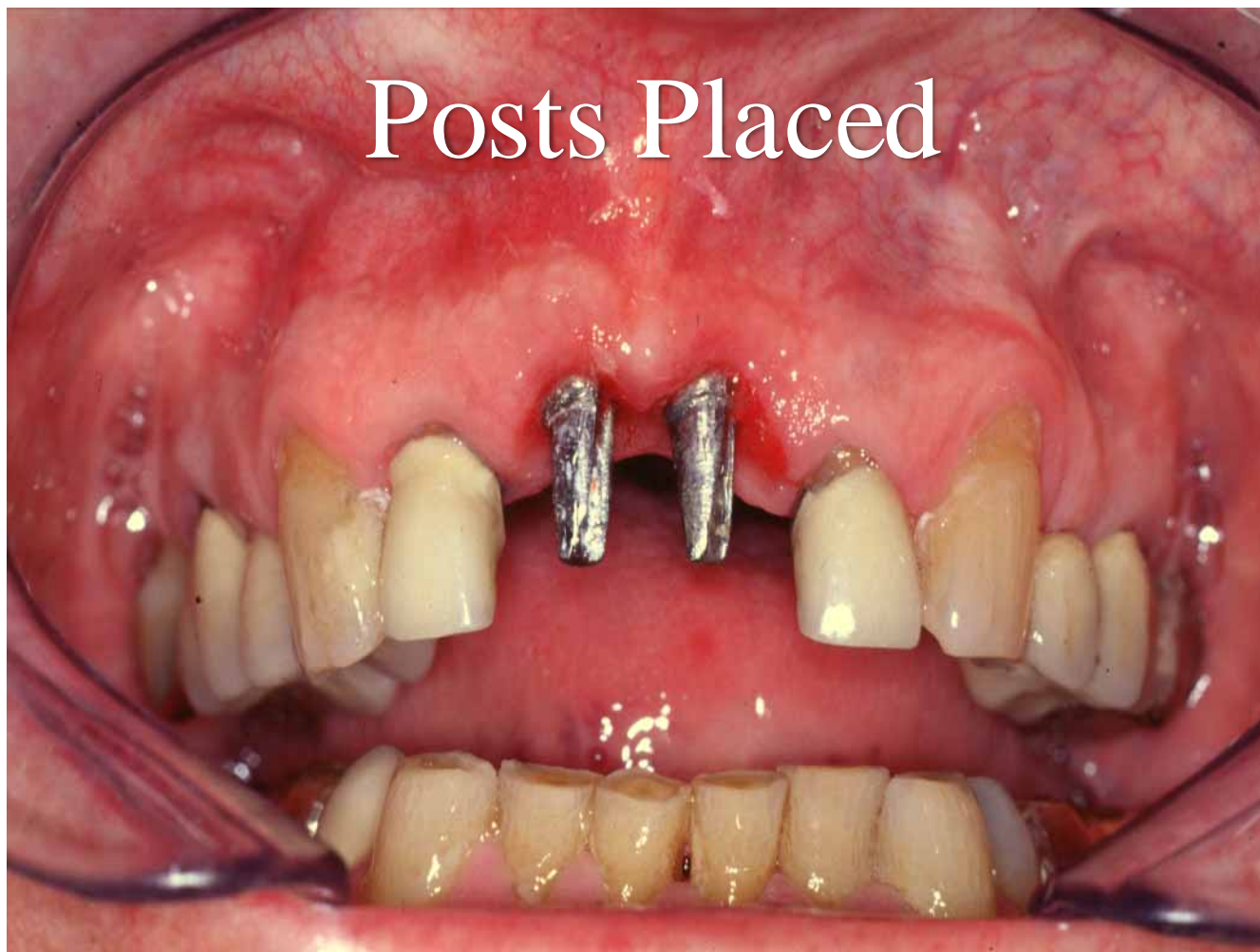Complications  
at the  
Restorative Stage

# Loose Implant at Crown Fitting

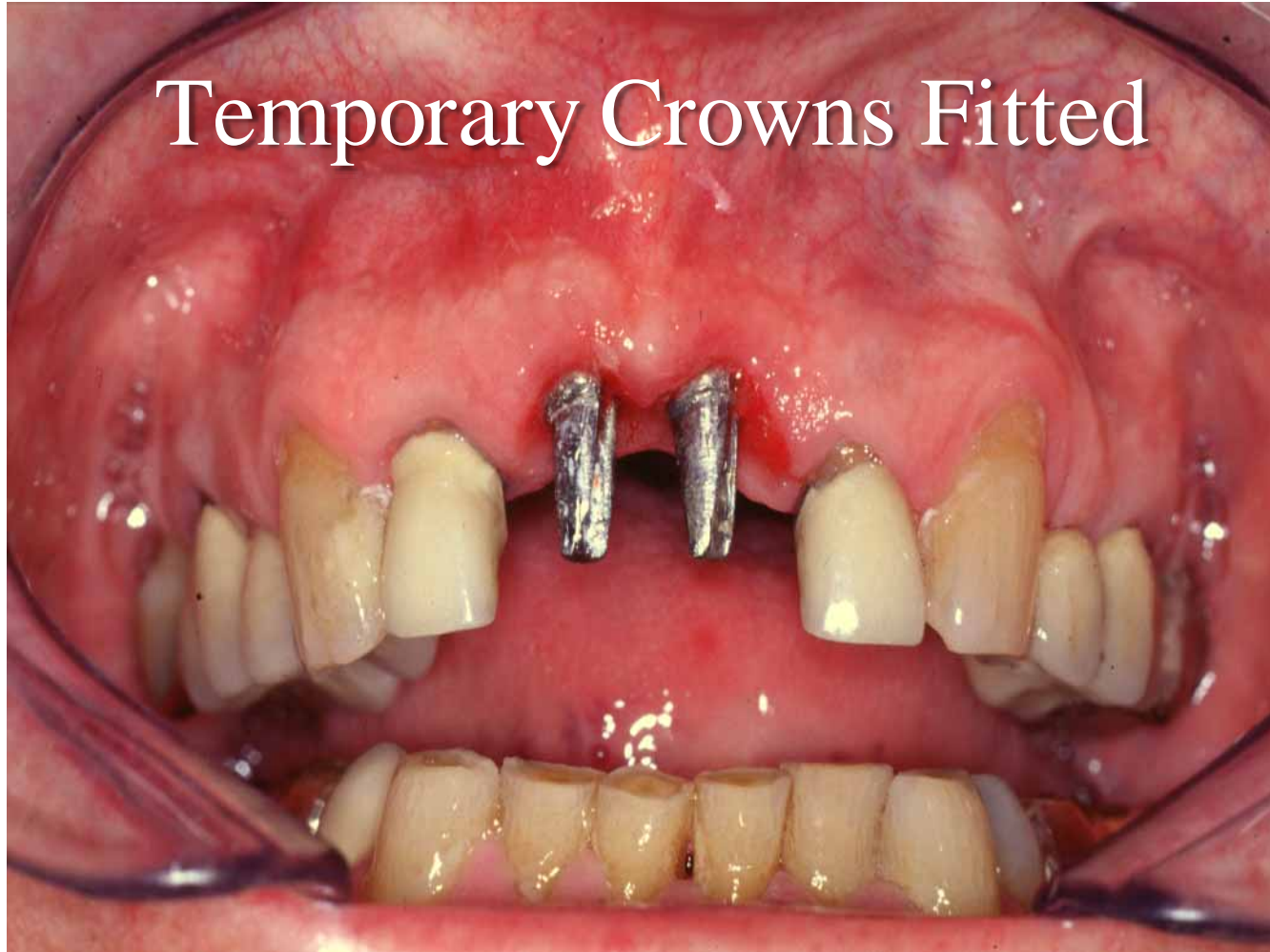Post Placement 20/12/1999



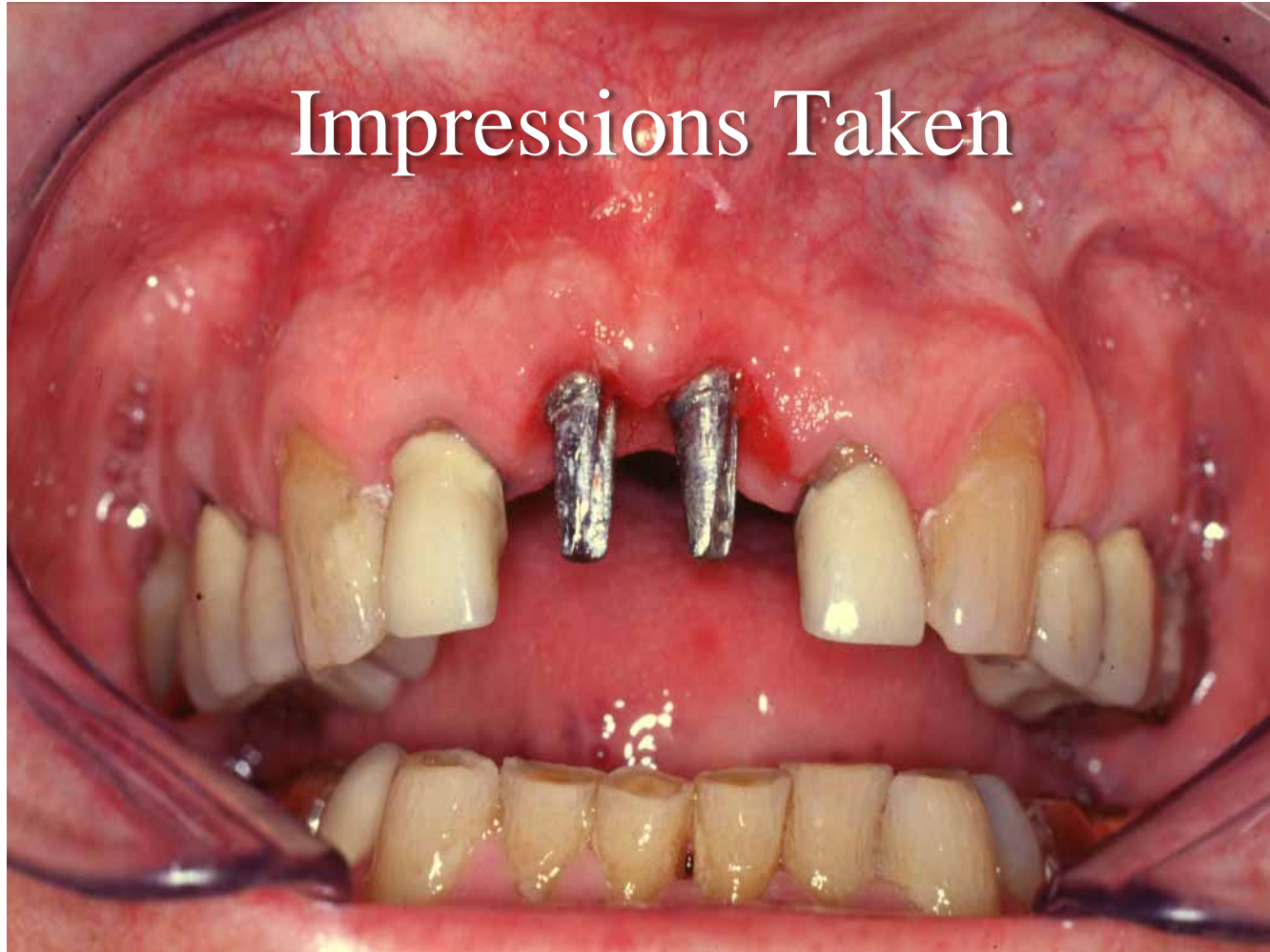
Posts Placed



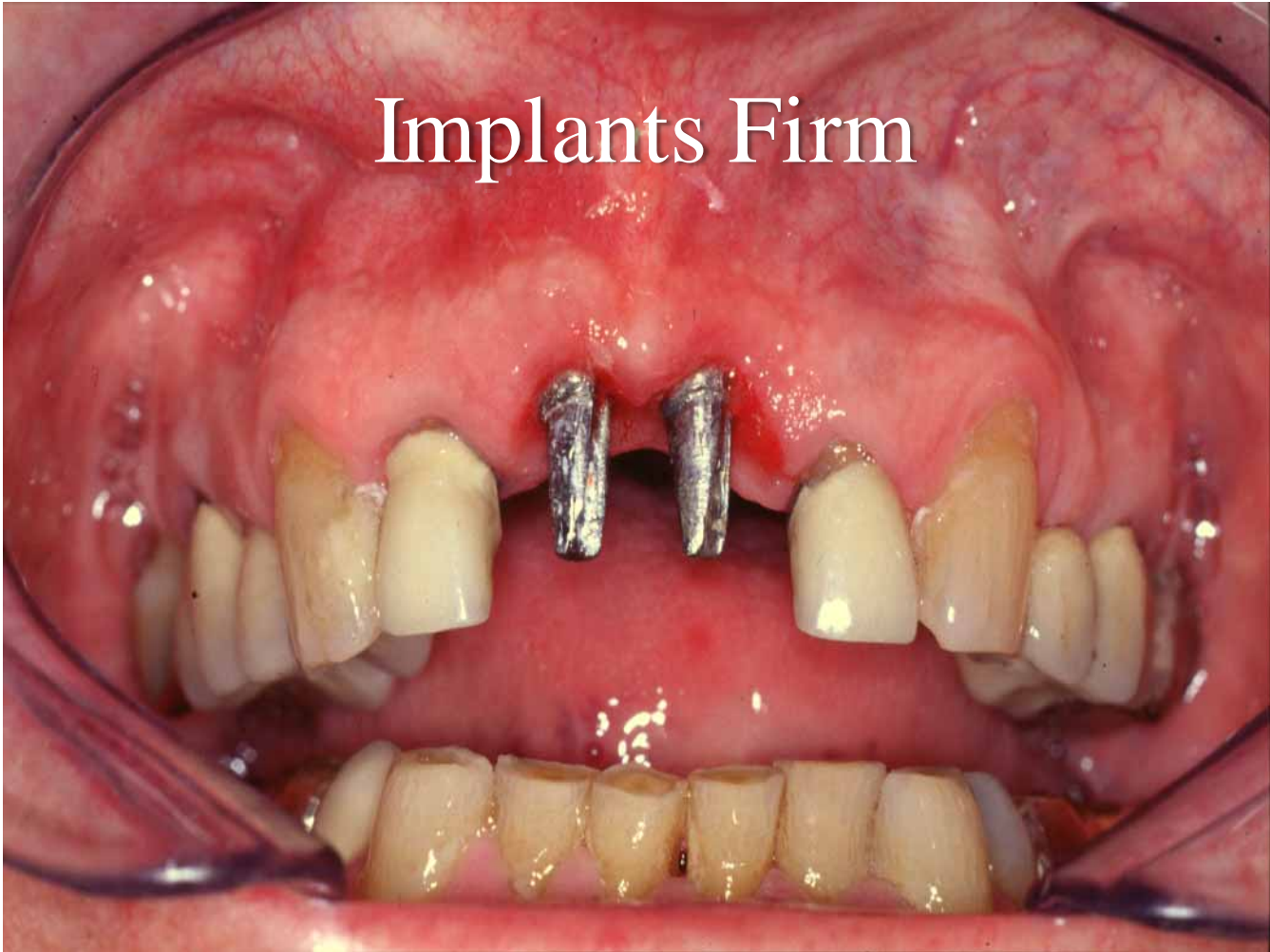
Temporary Crowns Fitted



Impressions Taken

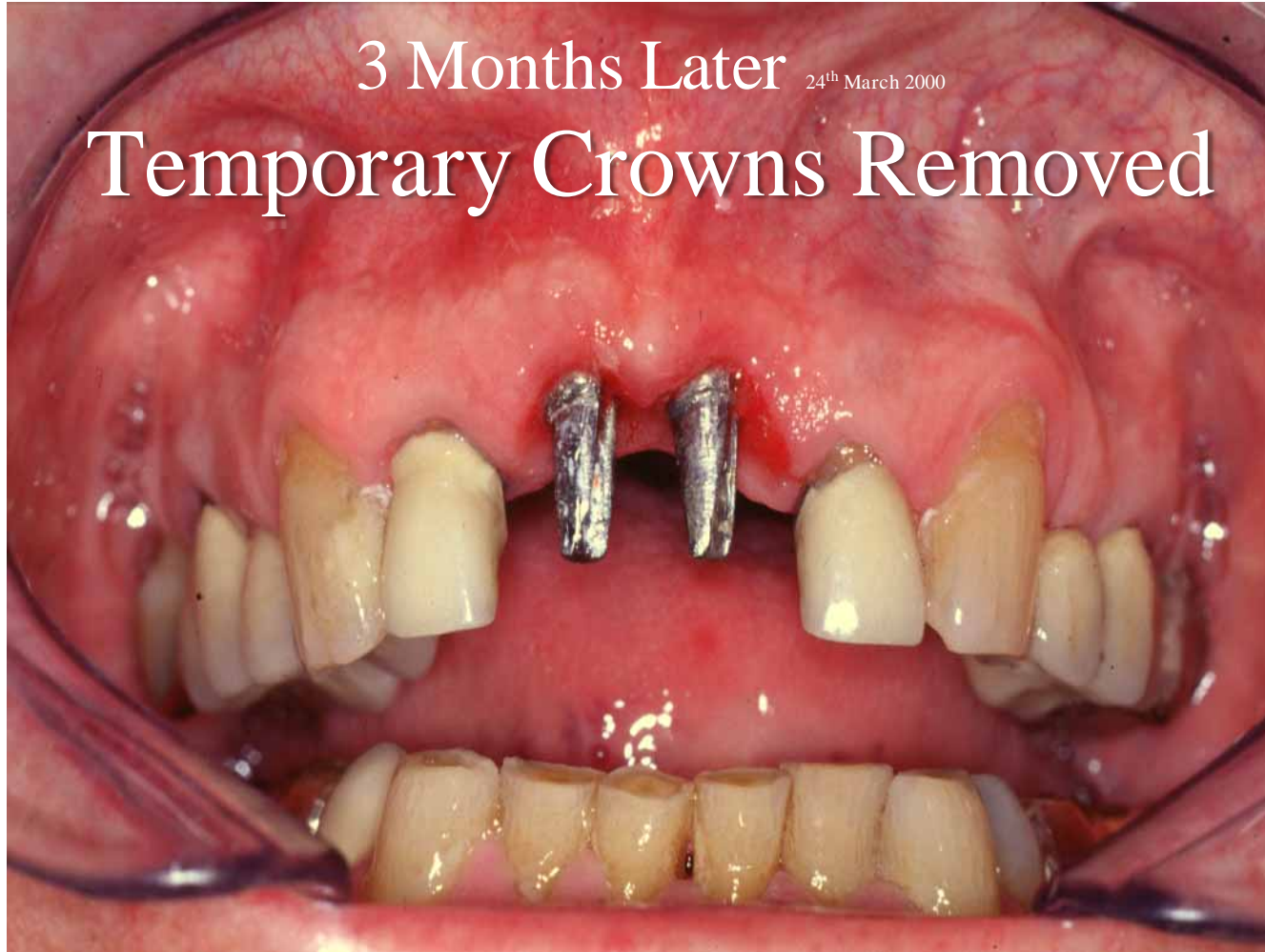

Implants Firm

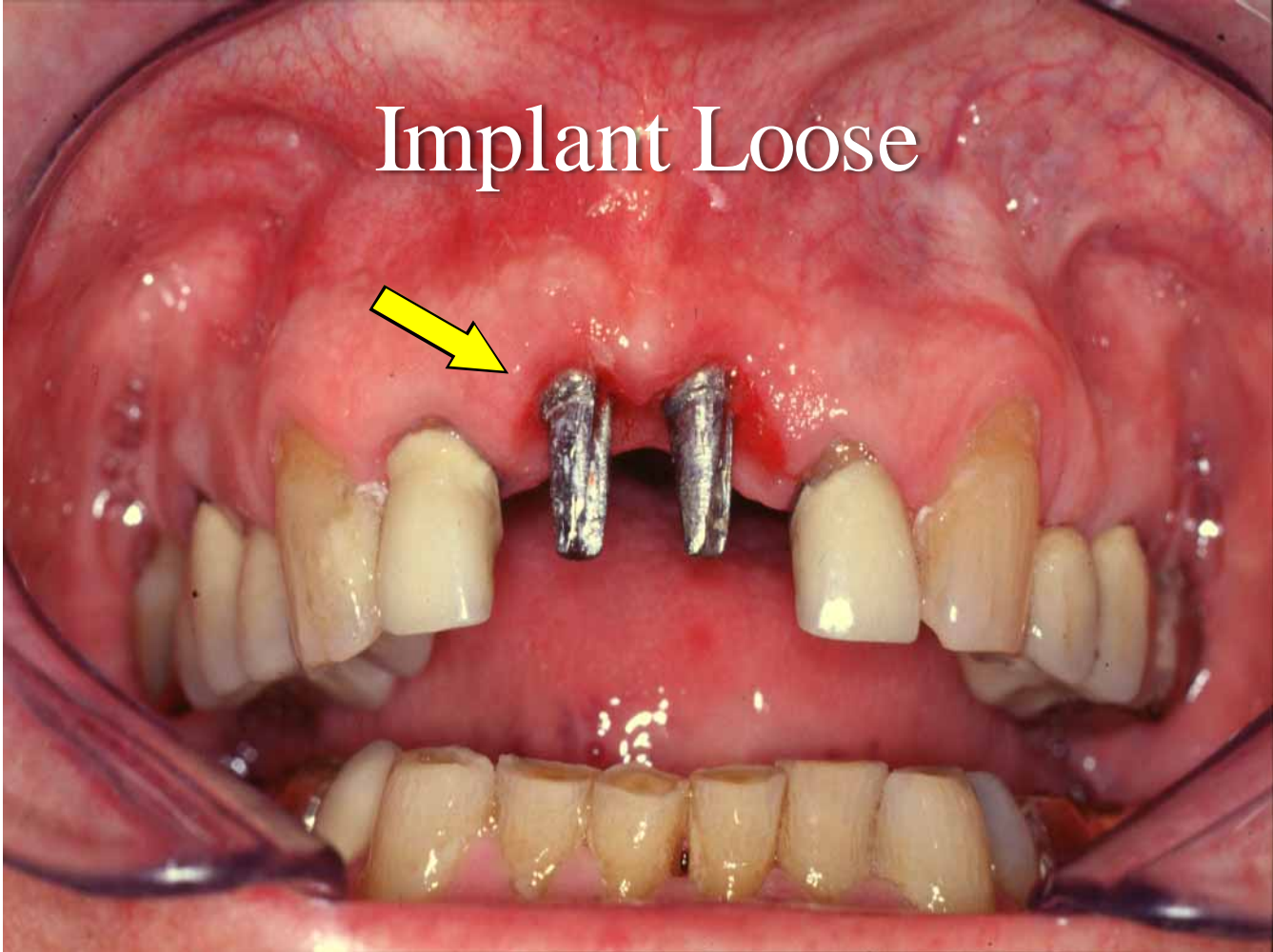


3 Months Later 24<sup>th</sup> March 2000

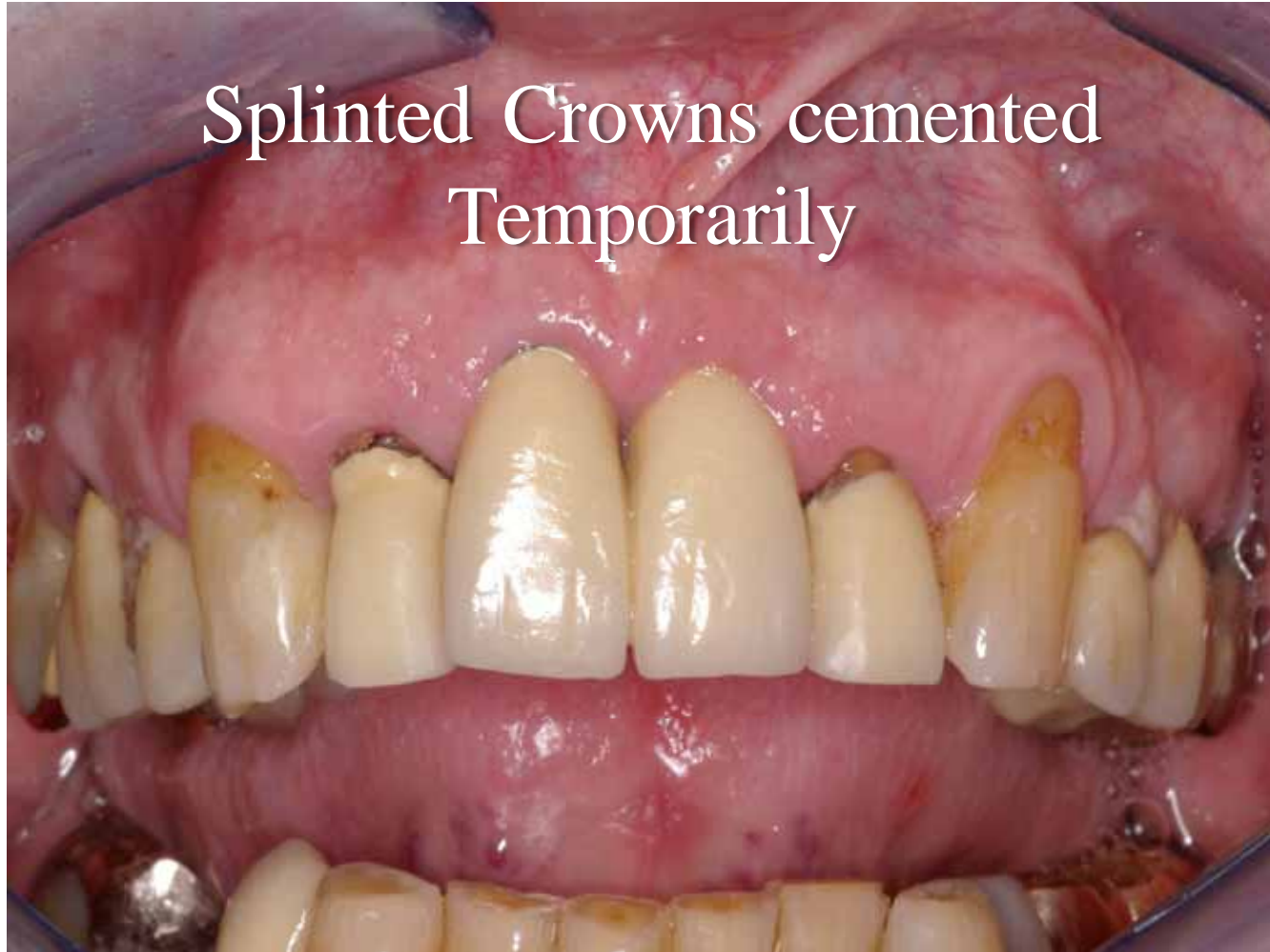Temporary Crowns Removed



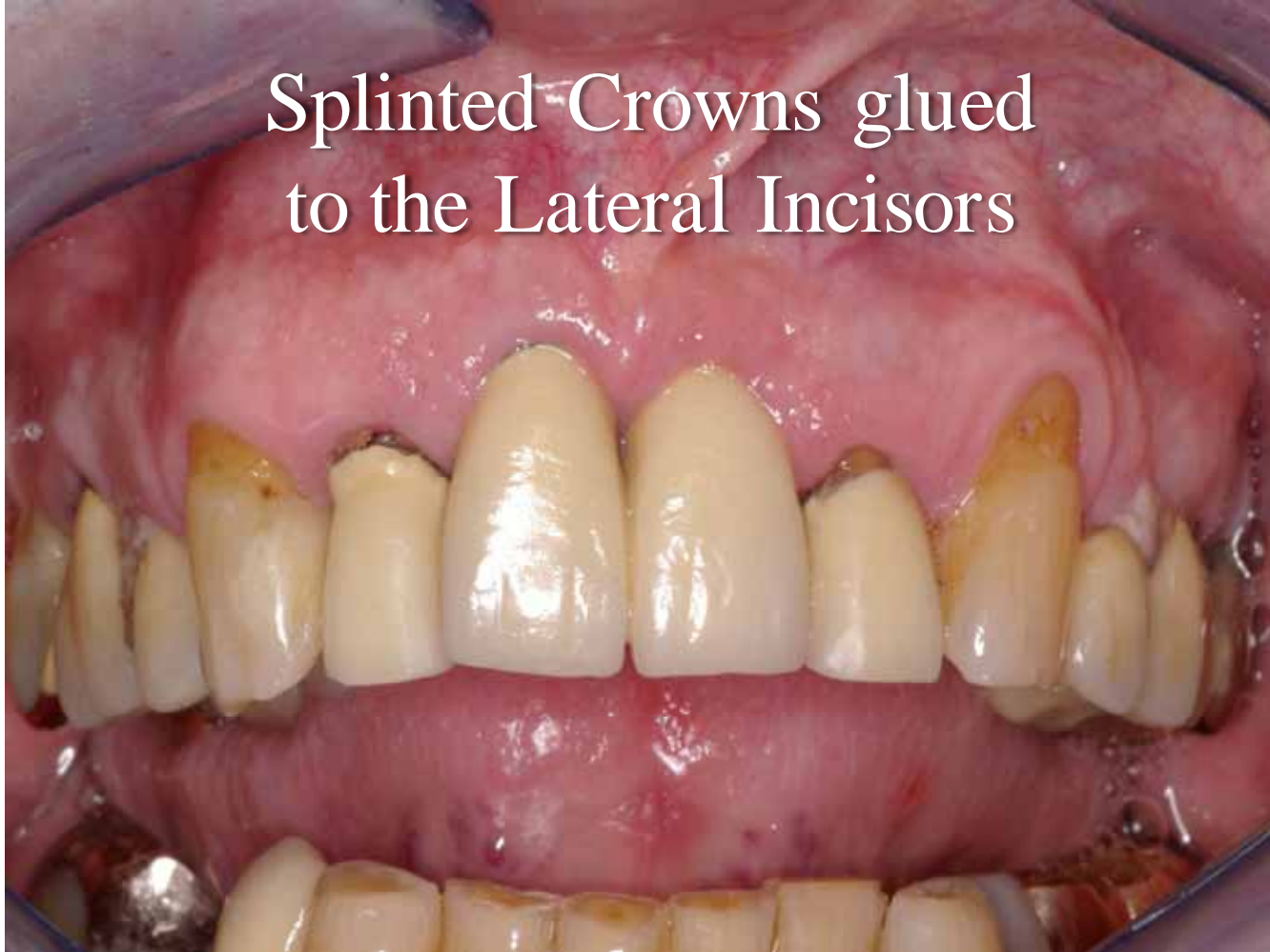Implant Loose



Splinted Crowns cemented  
Temporarily

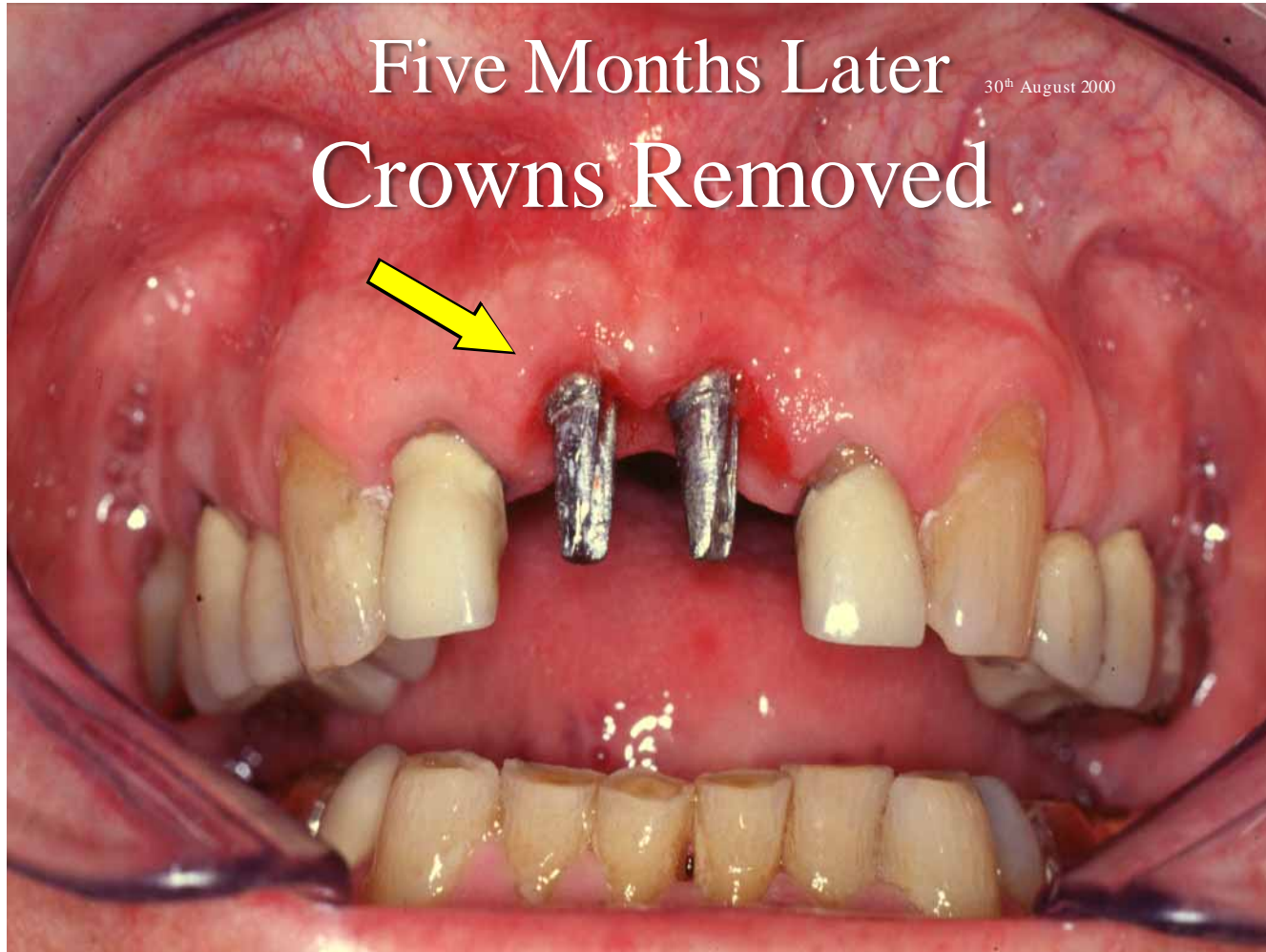

Splinted Crowns glued  
to the Lateral Incisors

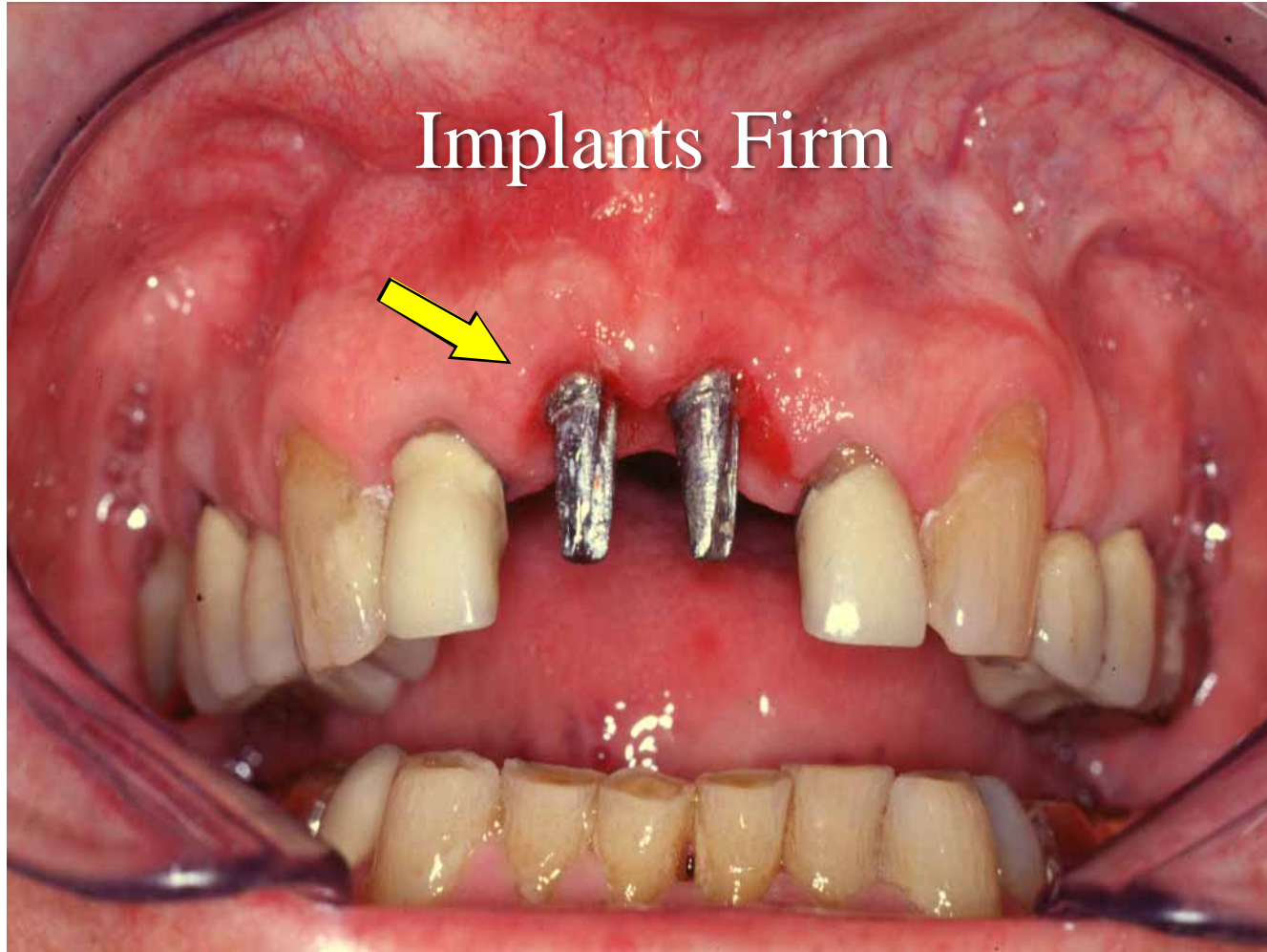


Five Months Later  
Crowns Removed

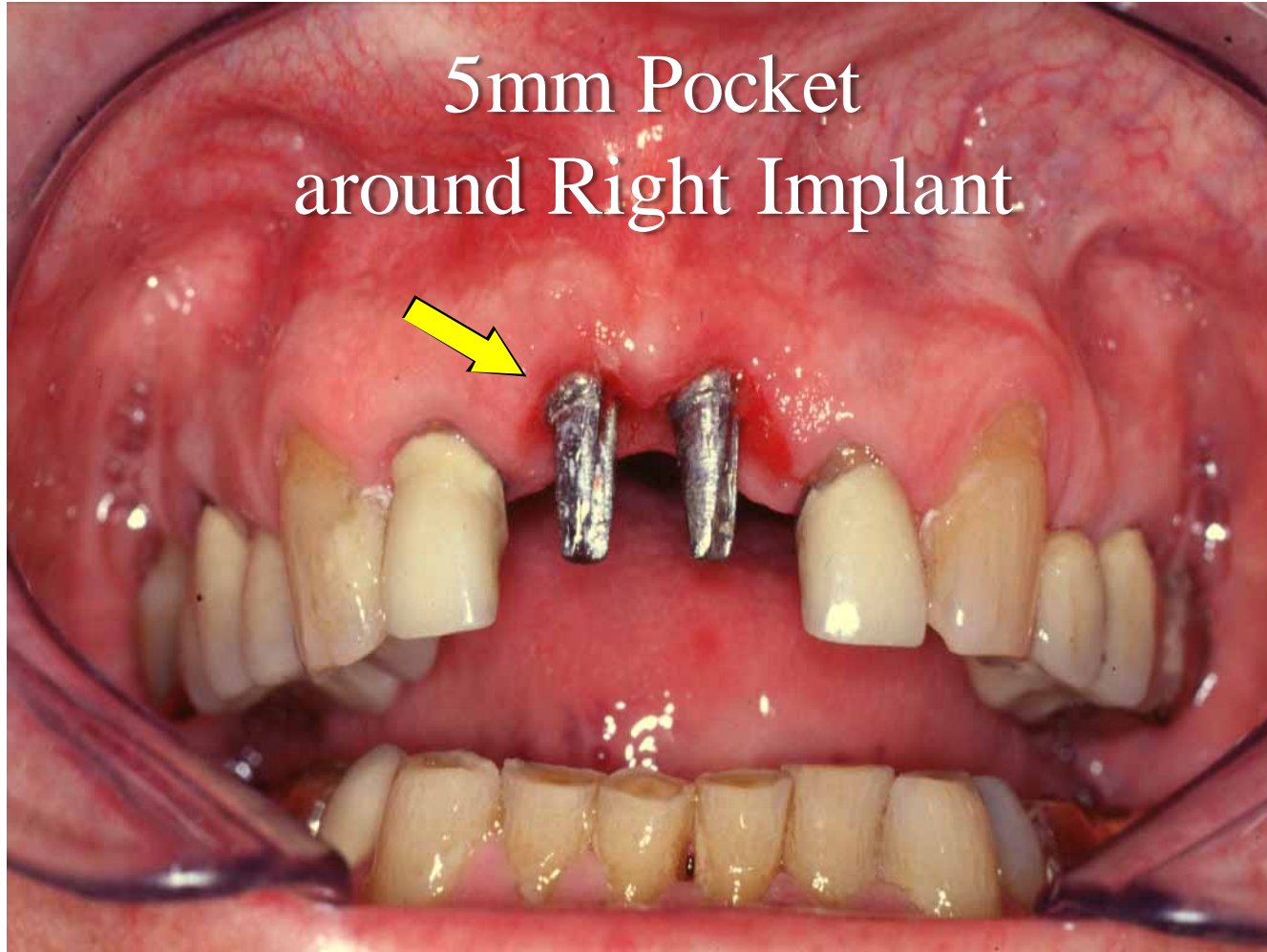
30<sup>th</sup> August 2000



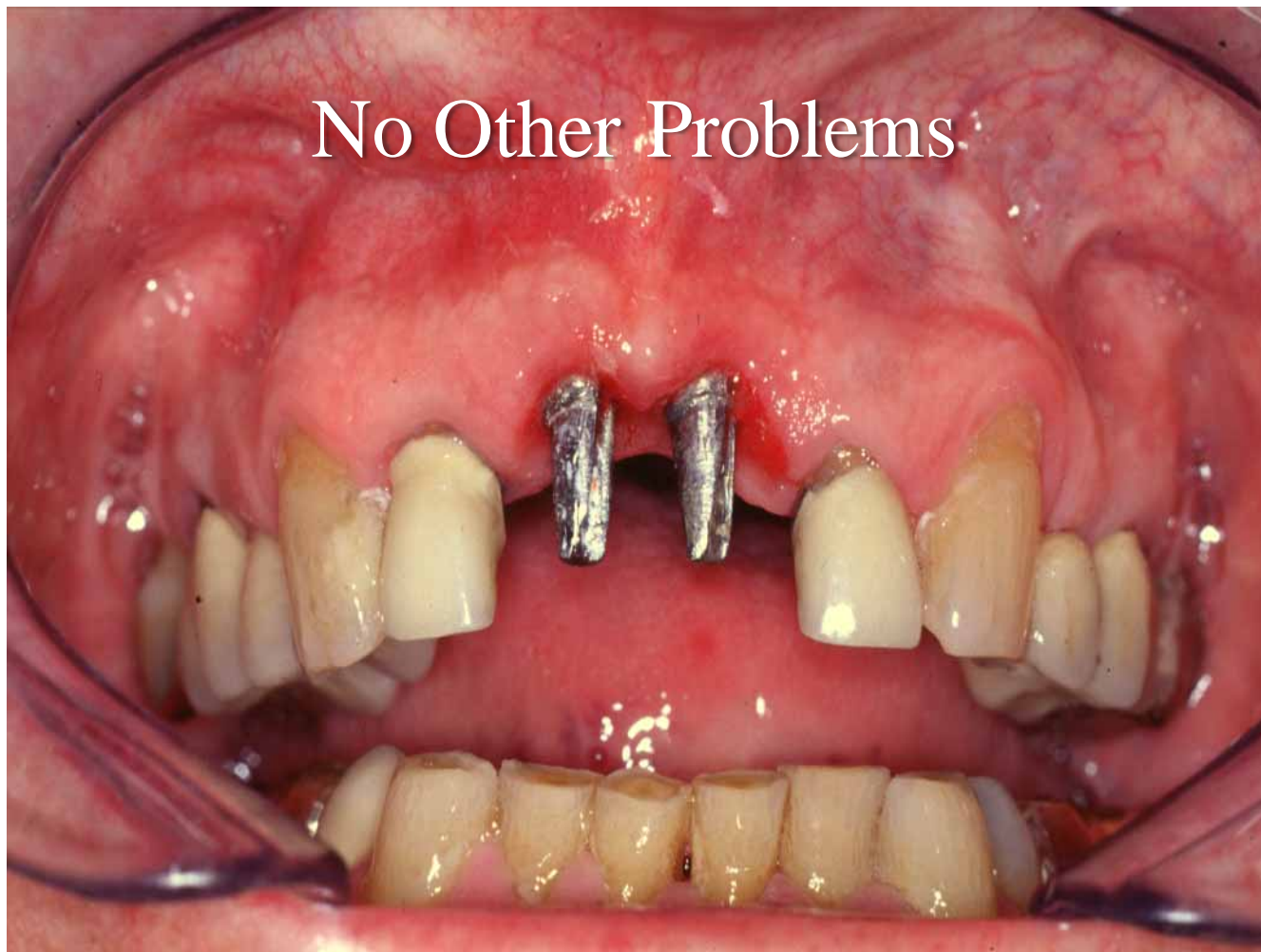Implants Firm

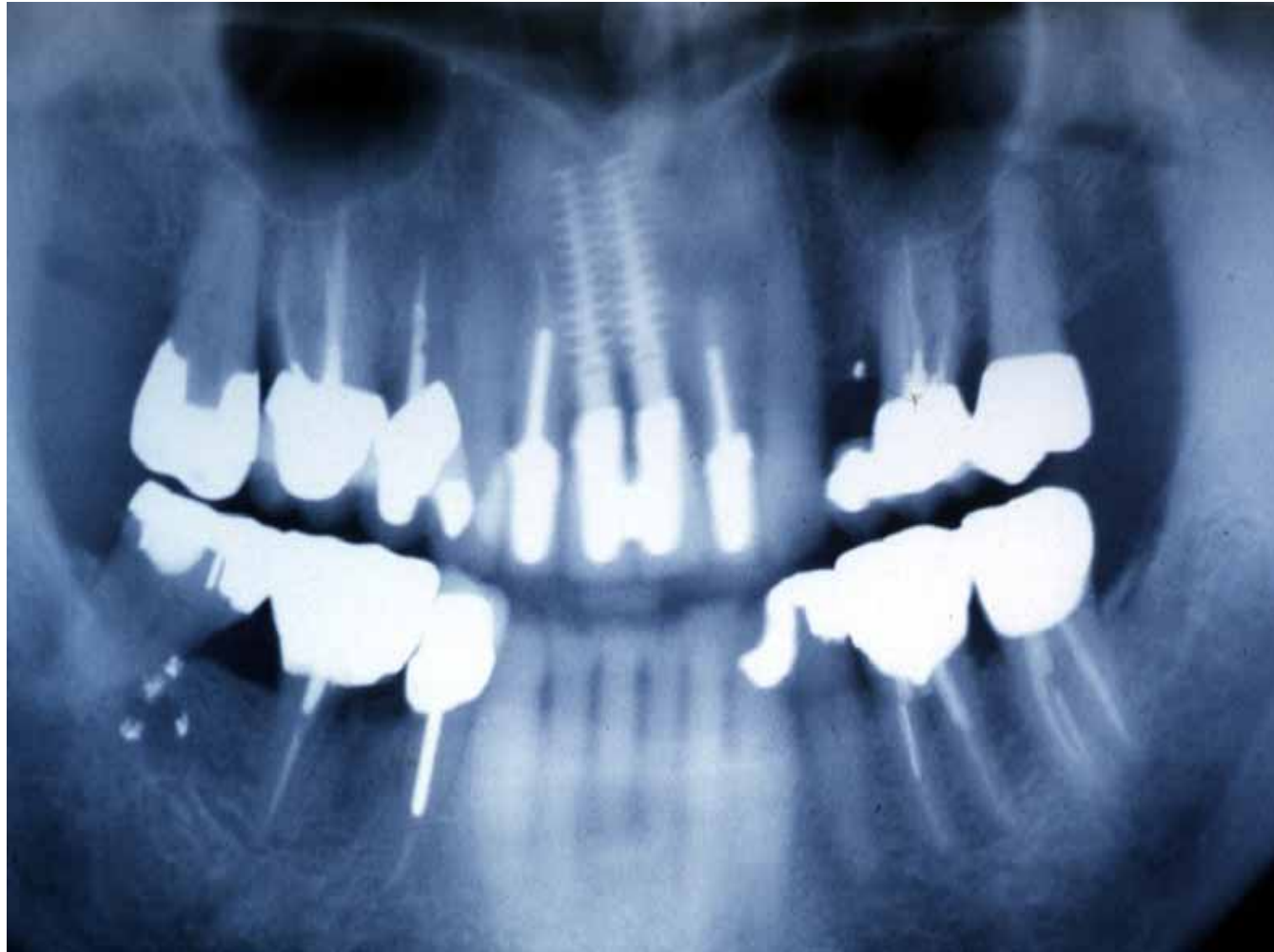

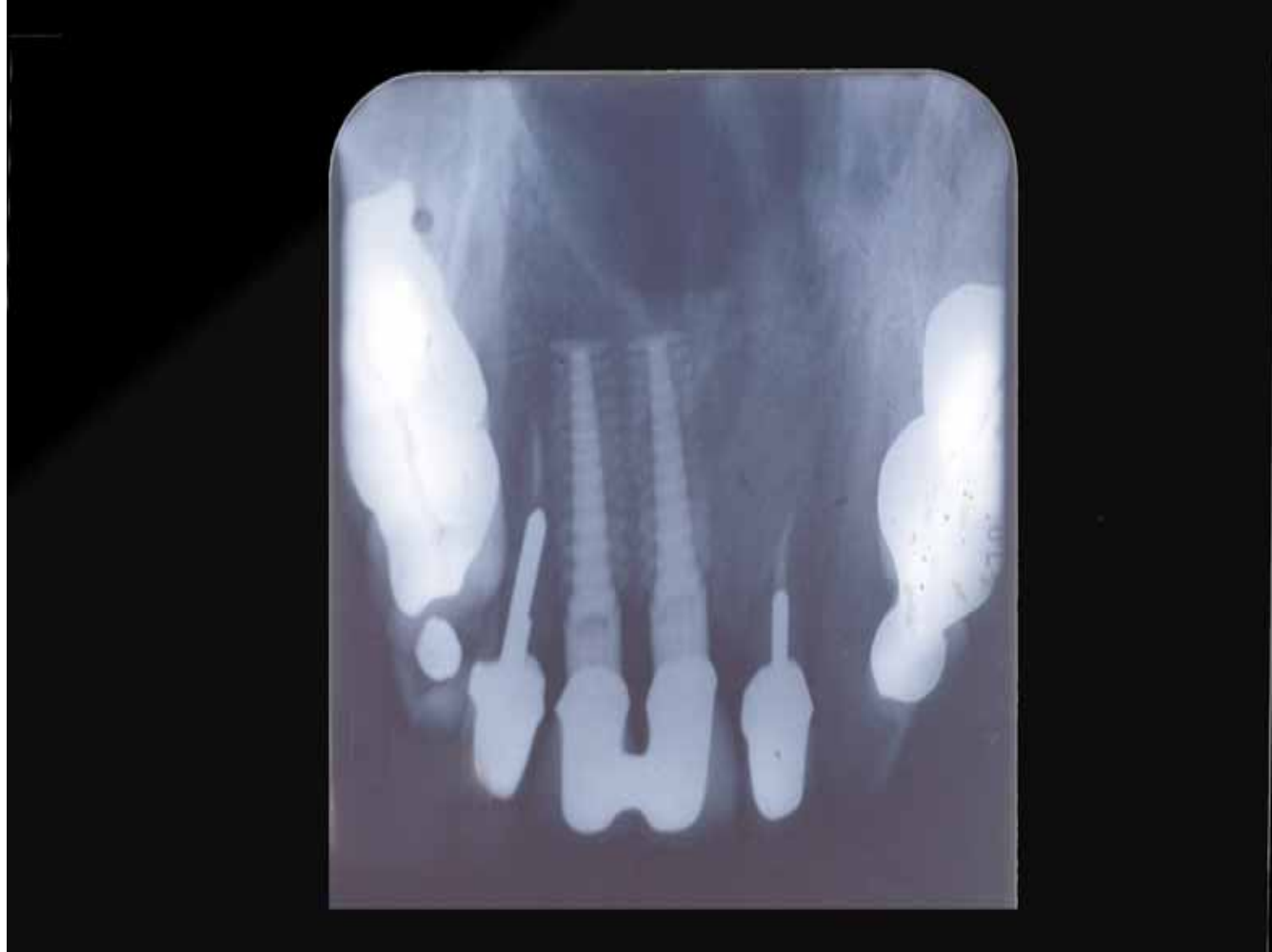5mm Pocket  
around Right Implant



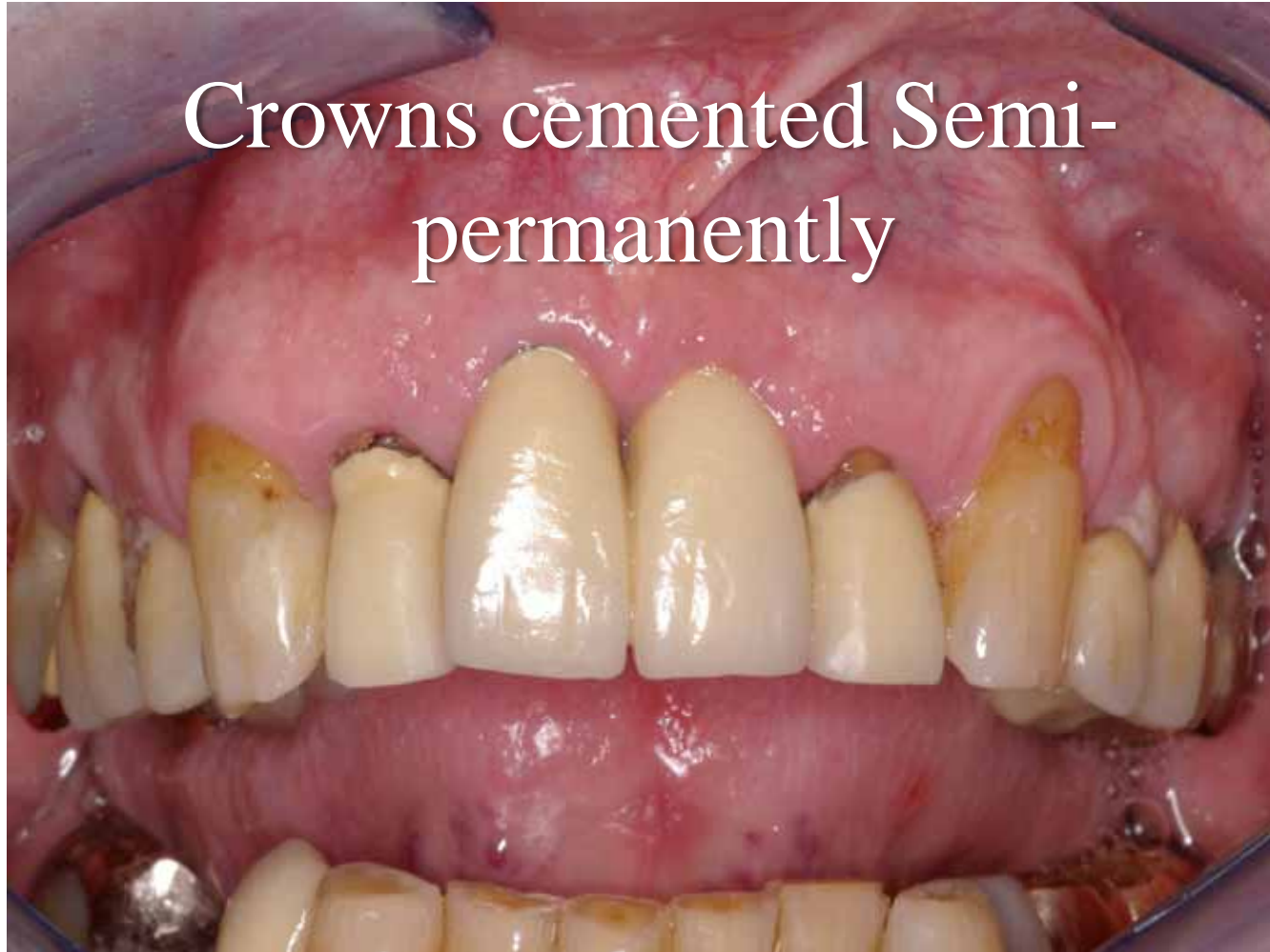No Other Problems







Crowns cemented Semi-  
permanently




# Porcelain Fracture Case Report


At the Time of Crown Fitting

Part of the Crown Fractured off

## The Fractured Crown



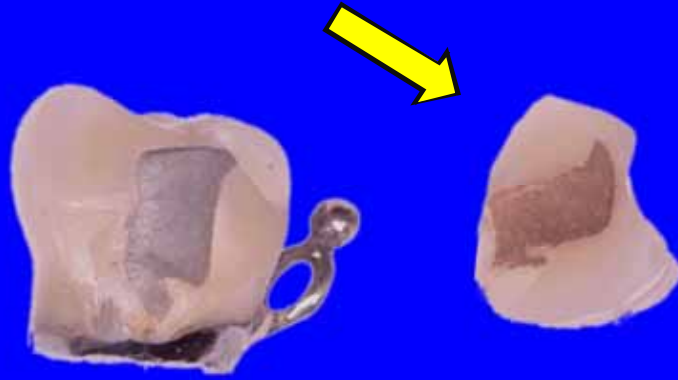
## The Fractured Piece



# The Fractured Crown



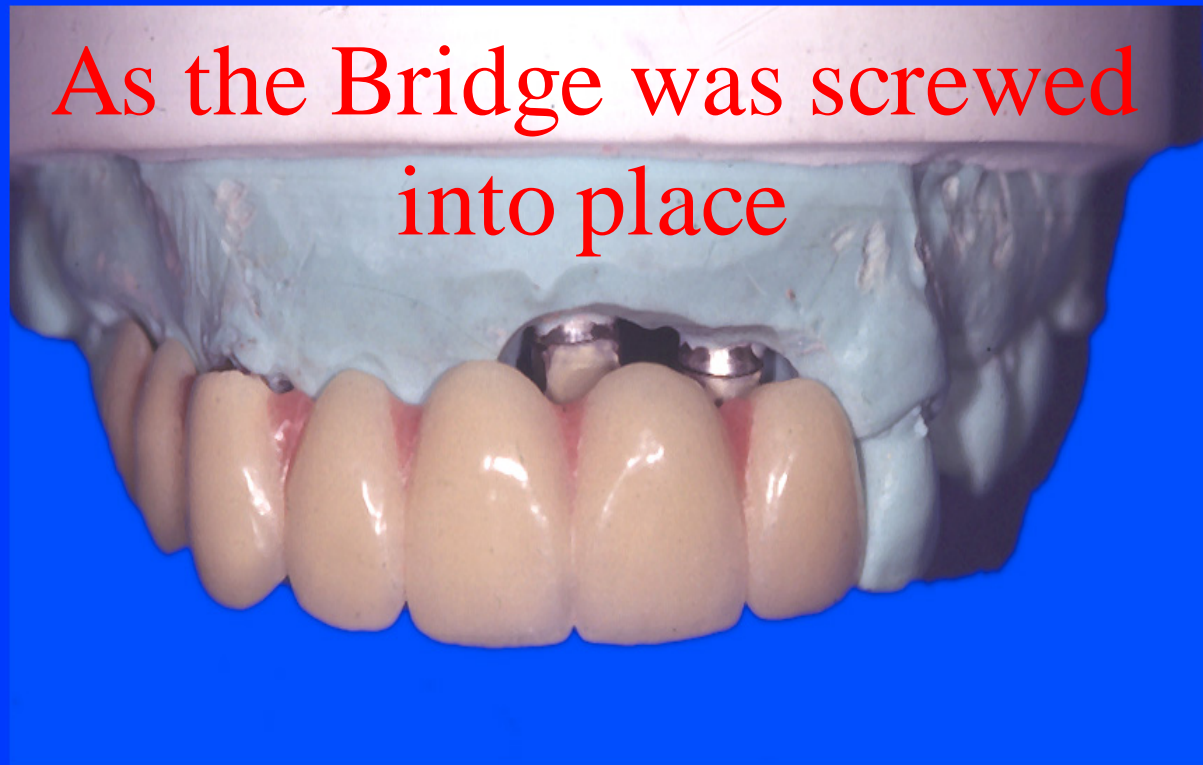# The Fractured Piece



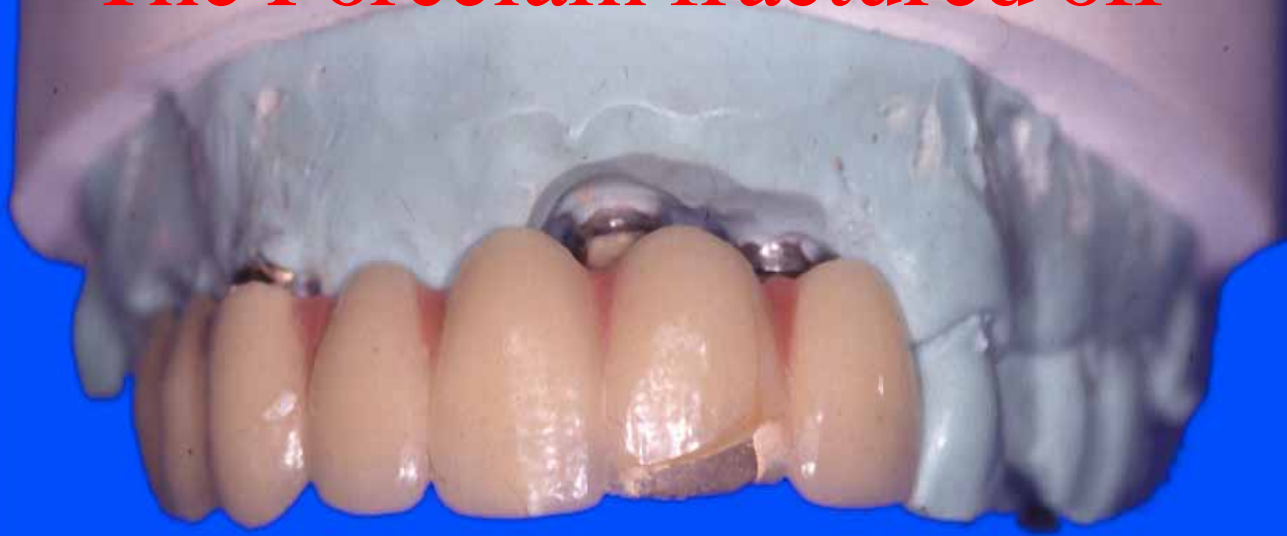# Porcelain Fracture Case Report

Porcelain Fracture as the Bridge  
was Screwed into place

As the Bridge was screwed  
into place



The Porcelain fractured off



# Poor Fit

Fit Checker used to Check the Fit  
Adjustments may need to be Made

Instrument Dropped  
down a Patient's Throat  
Case Reports

# Case History 1

- A Screw Driver was dropped down a Patient's Throat
- It passed into the Larynx
- The Patient sat up and coughed it out

## Case History 2

- At a Conference on Complications held in Chicago, USA
- Charlie English, a Well-known Prosthodontist
- showed an X-ray showing a Screwdriver in the Lung

## Case History 2

- He said that he had dropped down a Patient's Throat
- Most of the Other Lecturers showed how they solved other Dentist's Problems

## Case History 3

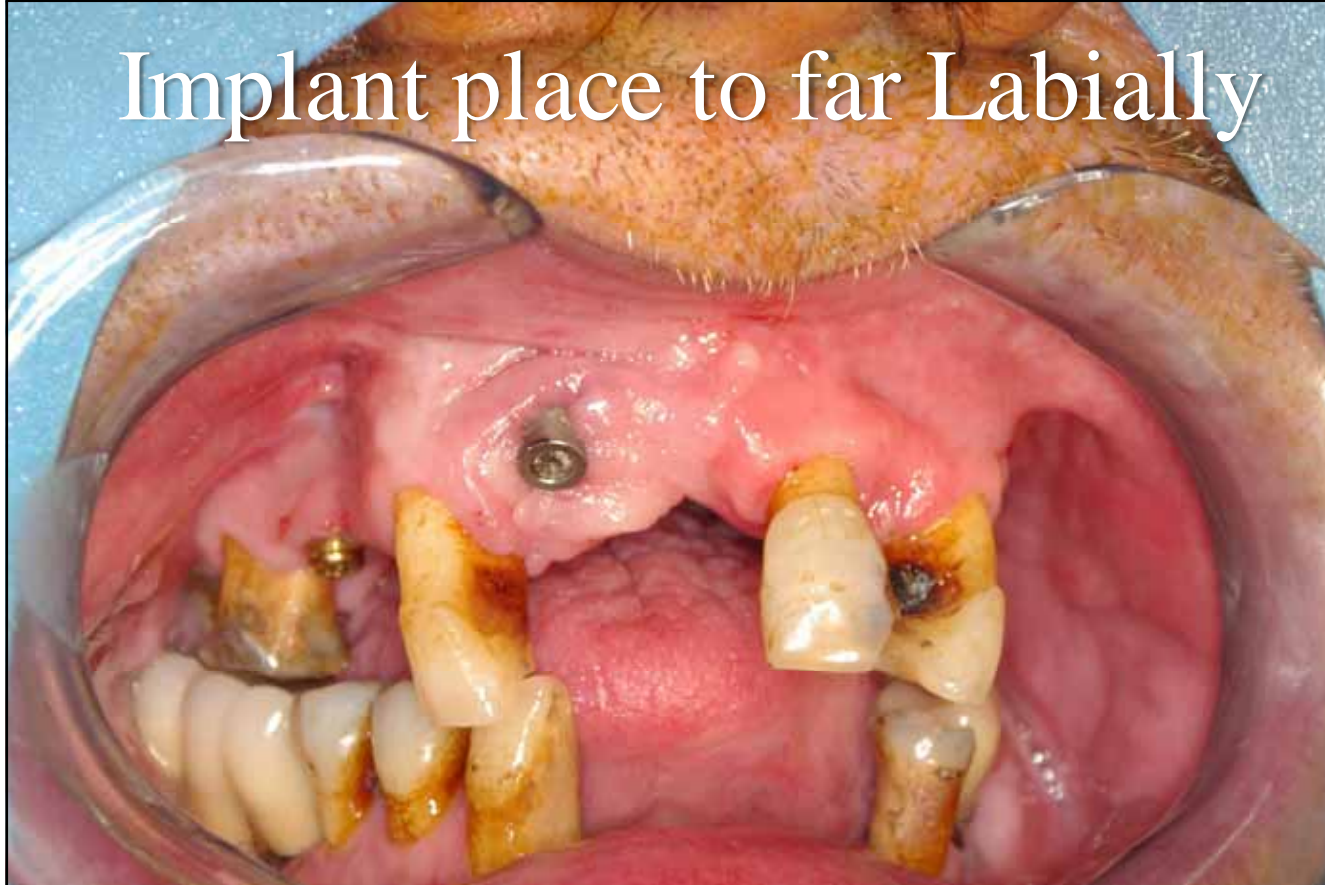- A Screwdriver was dropped down a Patient's Throat
- The Patient was sent for a Chest X-ray and an Abdominal X-ray
- The Patient telephoned later that Day complaining how long it took to have the X-ray taken

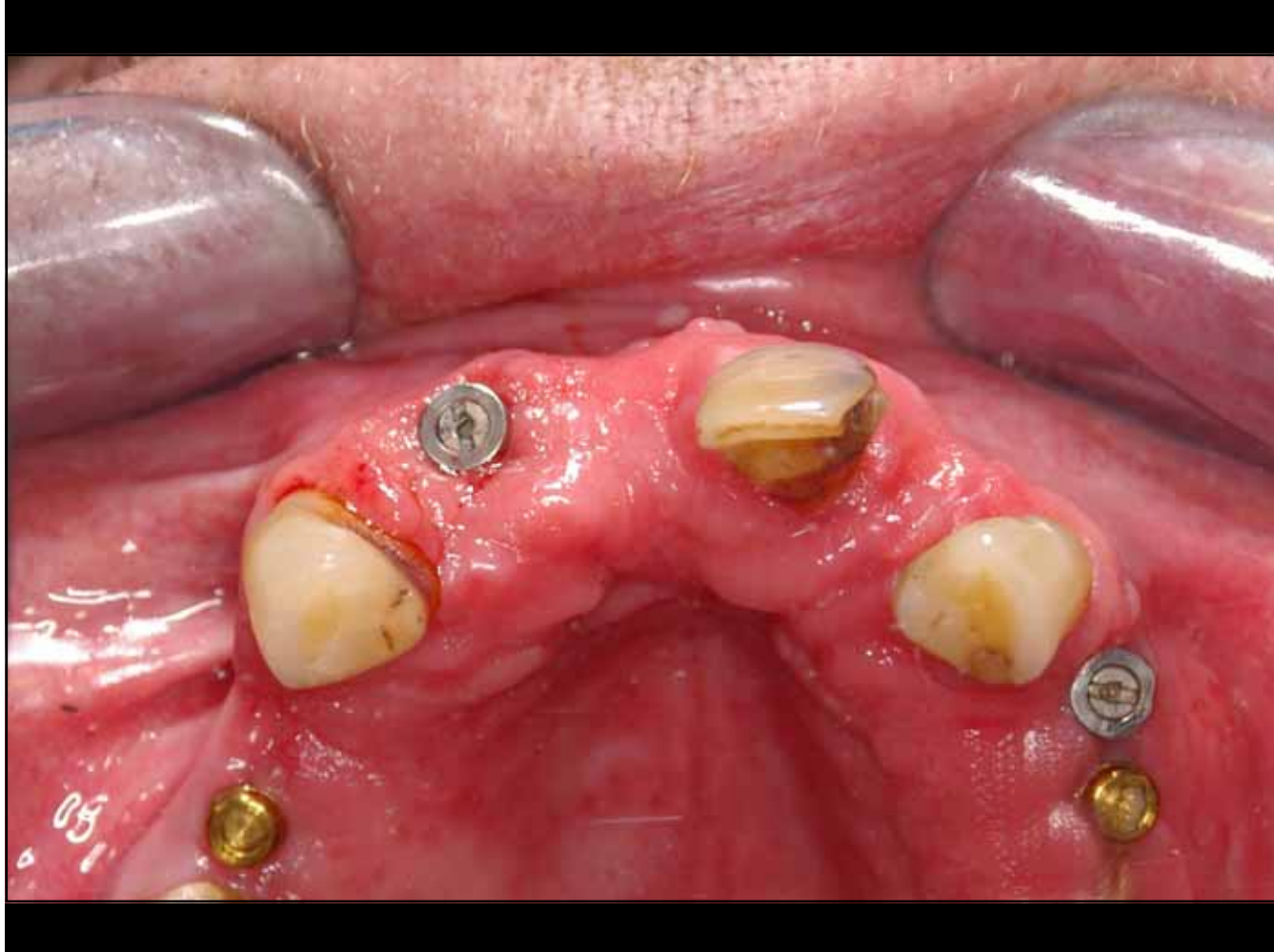- The Next Morning the Patient arrived at the Practice
- on meeting the Dentist he said
- “Thank you. You have saved my Life
- They found an Aortic Aneurysm
- and they are operating Tomorrow”

Add Davidge

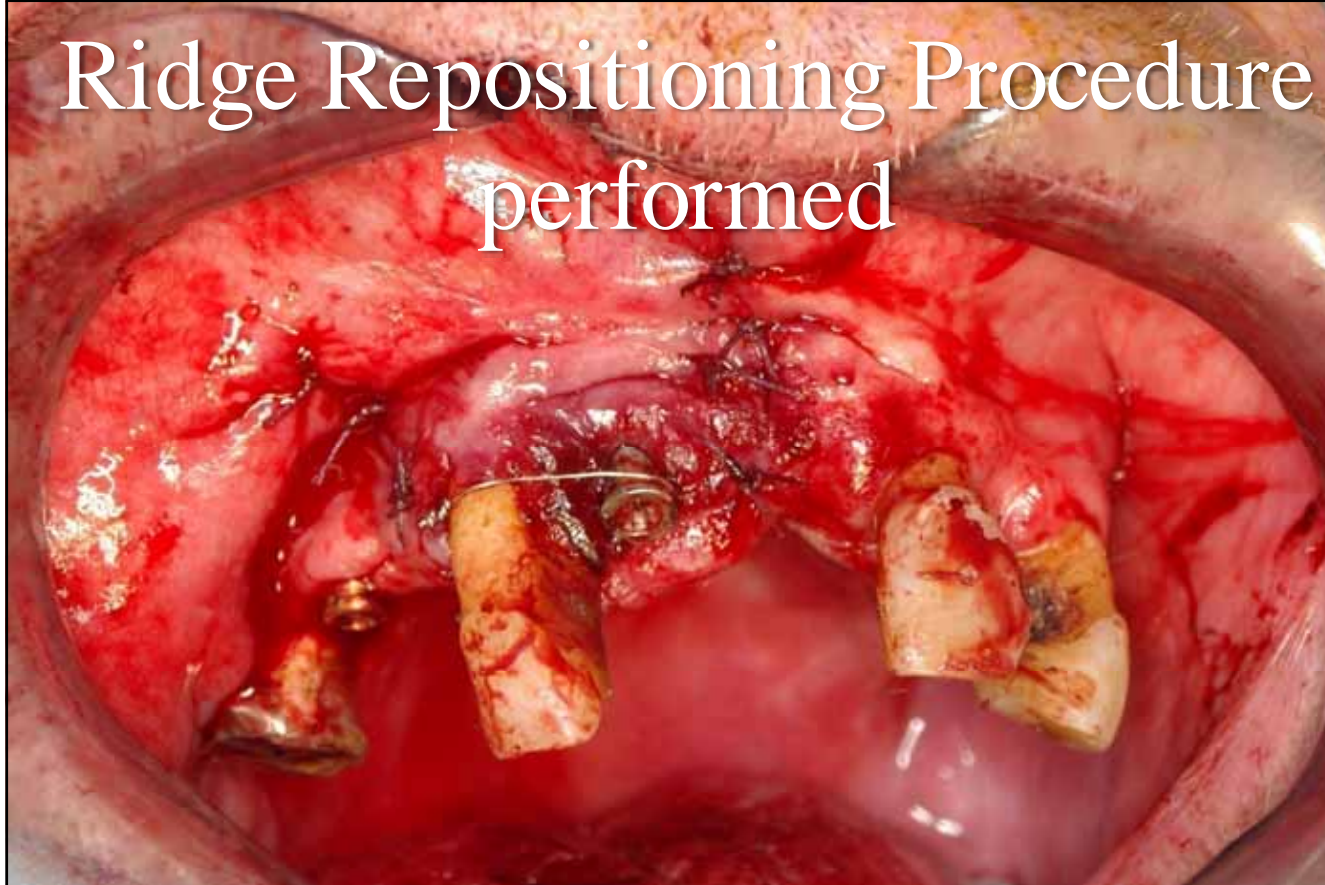
# Implant Repositioning

Implant place to far Labially

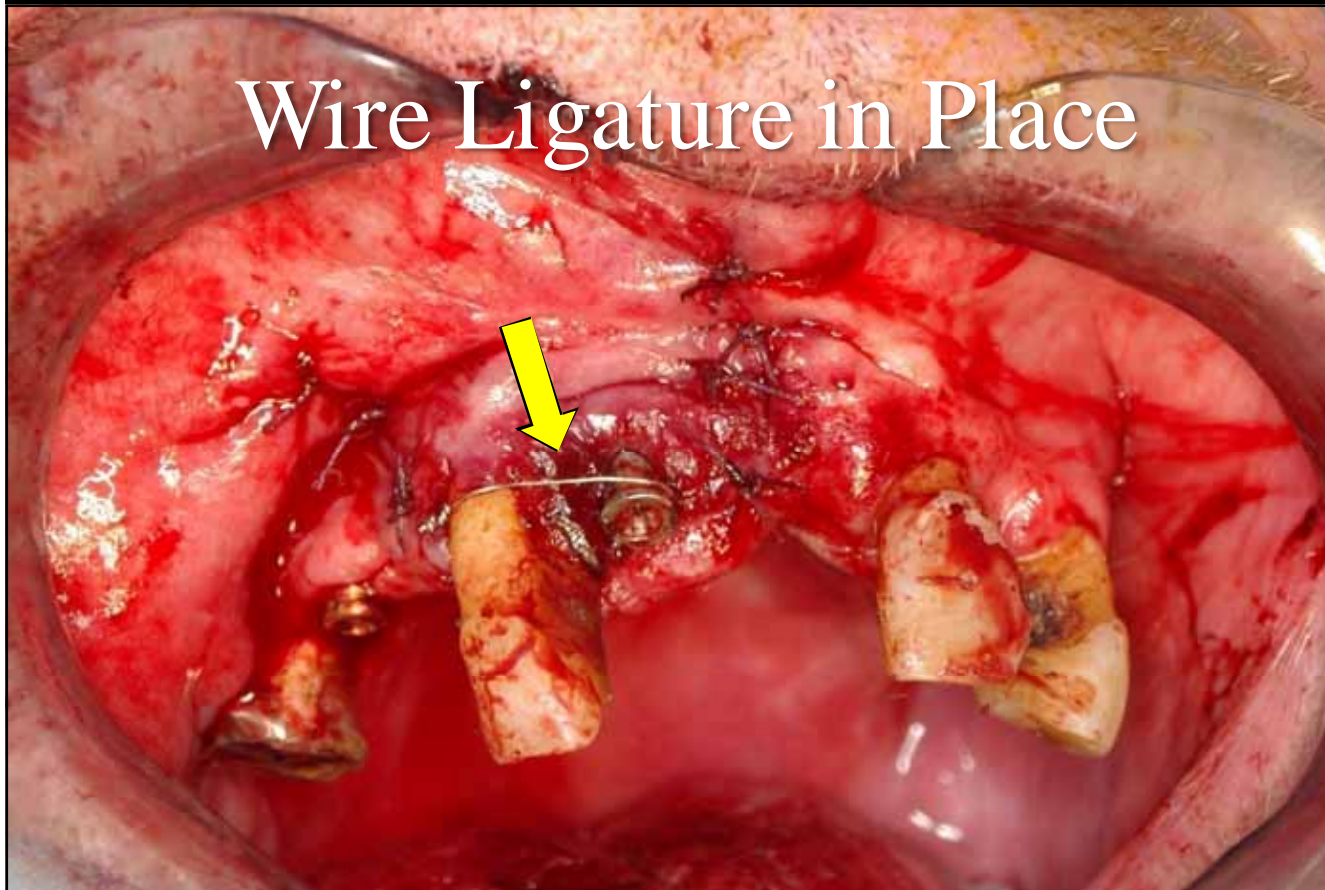


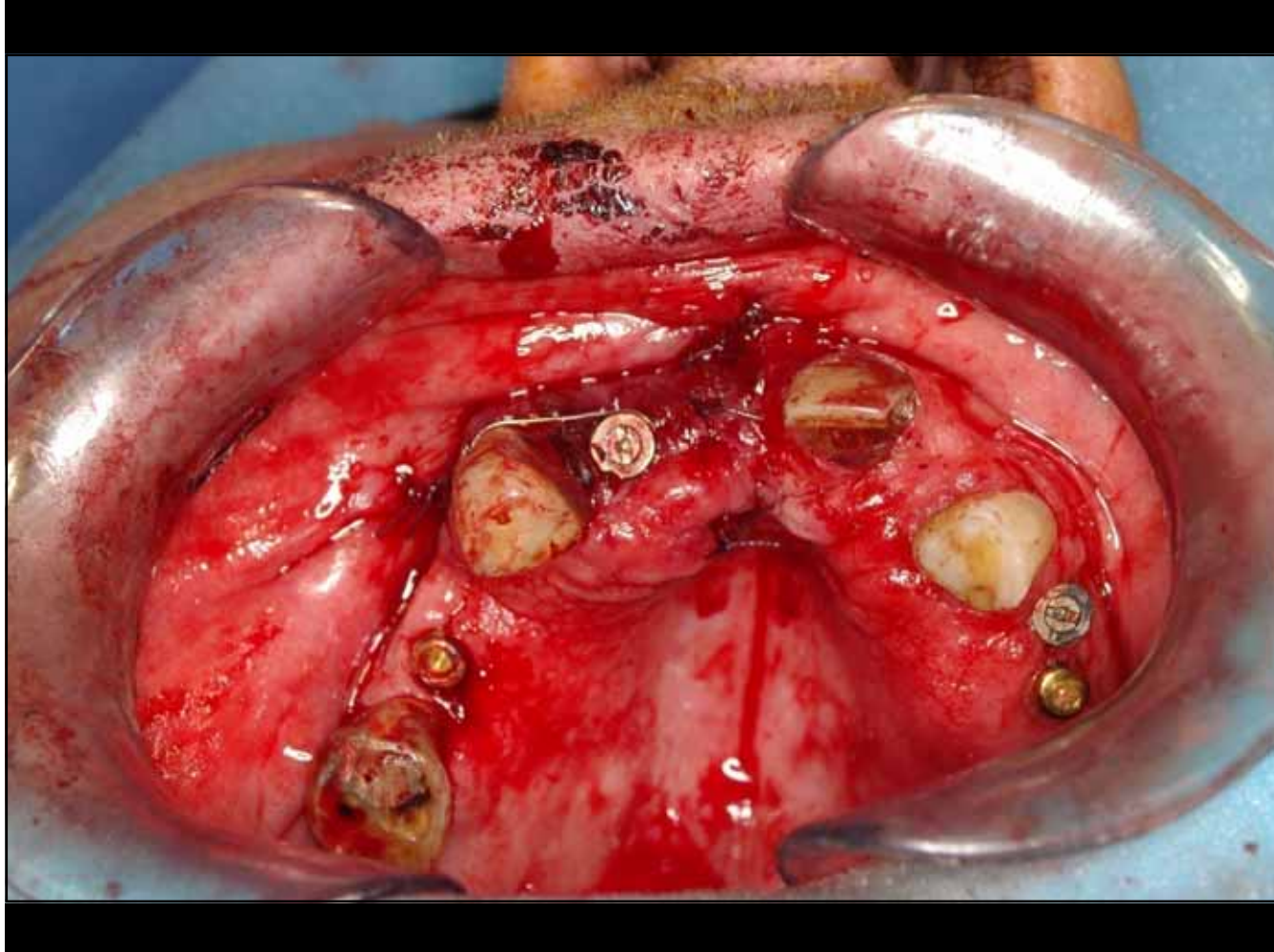


# Ridge Repositioning Procedure performed

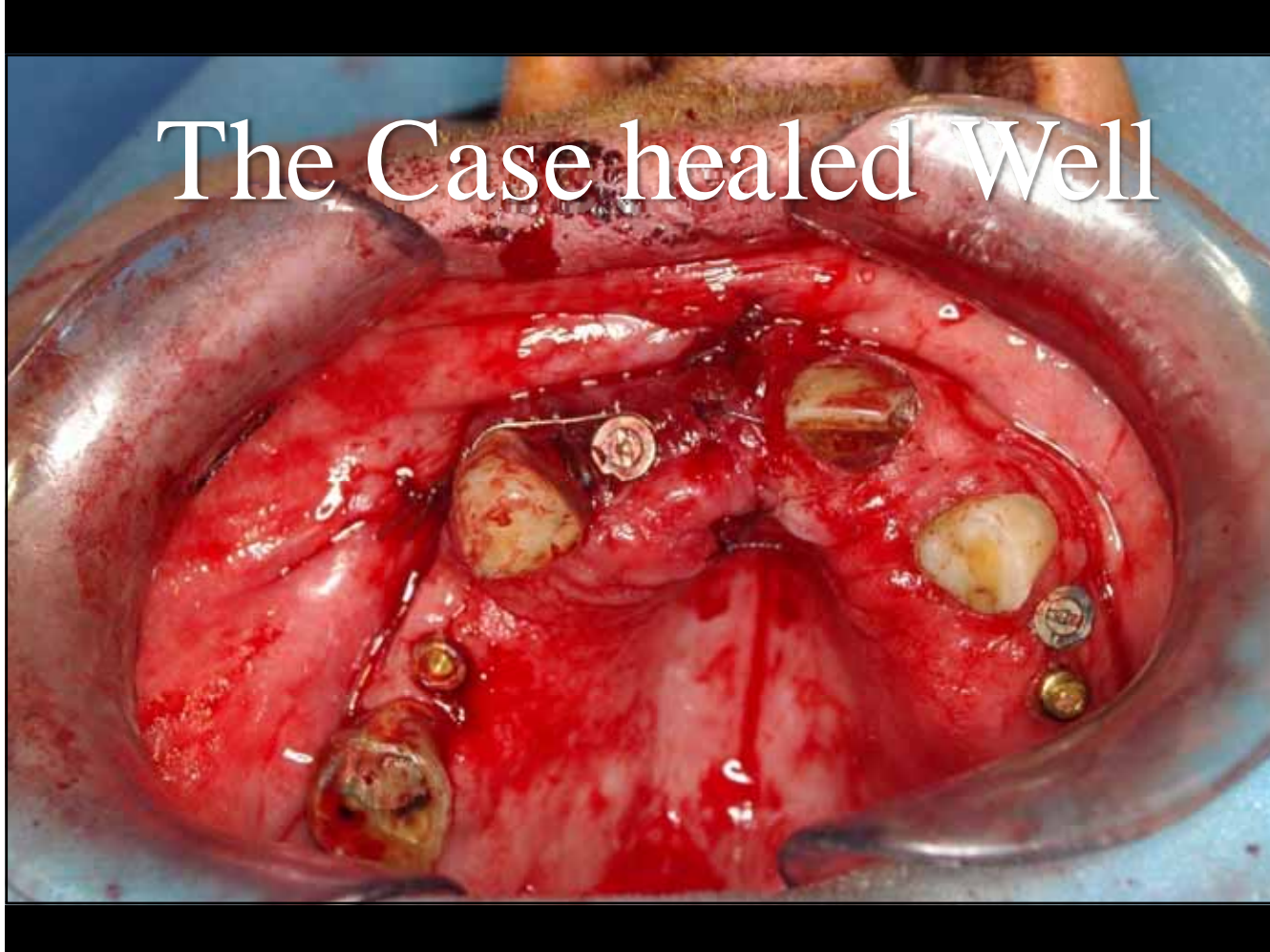

Wire Ligature in Place

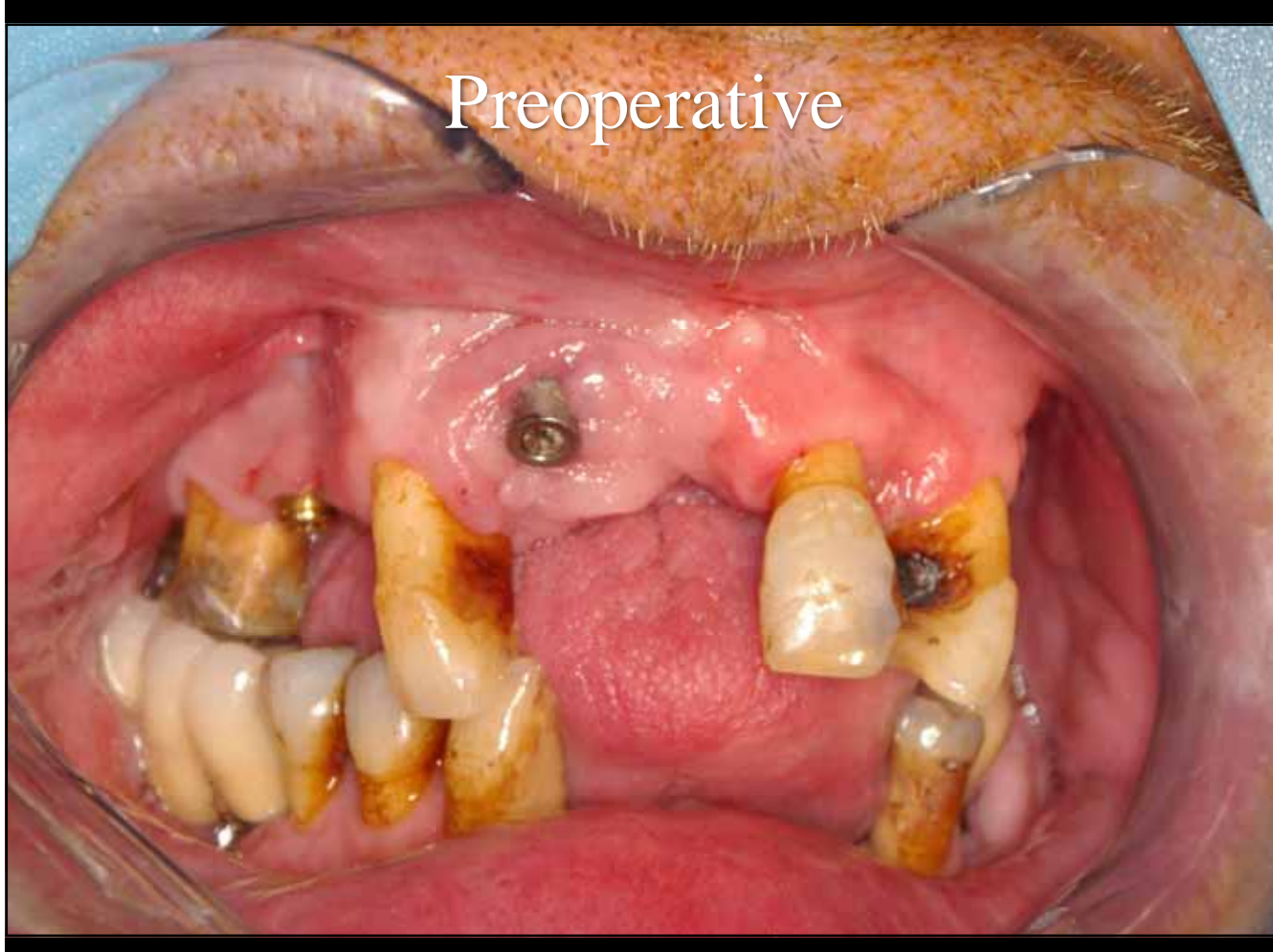




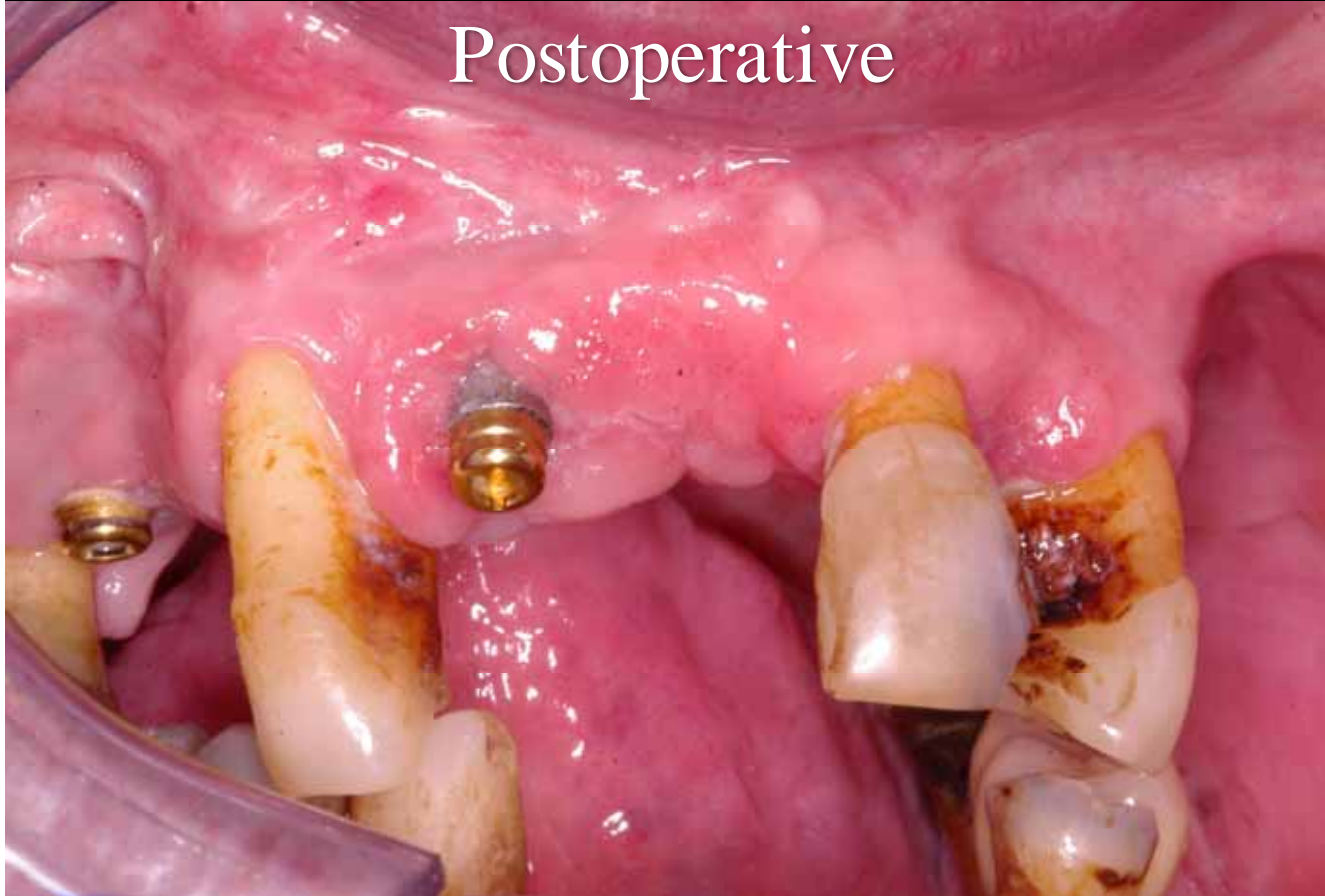The Case healed Well



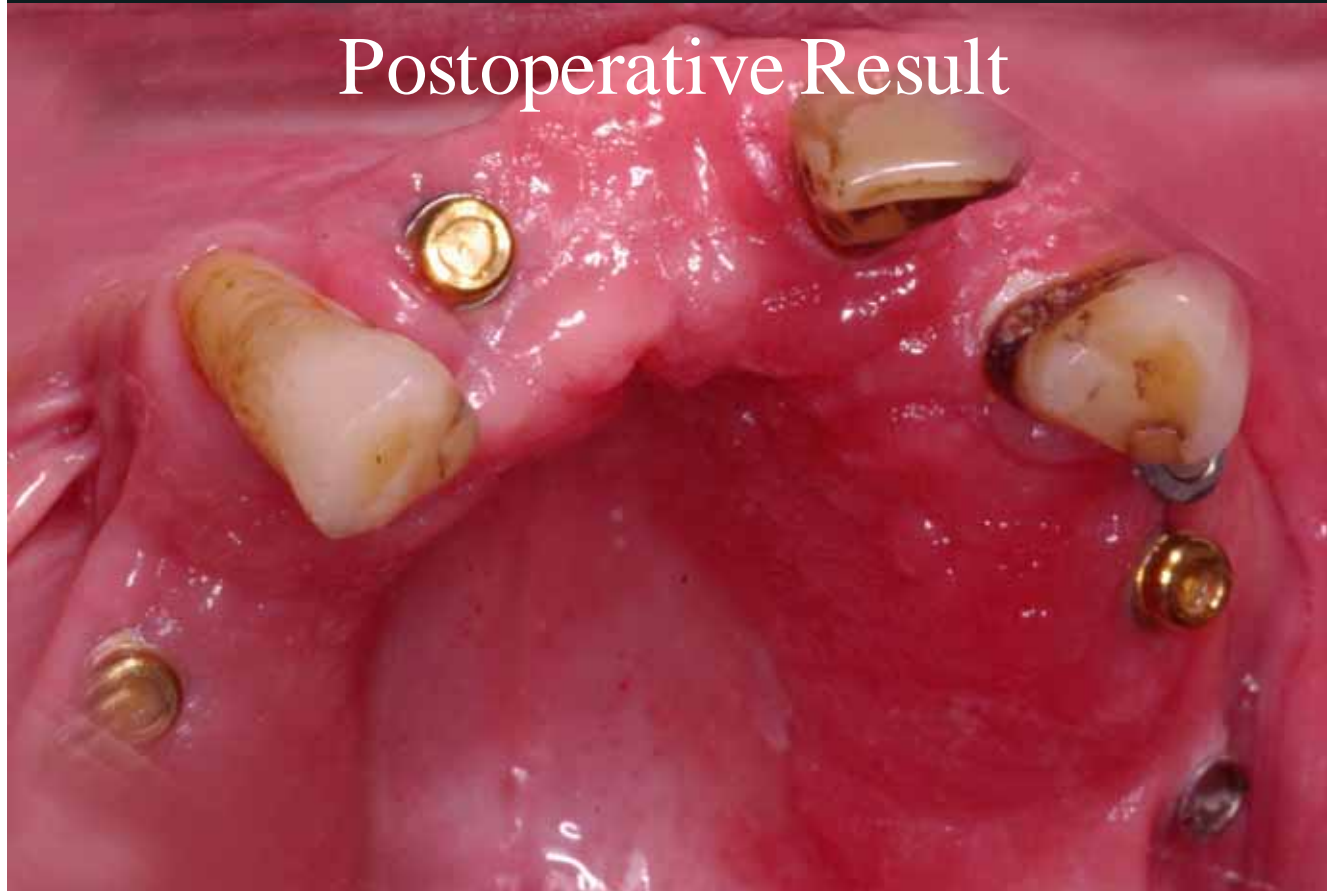Preoperative



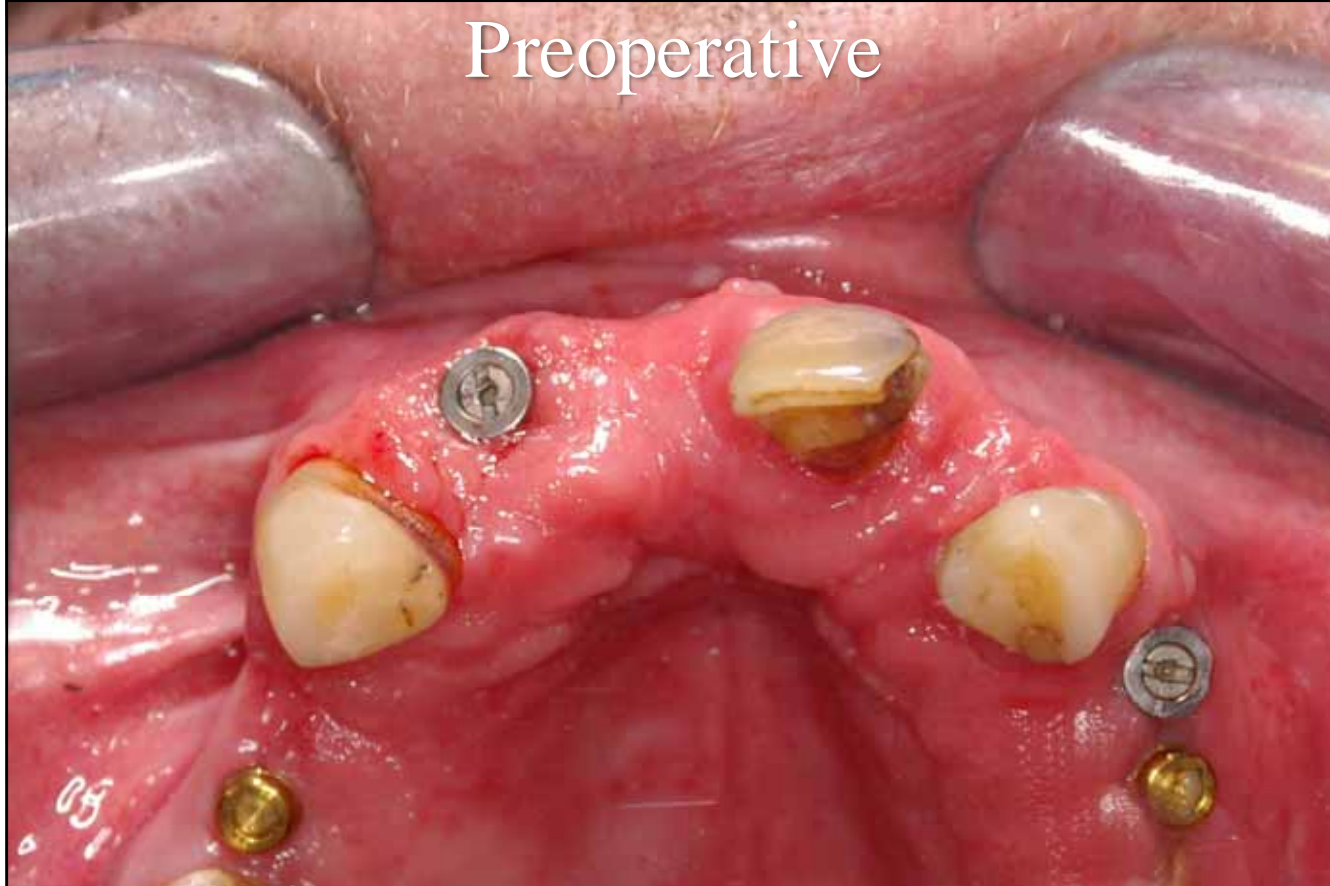Postoperative



# Postoperative Result



Preoperative



# Postoperative Result



The End