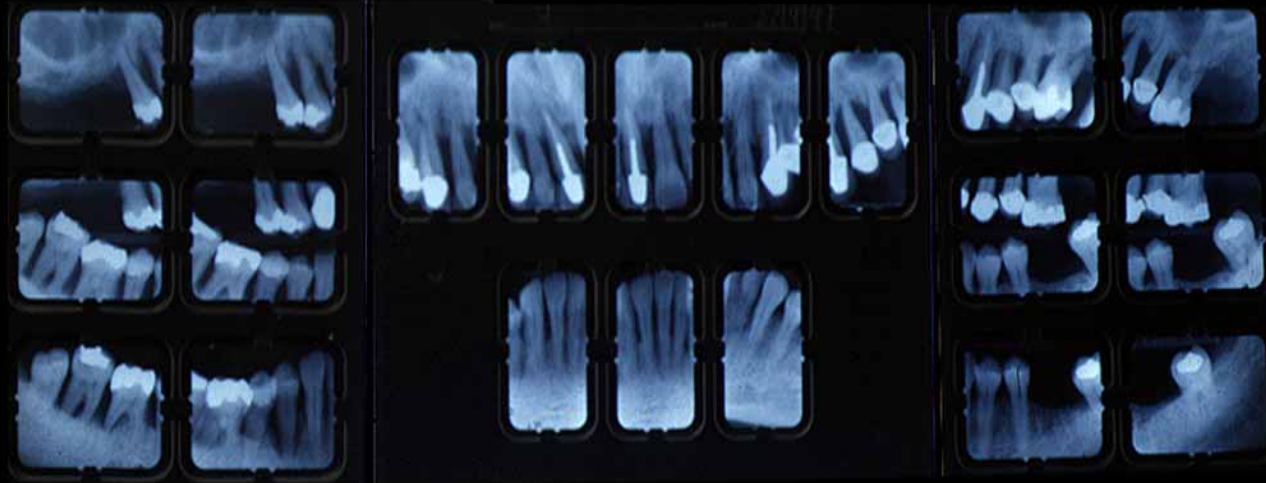


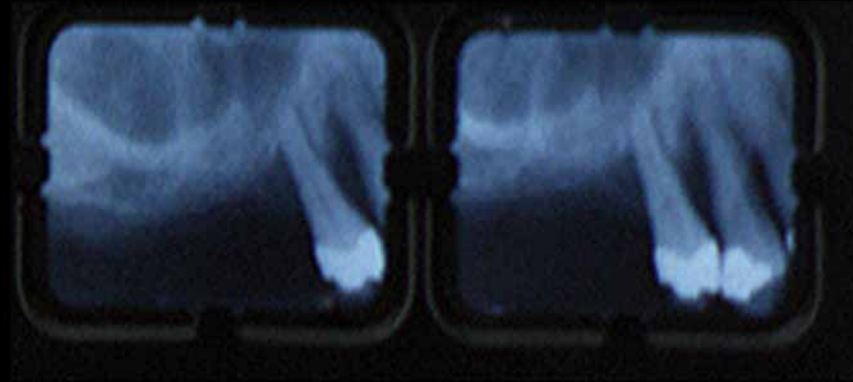
Completely Edentulous Cases

A Case of Severe Bone Loss



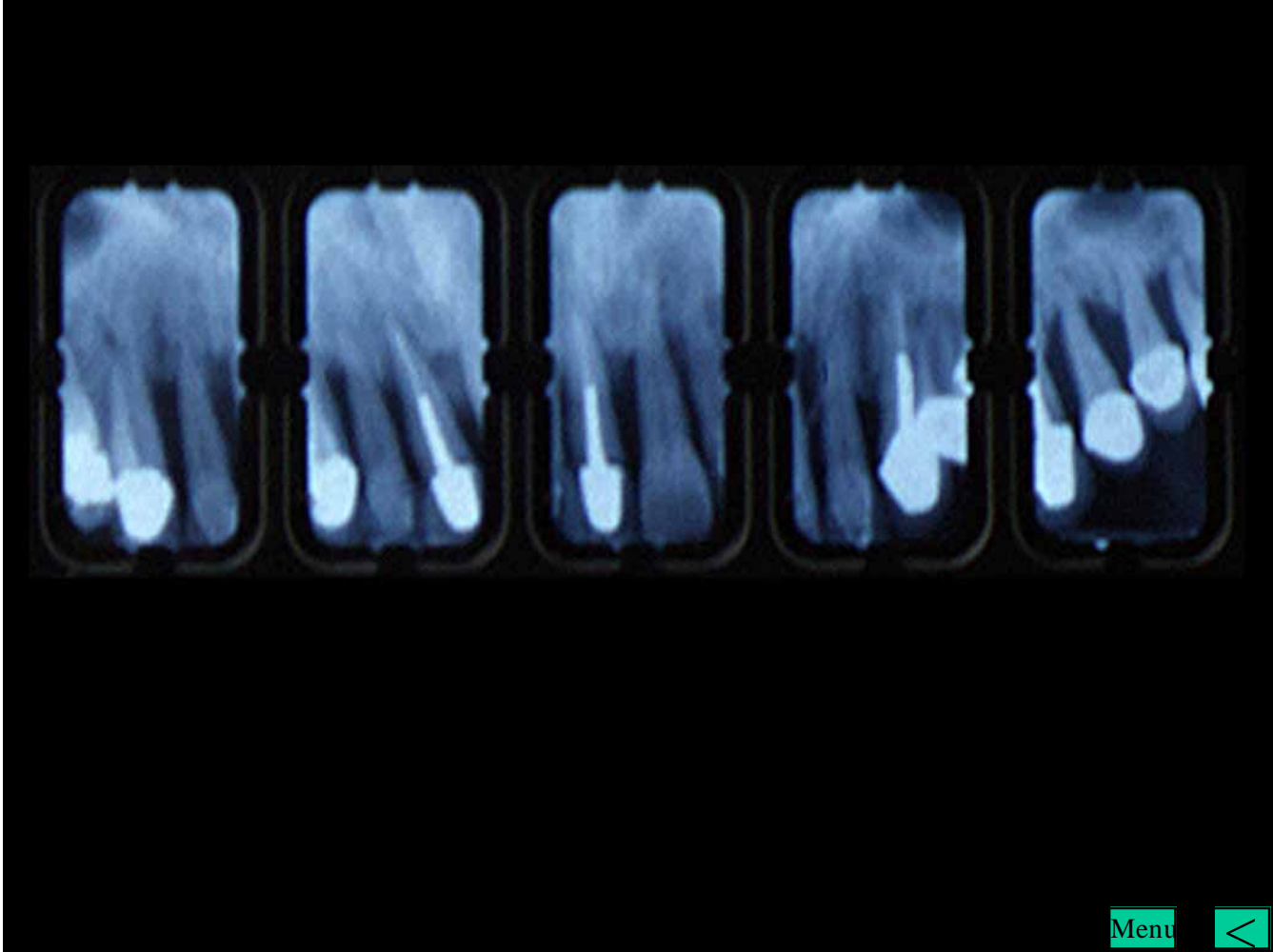
Menu

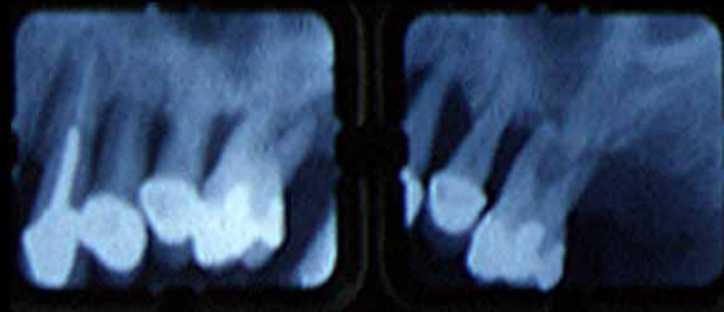




Menu

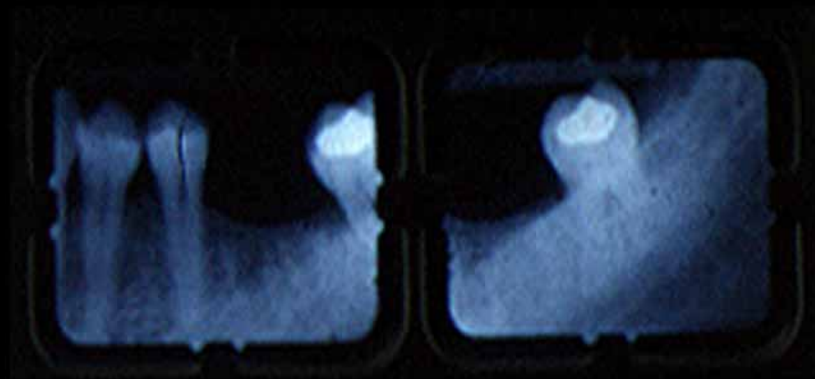






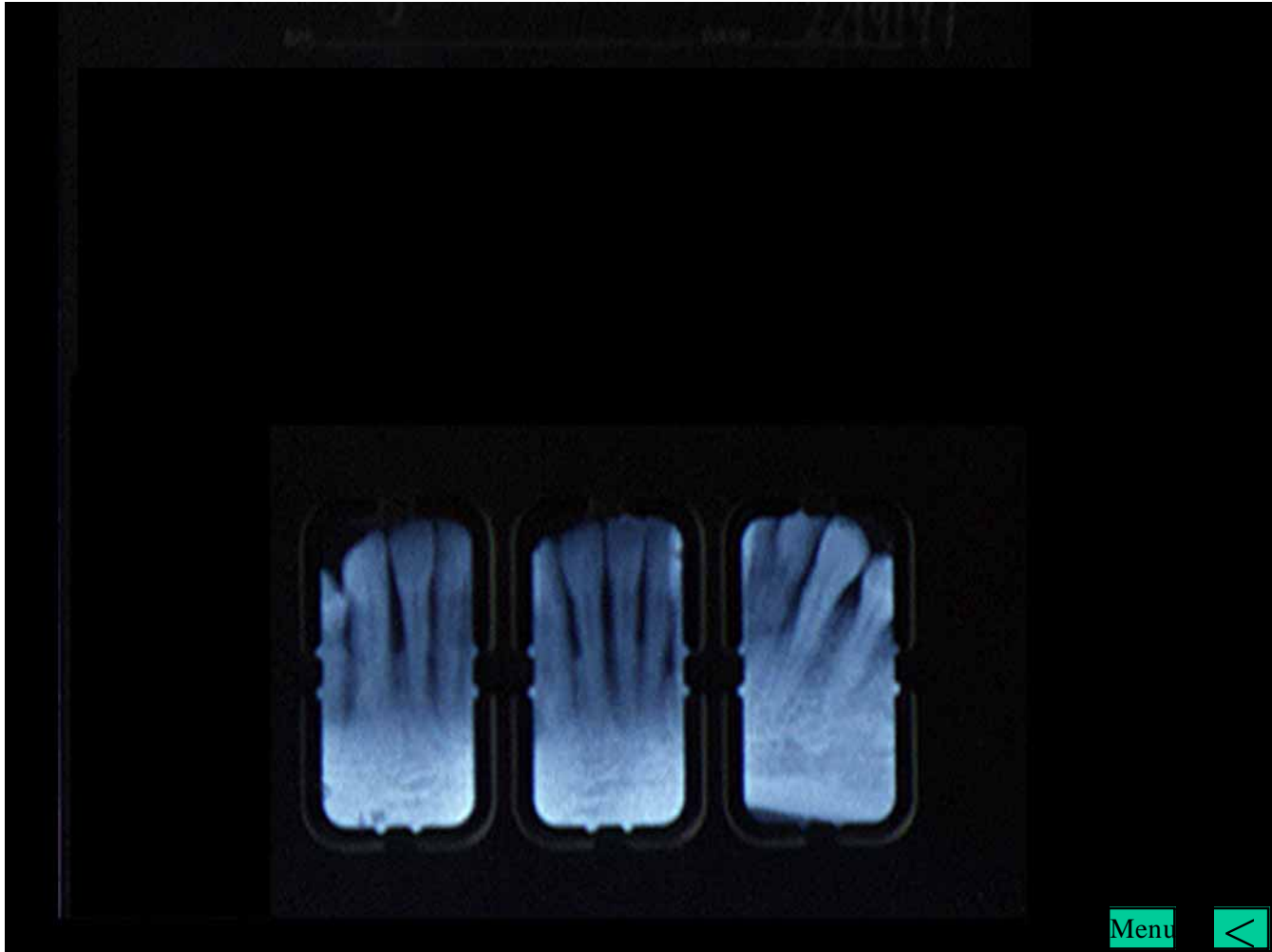
Menu

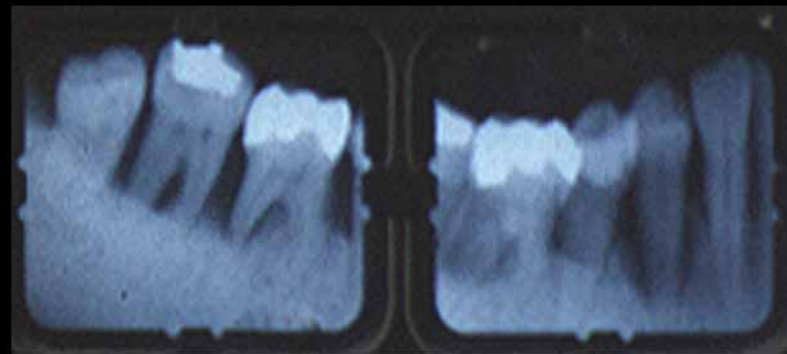




Menu

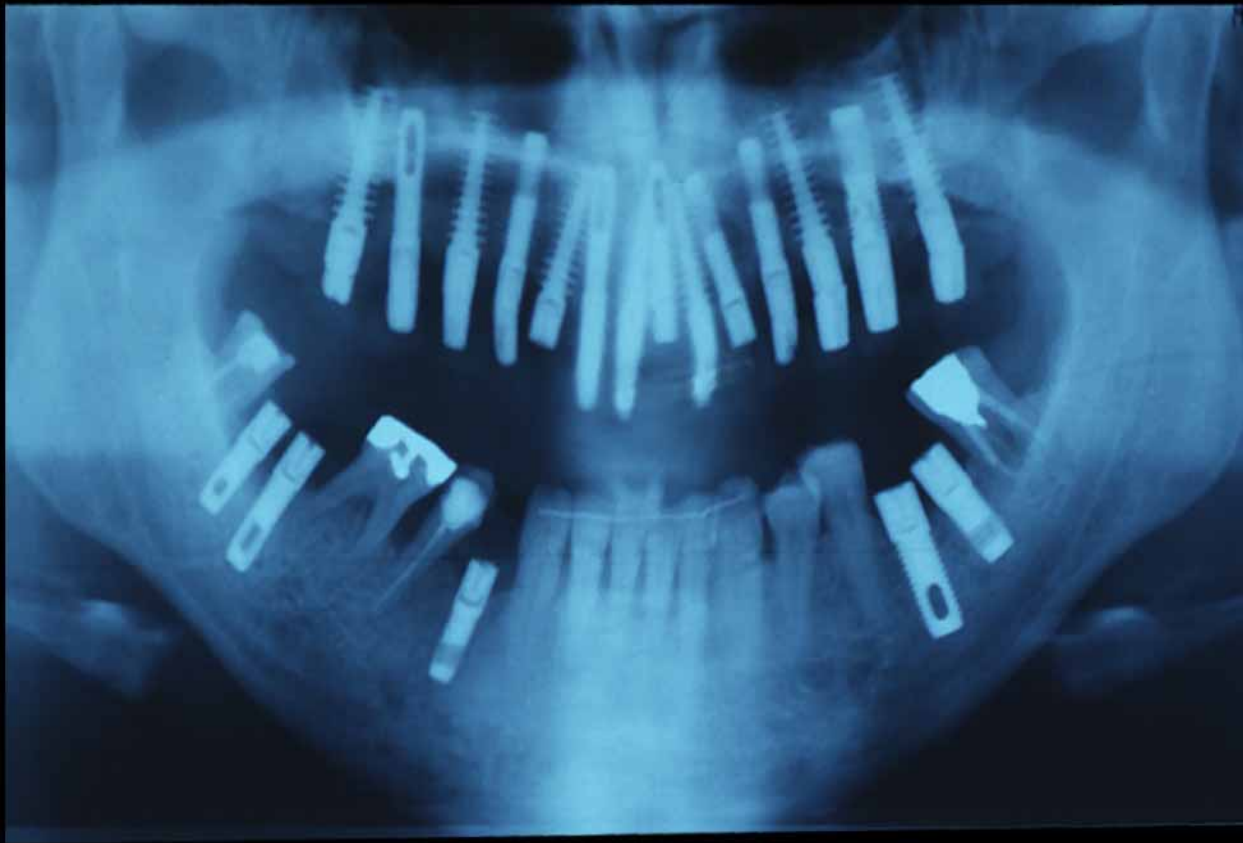






Menu

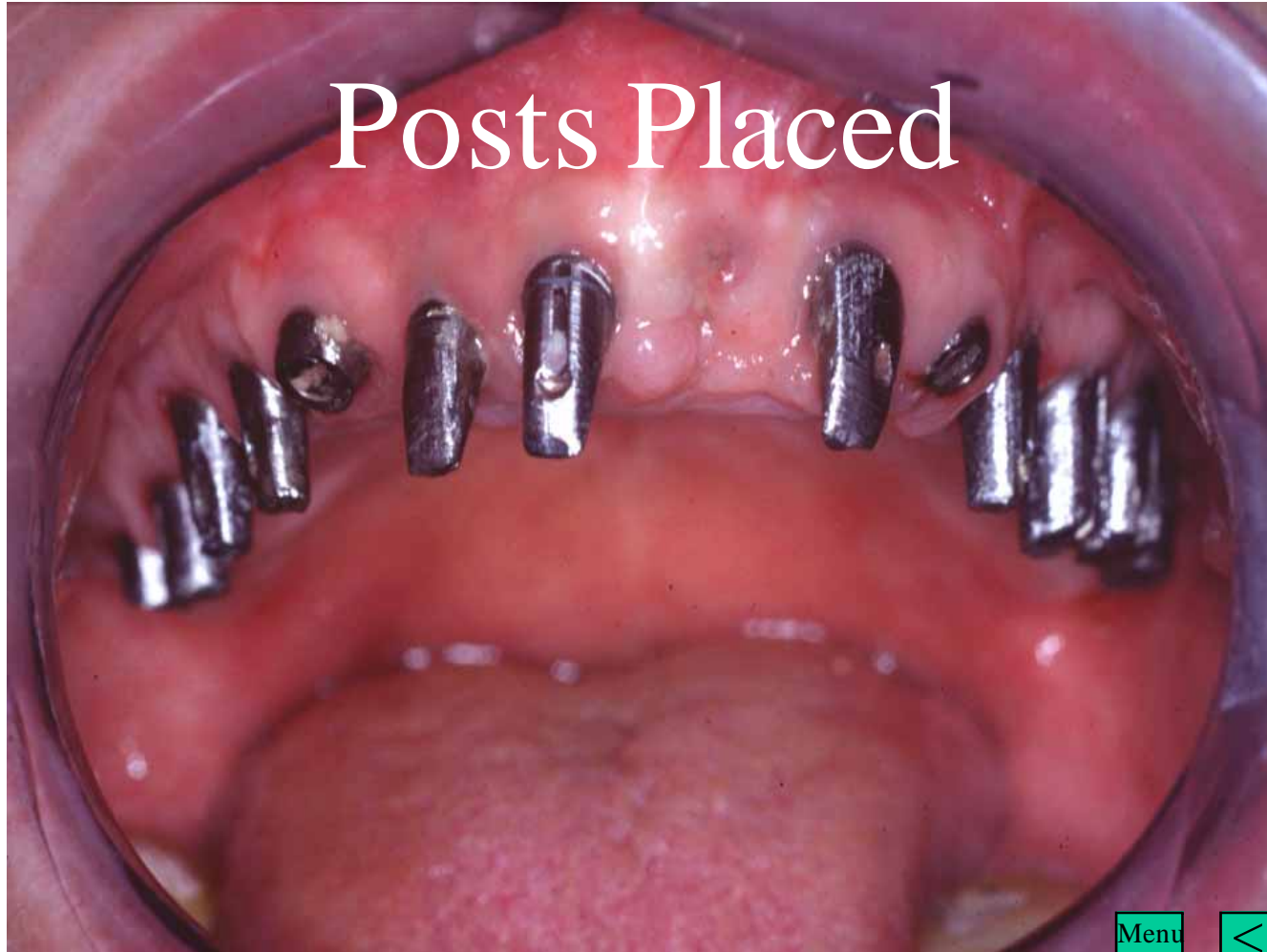



Menu



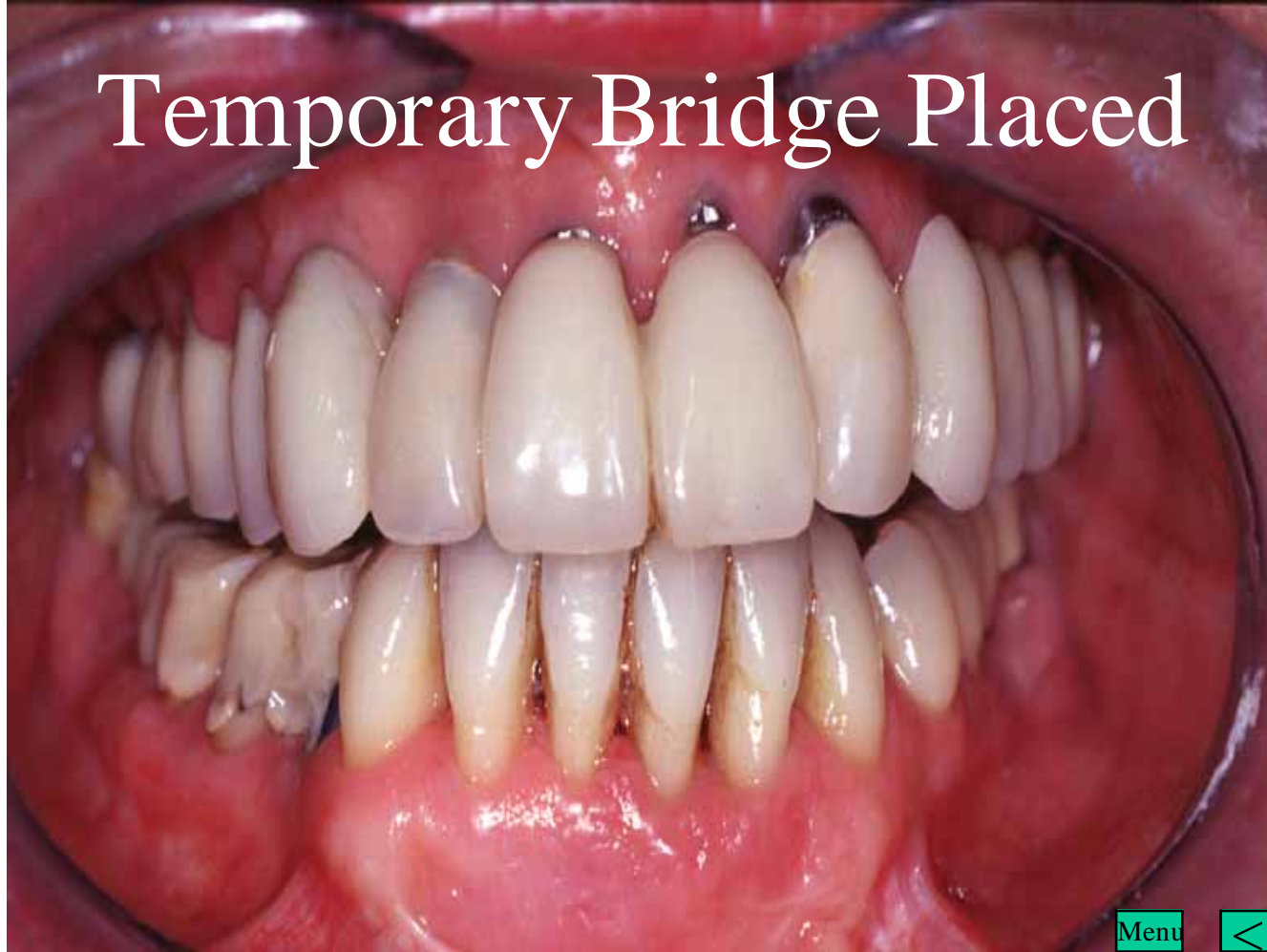Posts Placed



Menu

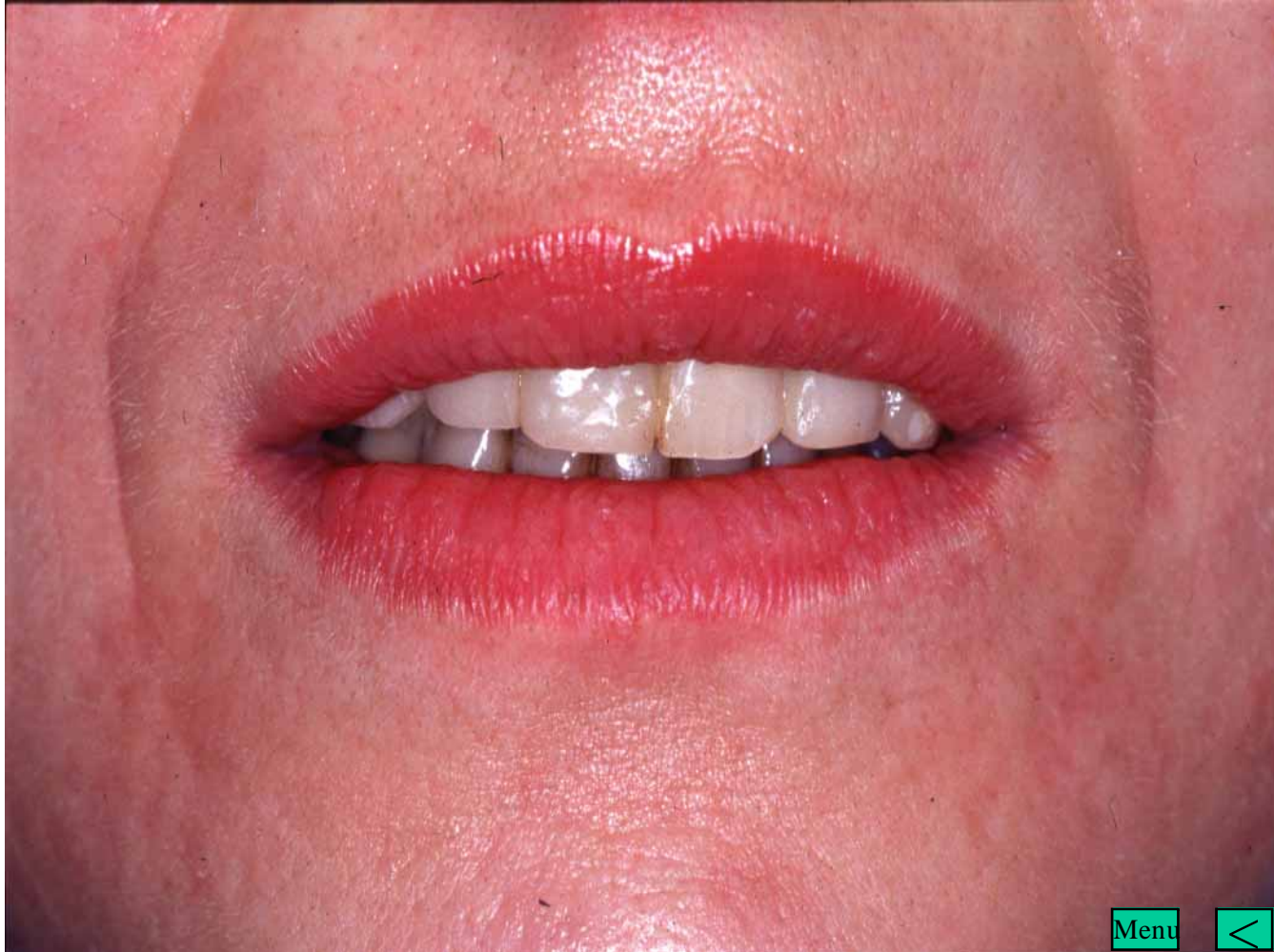

Temporary Bridge Placed



Menu

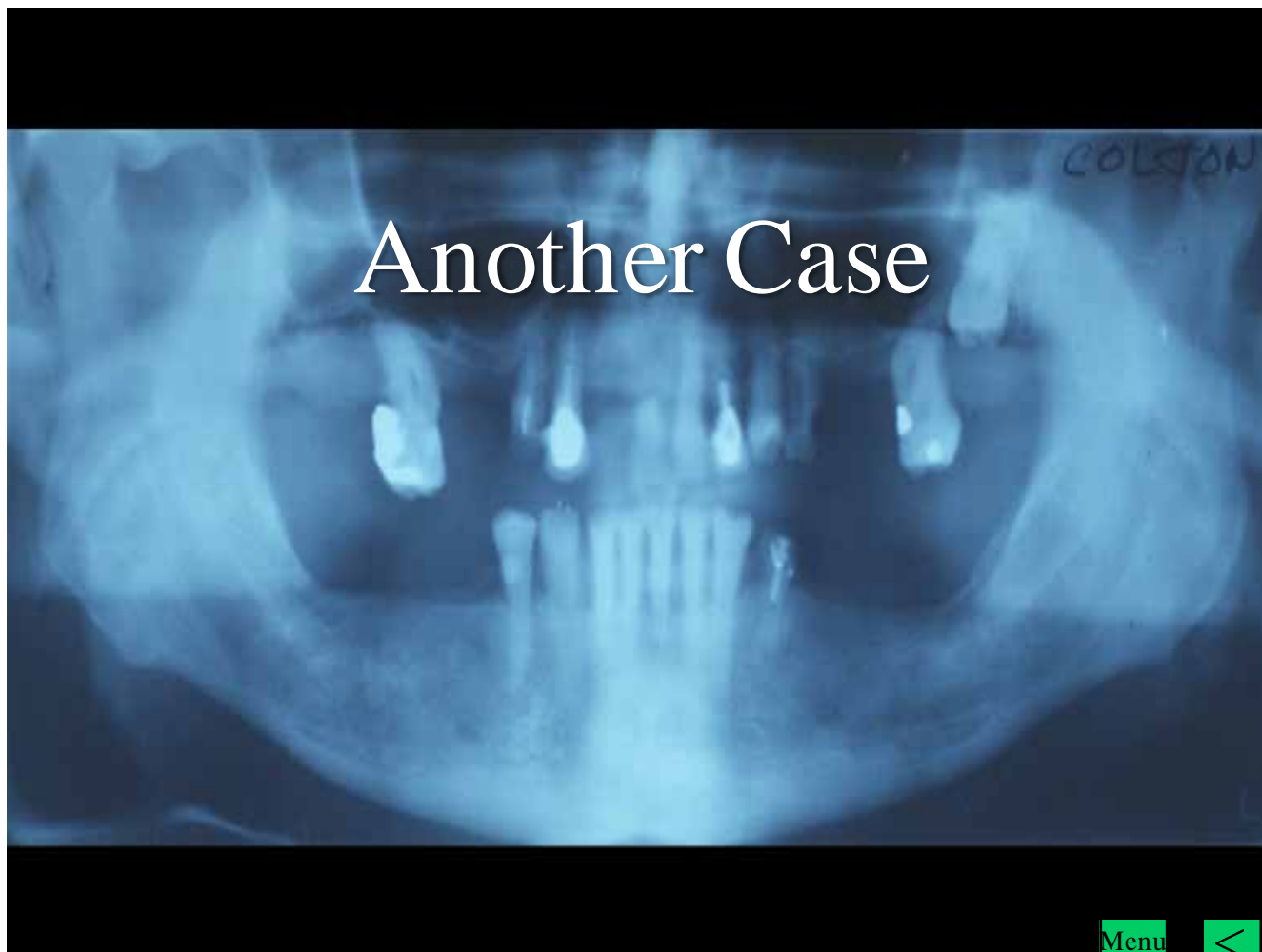

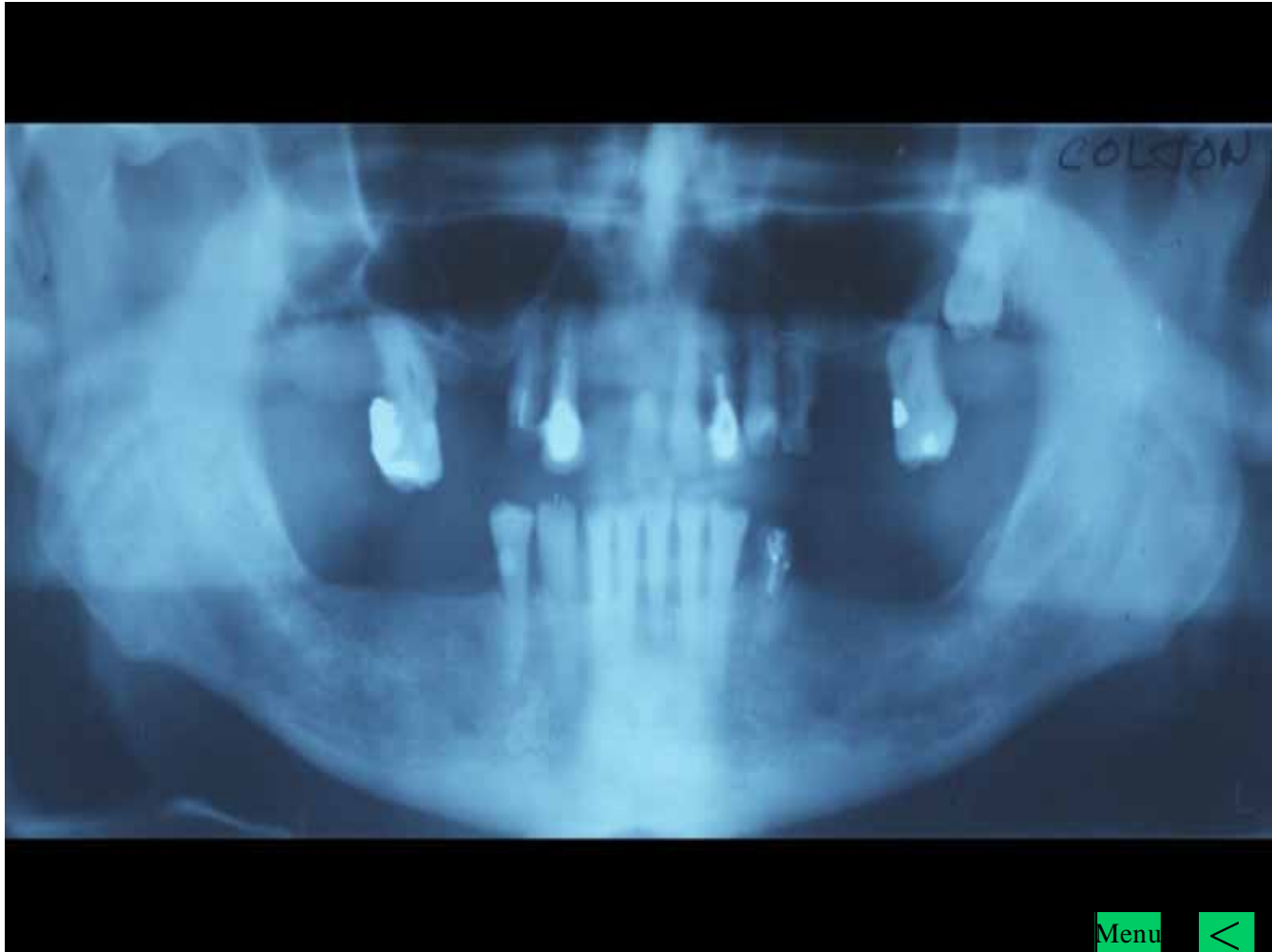


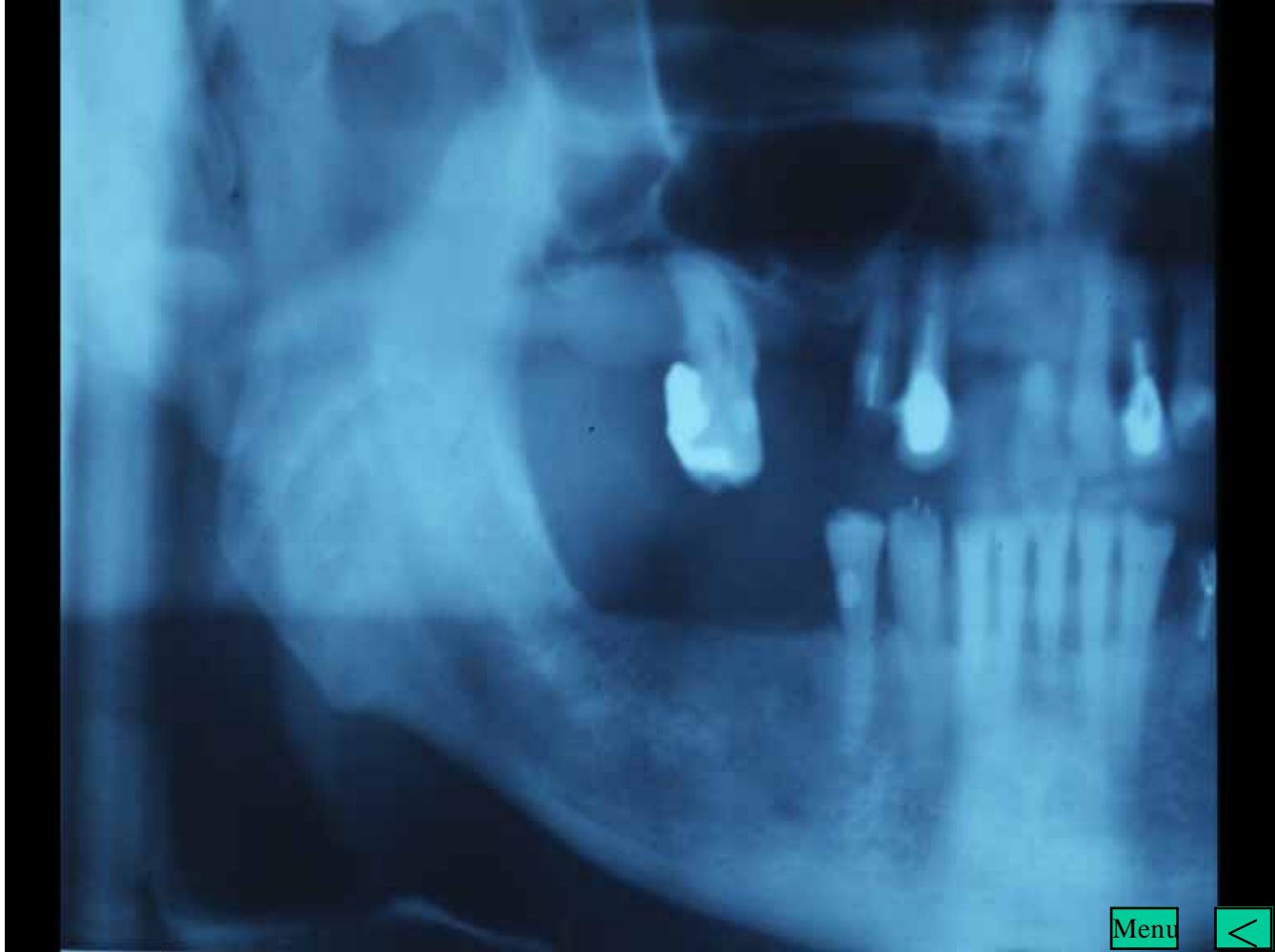Menu

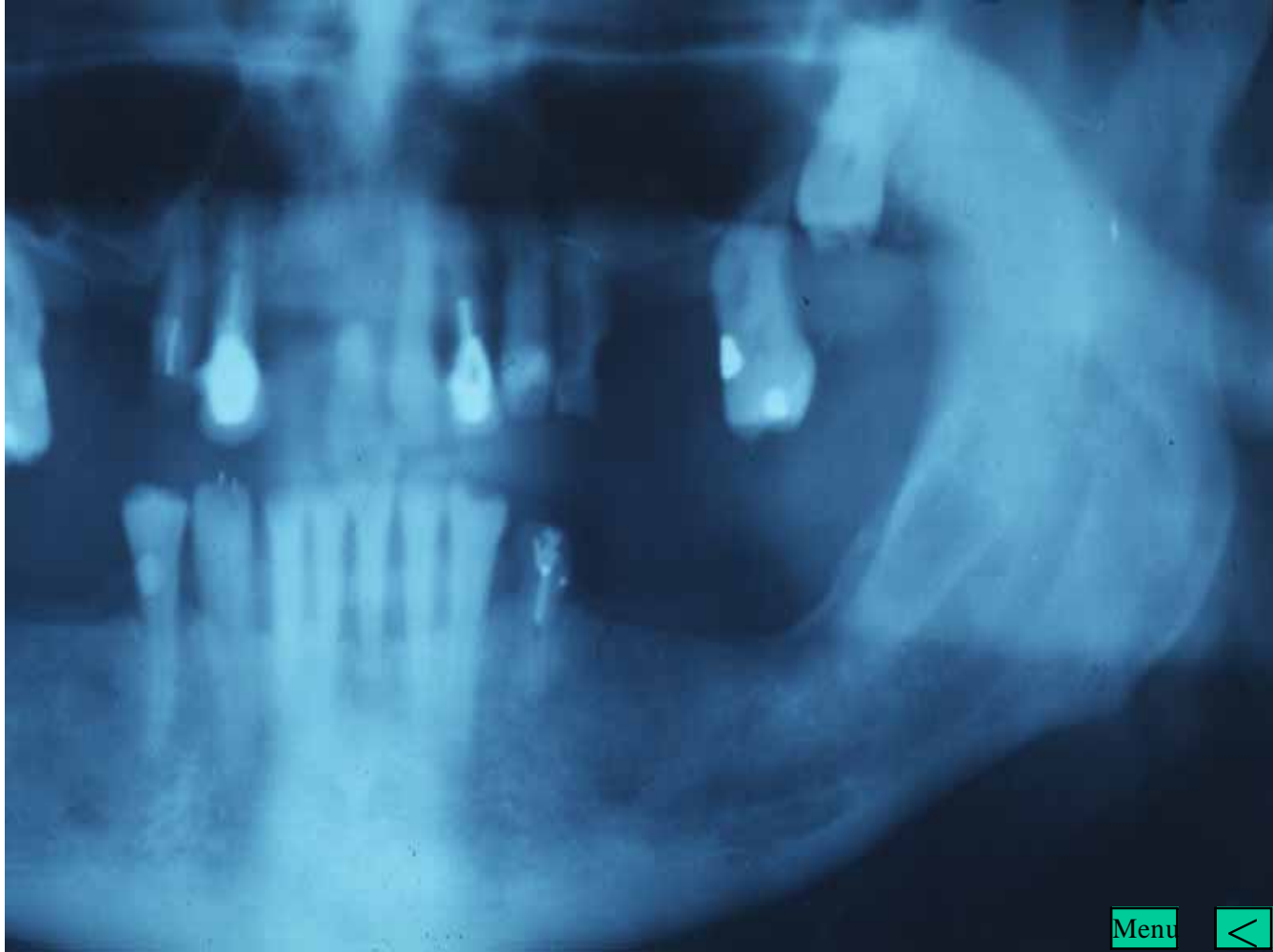


Another Case

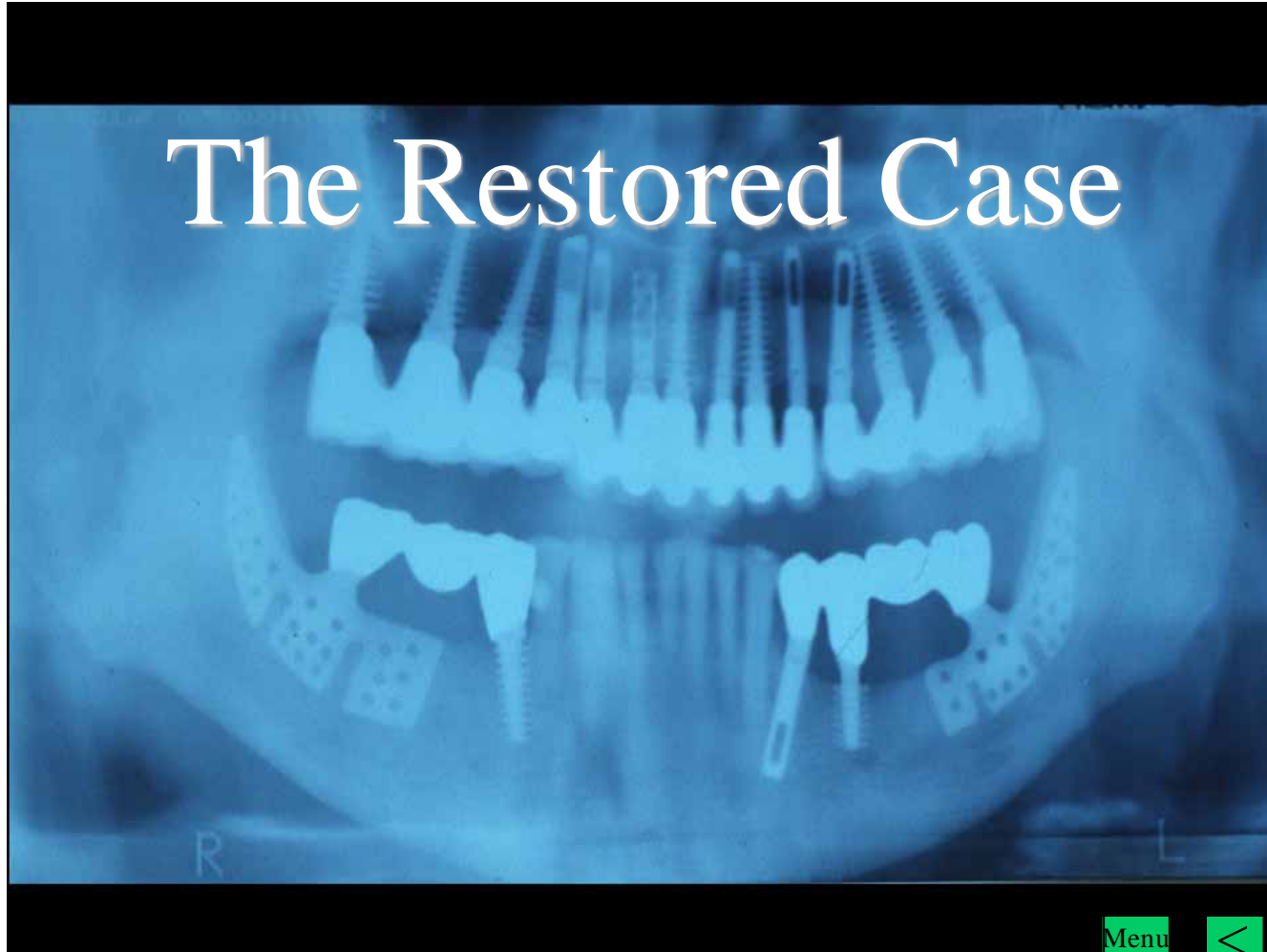

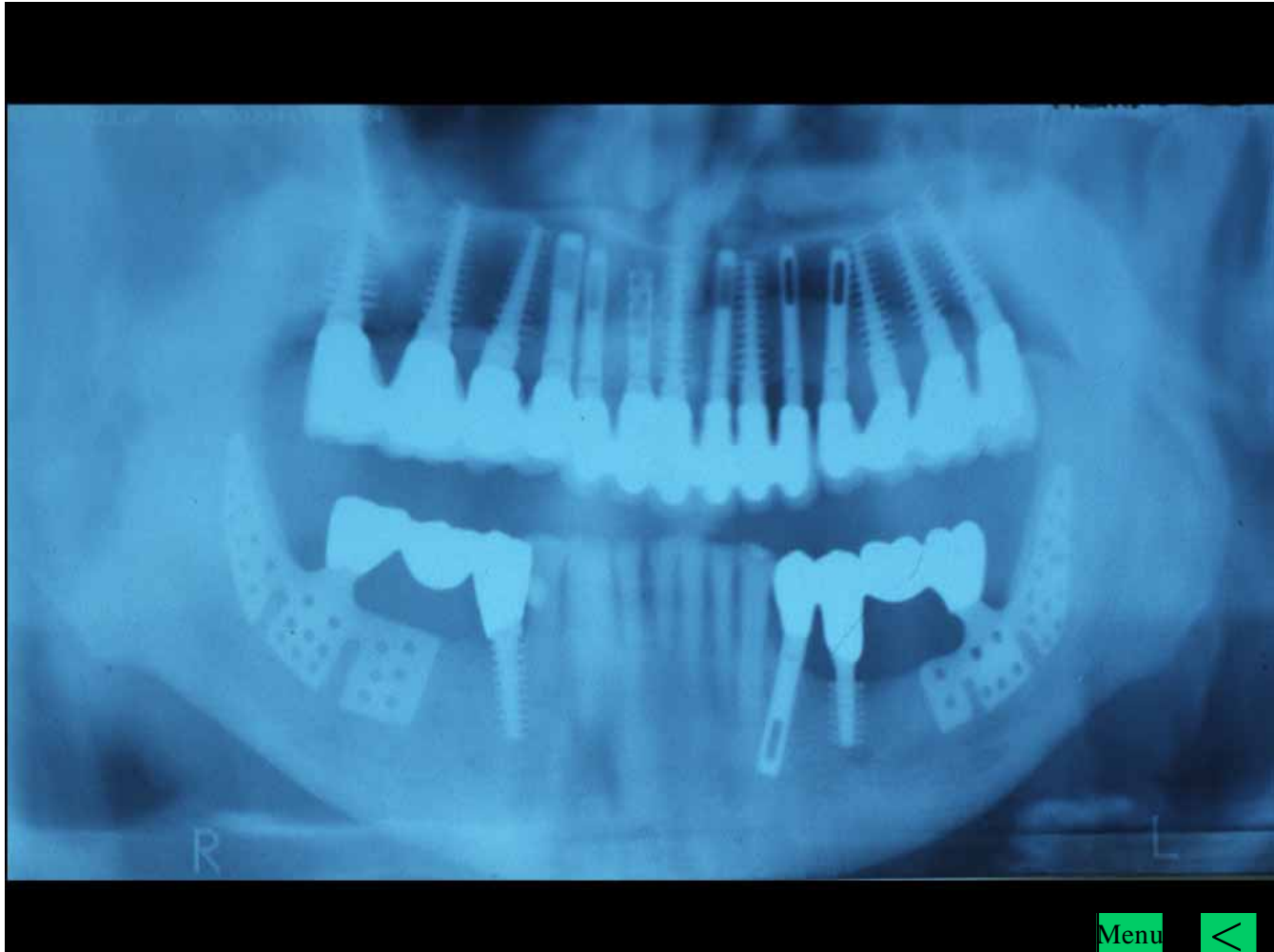




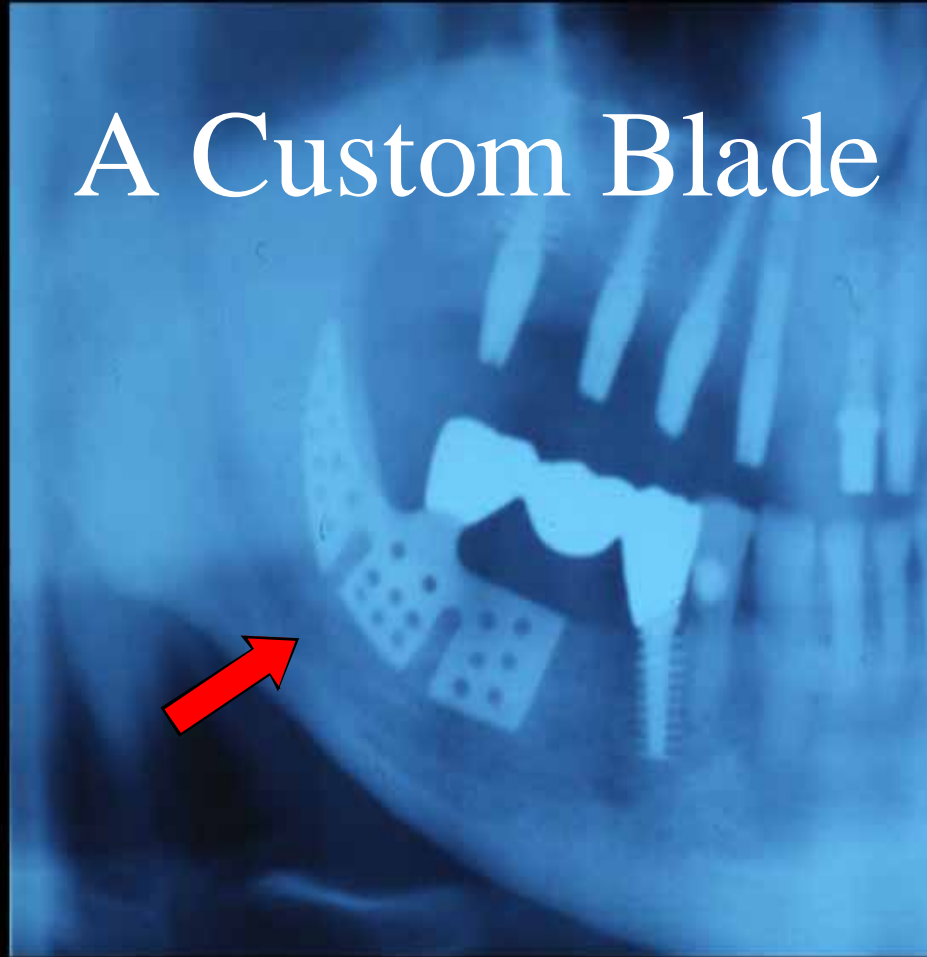


The Restored Case





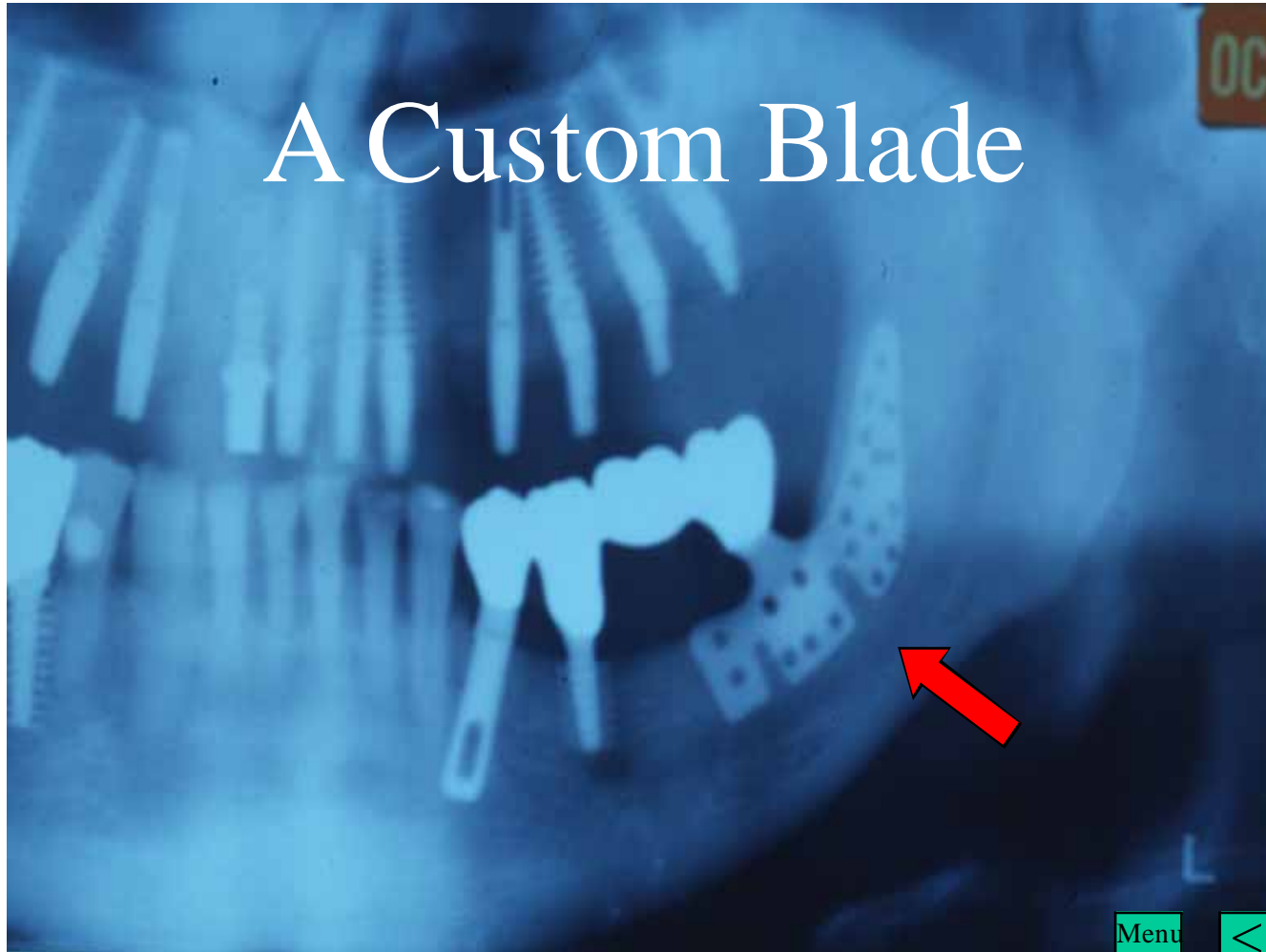
A Custom Blade



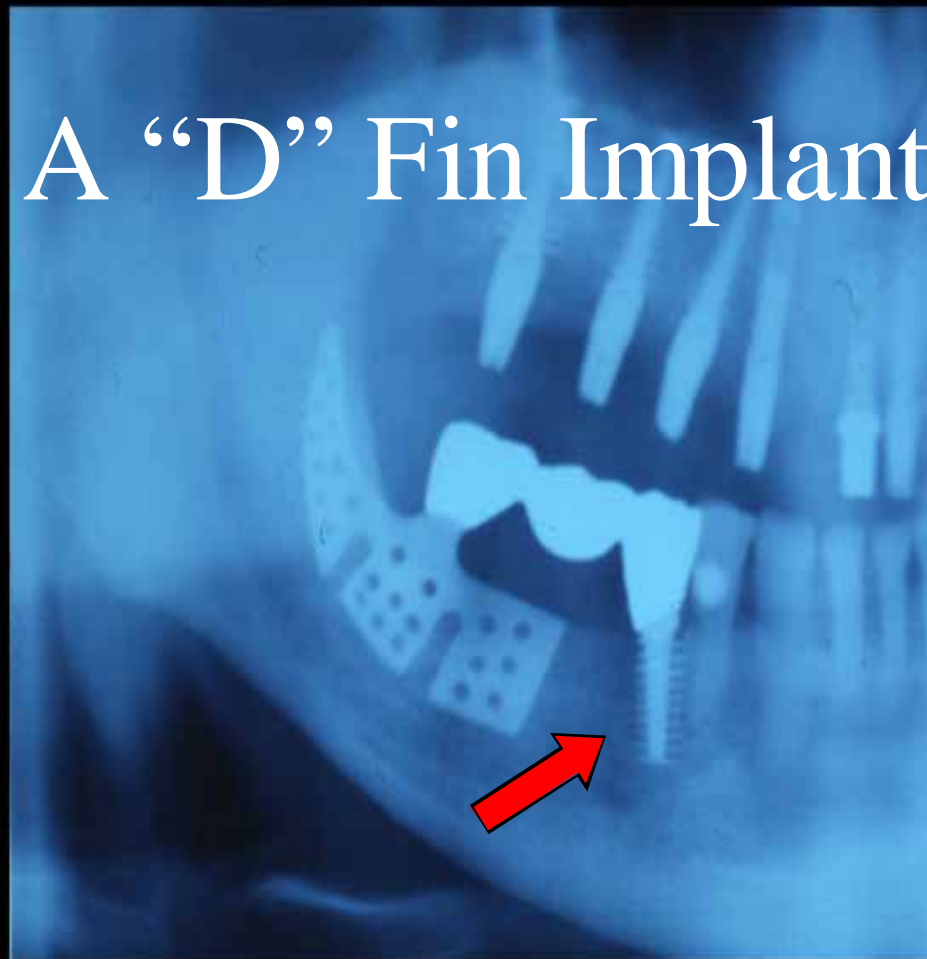
Menu



A Custom Blade



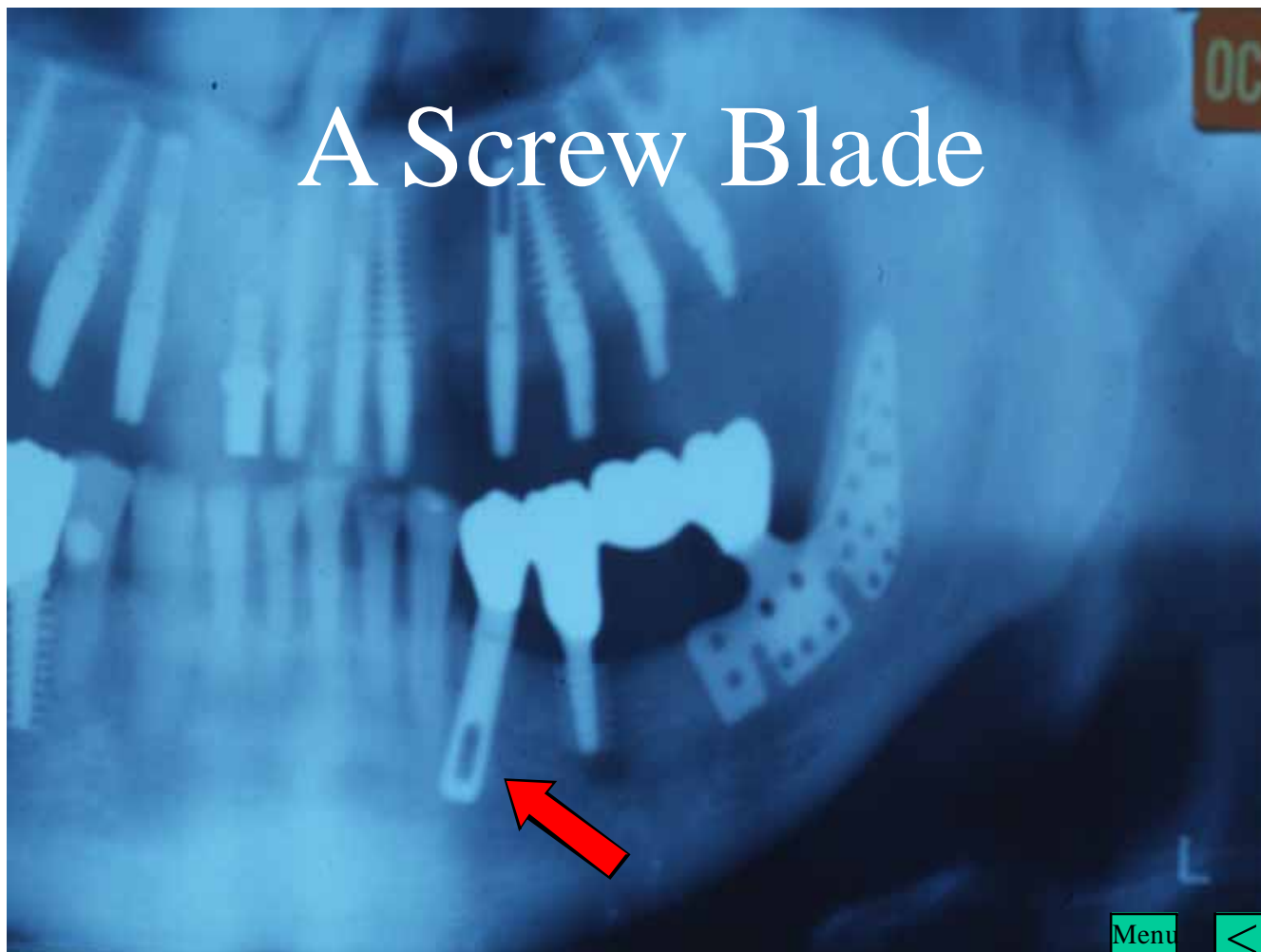
A “D” Fin Implant



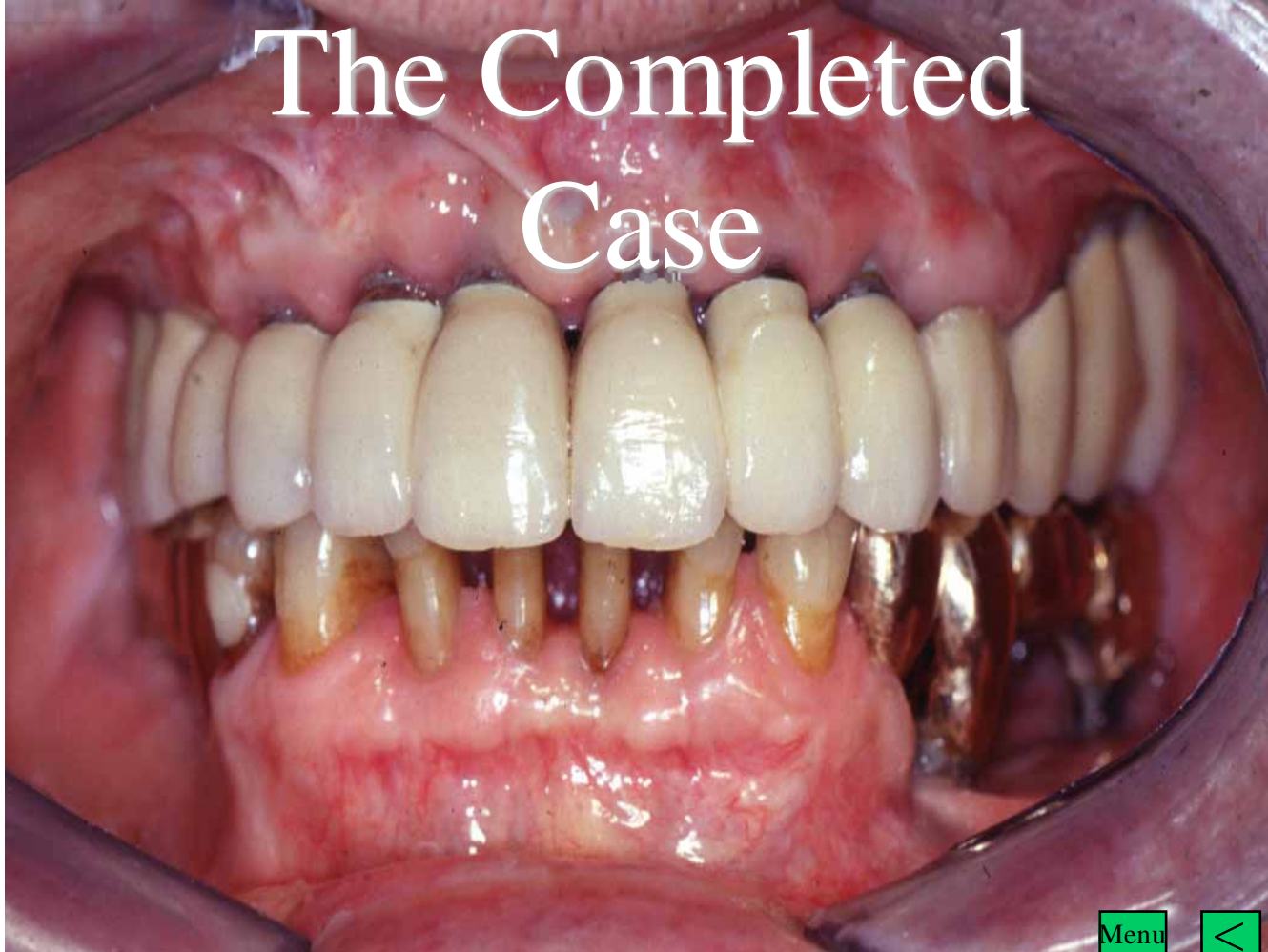
Menu



A Screw Blade

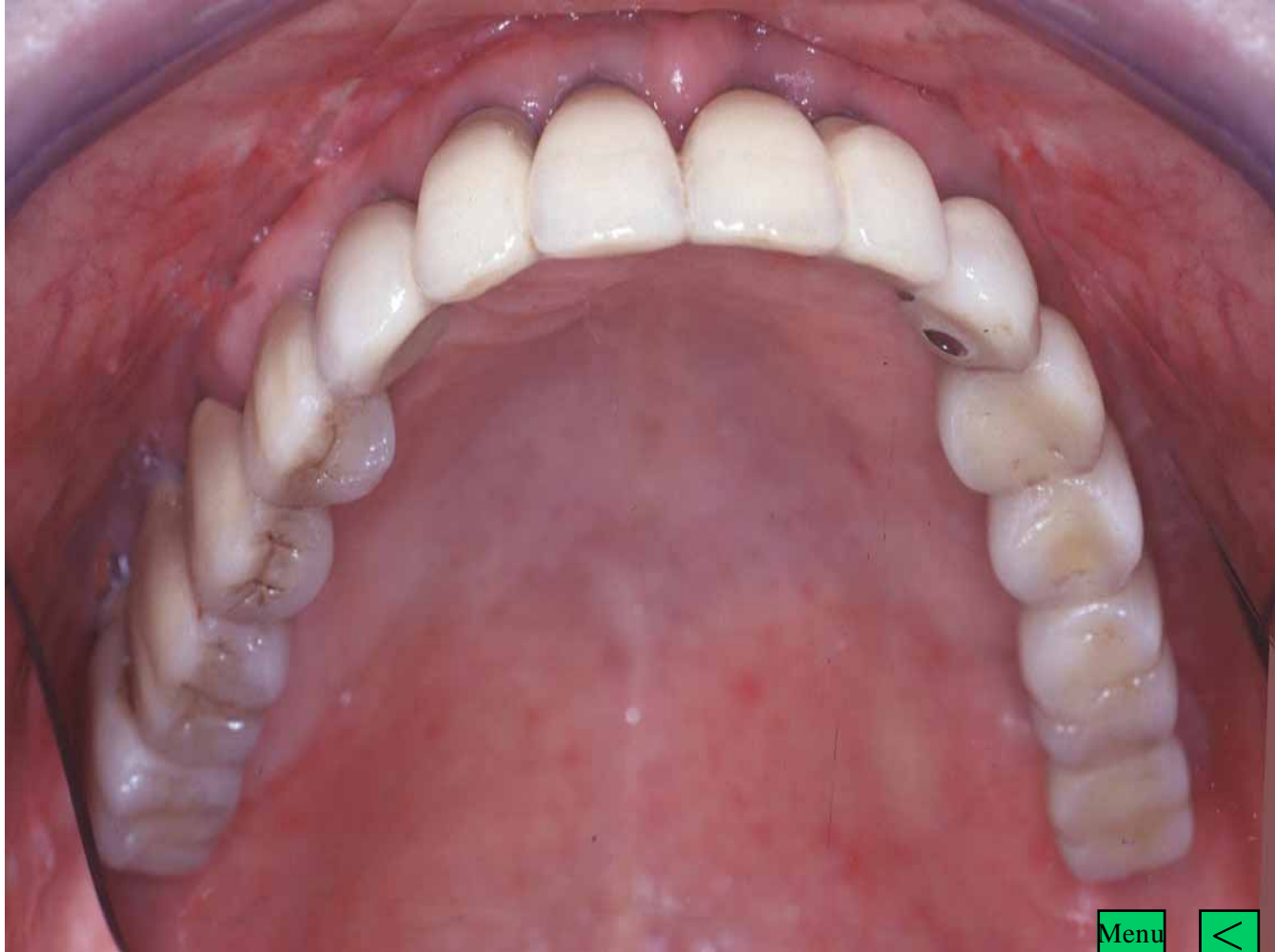


The Completed Case

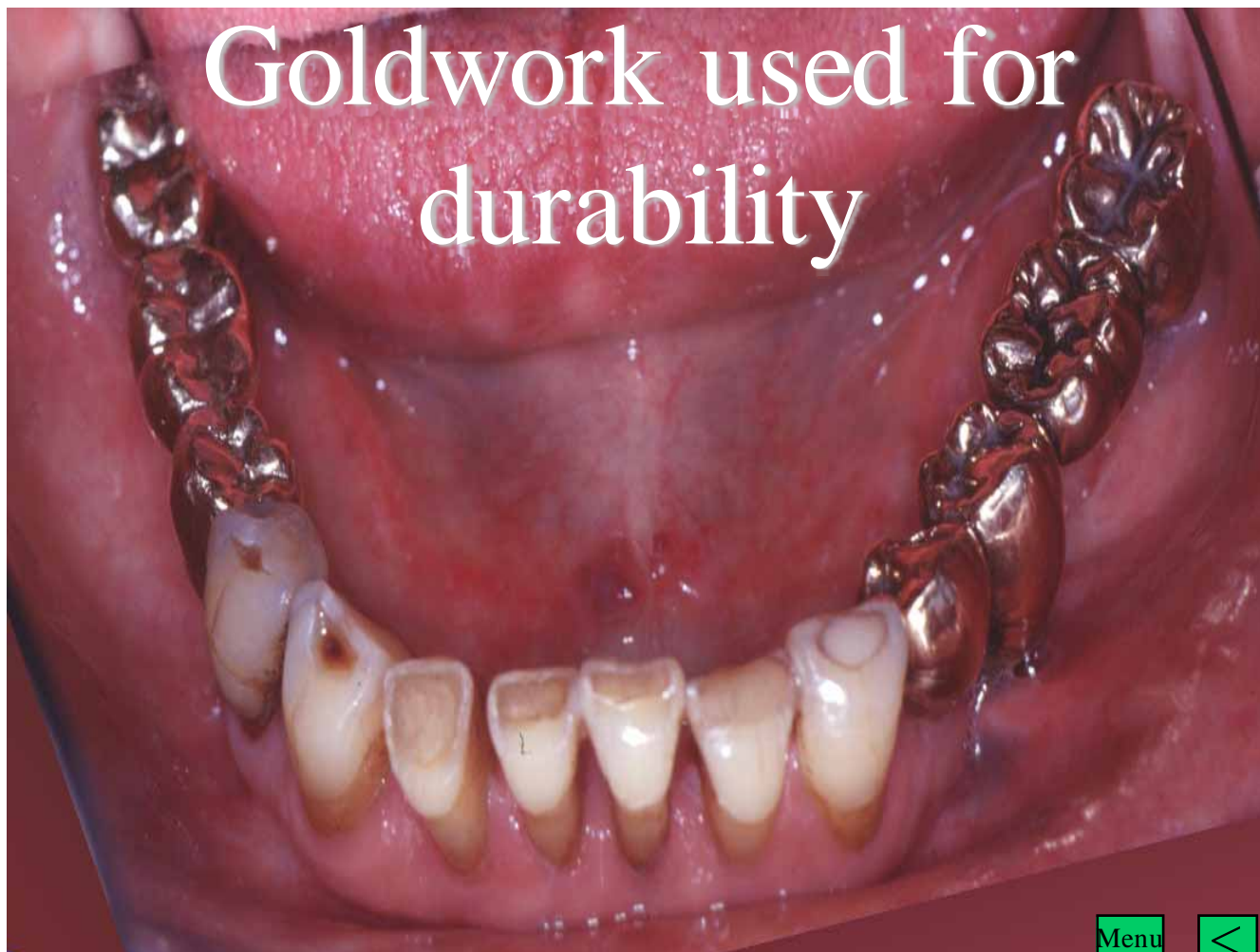


Menu



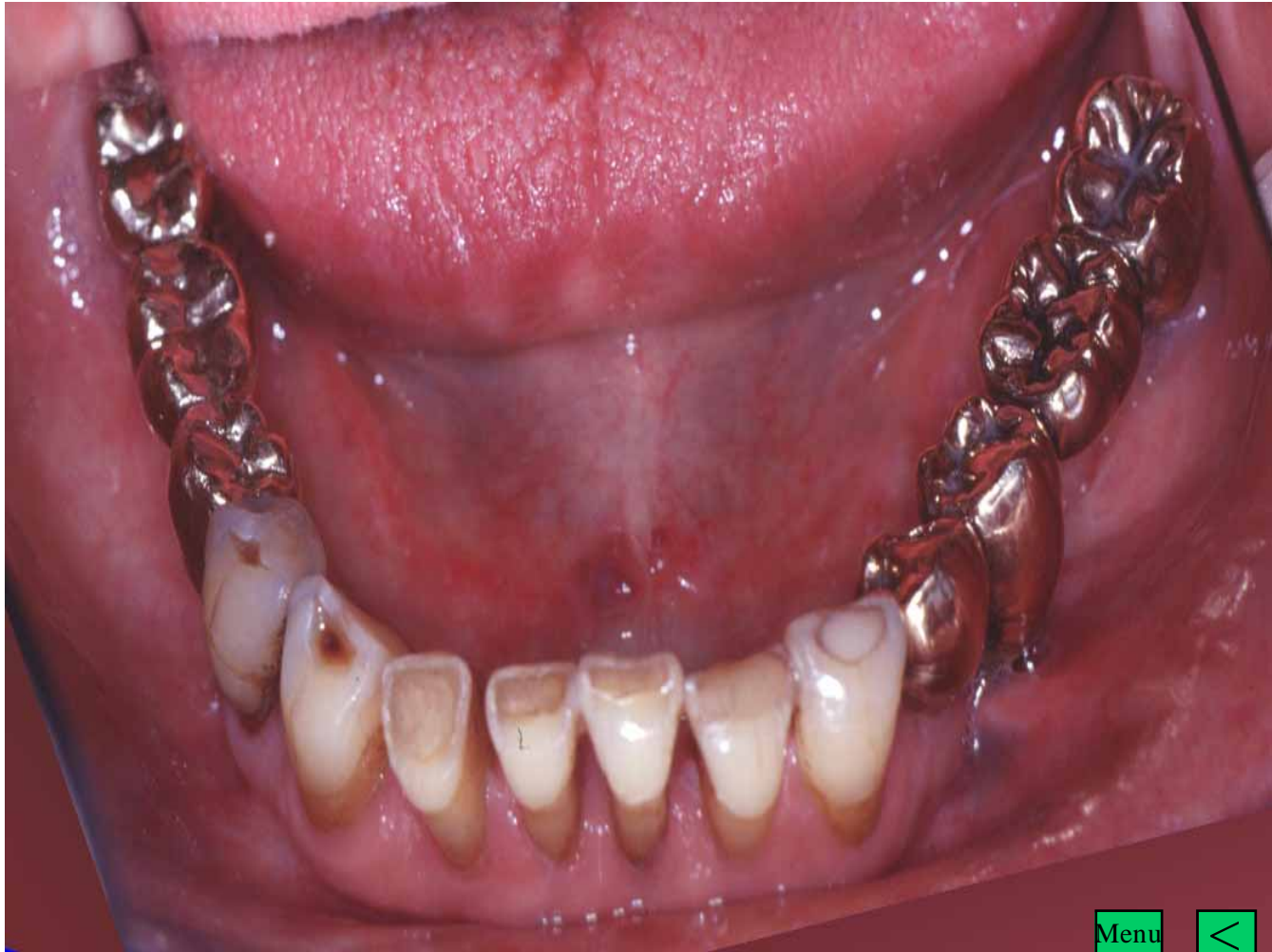

Goldwork used for
durability

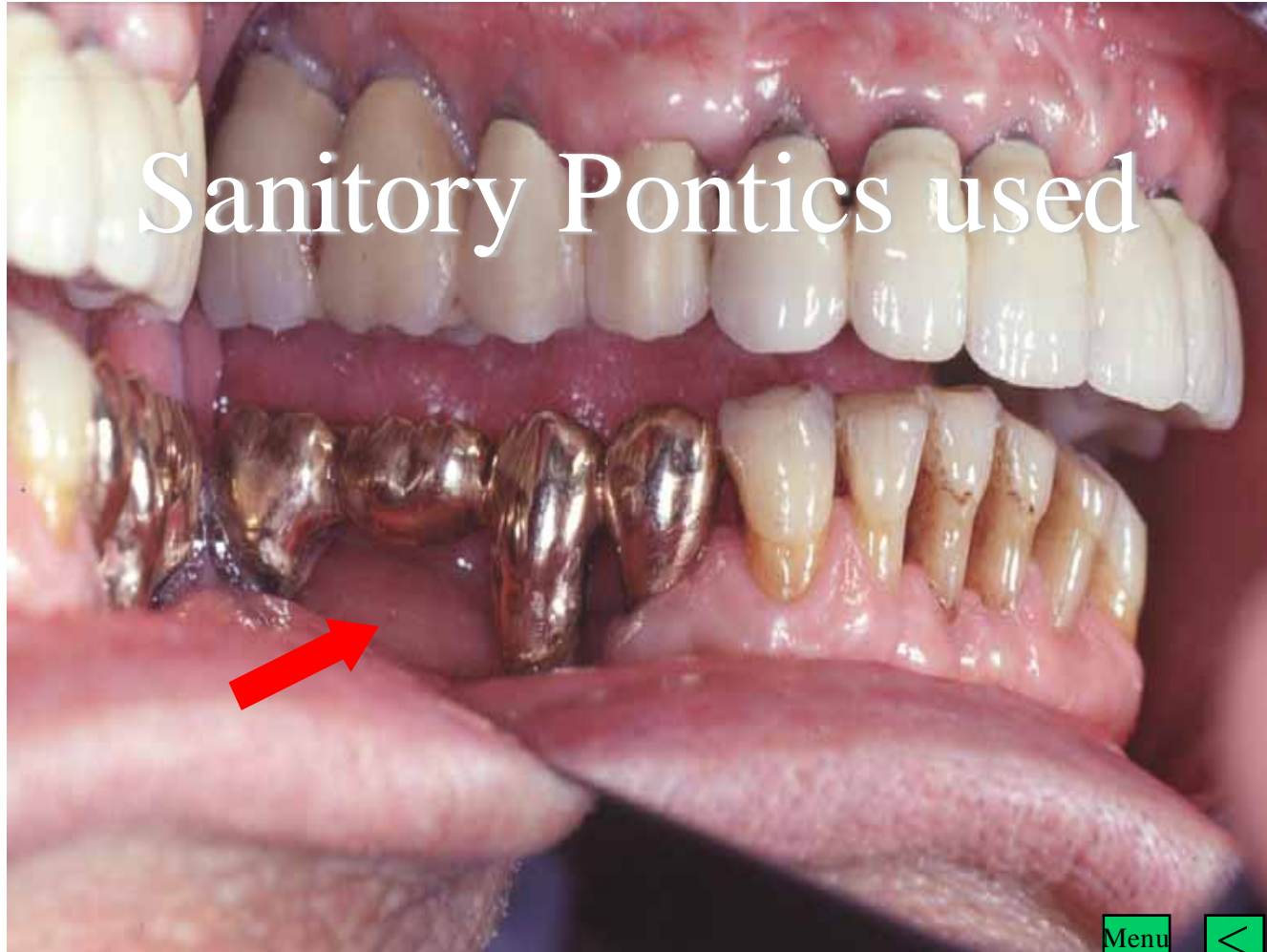


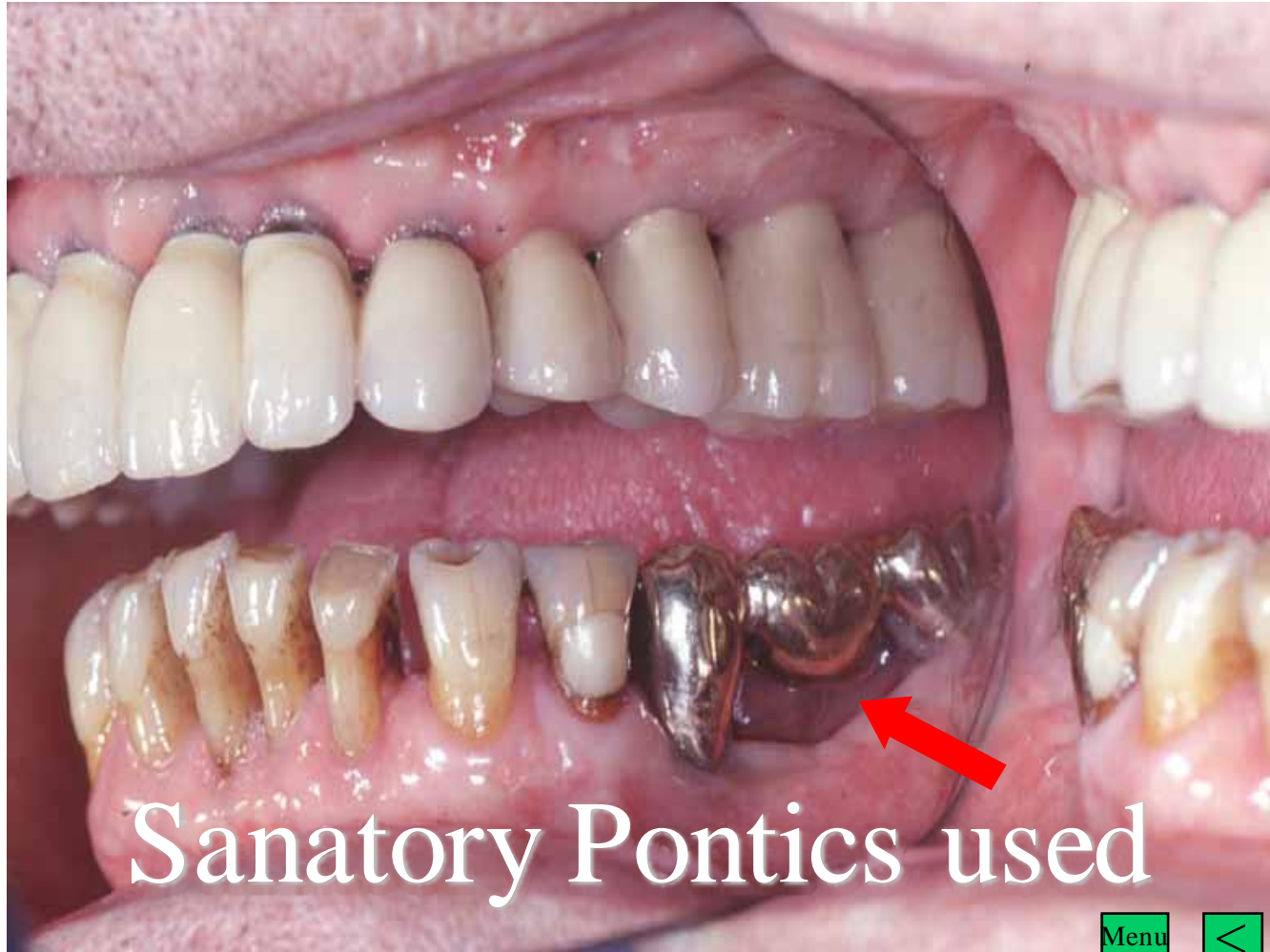
Menu





Sanitary Pontics used

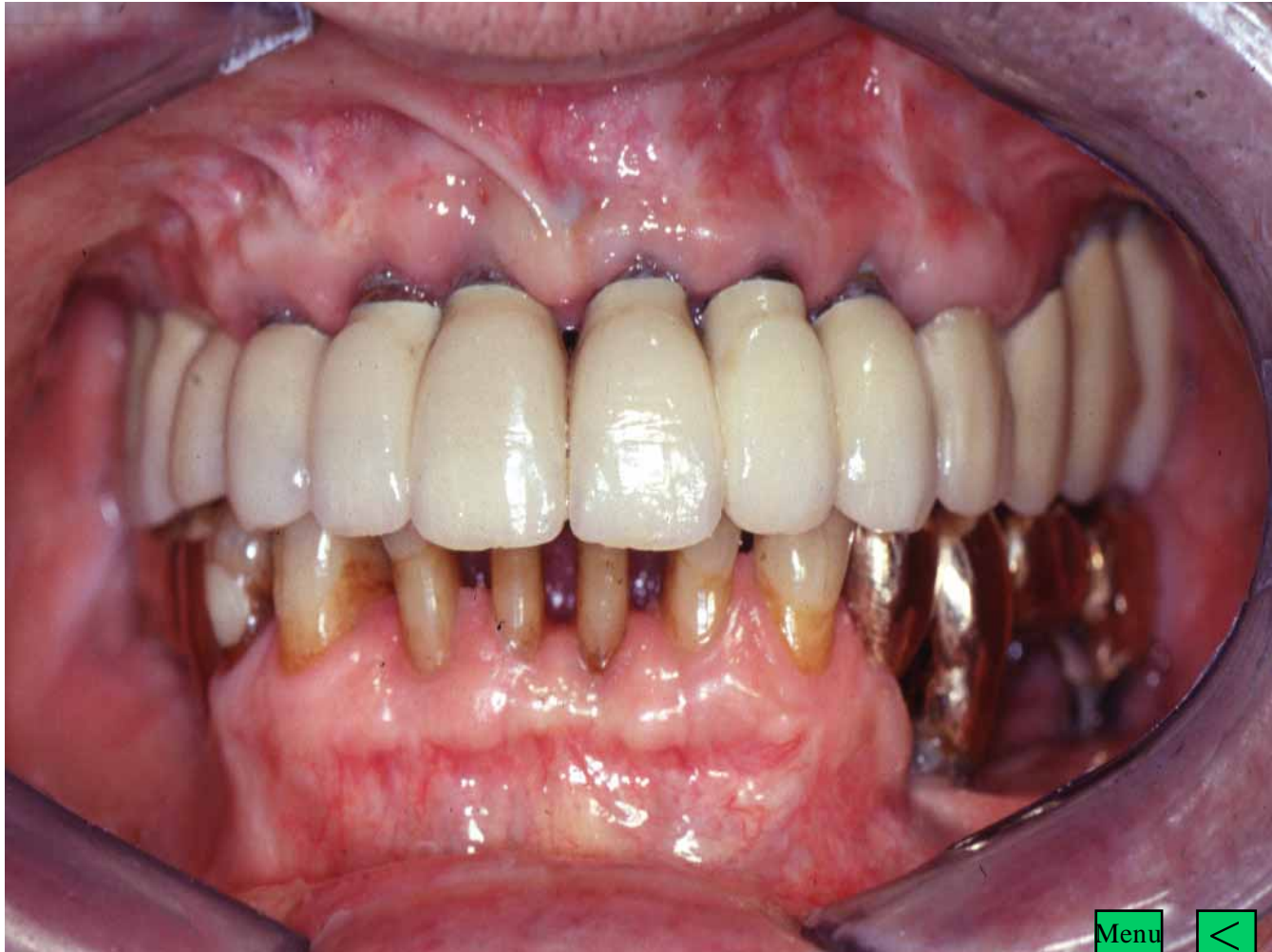



Sanatory Pontics used

Menu

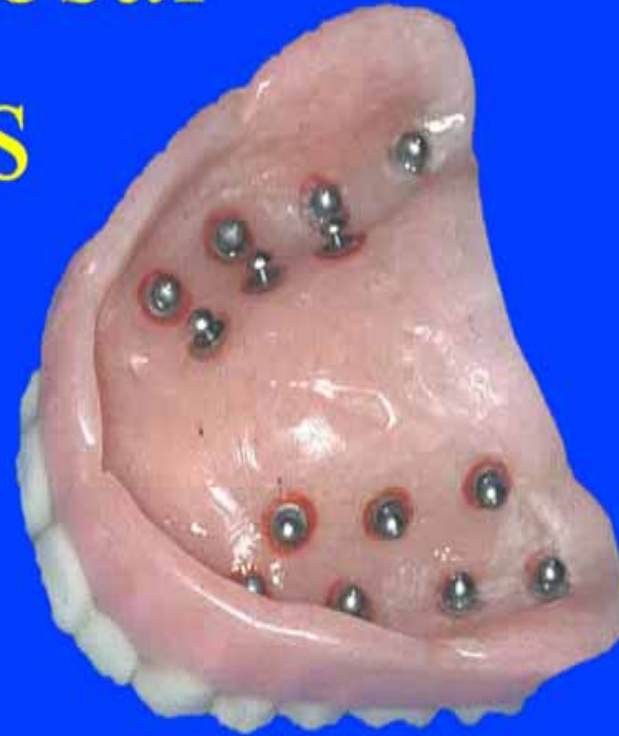



Menu



Intramucosal Inserts



Menu



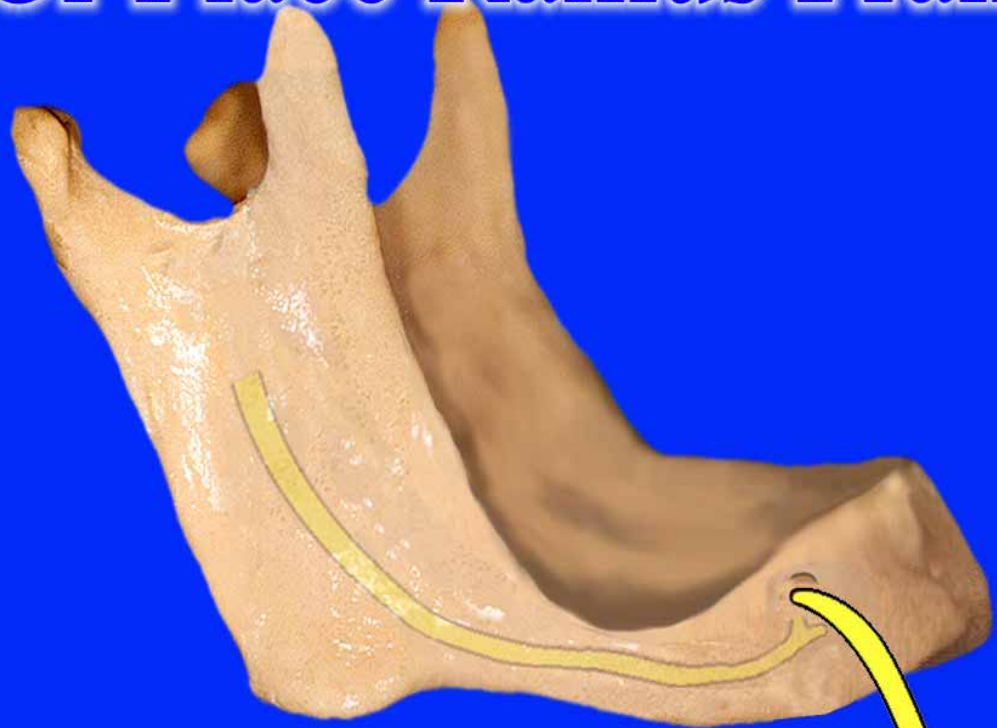
Fitted 1974 Still functioning well



Menu



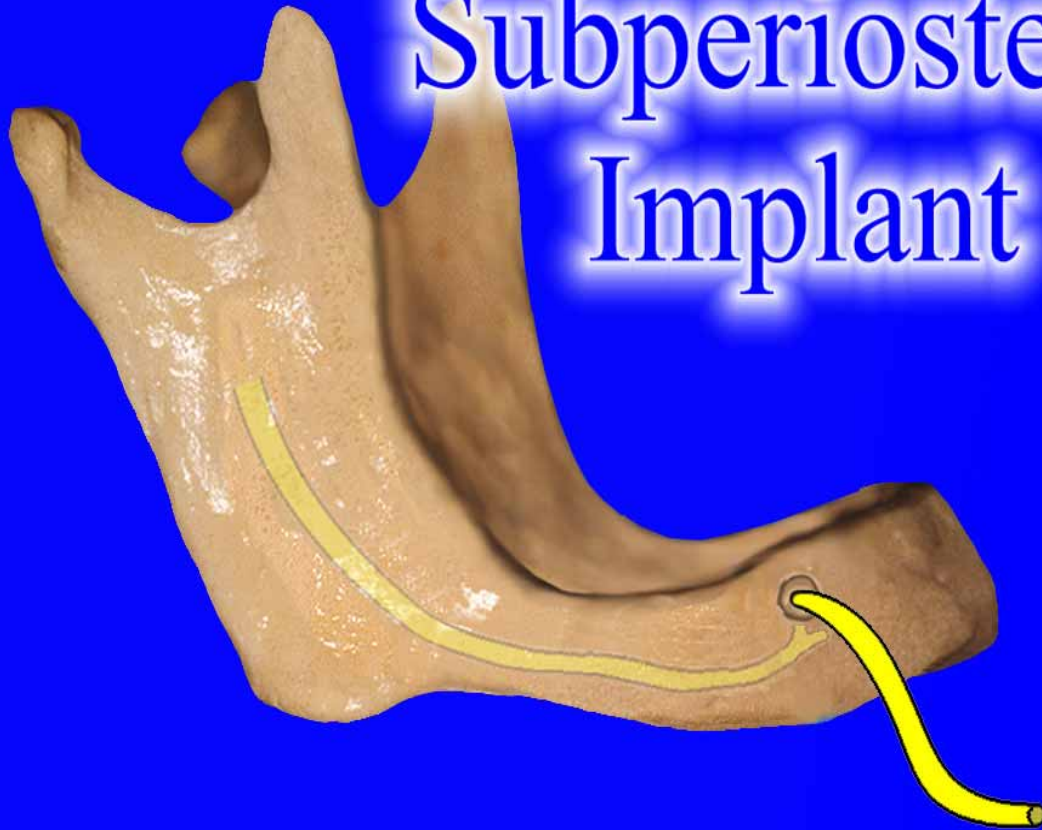
Or Place Ramus Frame



Menu



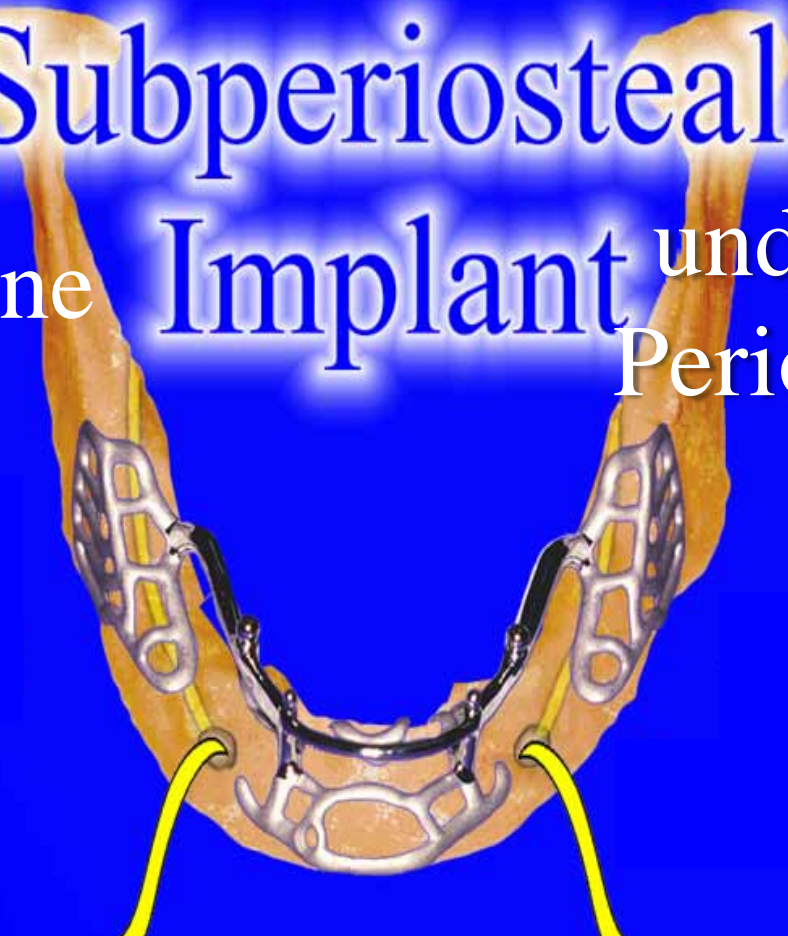Subperiosteal Implant



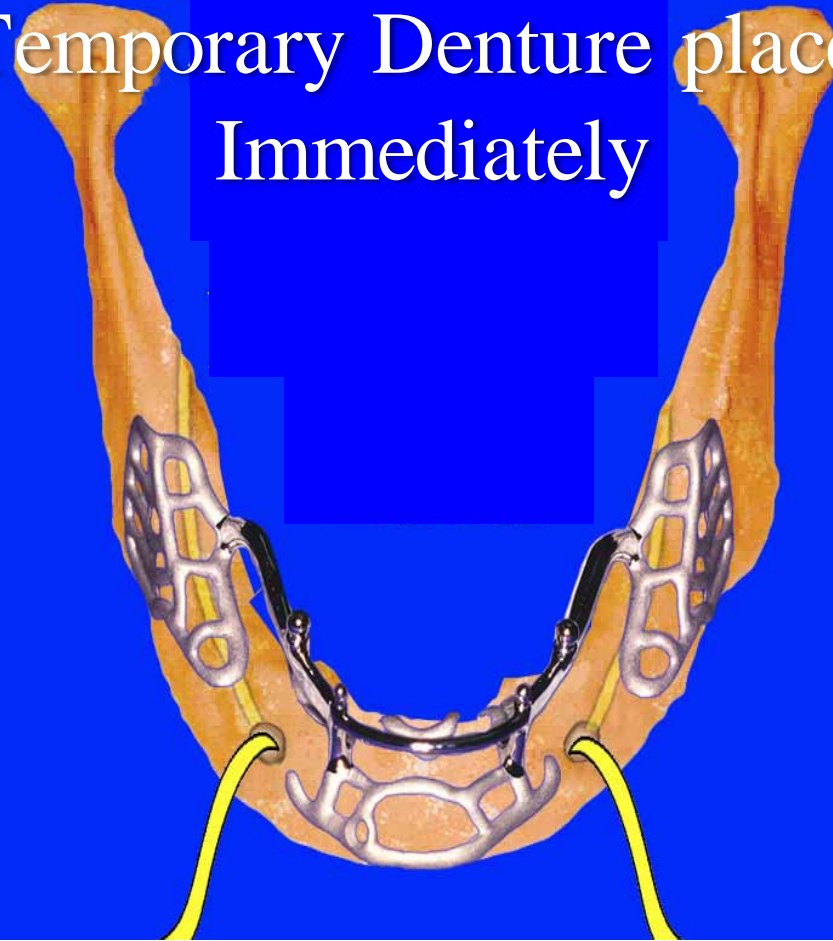
Menu



Subperiosteal On Bone Implant under the Periosteum



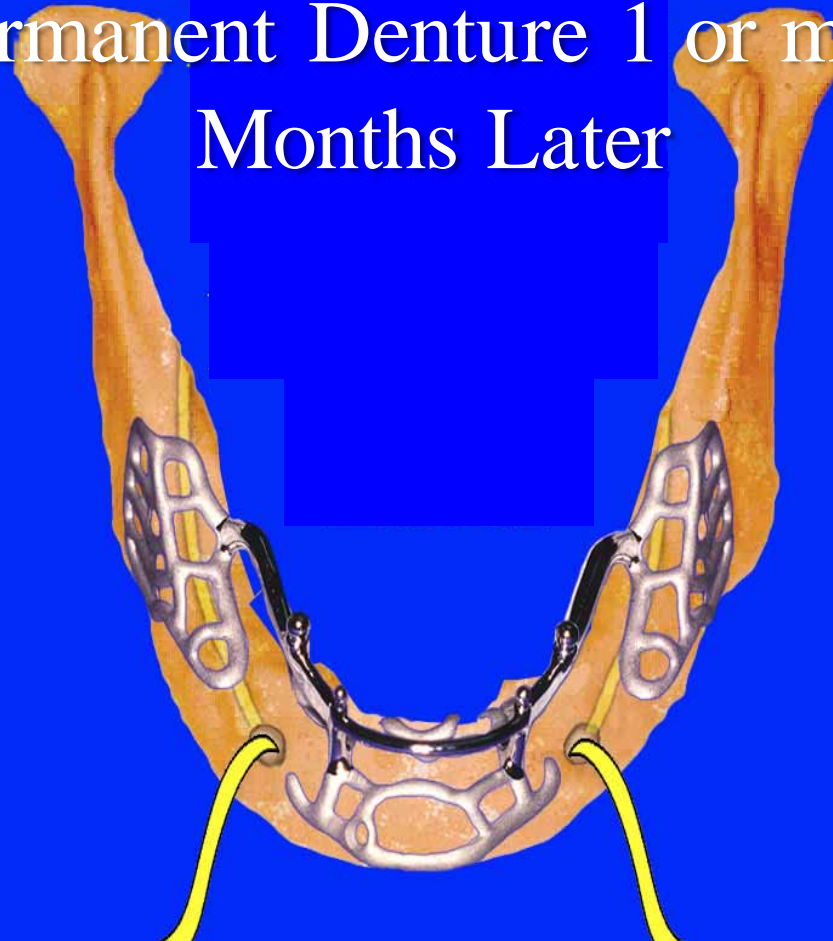
Temporary Denture placed Immediately



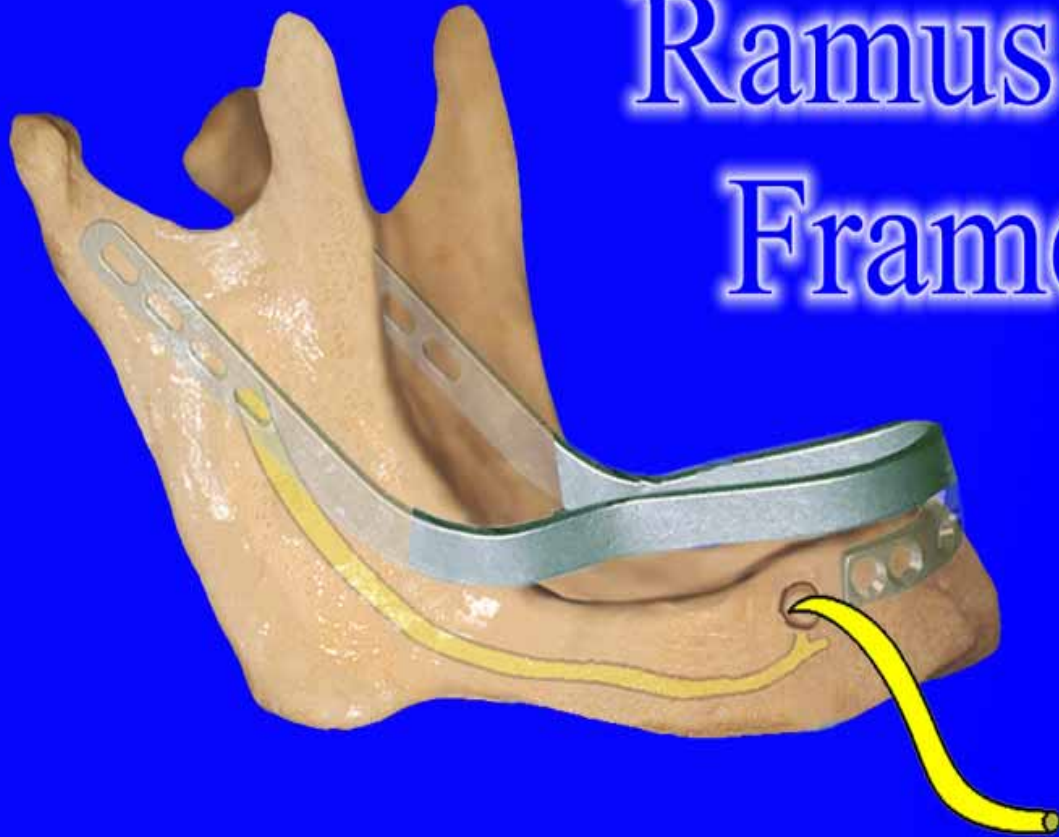
Menu



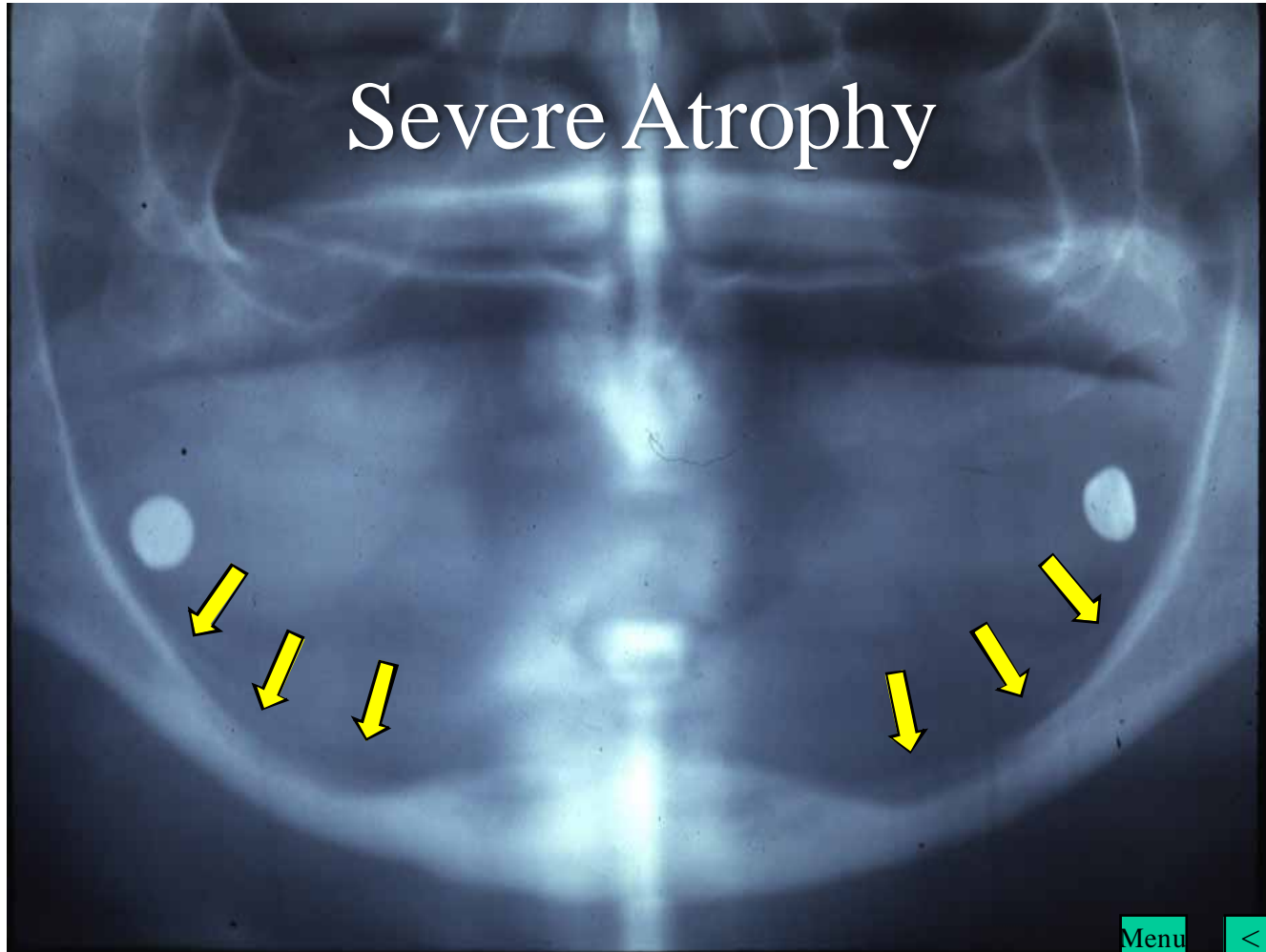
Permanent Denture 1 or more
Months Later



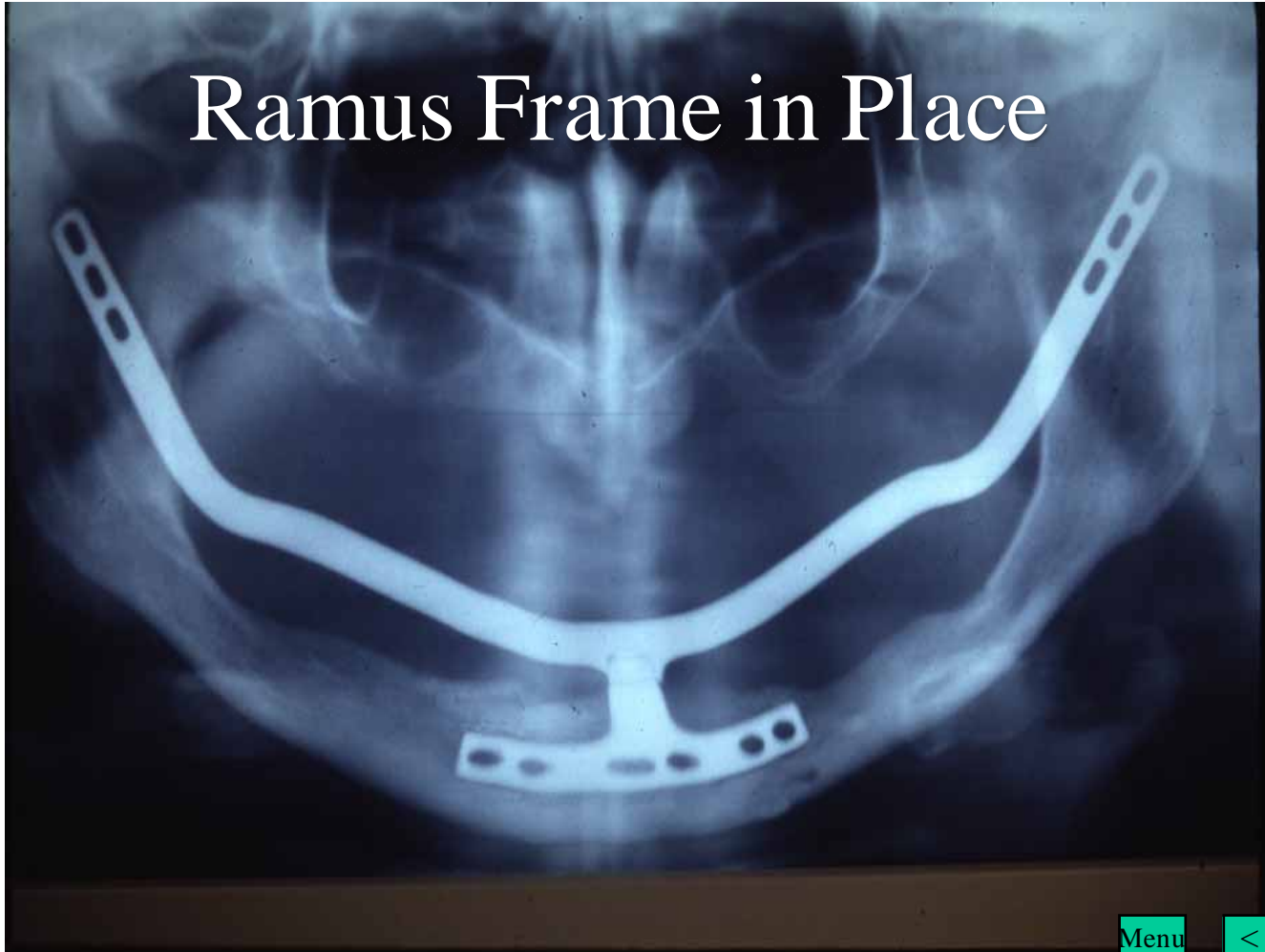
Ramus Frame



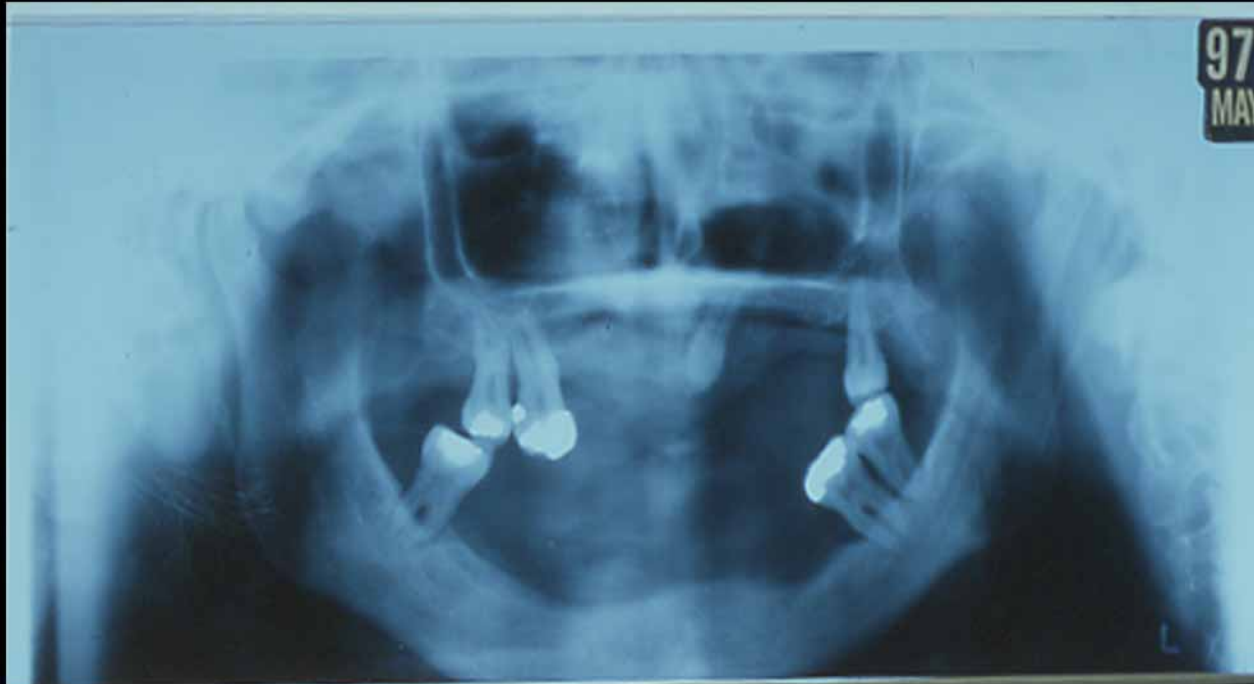Severe Atrophy

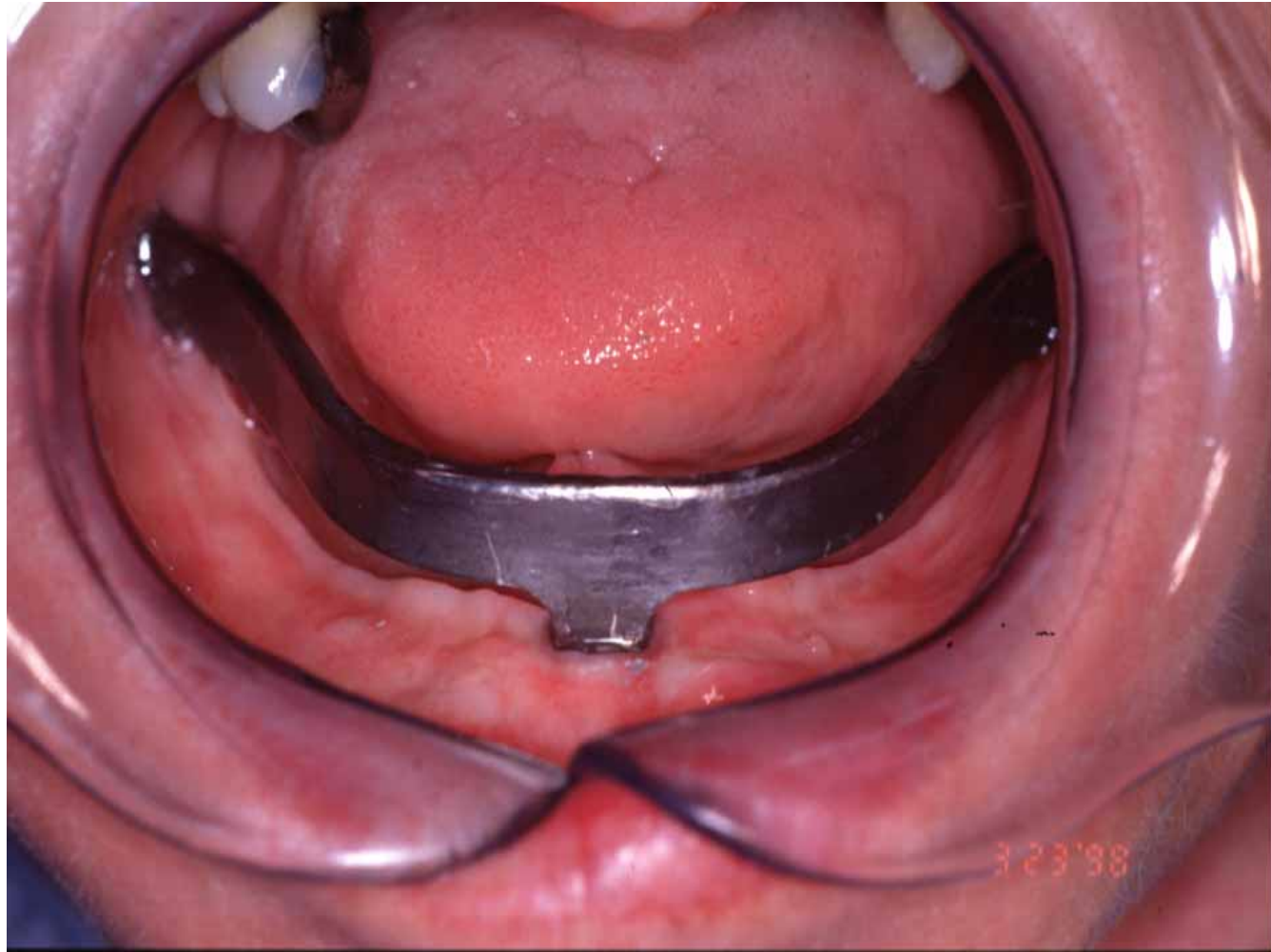


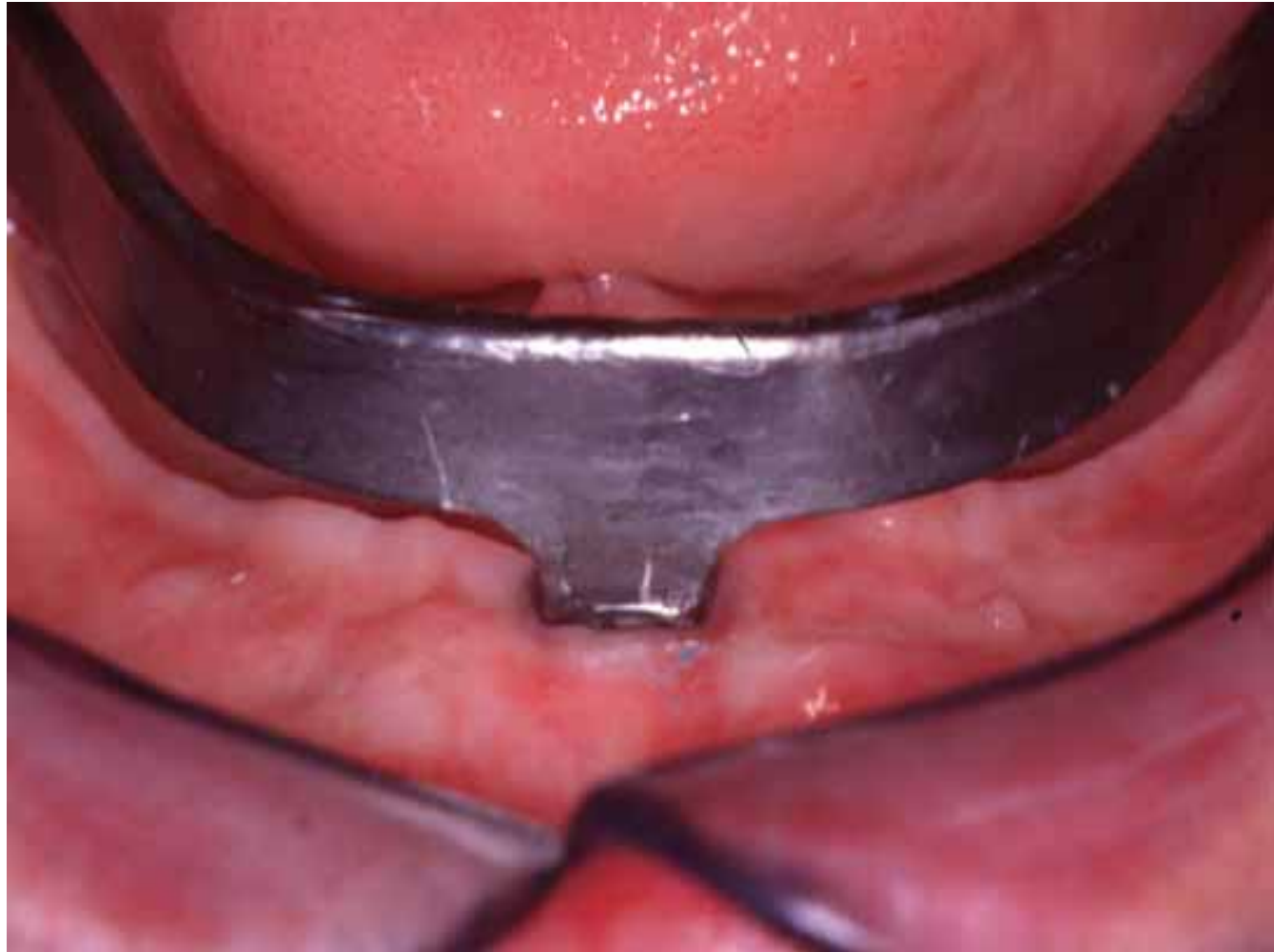Ramus Frame in Place

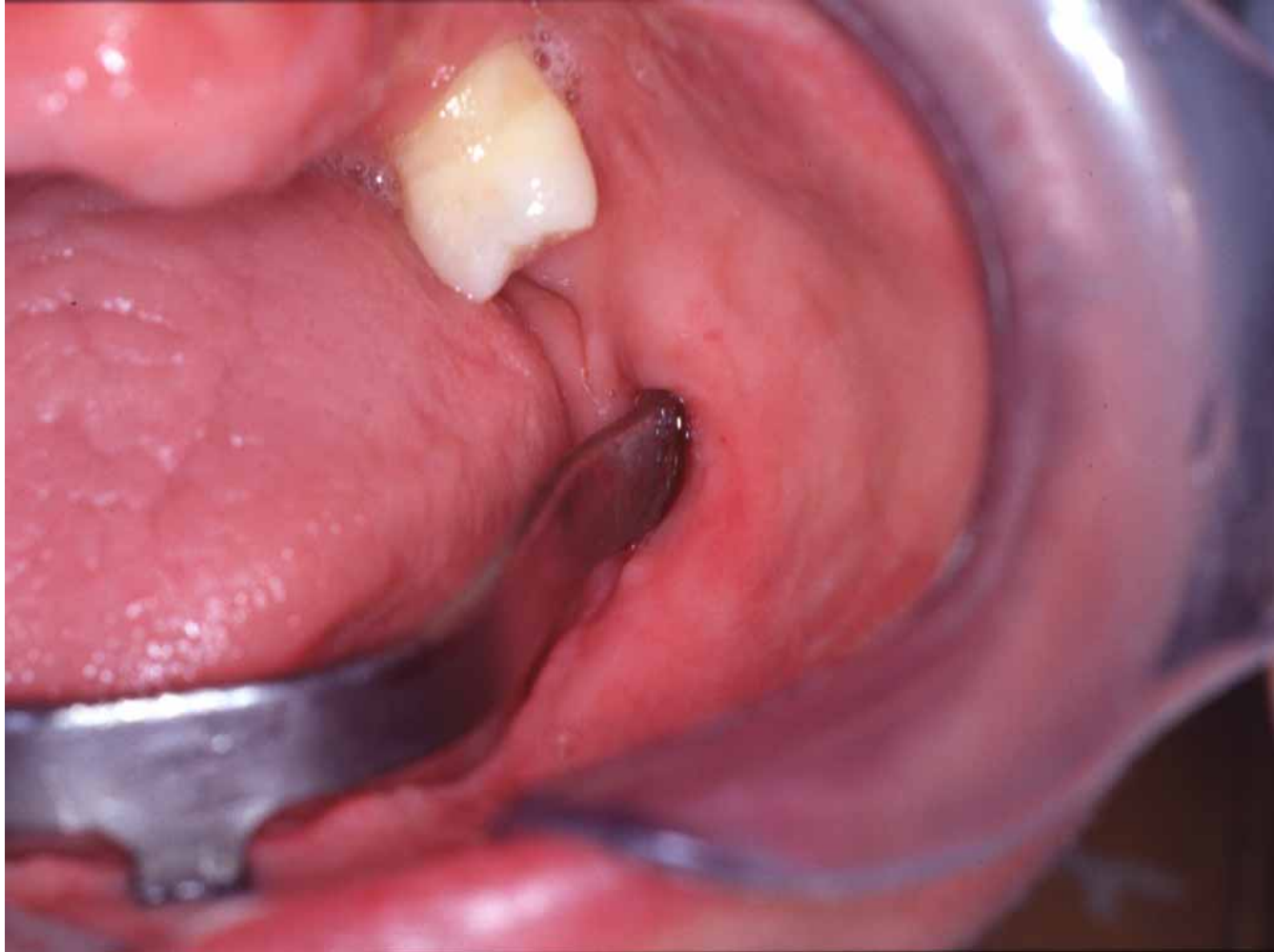


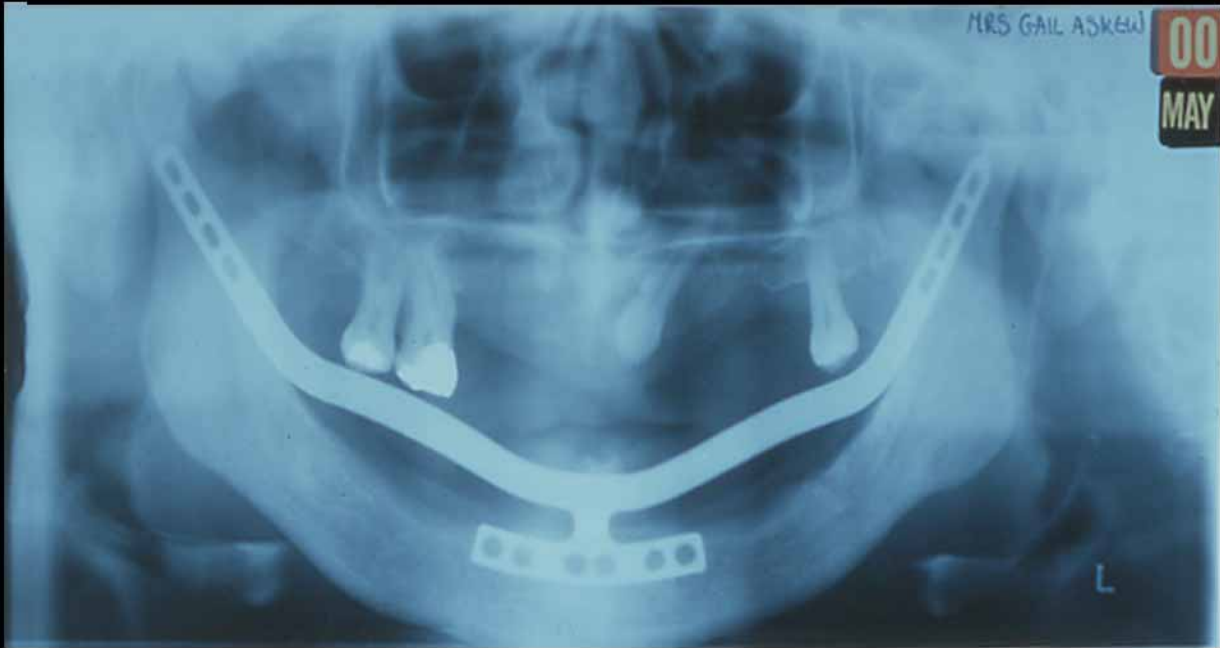A Clinical Case



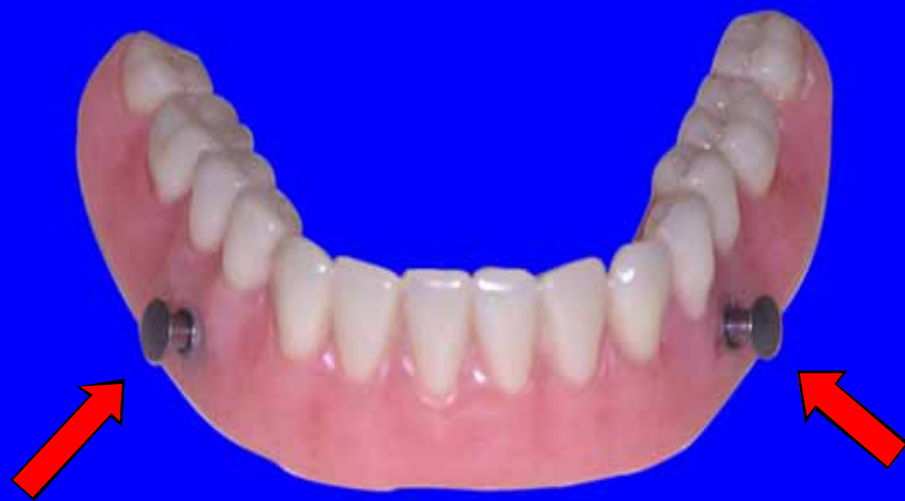






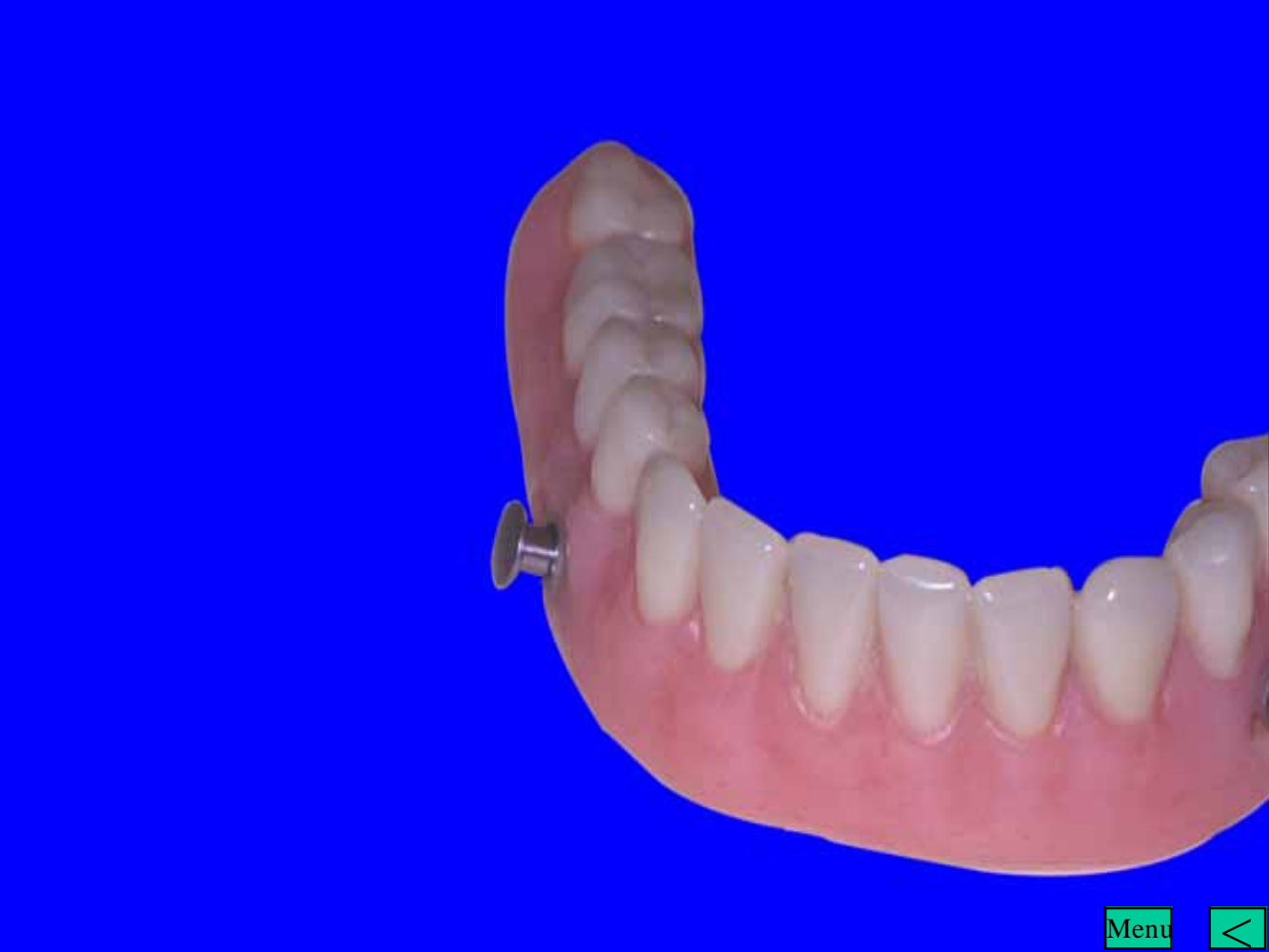
Lew Attachments

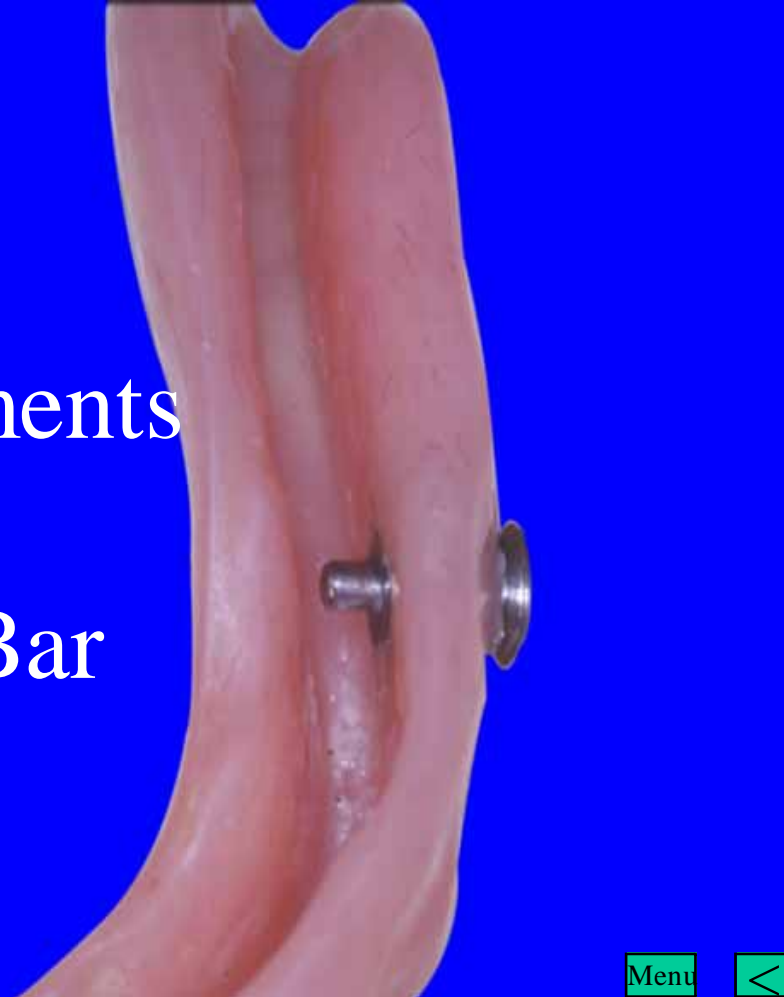

Menu





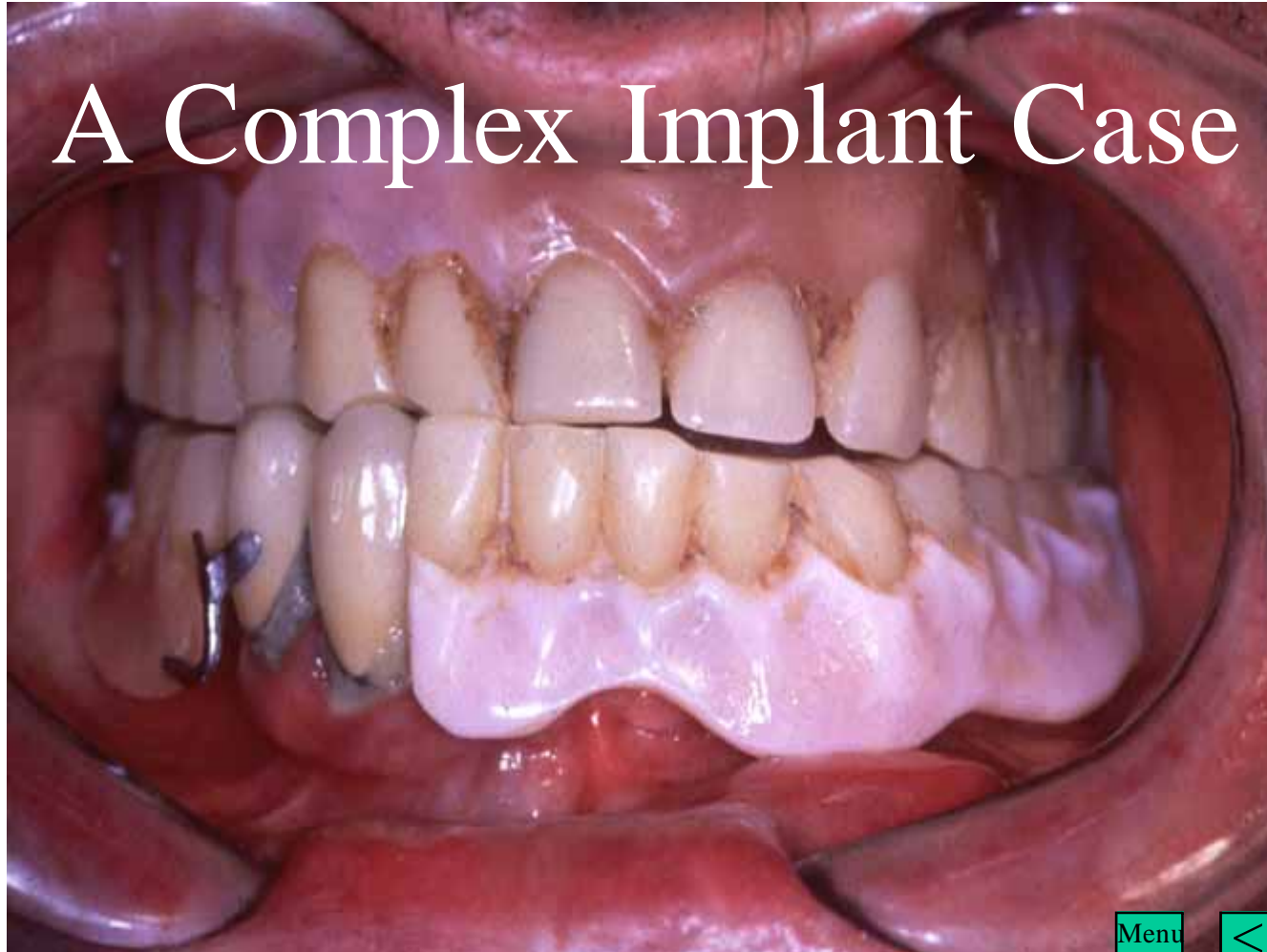
Low Attachments
Fit
under the Bar



Menu

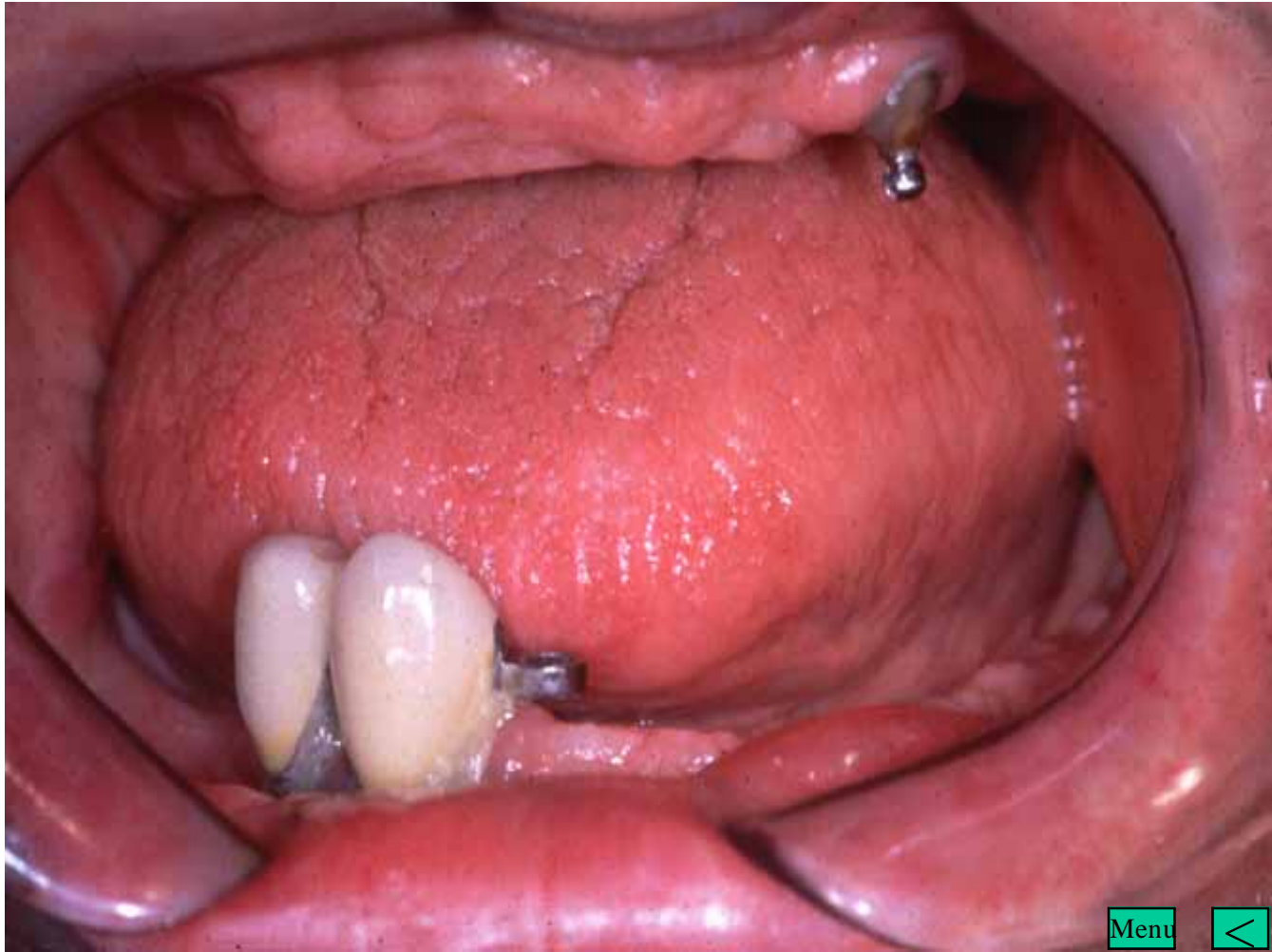

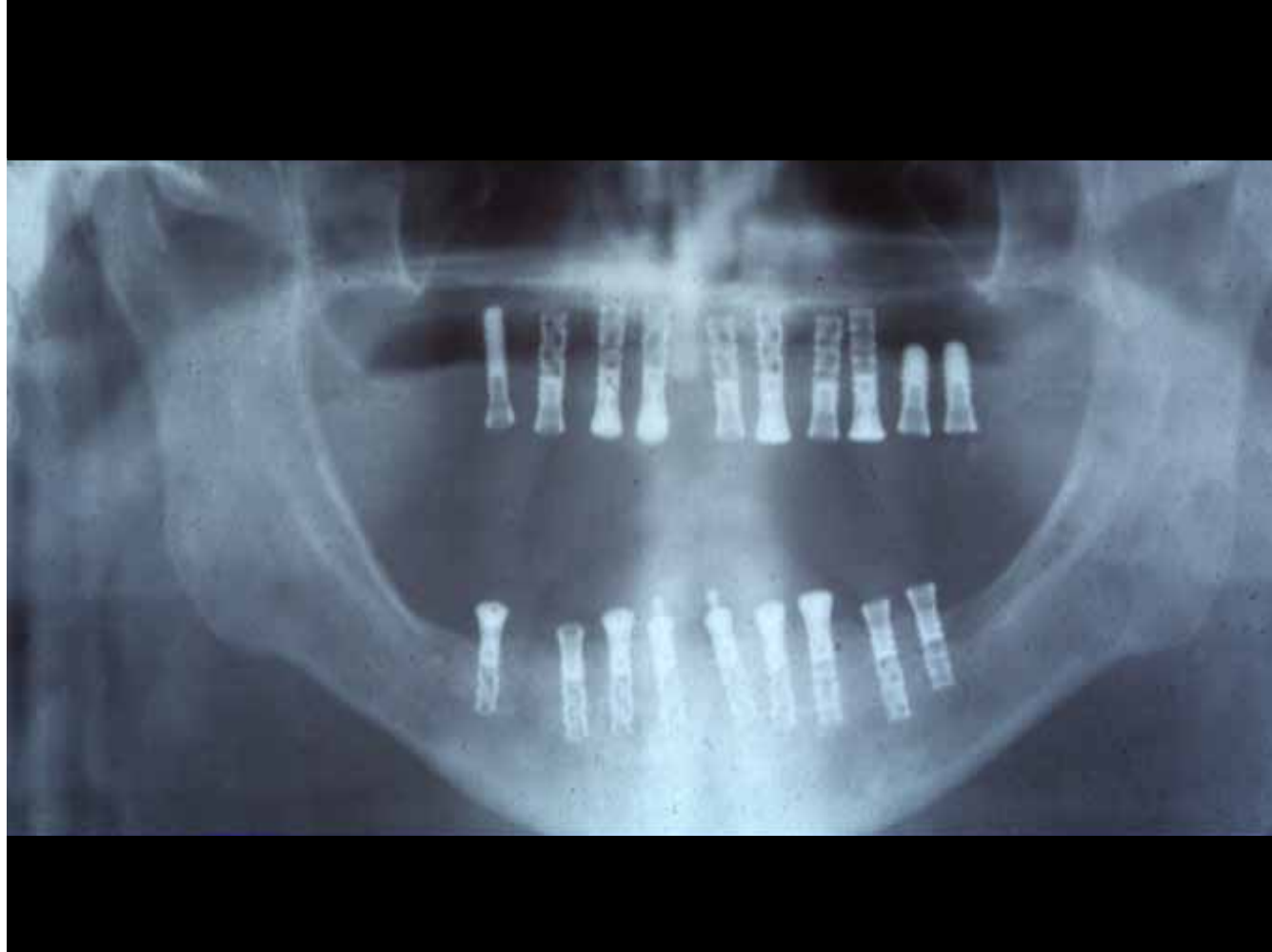
A Complex Implant Case

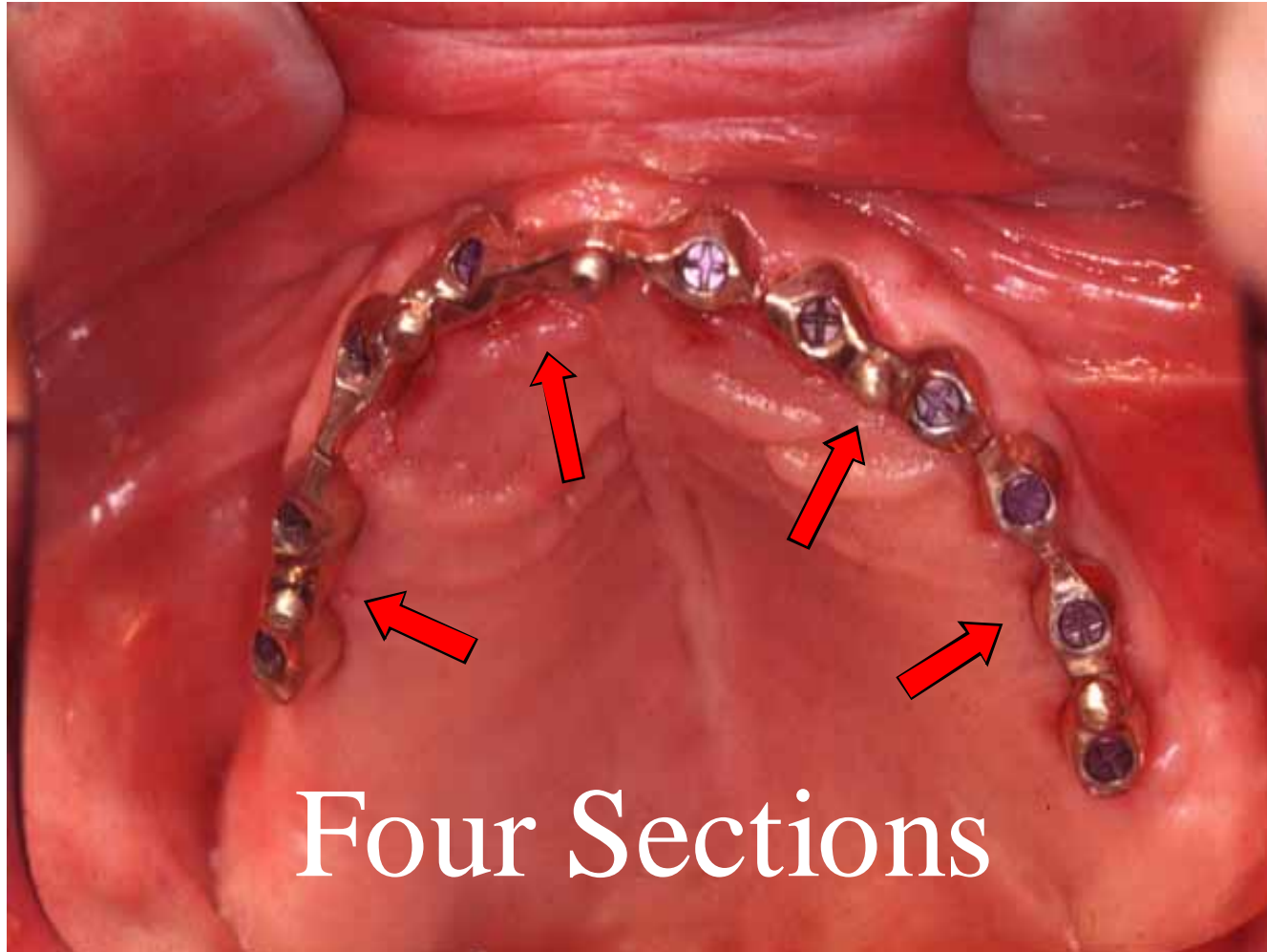


Menu

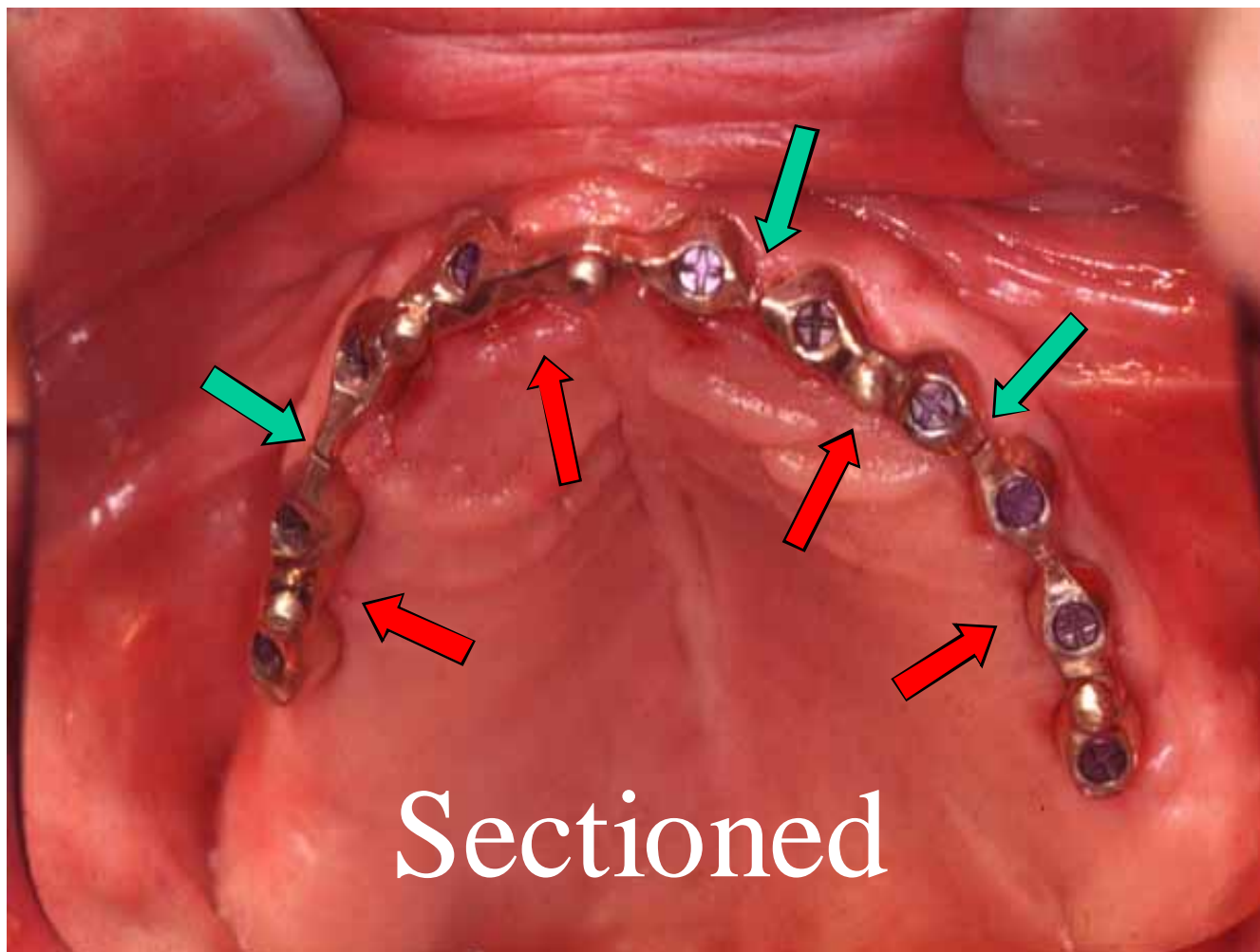




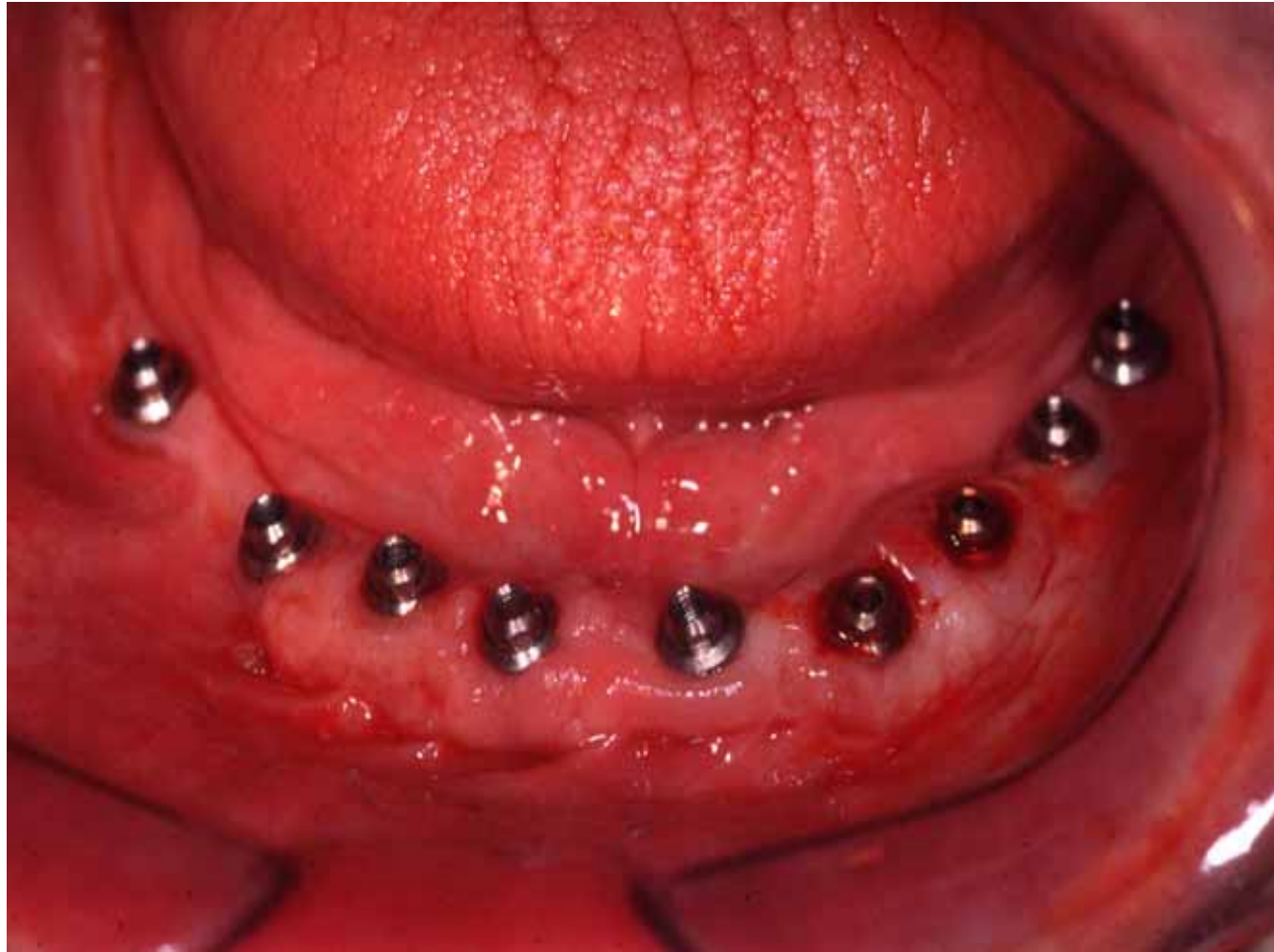



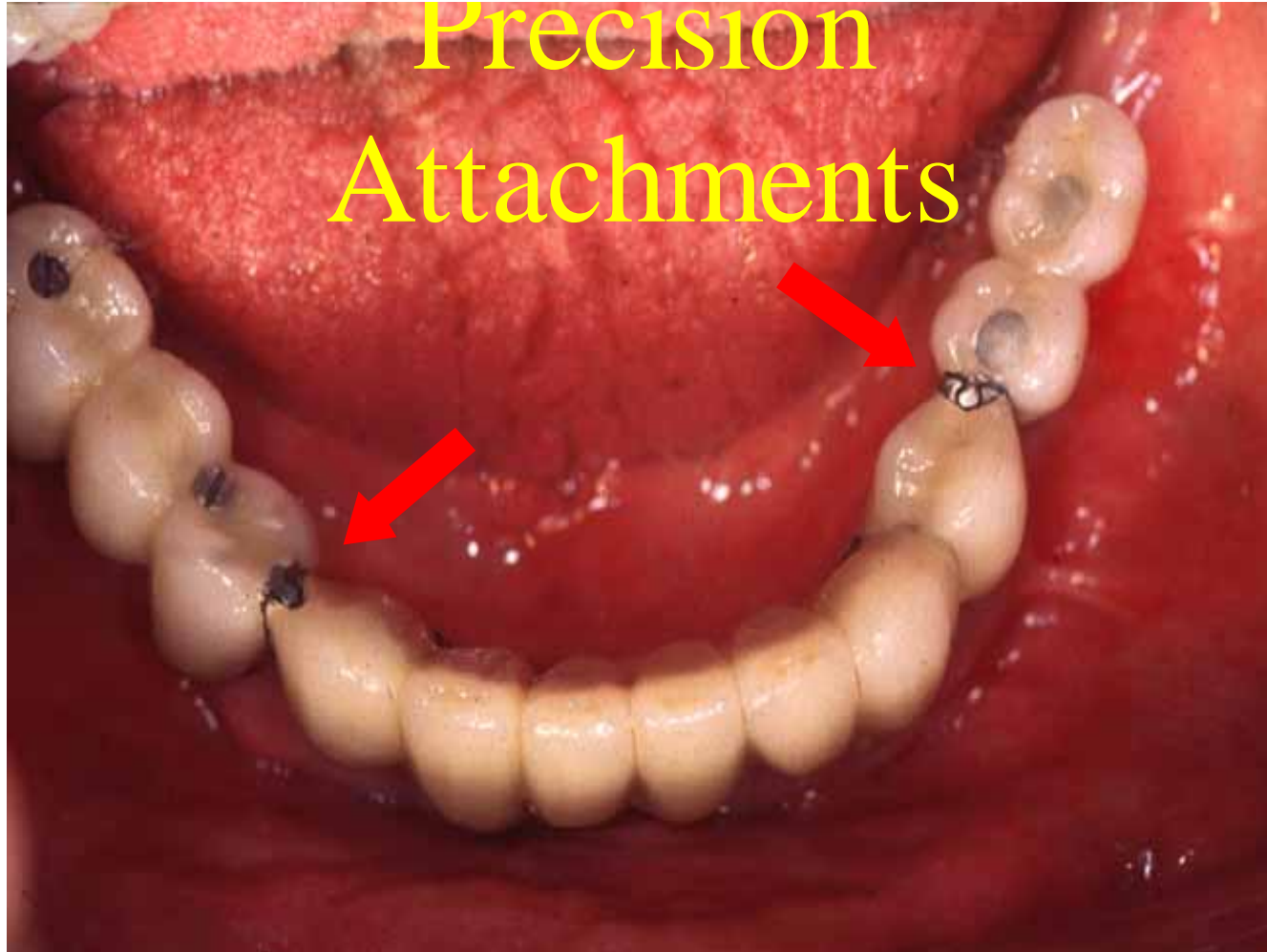
Four Sections



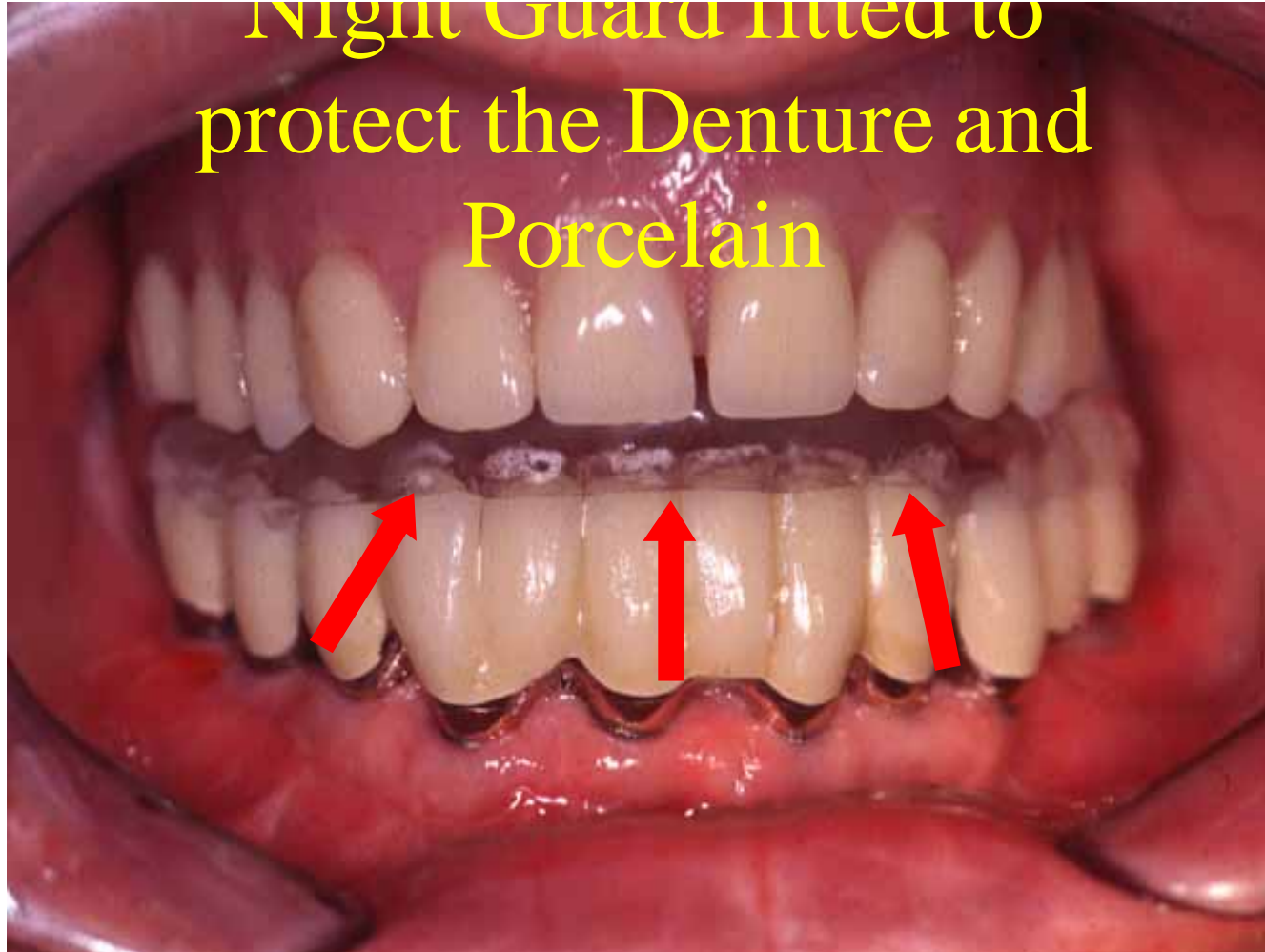
Sectioned



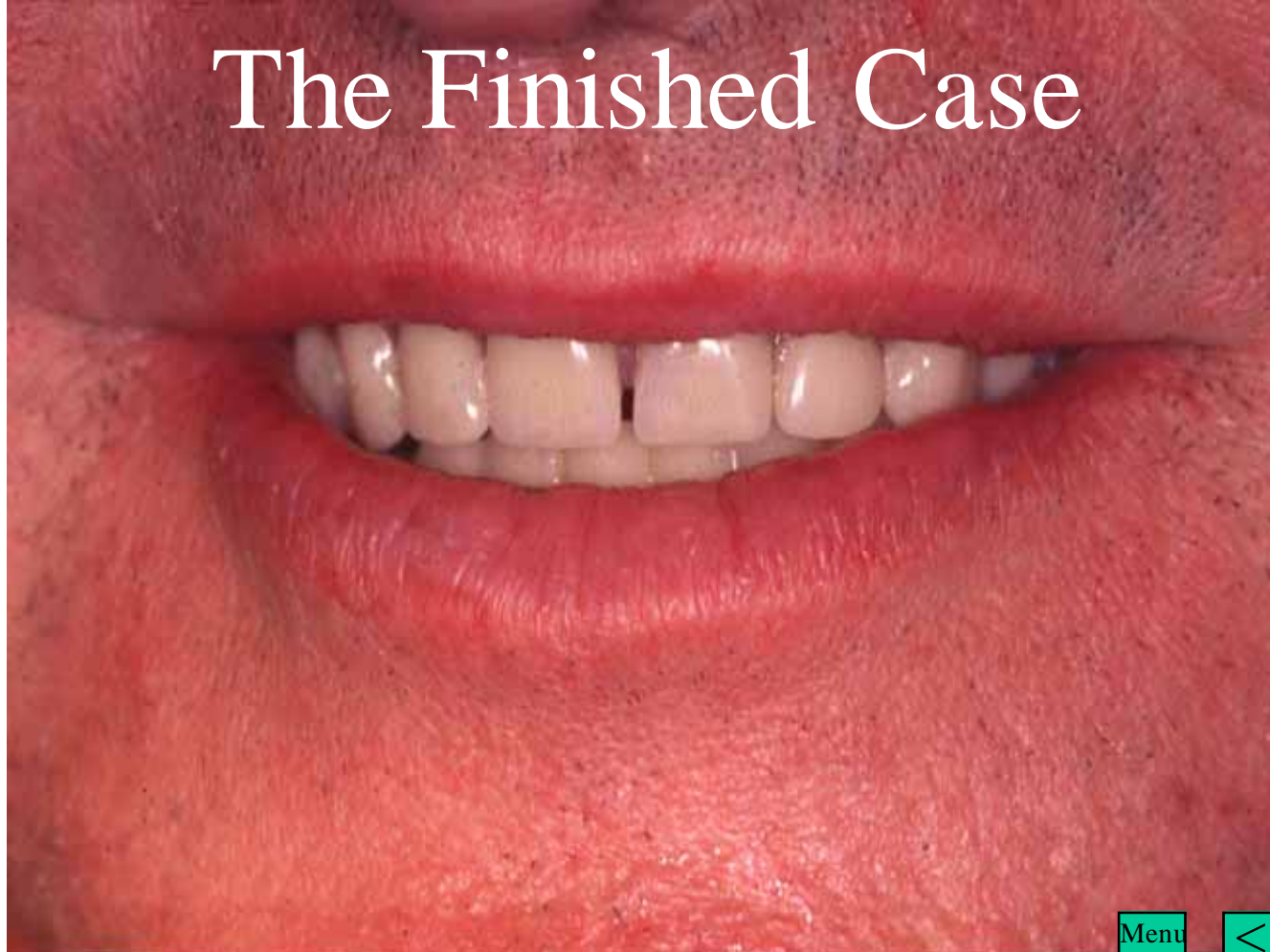
Precision Attachments



Night Guard fitted to
protect the Denture and
Porcelain



The Finished Case



Menu



The End

Menu

