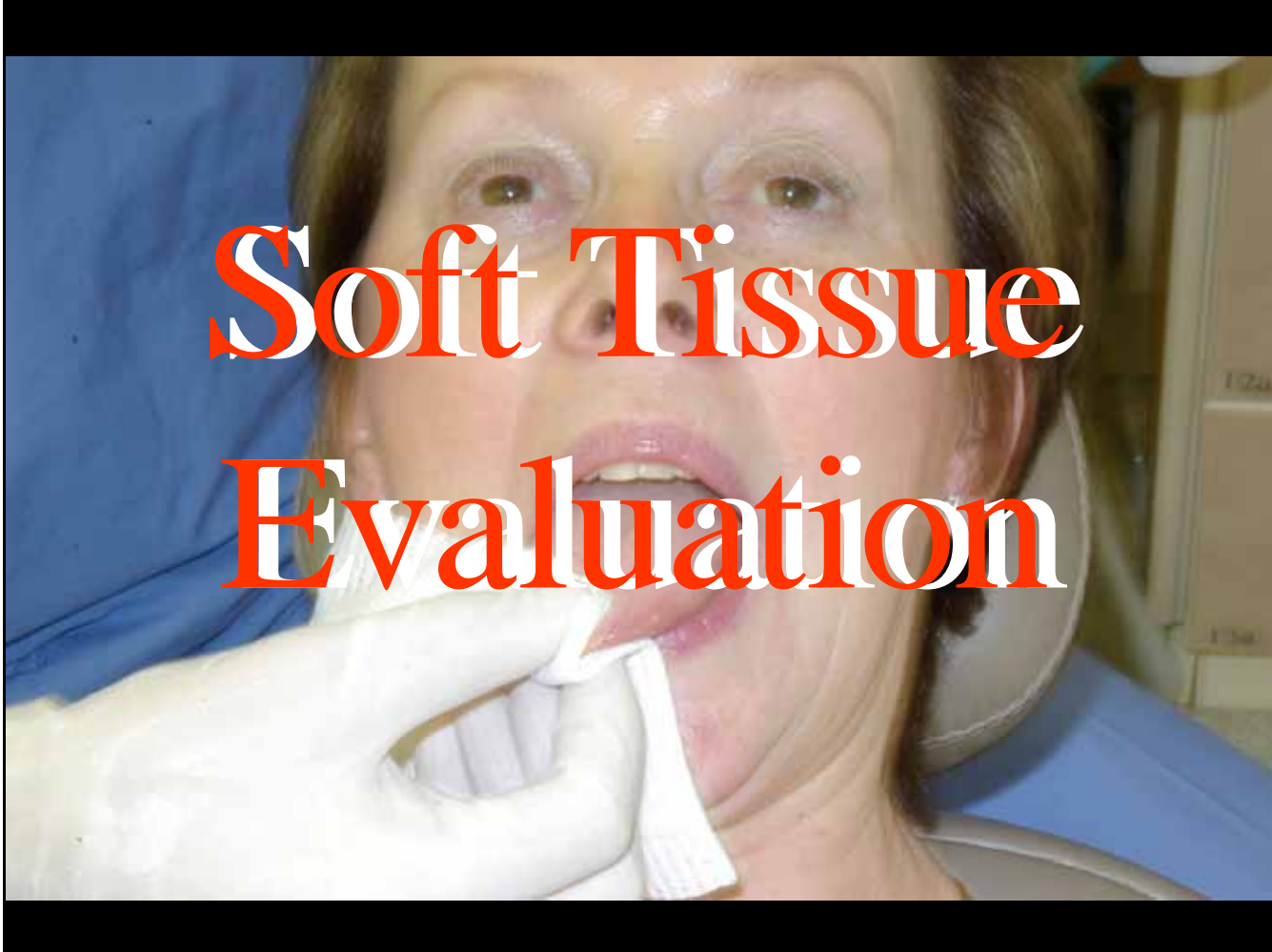
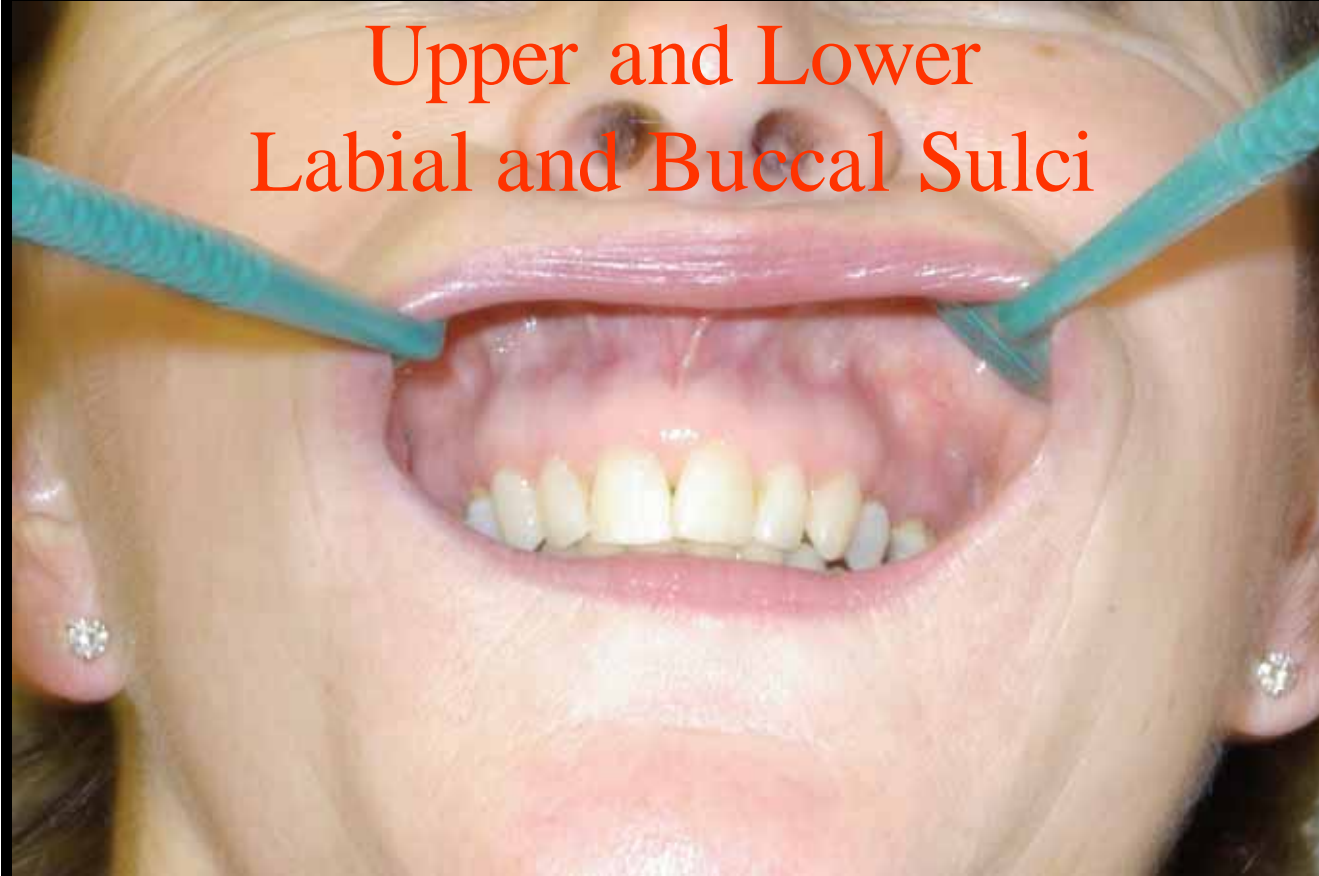
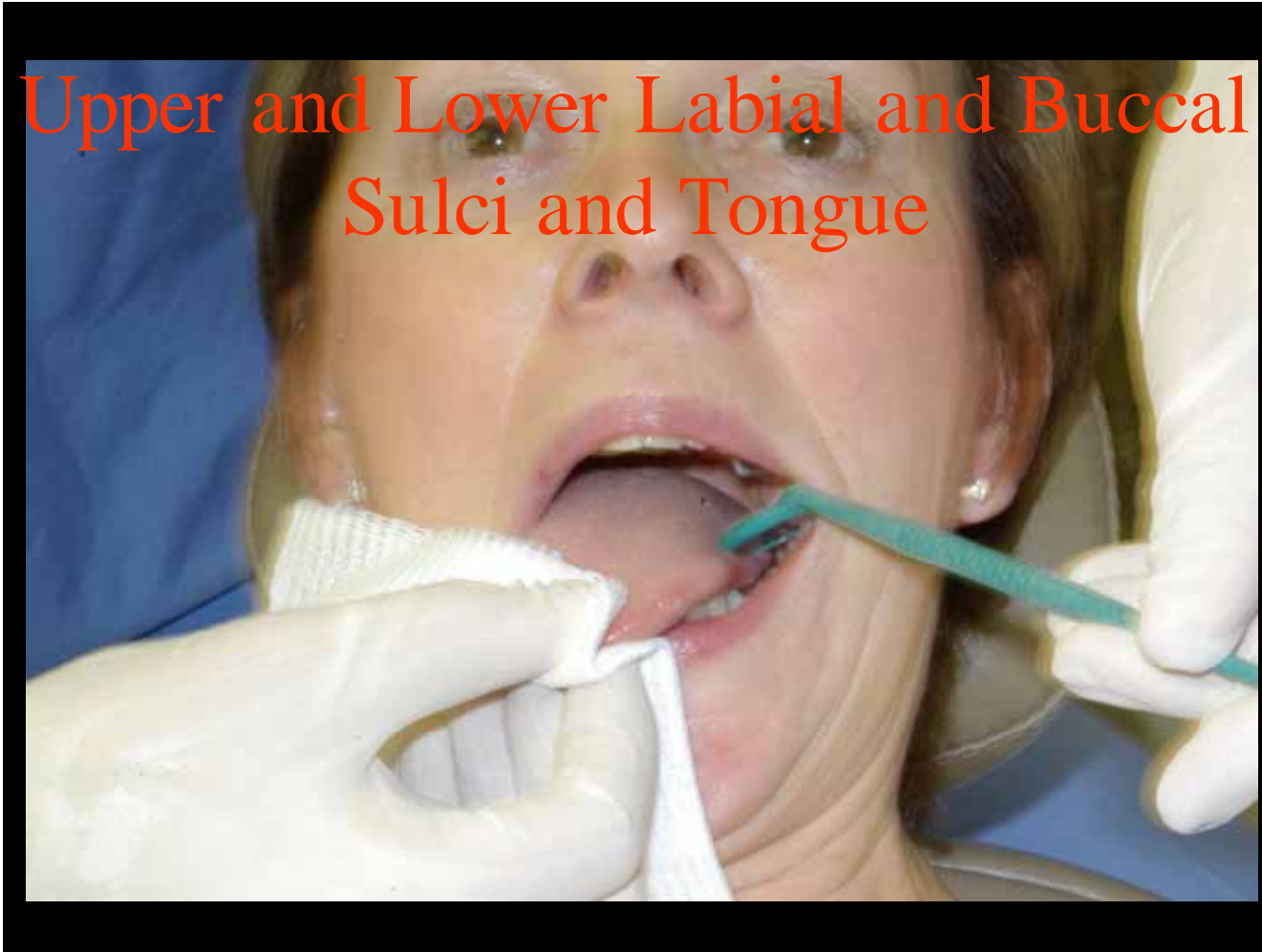


Soft Tissue Evaluation

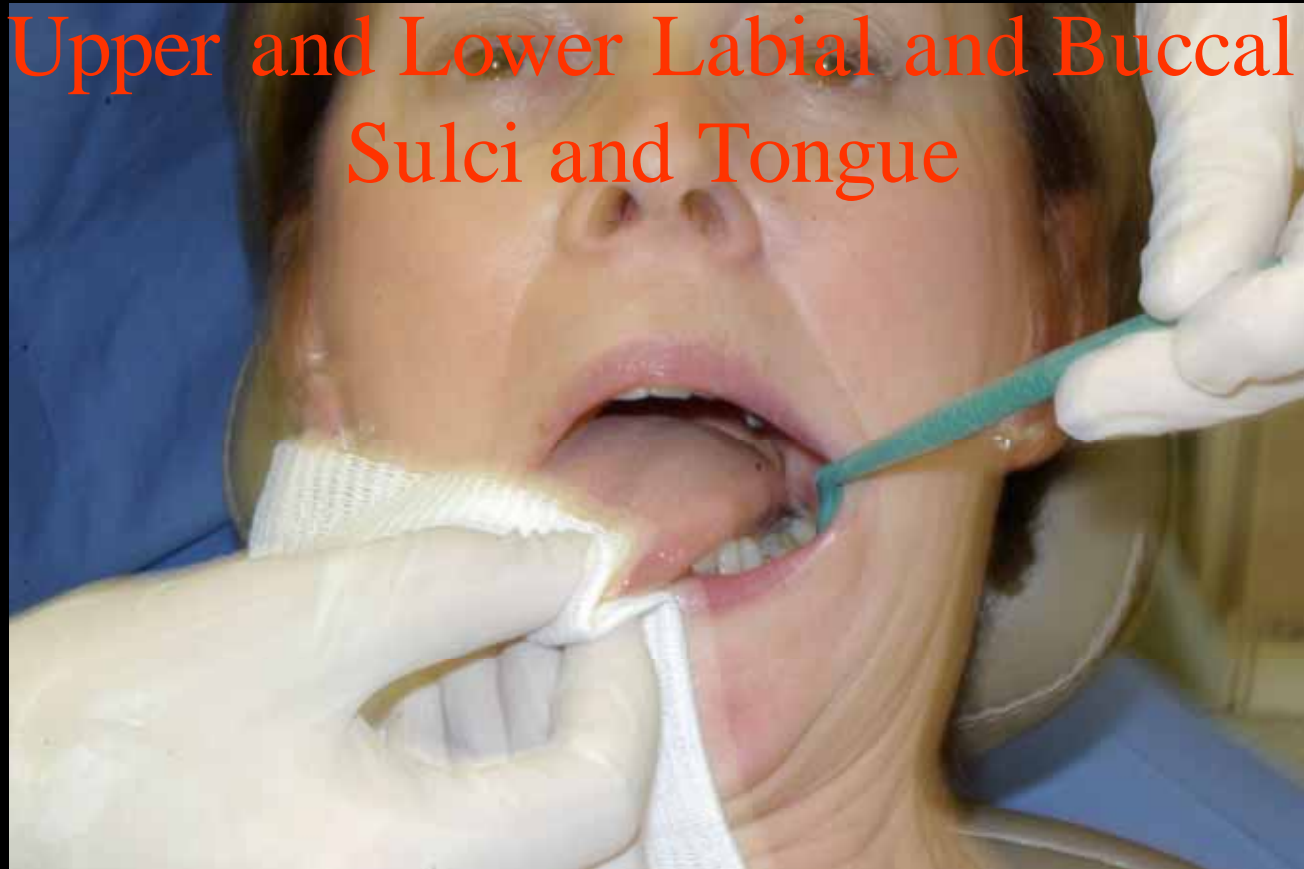
Upper and Lower
Labial and Buccal Sulci



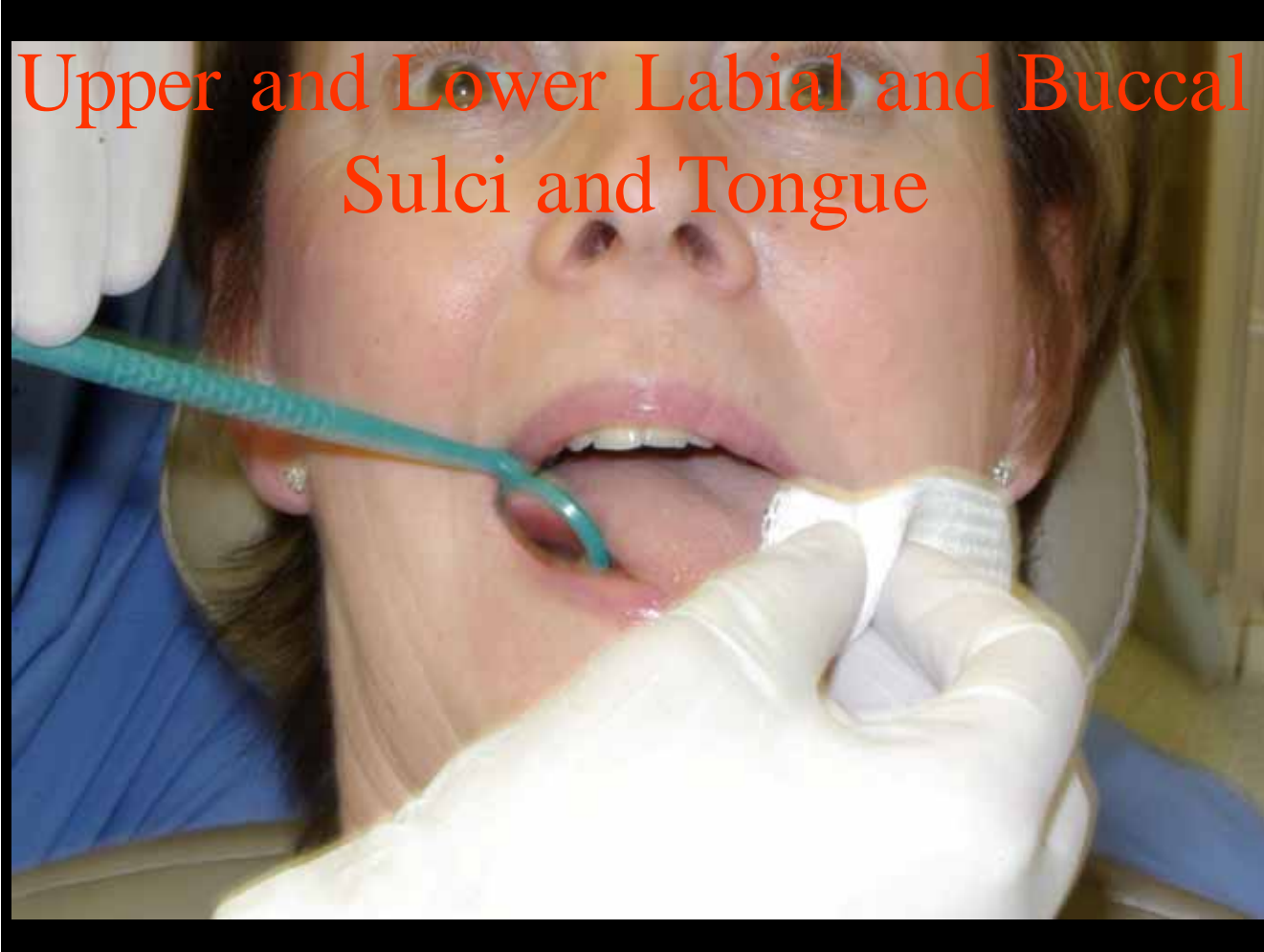
Upper and Lower Labial and Buccal
Sulci and Tongue



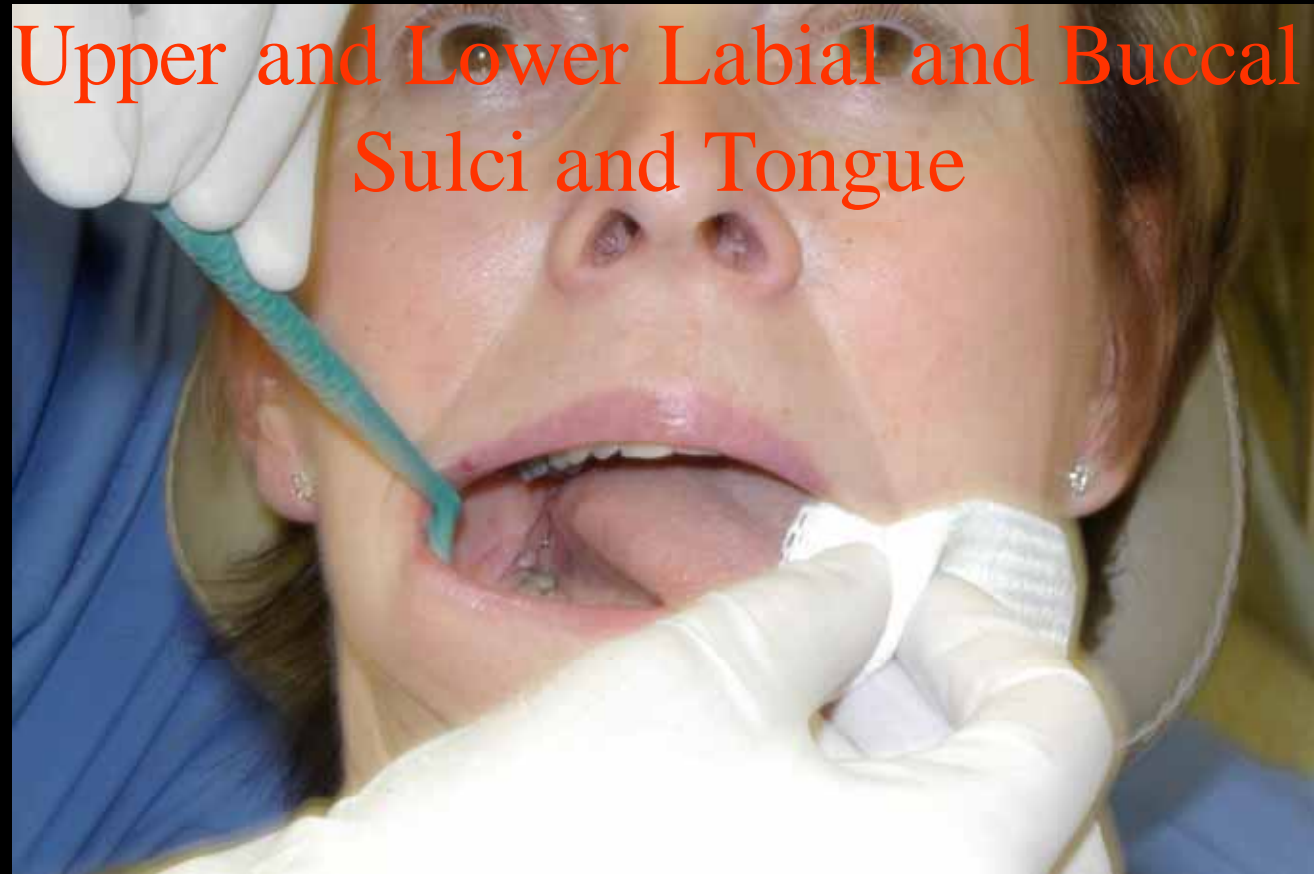
Upper and Lower Labial and Buccal
Sulci and Tongue



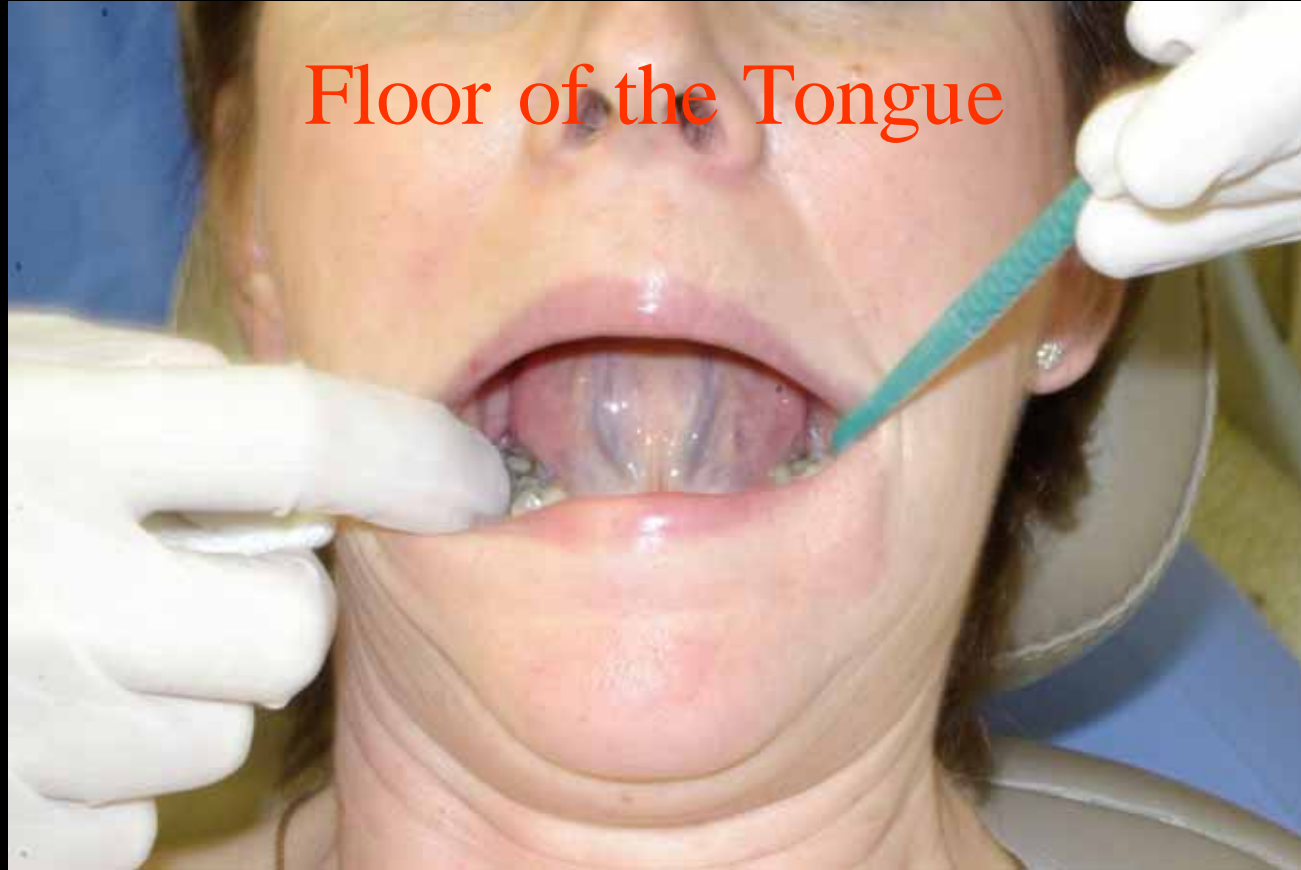Upper and Lower Labial and Buccal
Sulci and Tongue



Upper and Lower Labial and Buccal
Sulci and Tongue



Floor of the Tongue



Retracting with a Mirror

Examine

- The Lower Labial Sulcus
- The Lower Buccal Sulcus
- The Upper Labial Sulcus
- The Upper Buccal Sulcus
- The Palate

Retract with a Mirror

- Hold the Tip of the Tongue with Gauze Examine
- The Top of the Tongue
- The Sides of the Tongue
- The Lingual Sulcus

The End

Menu

