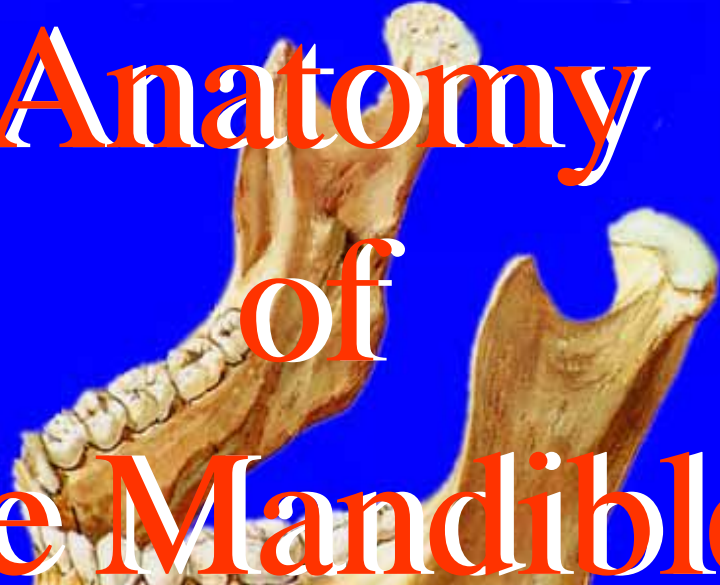


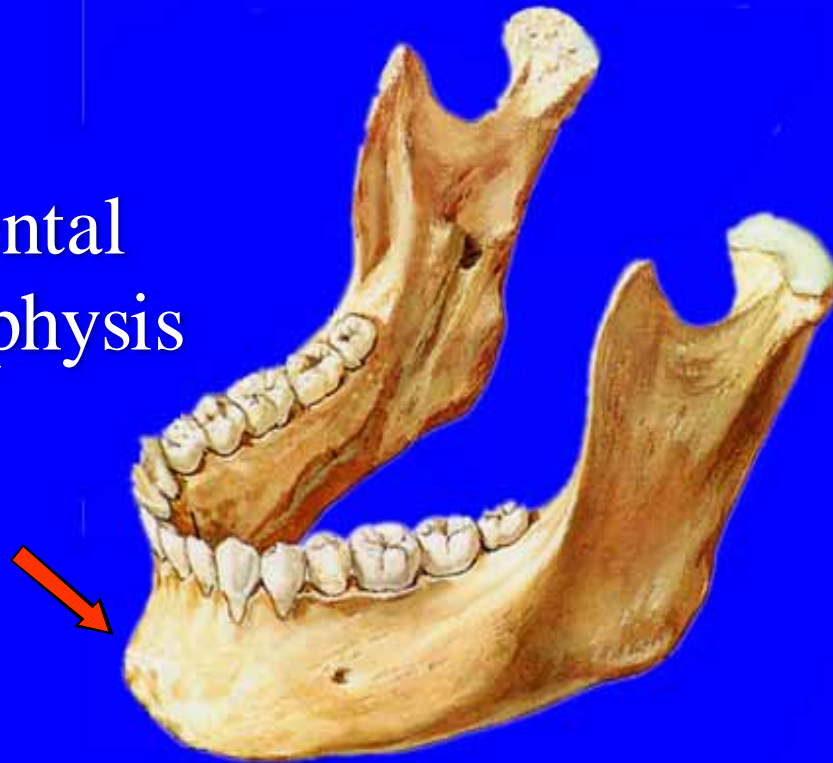
Anatomy of the Mandible



Menu



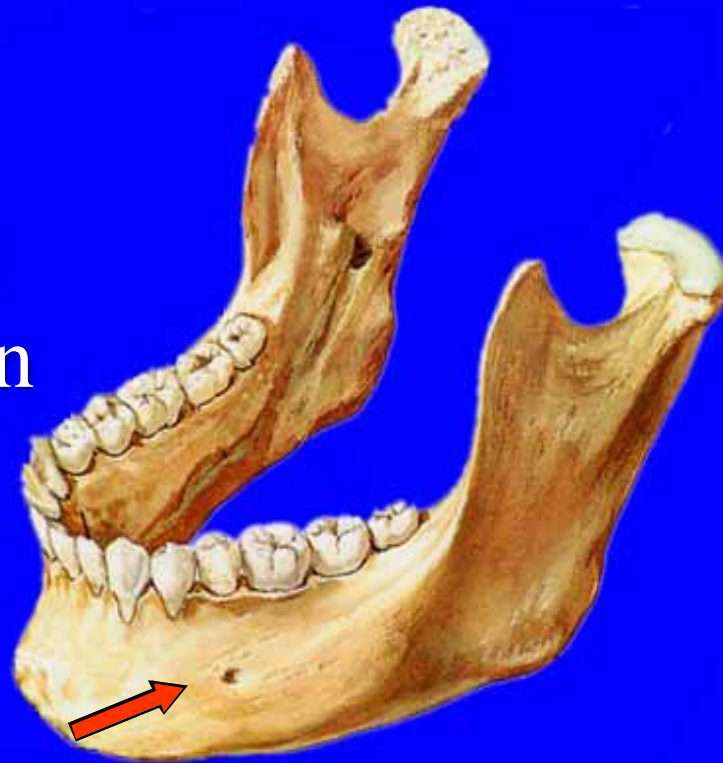Mental
Symphysis



Menu

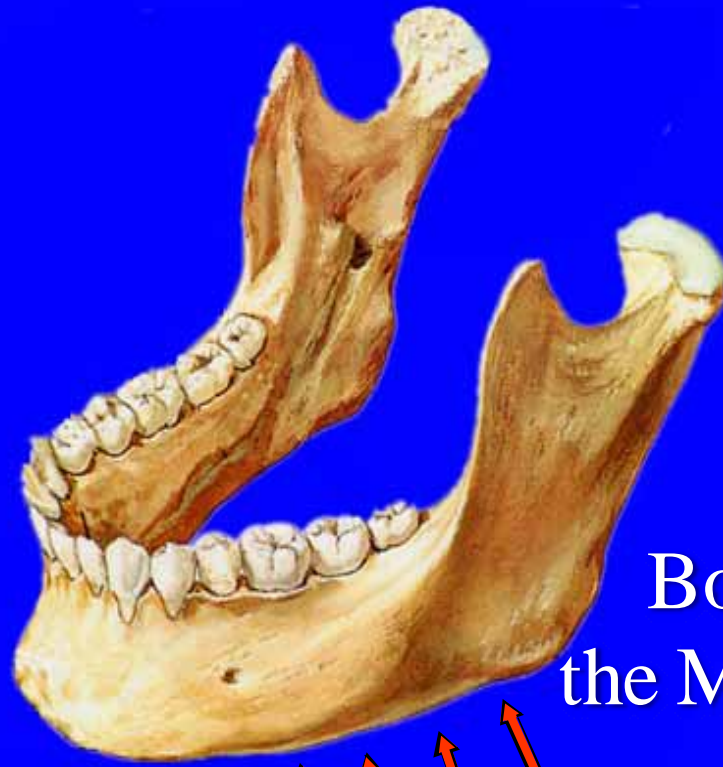

Mental Foramen



Menu



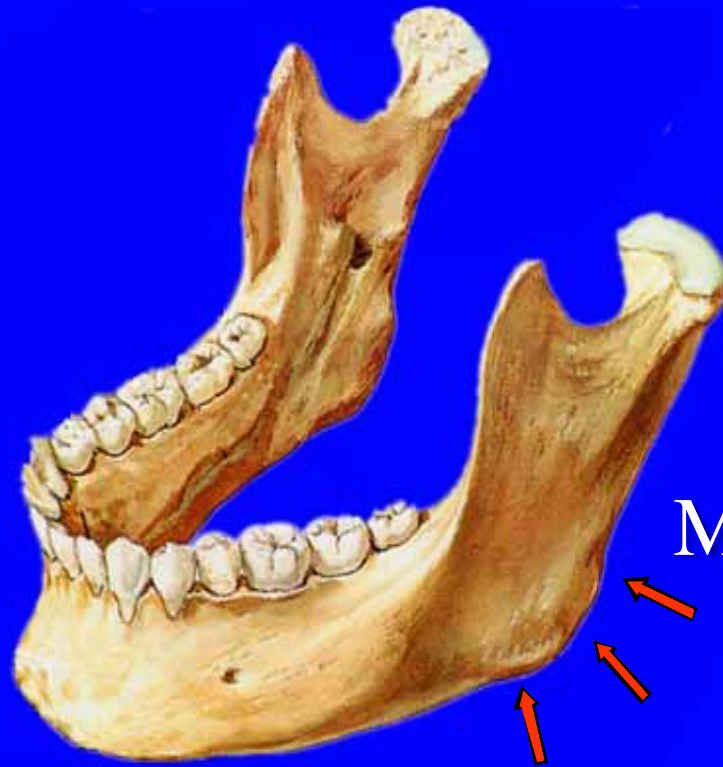

Body of
the Mandible



Menu



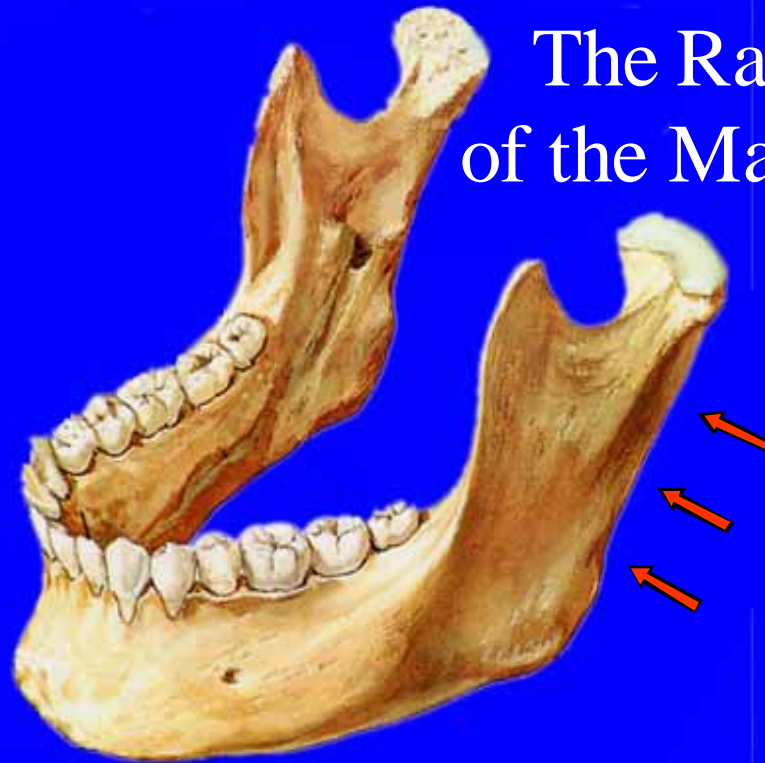

Angle
of the
Mandible

Menu



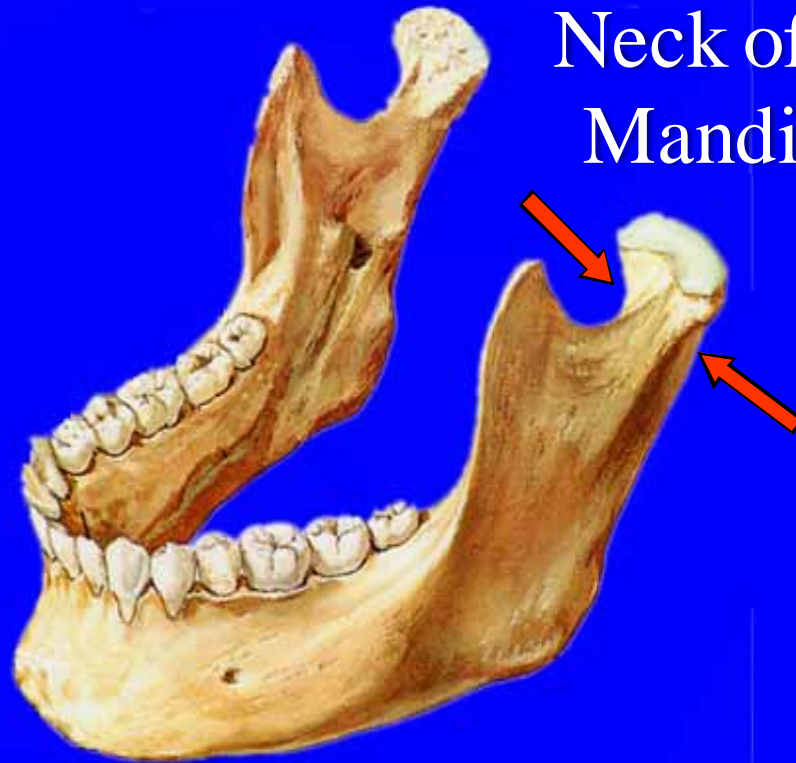
The Ramus of the Mandible



Menu



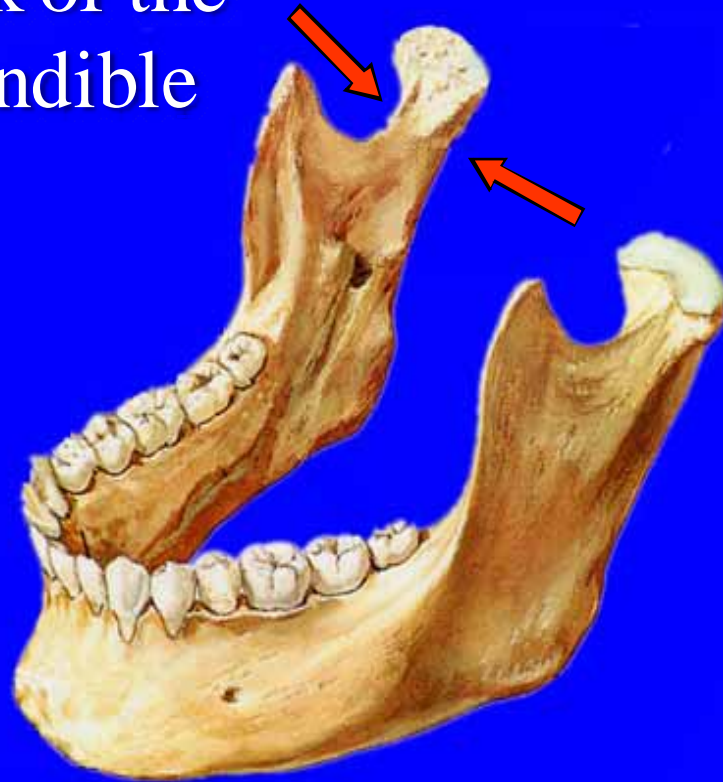
Neck of the
Mandible



Menu



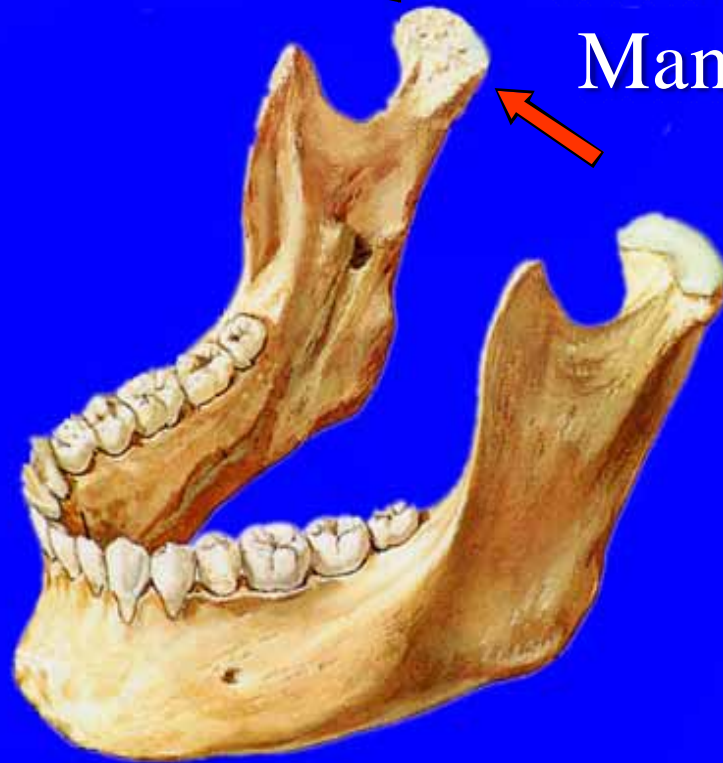Neck of the Mandible



Menu



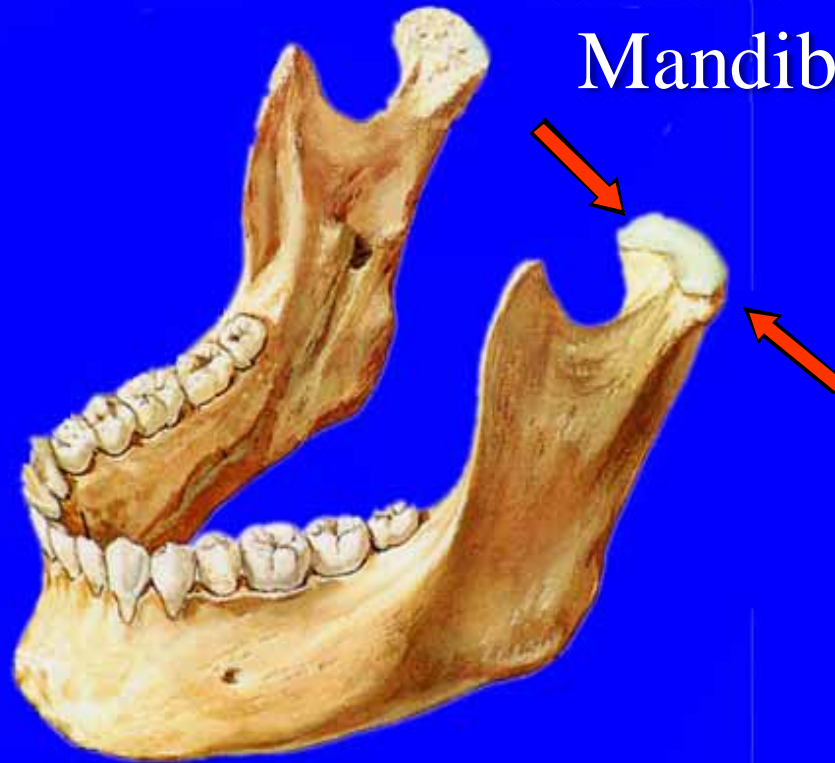
Head of the
Mandible



Menu



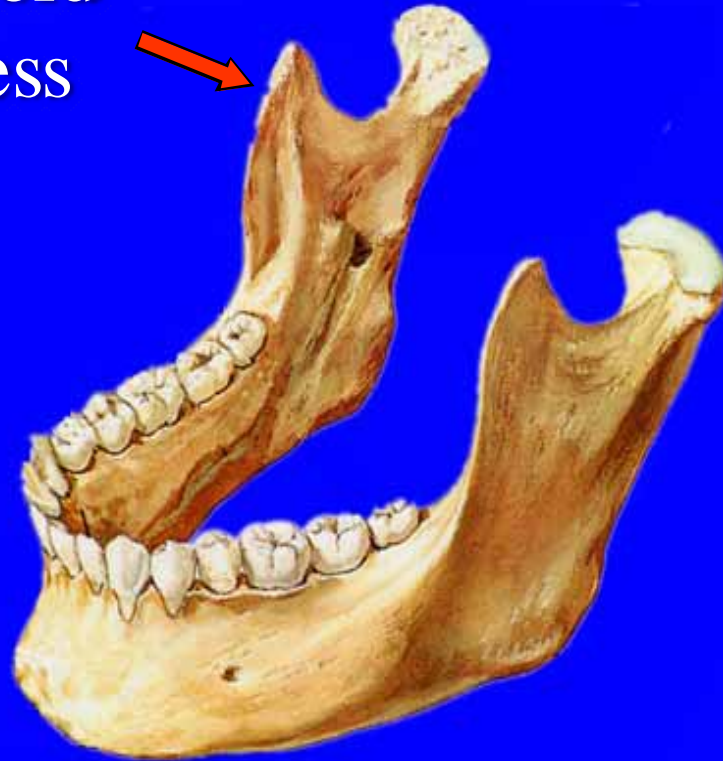Head of the
Mandible



Menu



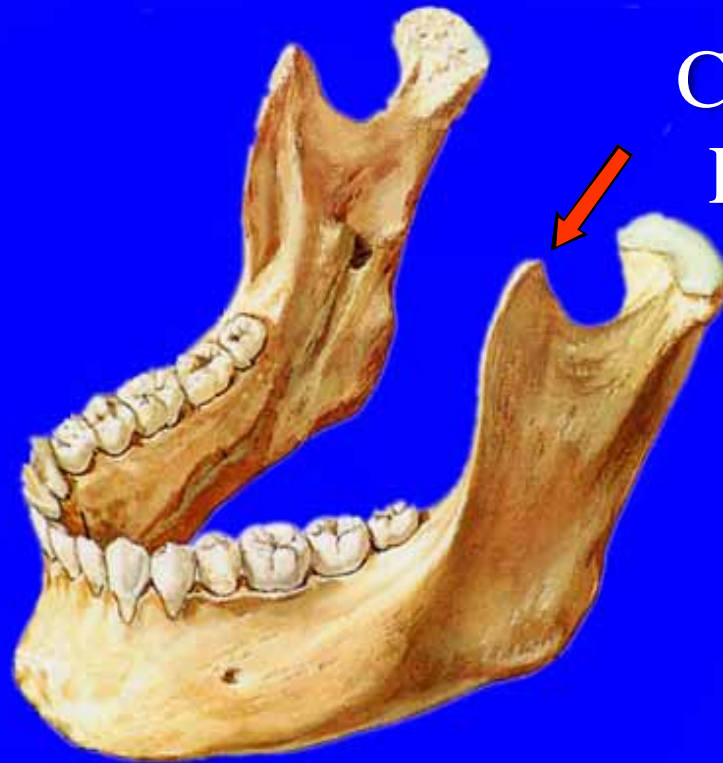Coronoid
Process



Menu

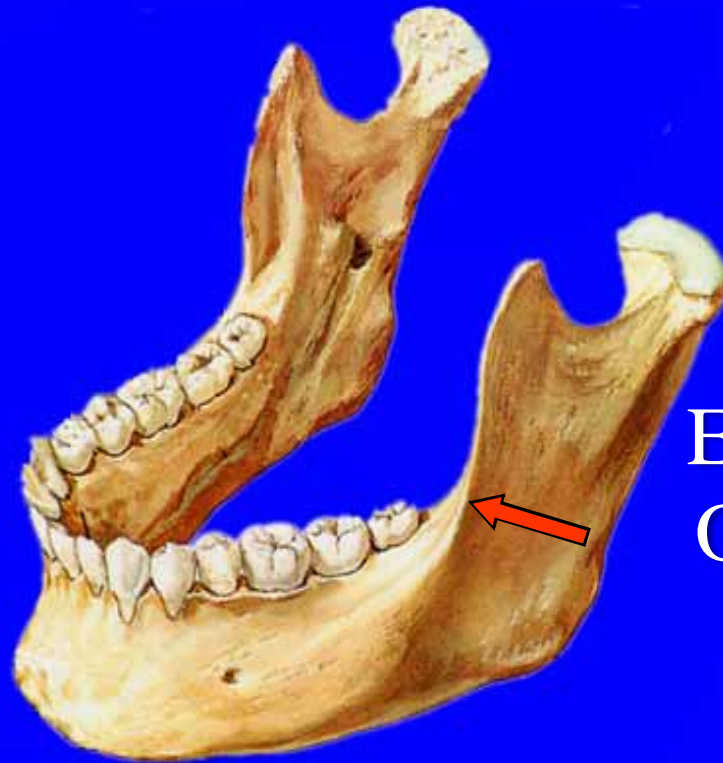

Coronoid
Process



Menu

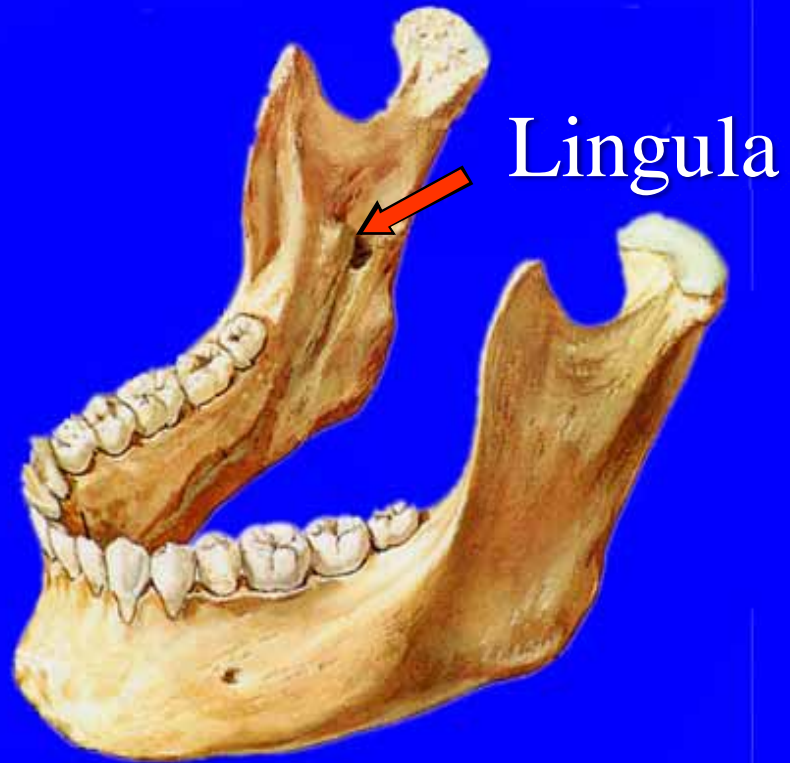




External
Oblique
Ridge

Menu

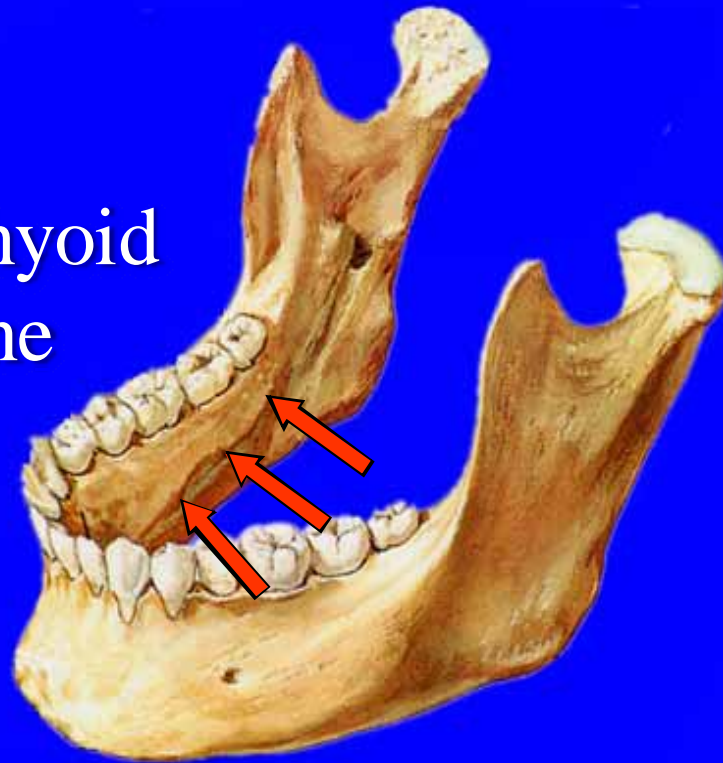




Menu



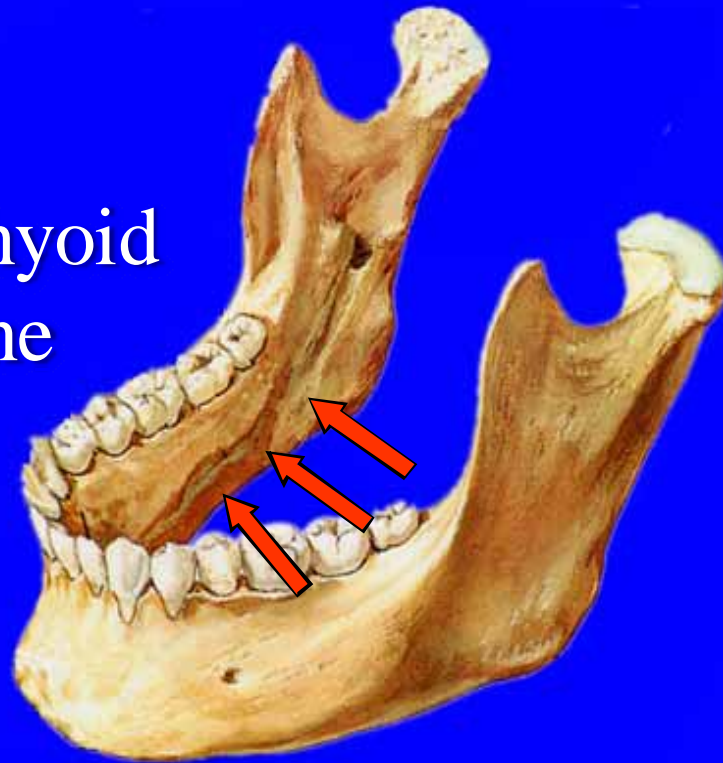
Mylohyoid Line



Menu



Mylohyoid Line



Menu



Symphyseal Anatomy

Menu

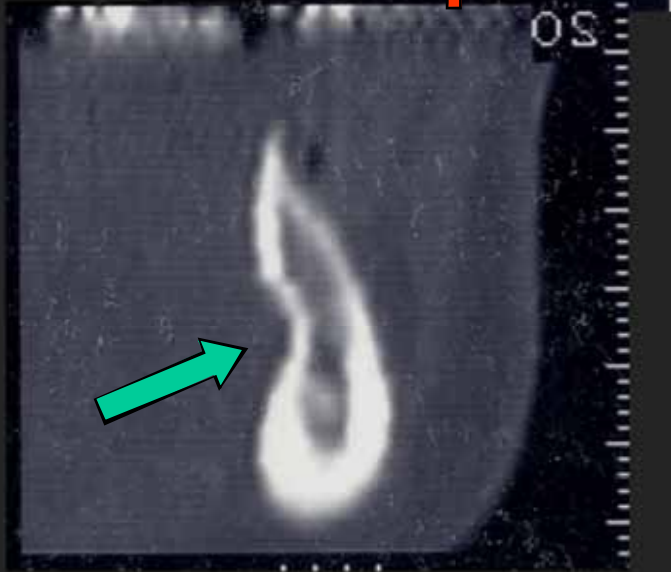
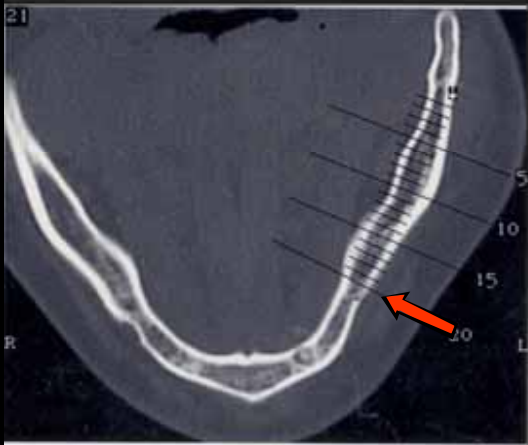
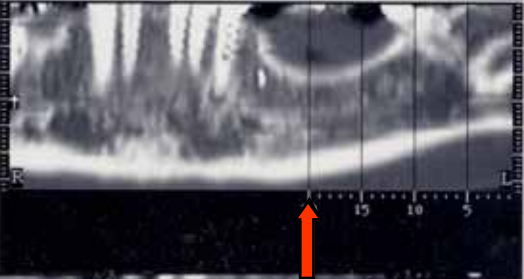


CT Scans of the Mandible

Menu



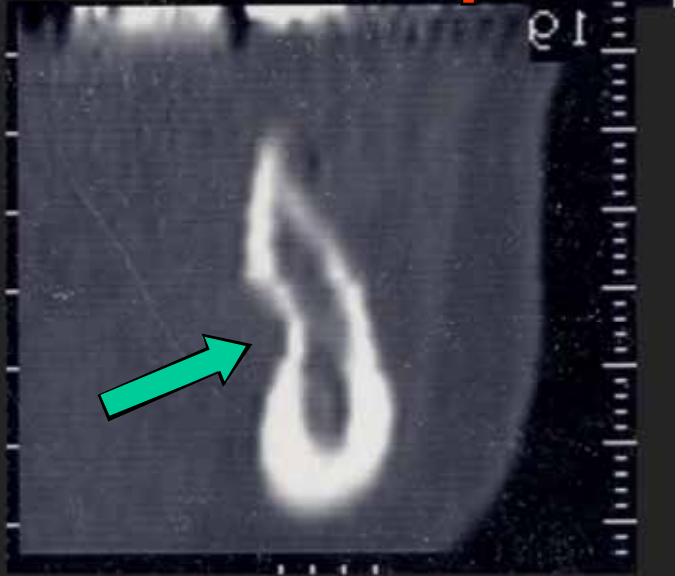
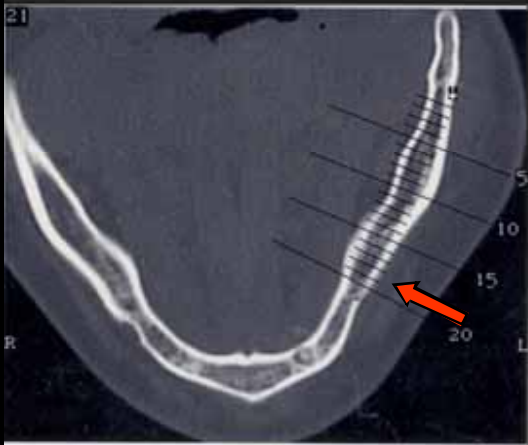
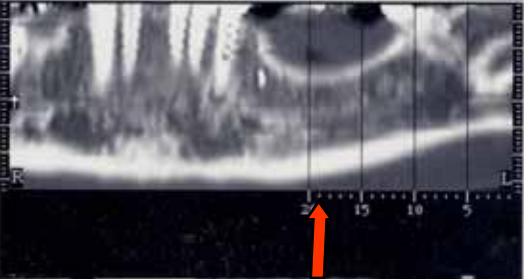
Mylohyoid Fossa



Menu



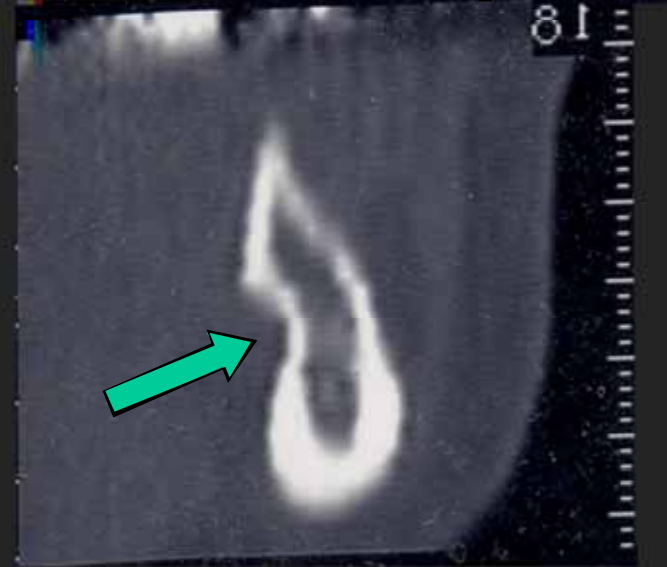
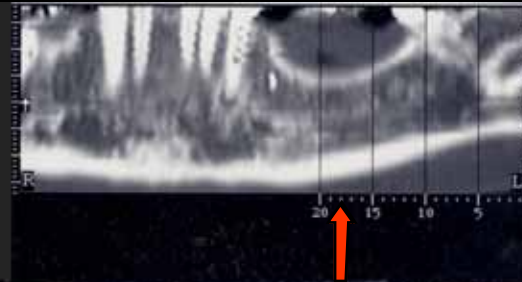
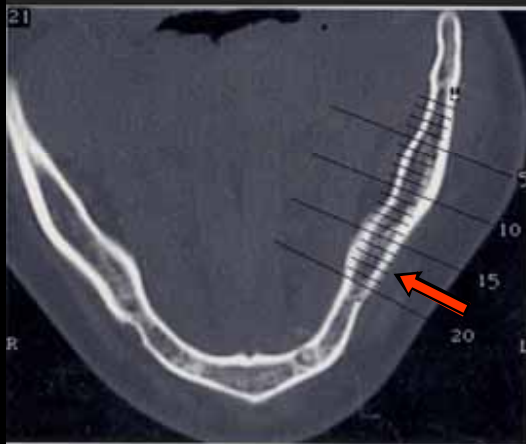
Mylohyoid Fossa



Menu



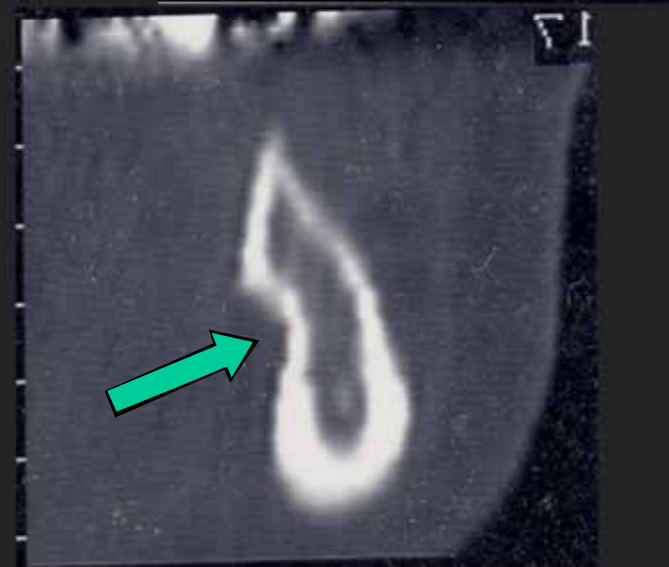
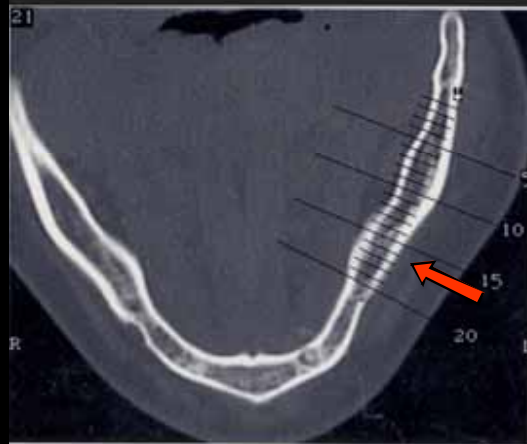
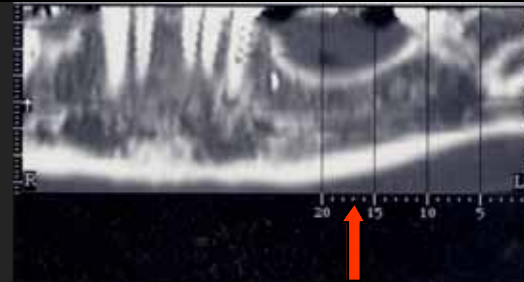
Mylohyoid Fossa



Menu



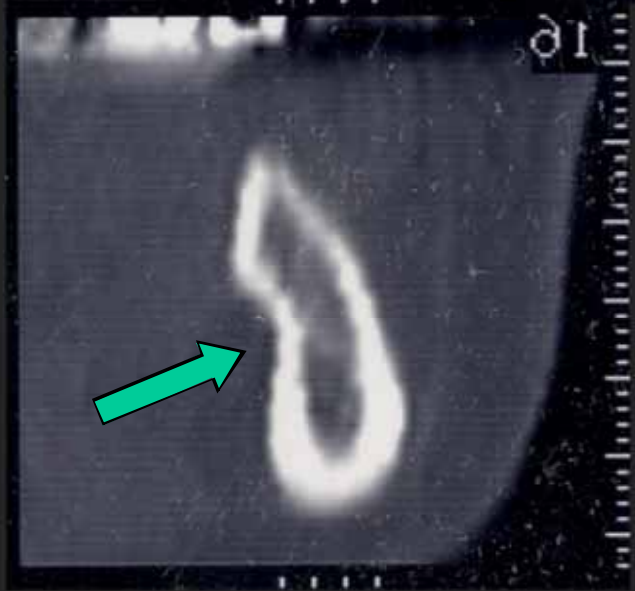
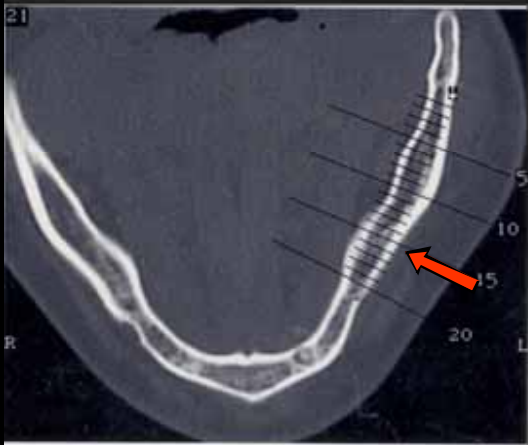
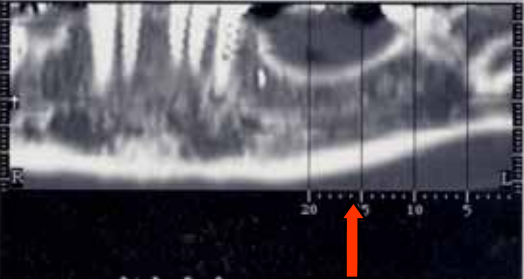
Mylohyoid Fossa



Menu



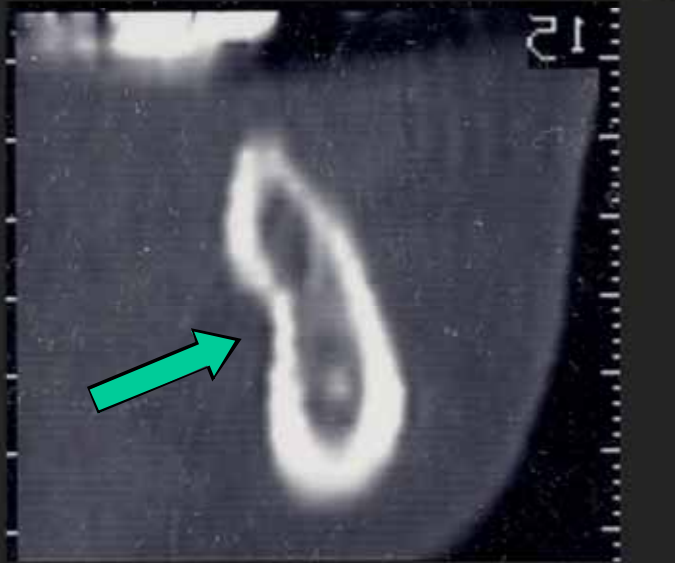
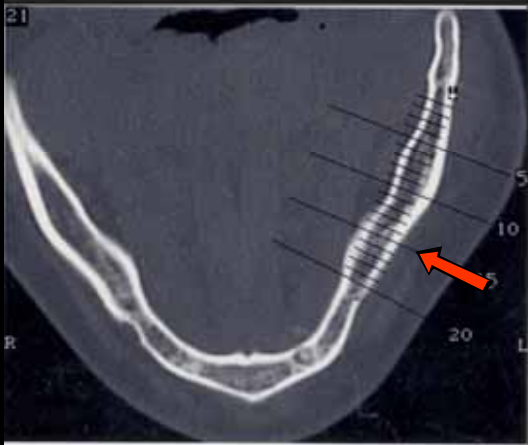
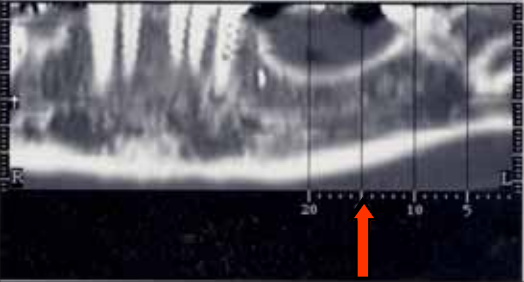Mylohyoid Fossa



Menu



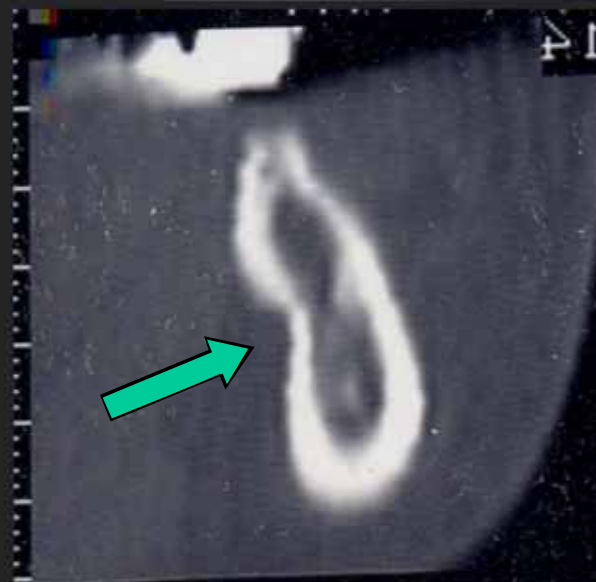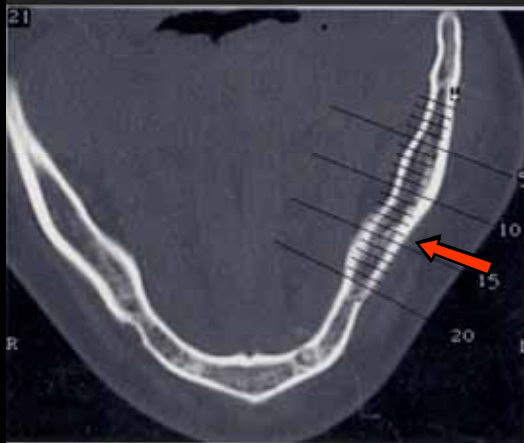
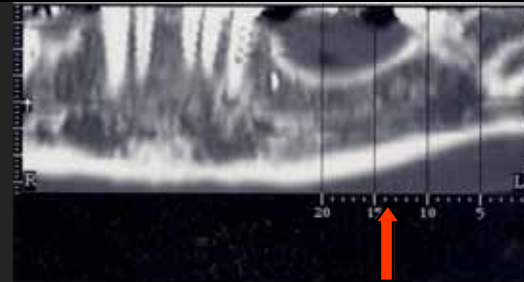
Mylohyoid Fossa



Menu



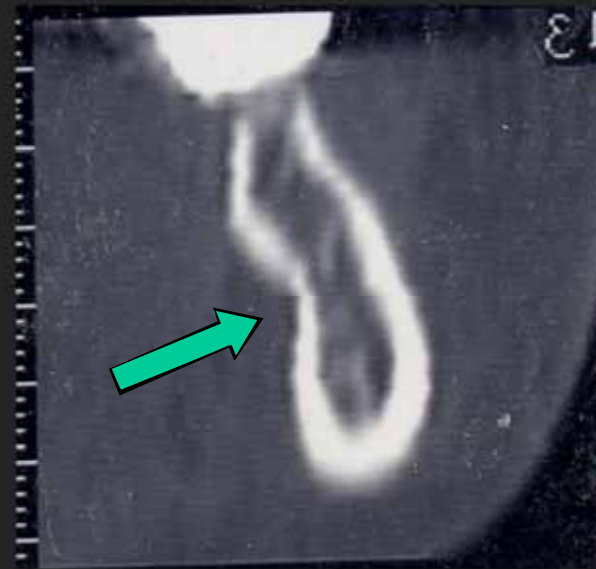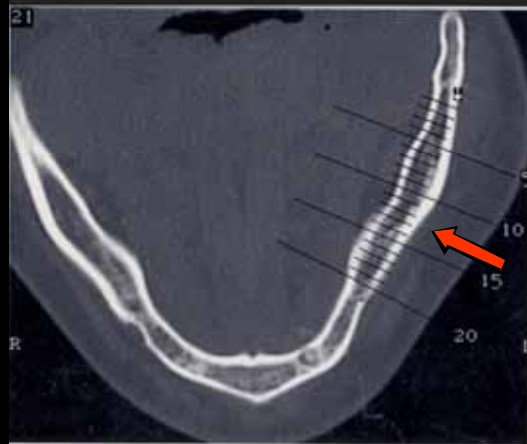
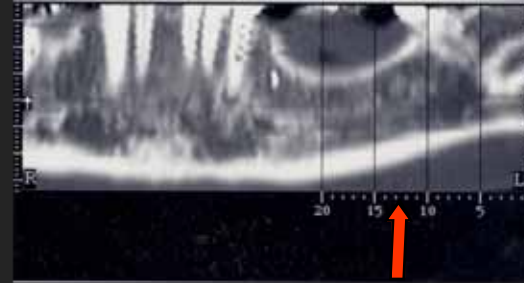
Mylohyoid Fossa



Menu



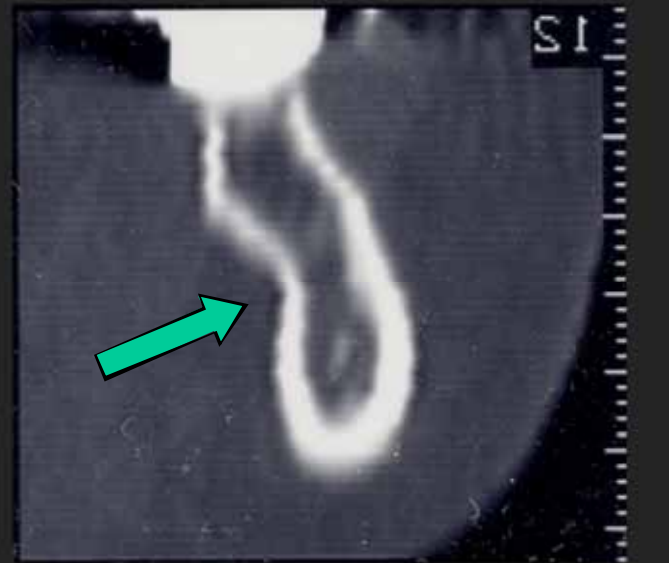
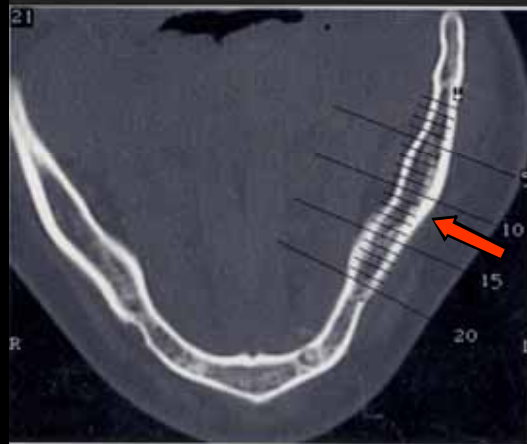
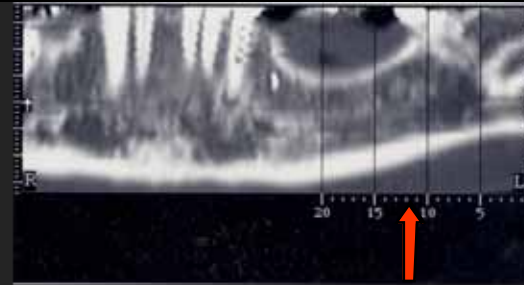
Mylohyoid Fossa



Menu



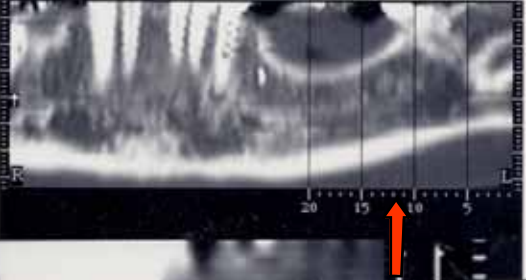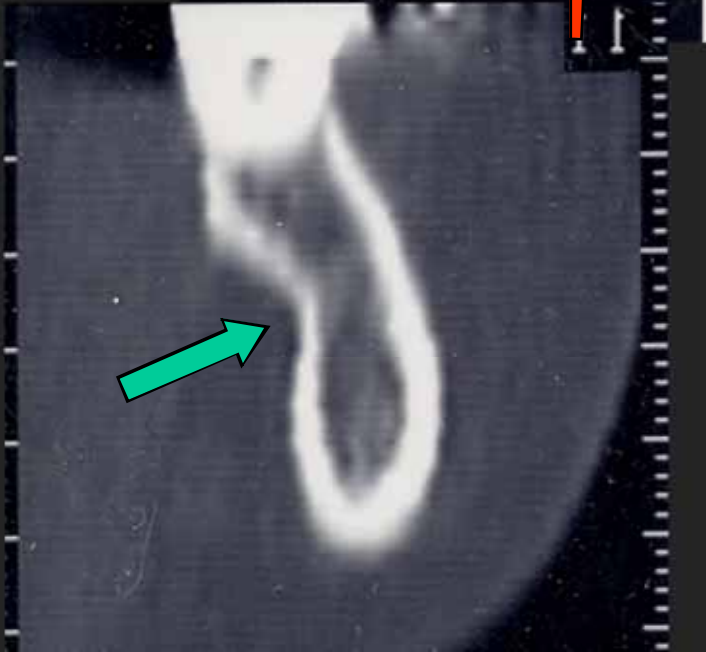
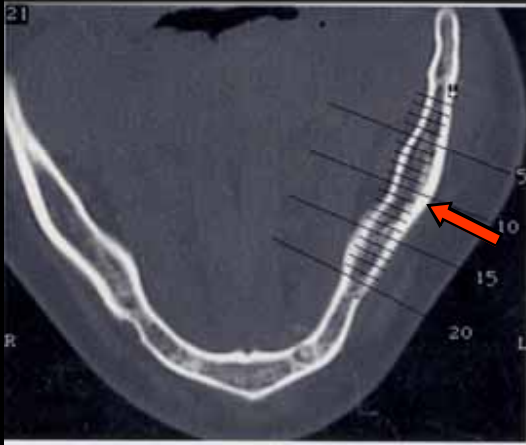
Mylohyoid Fossa



Menu



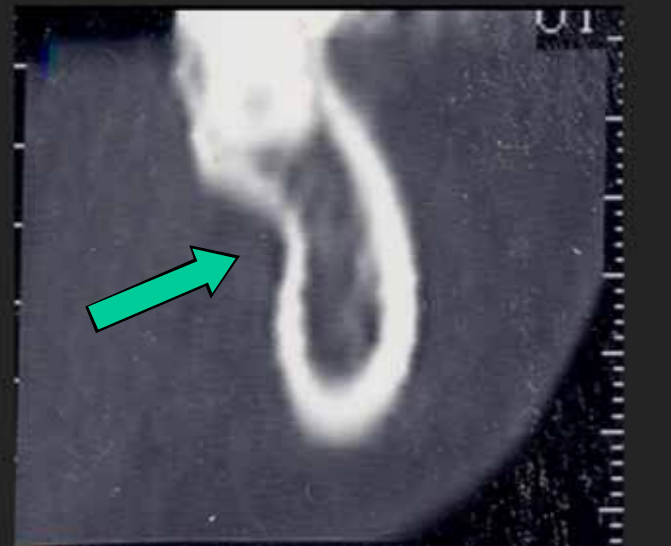
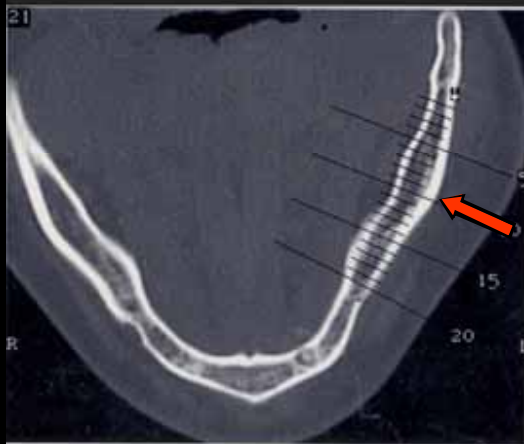
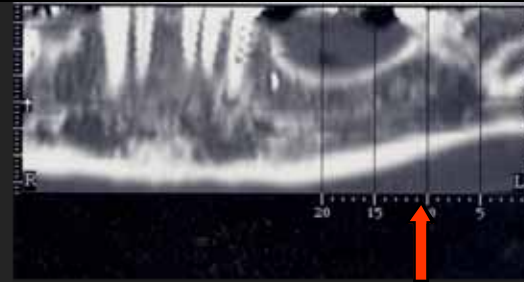
Mylohyoid Fossa



Menu



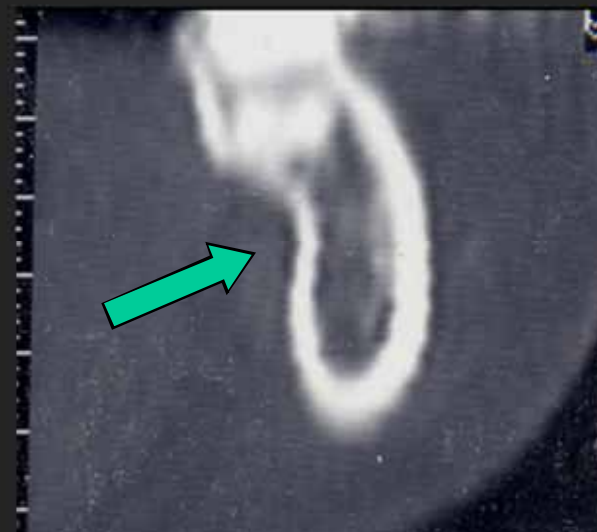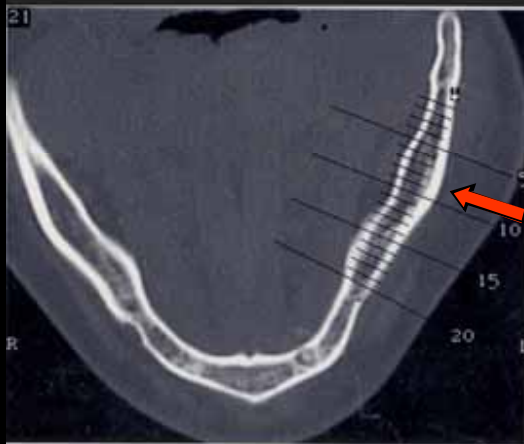
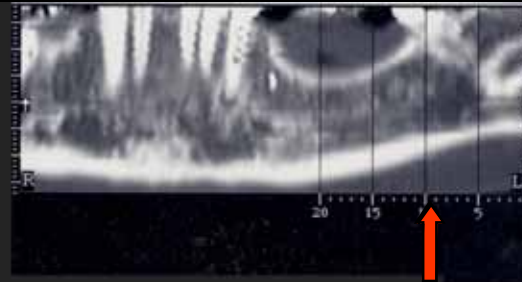
Mylohyoid Fossa



Menu



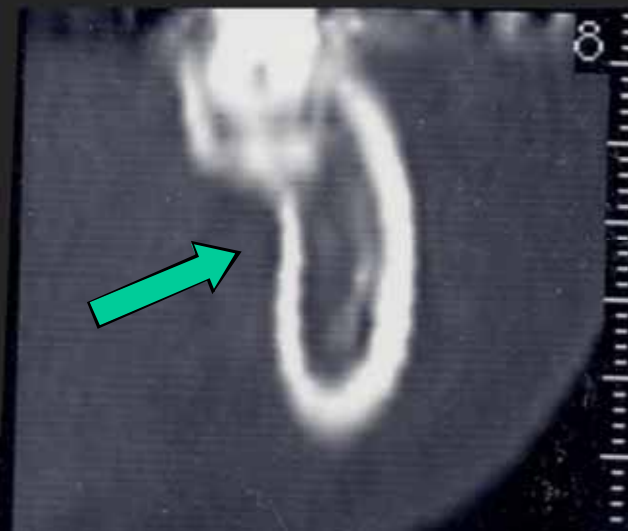
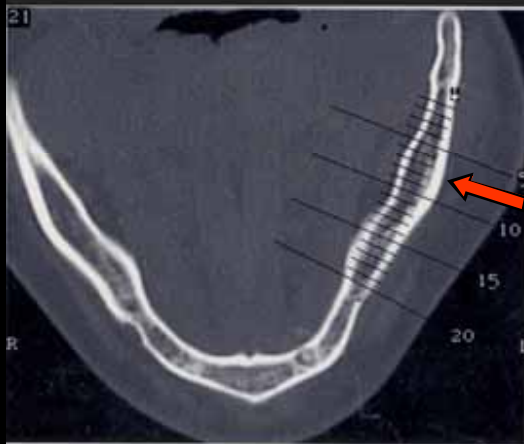
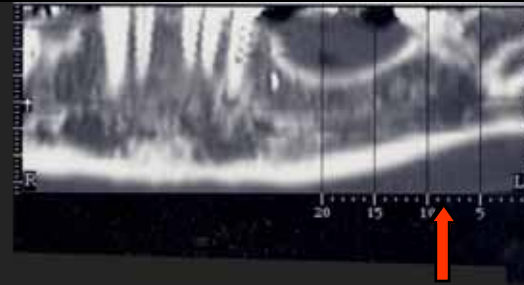
Mylohyoid Fossa



Menu



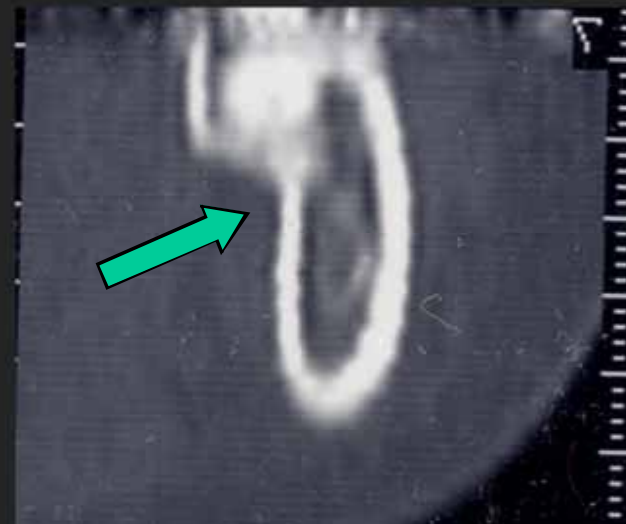
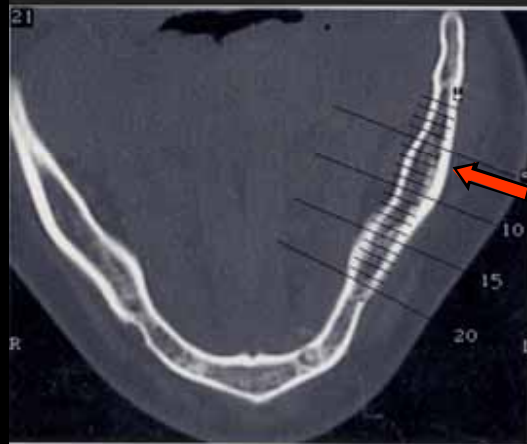
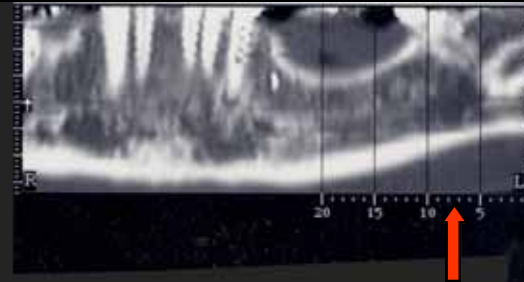
Mylohyoid Fossa



Menu



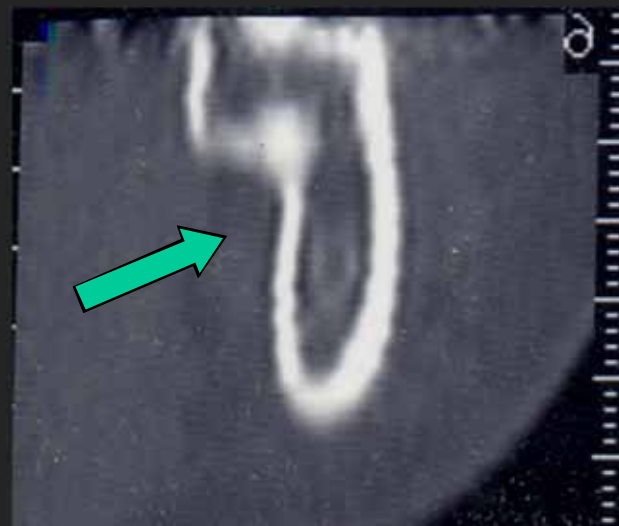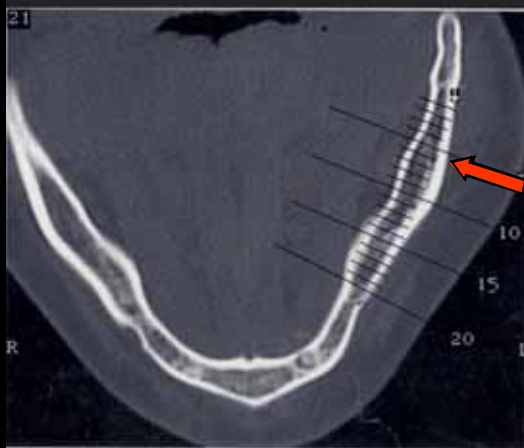
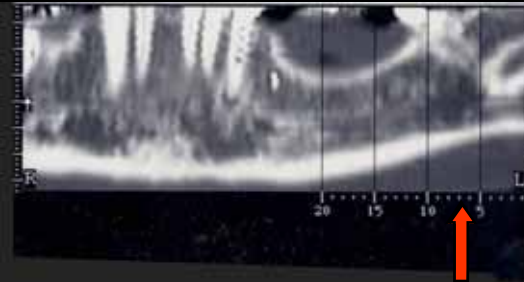
Mylohyoid Fossa



Menu




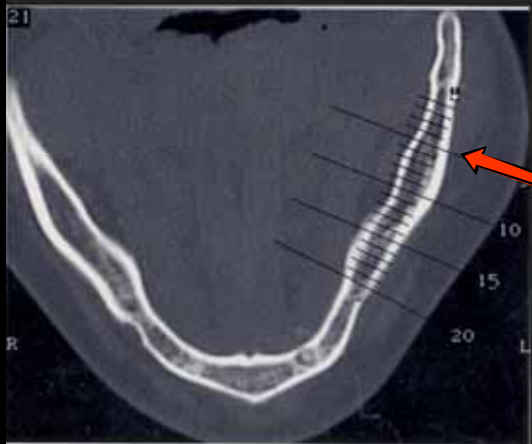
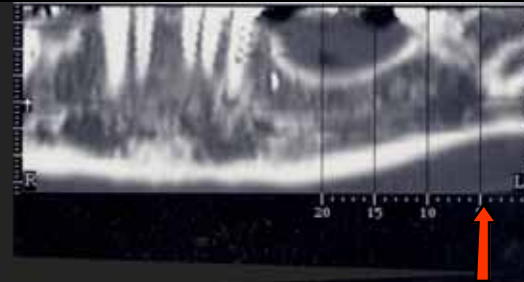
Mylohyoid Fossa



Menu



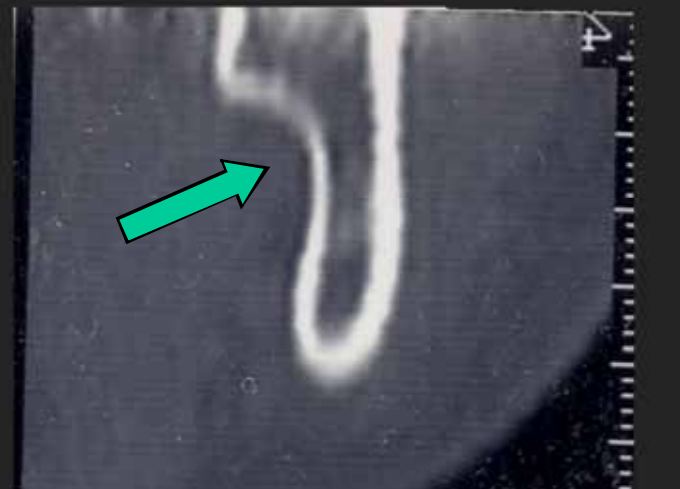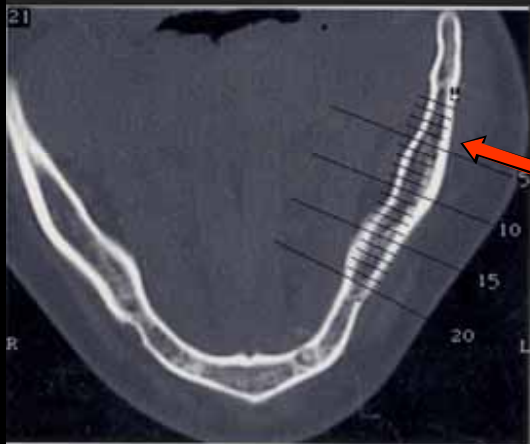
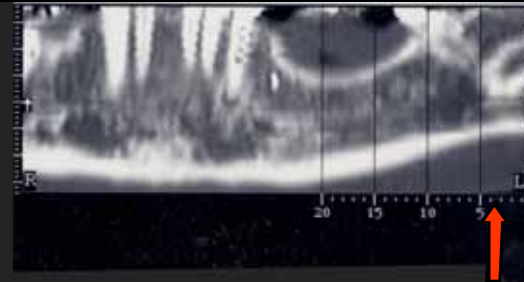
Mylohyoid Fossa



Menu



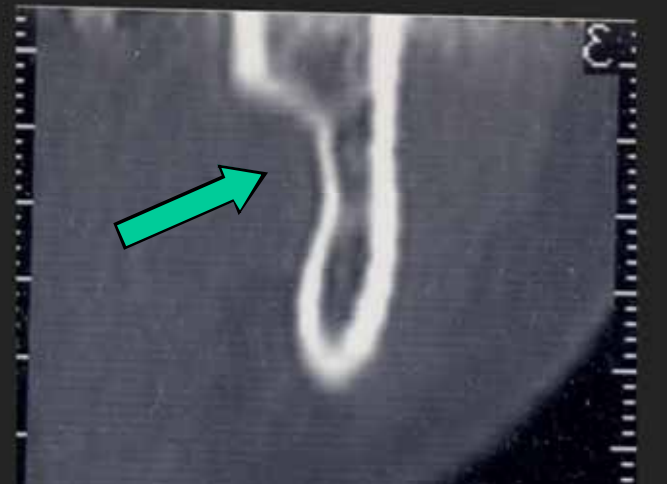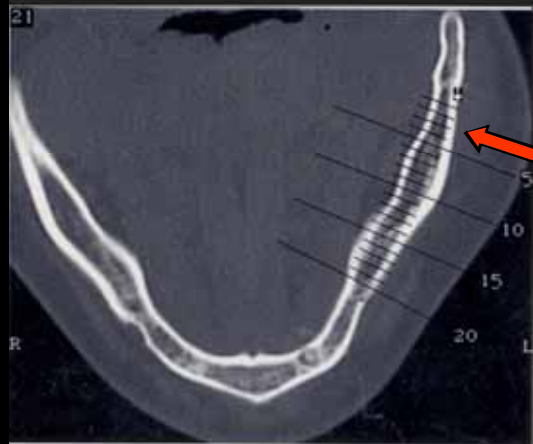
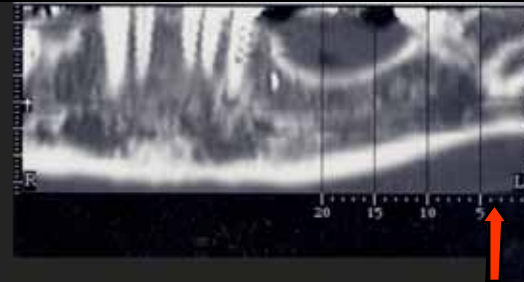
Mylohyoid Fossa



Menu



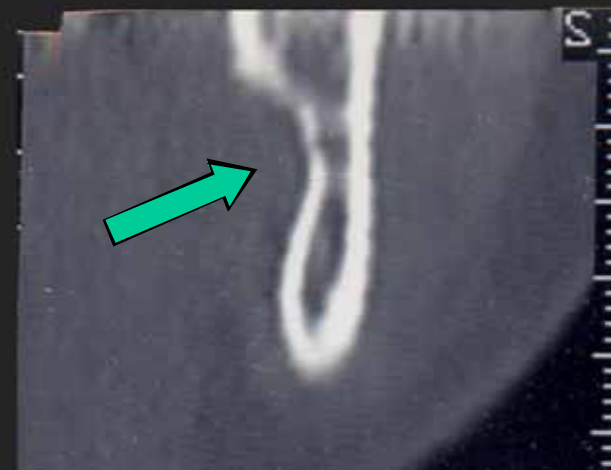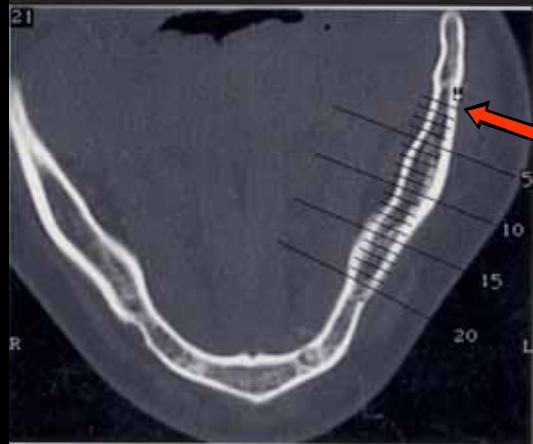
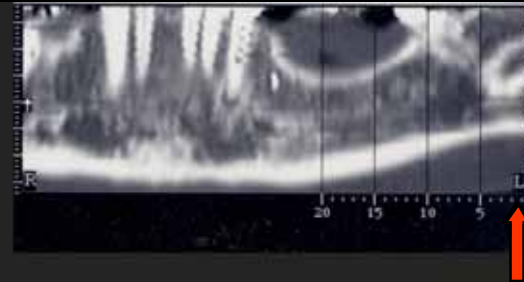
Mylohyoid Fossa



Menu



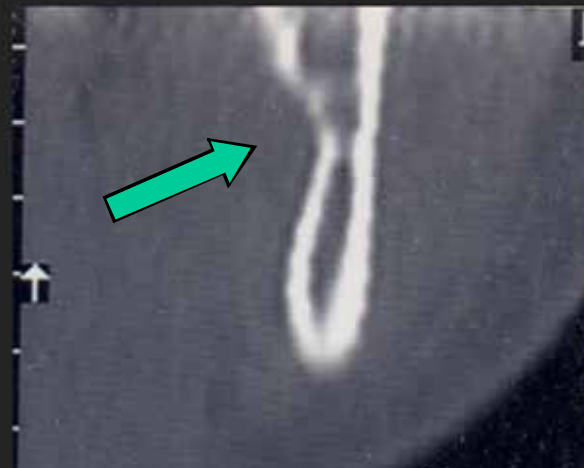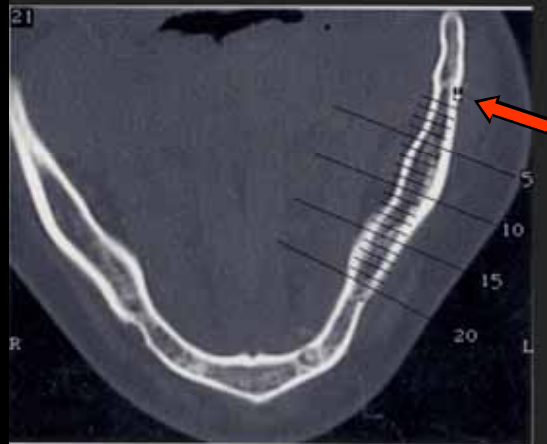
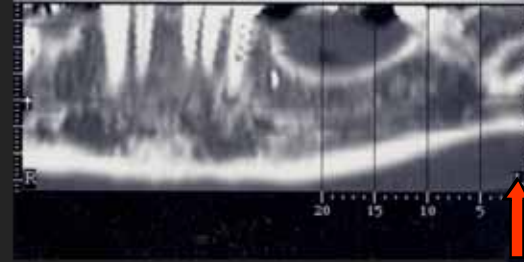
Mylohyoid Fossa



Menu



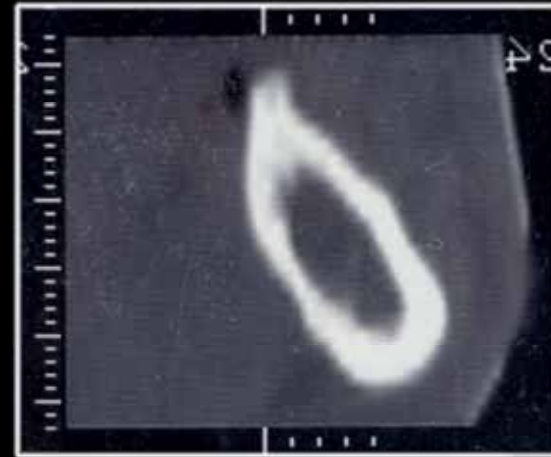
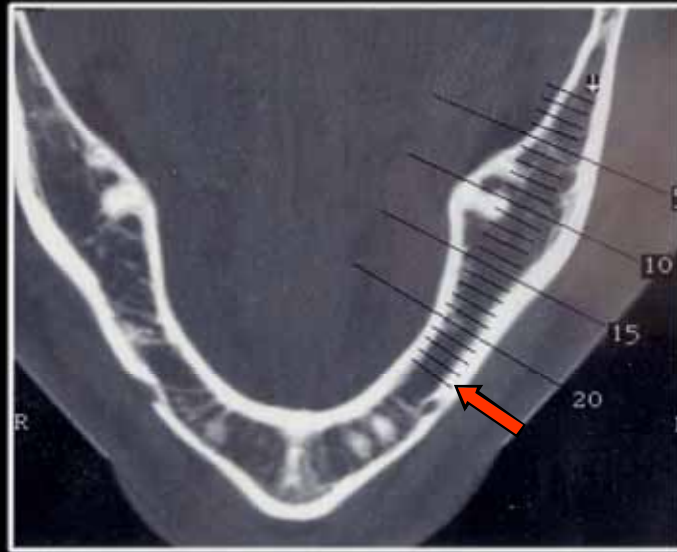

Mylohyoid Fossa



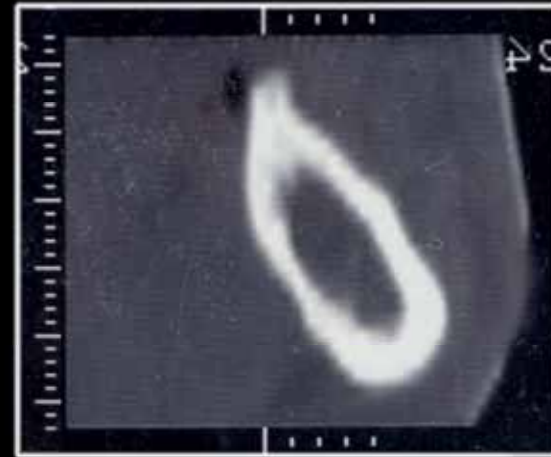
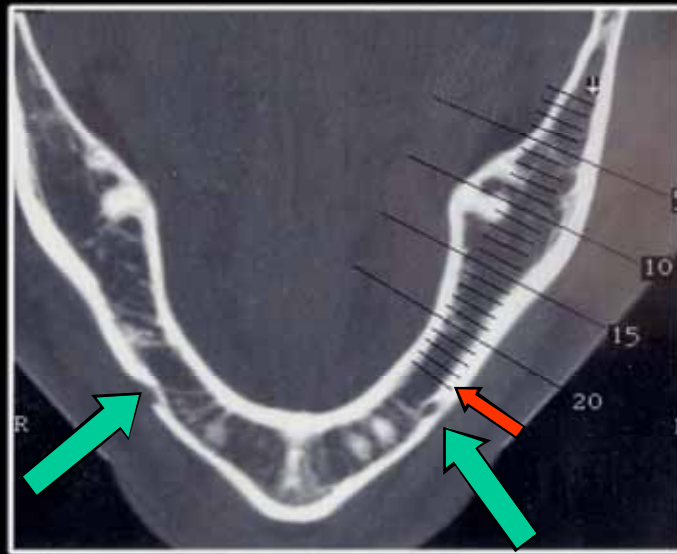

Menu



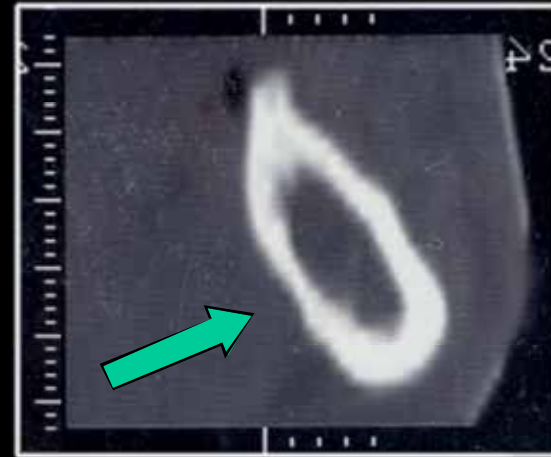
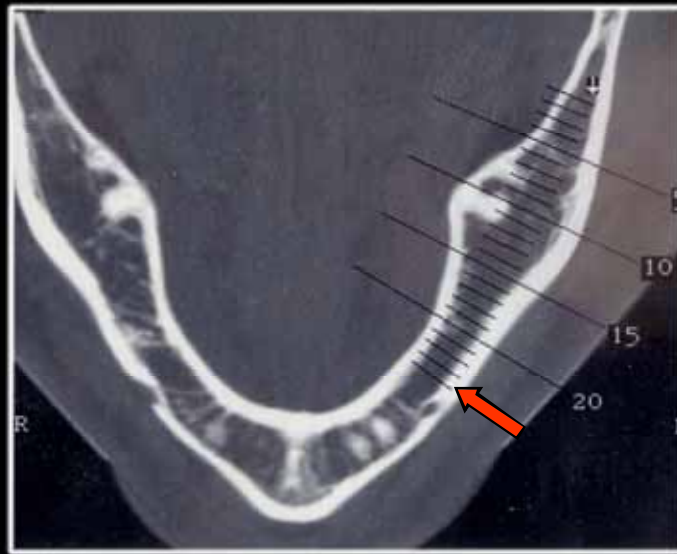

Another Example



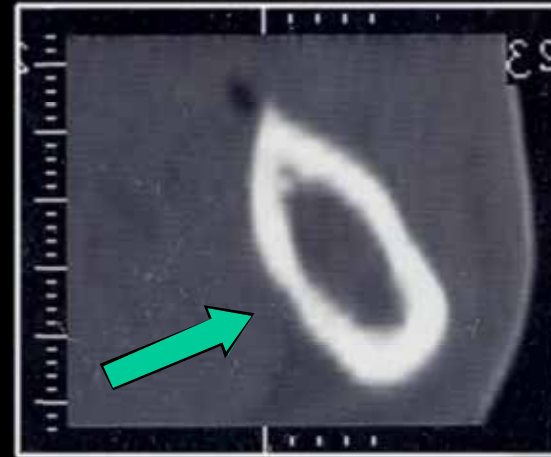
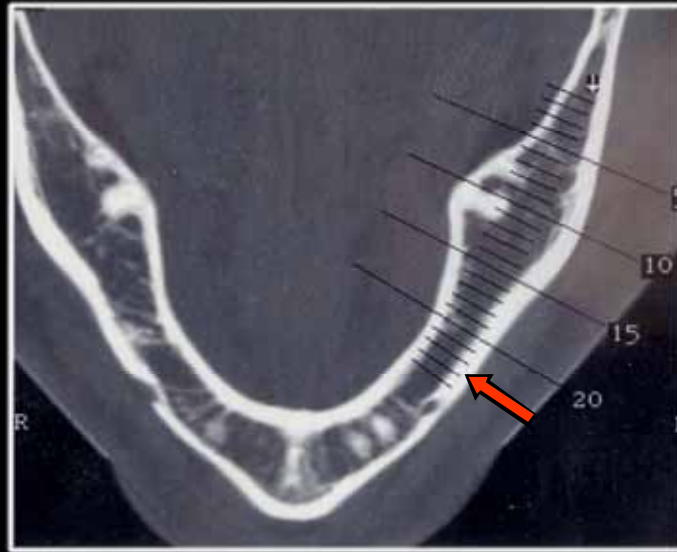

Mental Foramina



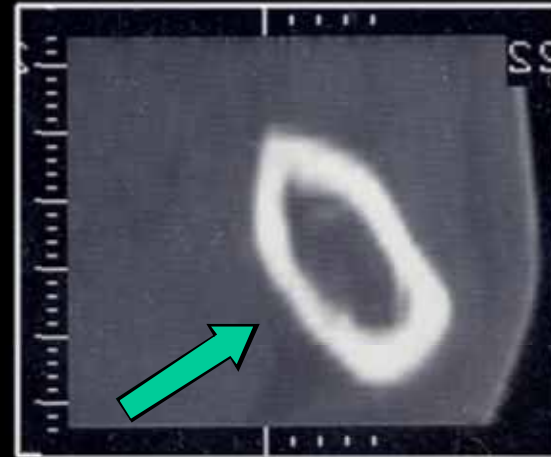
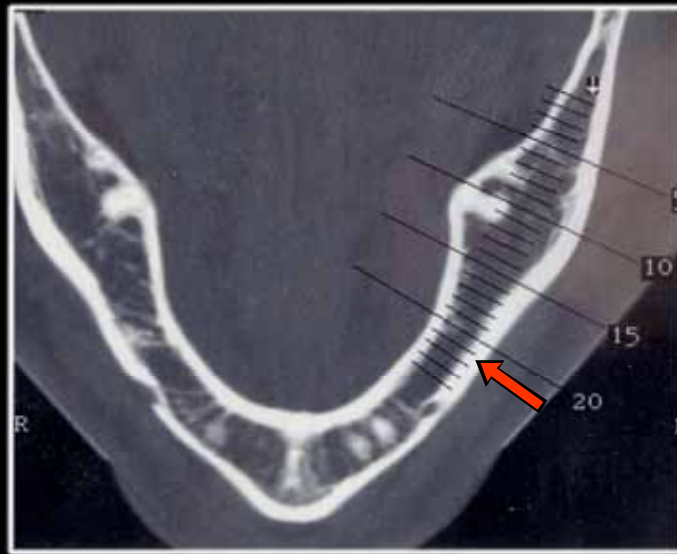
Mylohyoid Fossa



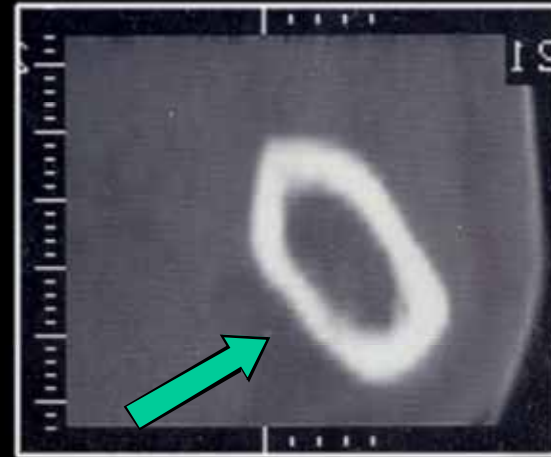
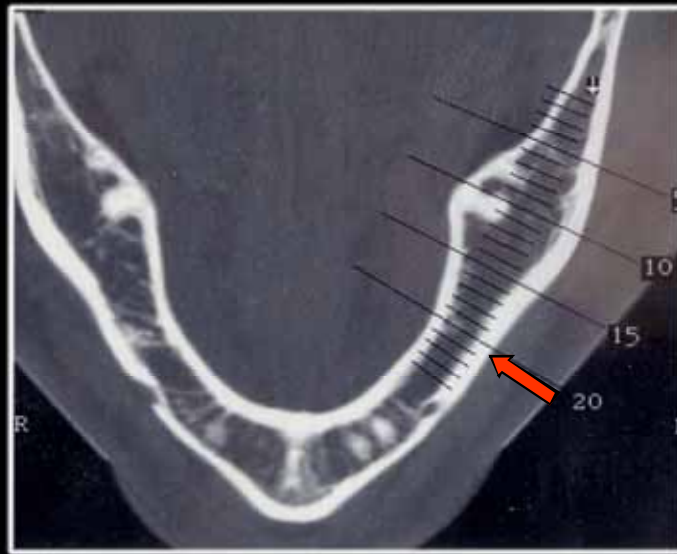
Mylohyoid Fossa



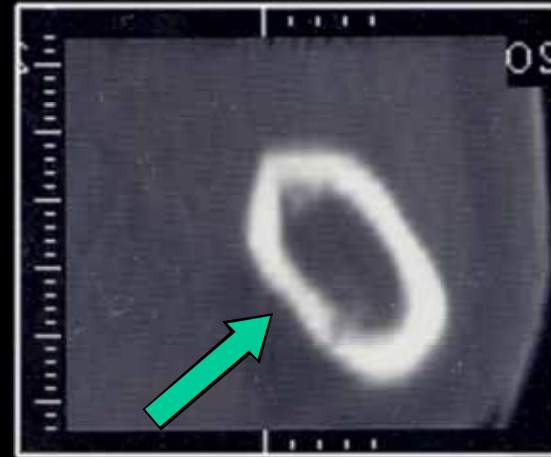
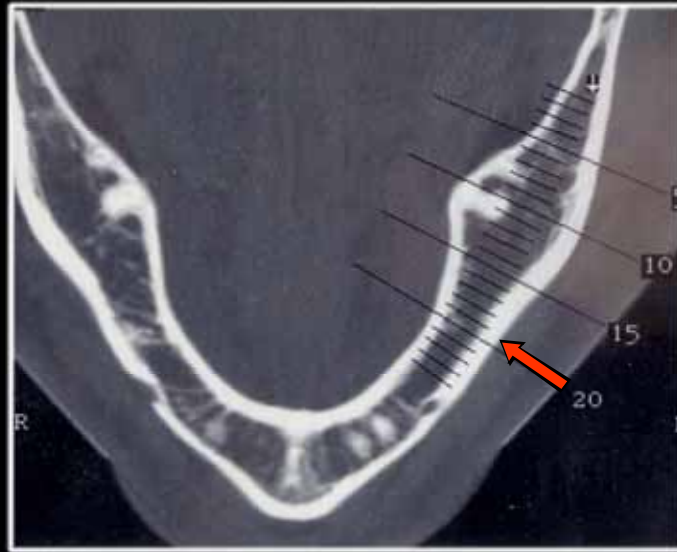

Mylohyoid Fossa



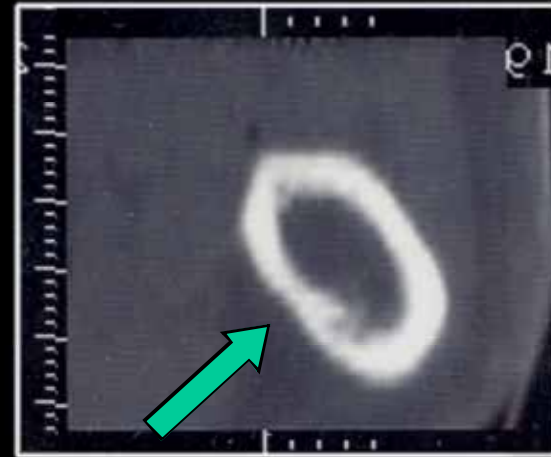
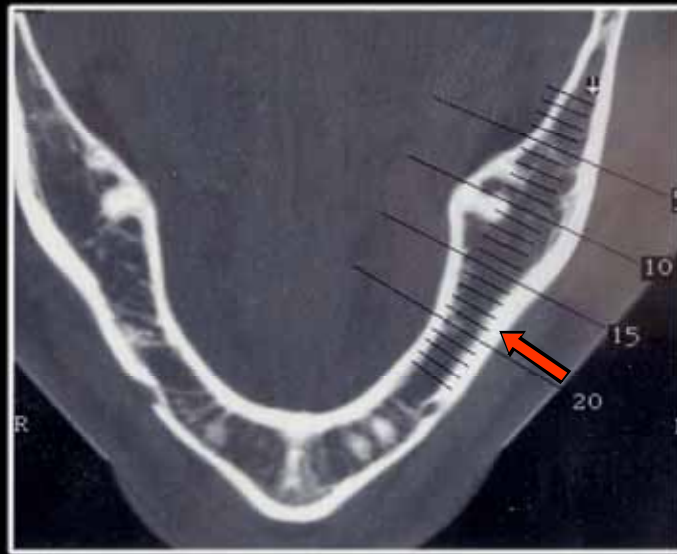

Mylohyoid Fossa



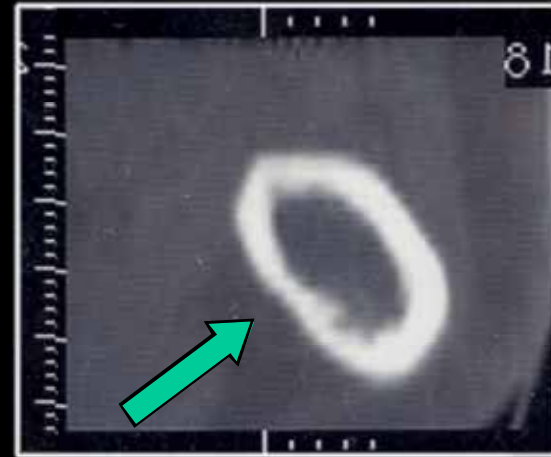
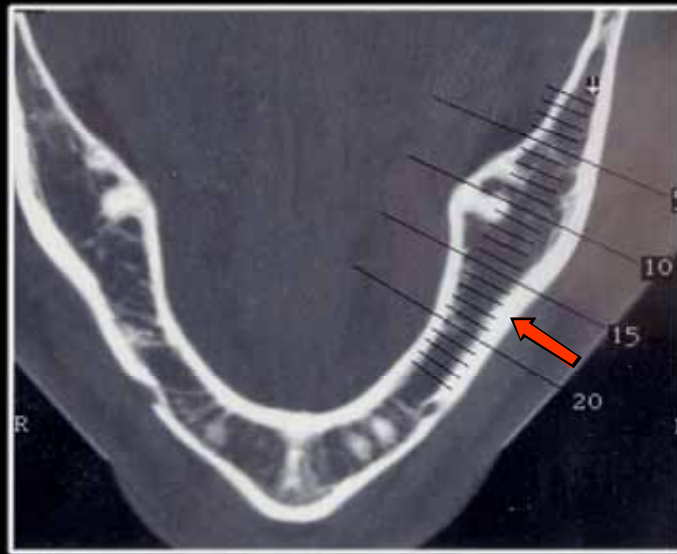

Mylohyoid Fossa



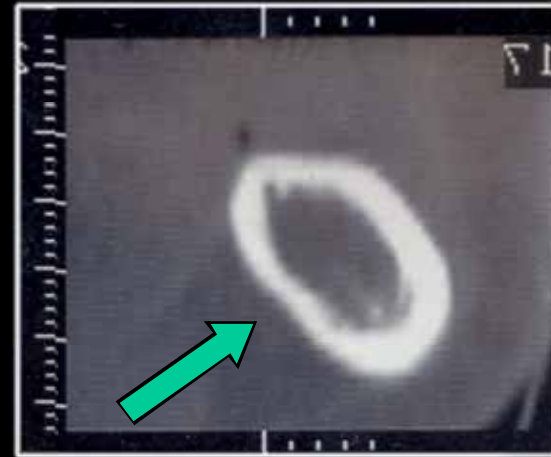
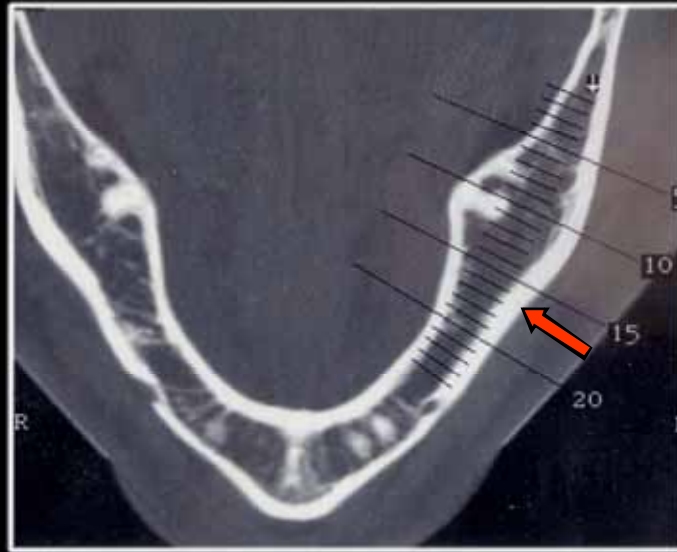

Mylohyoid Fossa



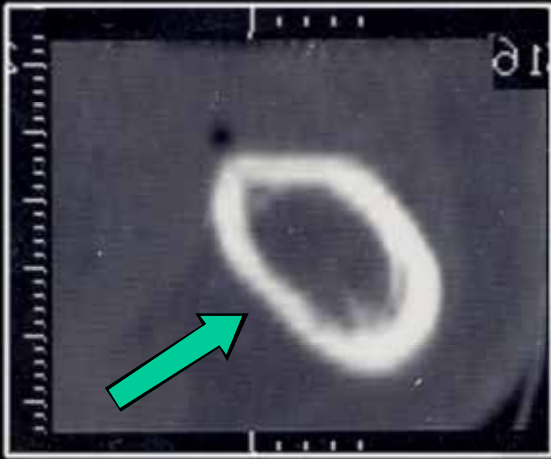
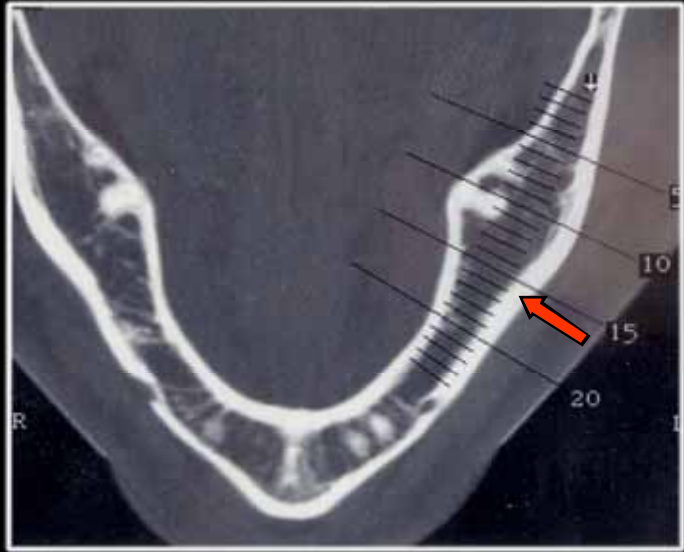

Mylohyoid Fossa



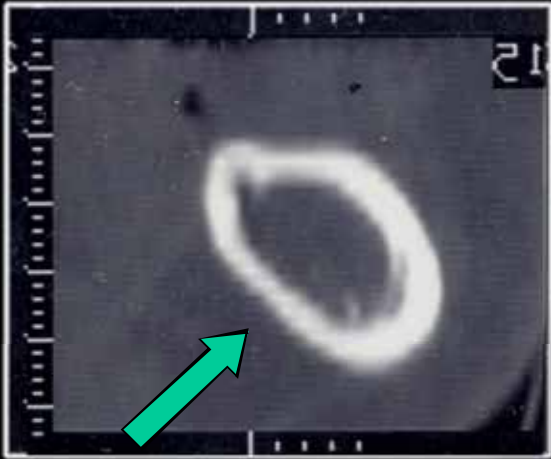
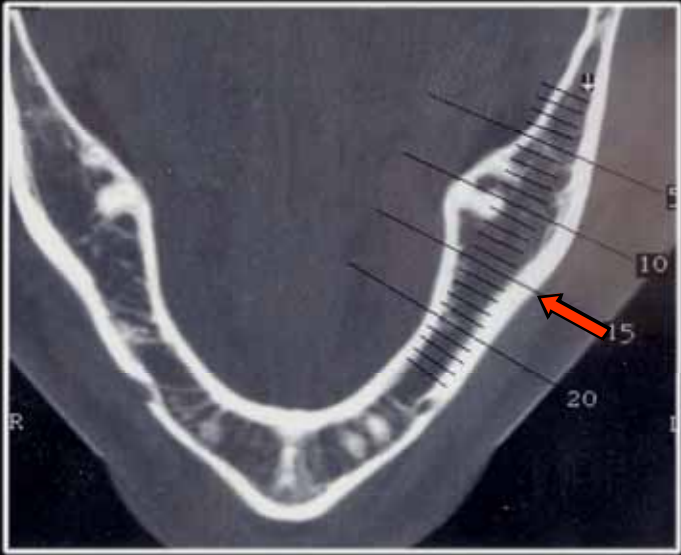

Mylohyoid Fossa



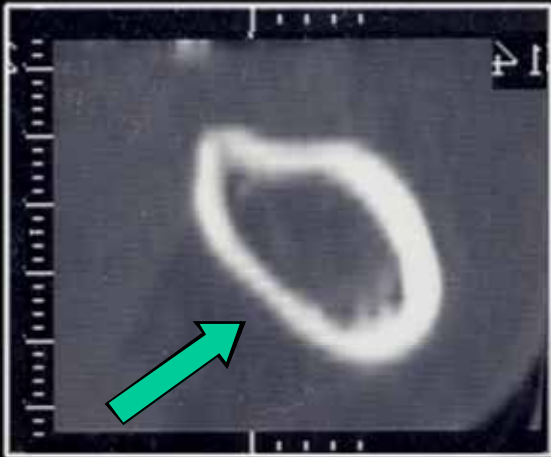
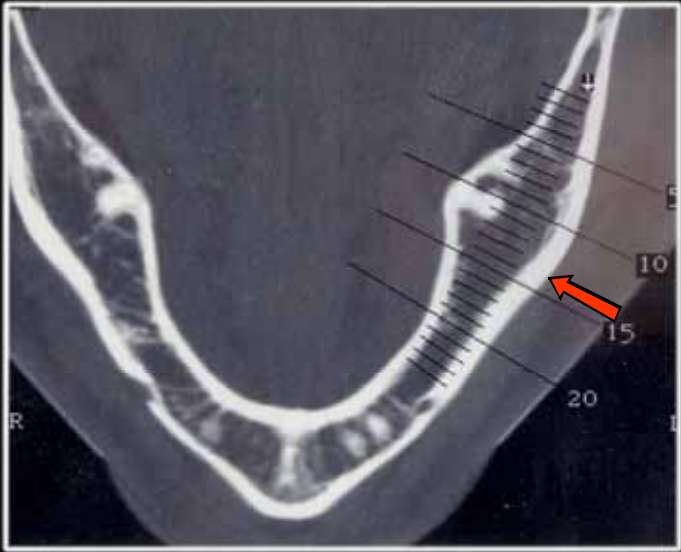

Mylohyoid Fossa



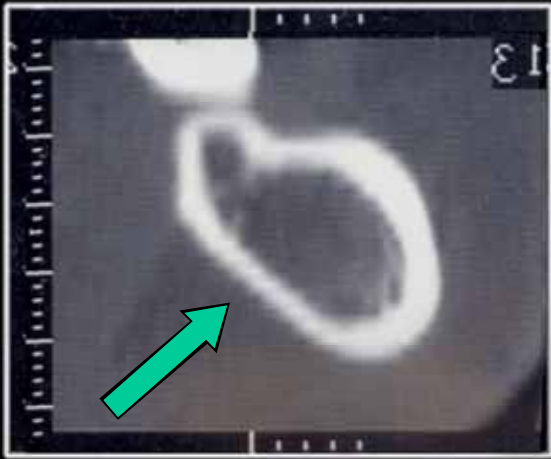
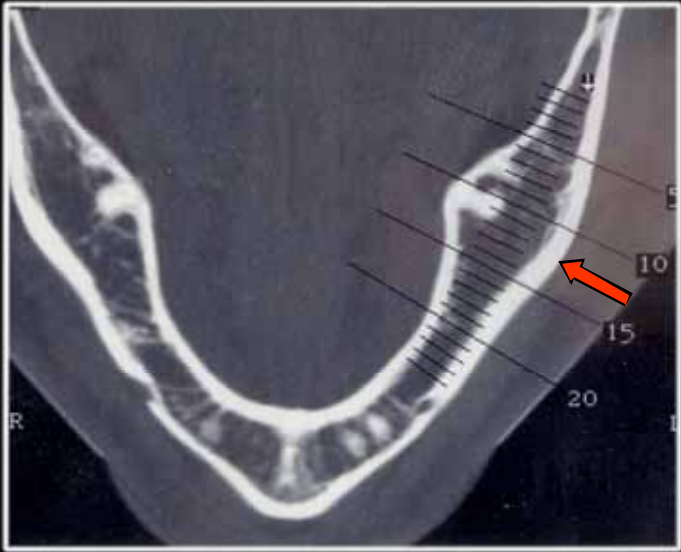

Mylohyoid Fossa



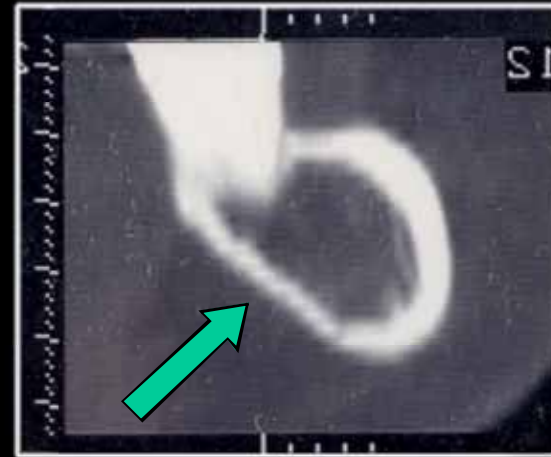
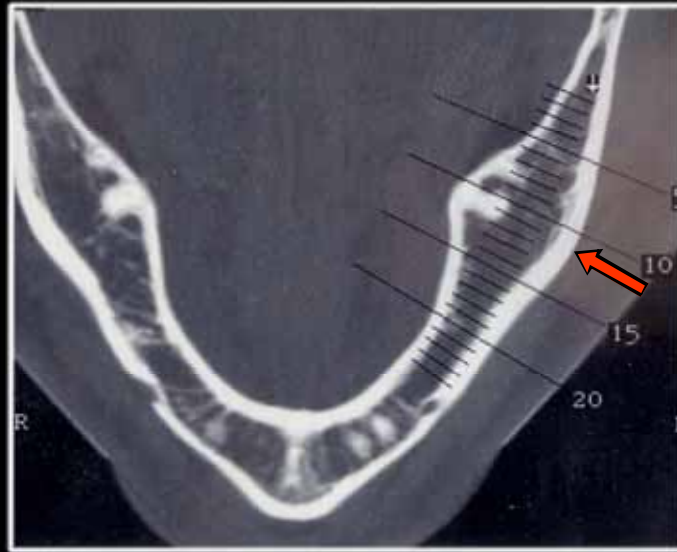

Mylohyoid Fossa



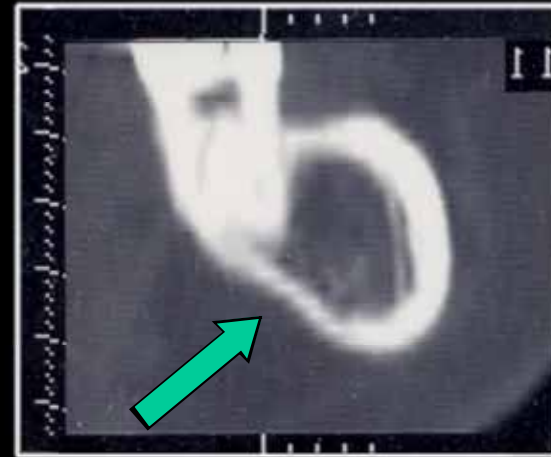
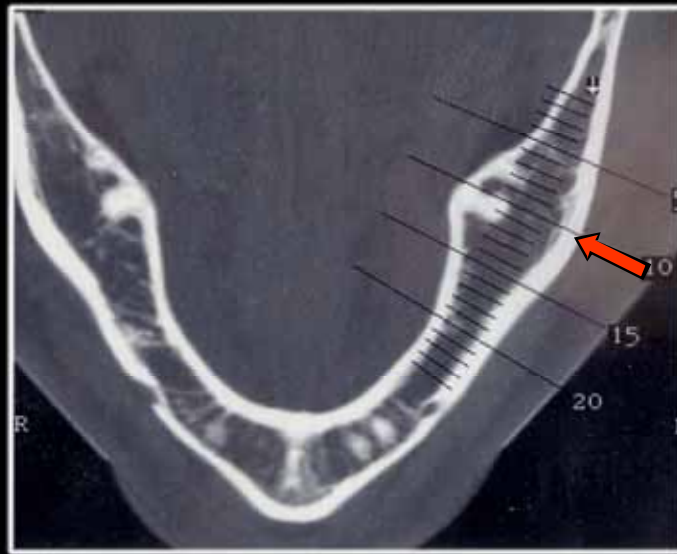

Mylohyoid Fossa



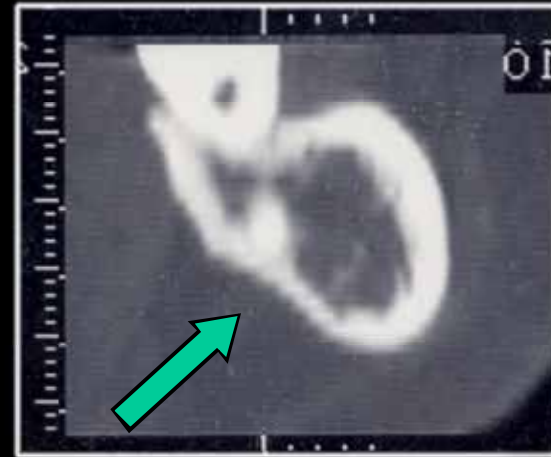
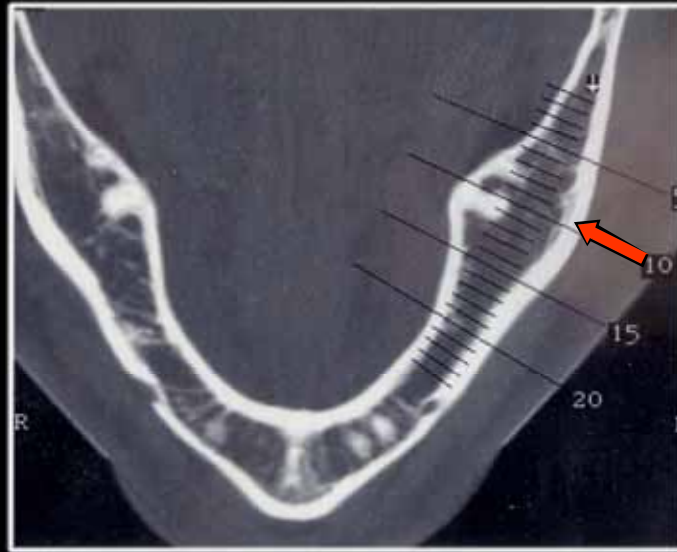

Mylohyoid Fossa



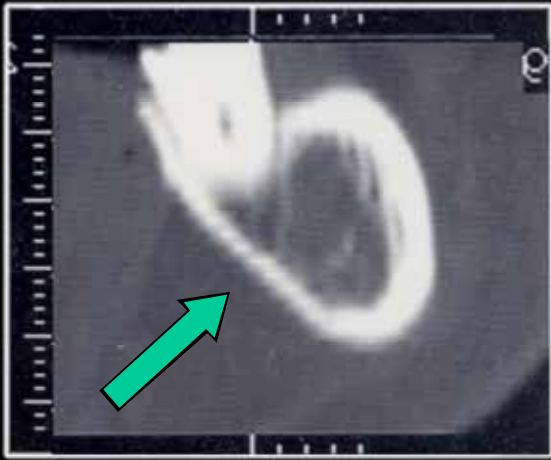
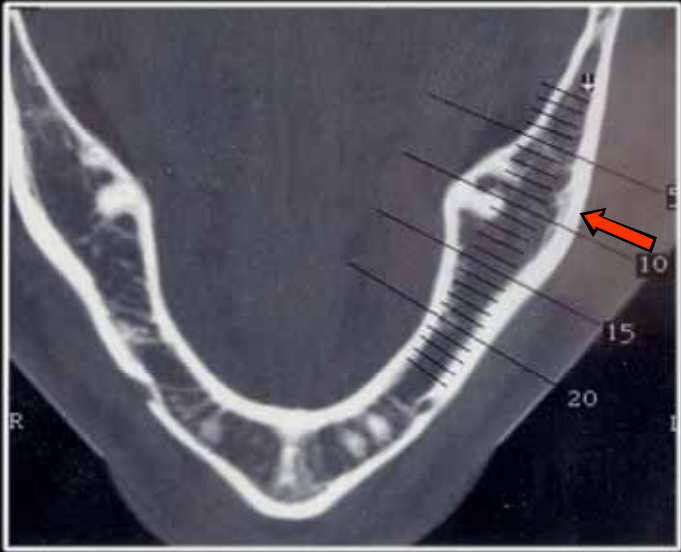
Mylohyoid Fossa



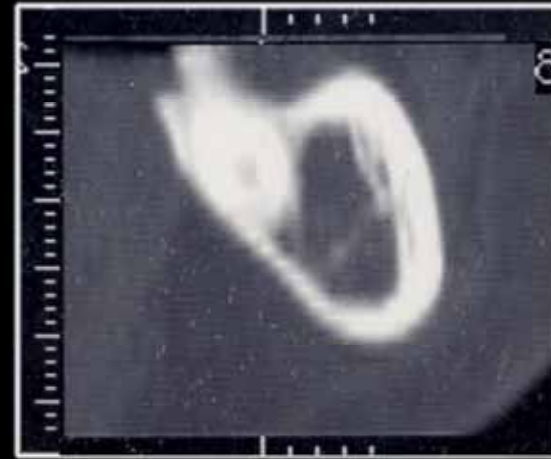
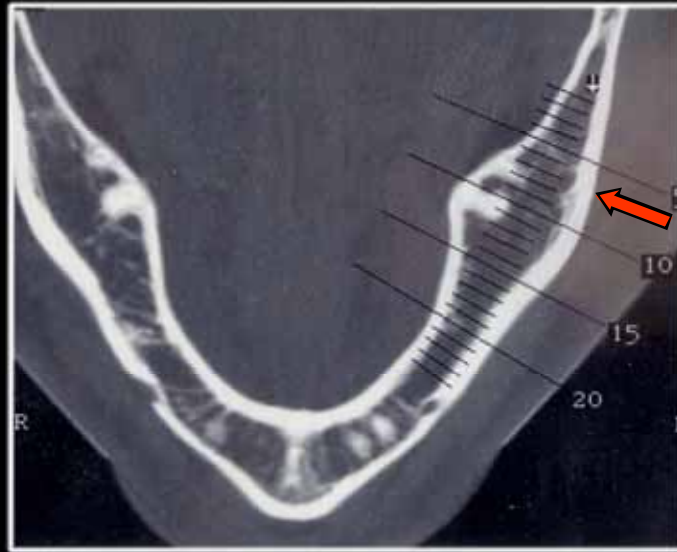

Mylohyoid Fossa



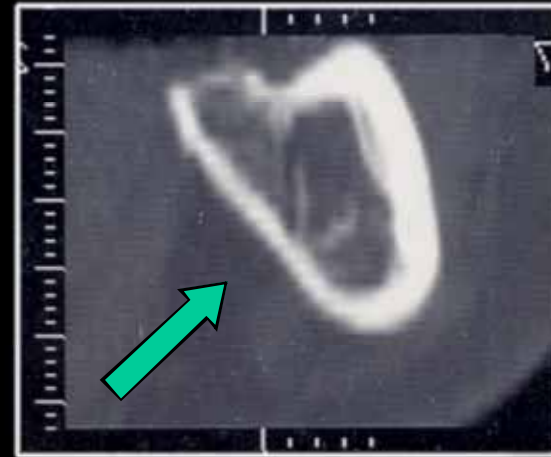
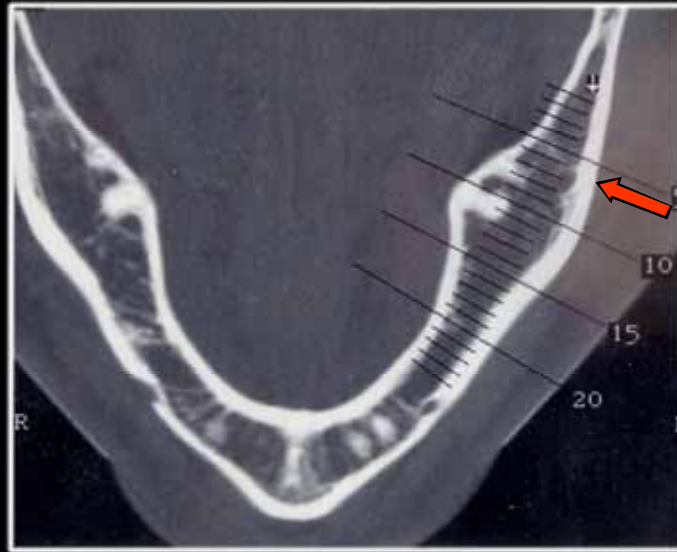

Mylohyoid Fossa



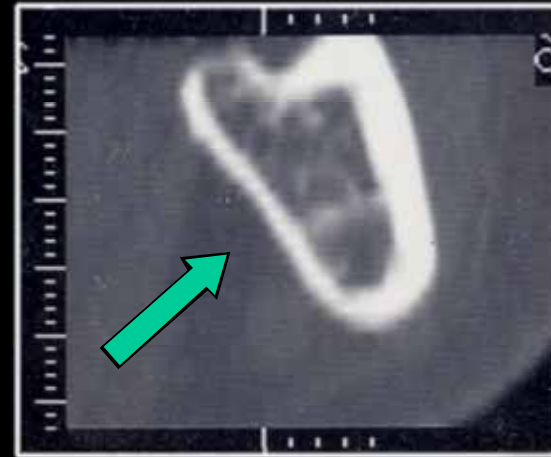
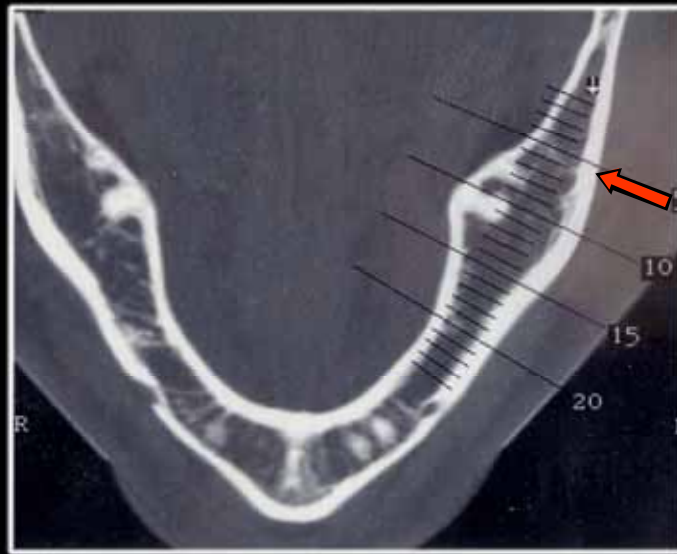

Mylohyoid Fossa



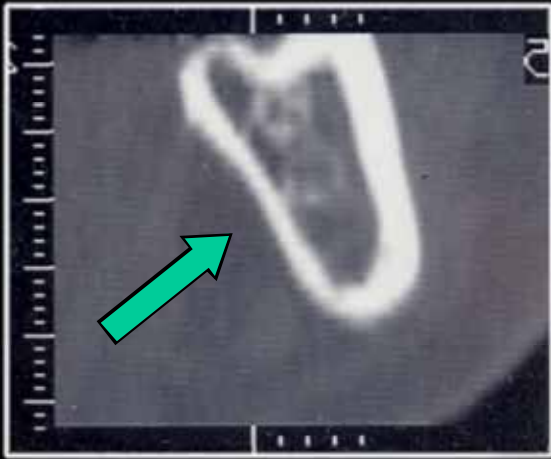
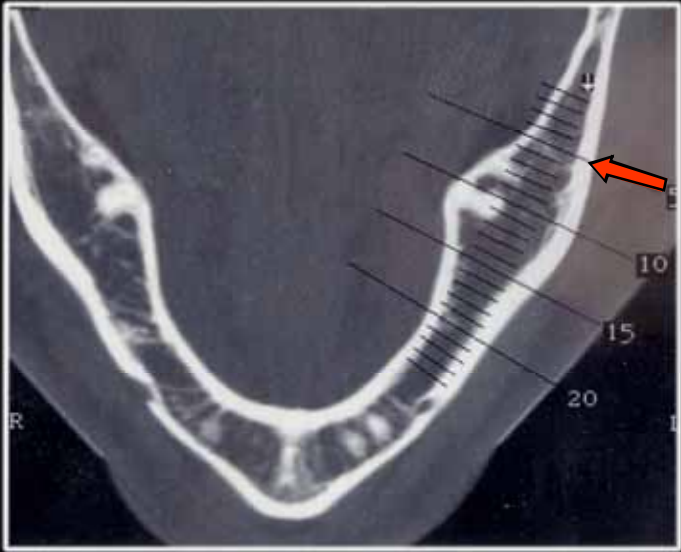
Mylohyoid Fossa



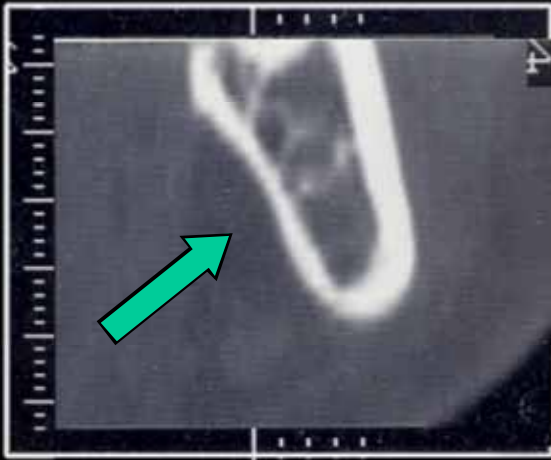
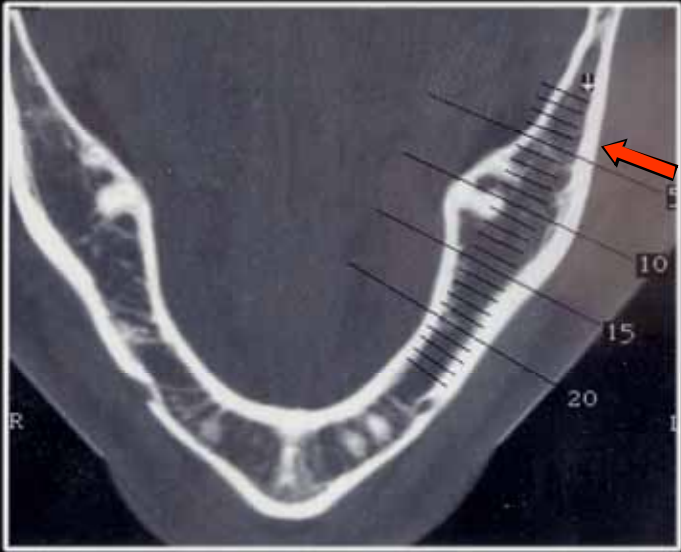

Mylohyoid Fossa



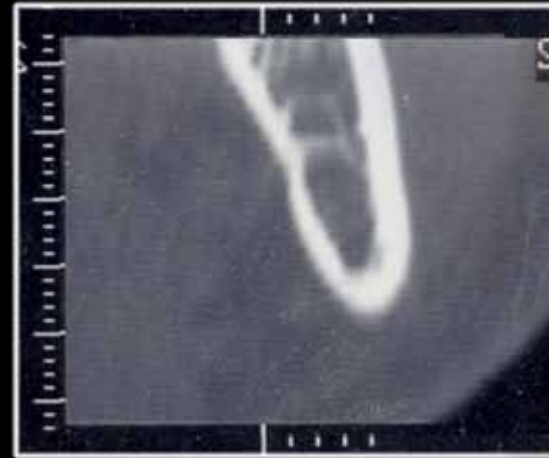
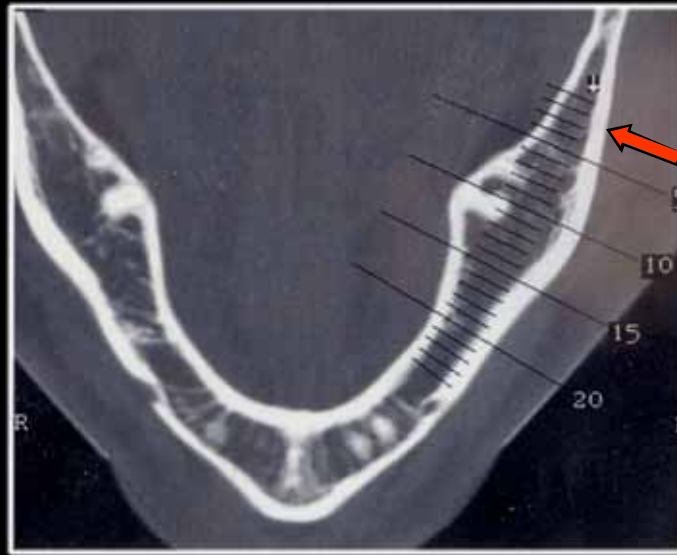
Mylohyoid Fossa



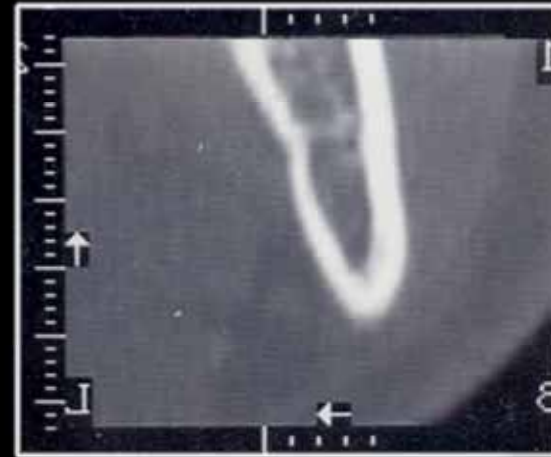
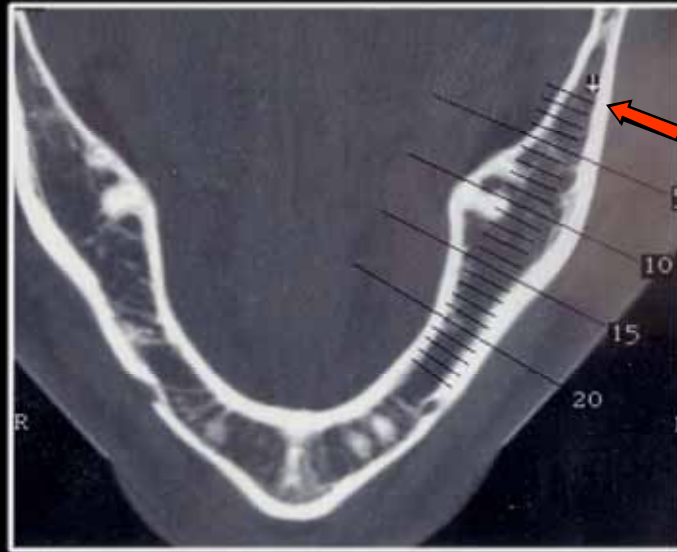
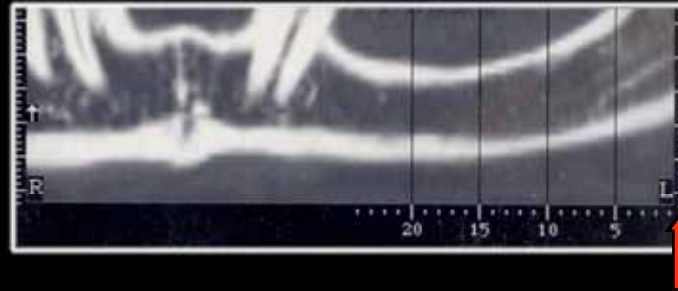Mylohyoid Fossa



Mylohyoid Fossa



Mylohyoid Fossa



Palpation of the Mandible

- Mylohyoid Fossa
- The Symphysis
- Lingual Surface of the Symphysis

Palpation of the Mandible

- The External Oblique Ridge
- The Internal Oblique Ridge
- The Angle between Ramus and the Medial Pterygoid Muscle

The End

Menu

