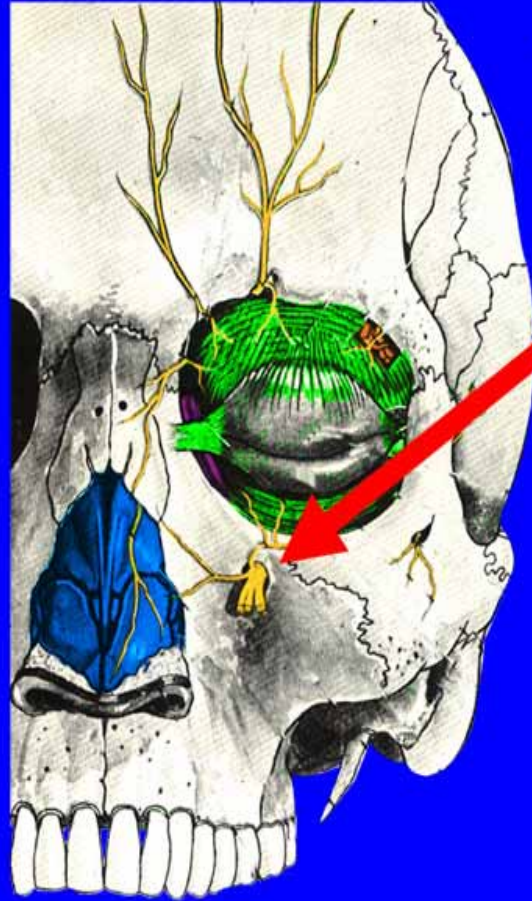
An anatomical illustration of a human skull, viewed from a three-quarter perspective. The skull is rendered in a realistic, light brown color with detailed shading to show the texture of the bone. The text 'The Anatomy of the Maxilla' is overlaid on the skull in a large, stylized font. The words 'The Anatomy' and 'the Maxilla' are in a red color with a white outline, while the word 'of' is in white with a red outline. The background of the entire slide is a solid blue color.

The Anatomy of the Maxilla

Menu



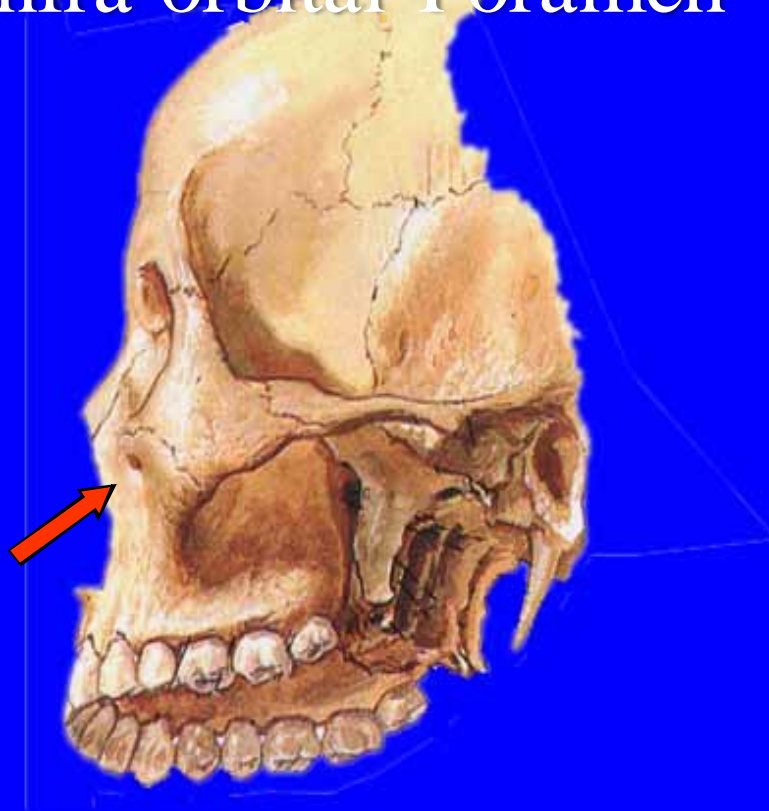
Infra-Orbital Nerve



Menu



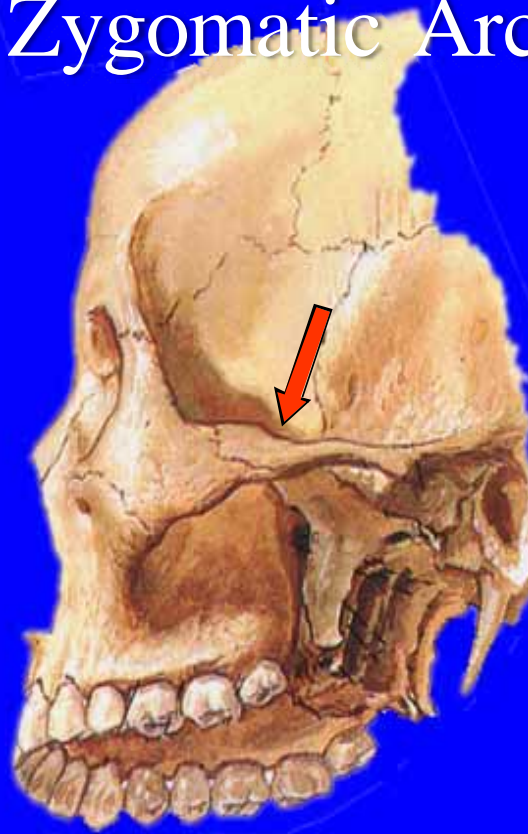
Infra-orbital Foramen



Menu



Zygomatic Arch



Menu



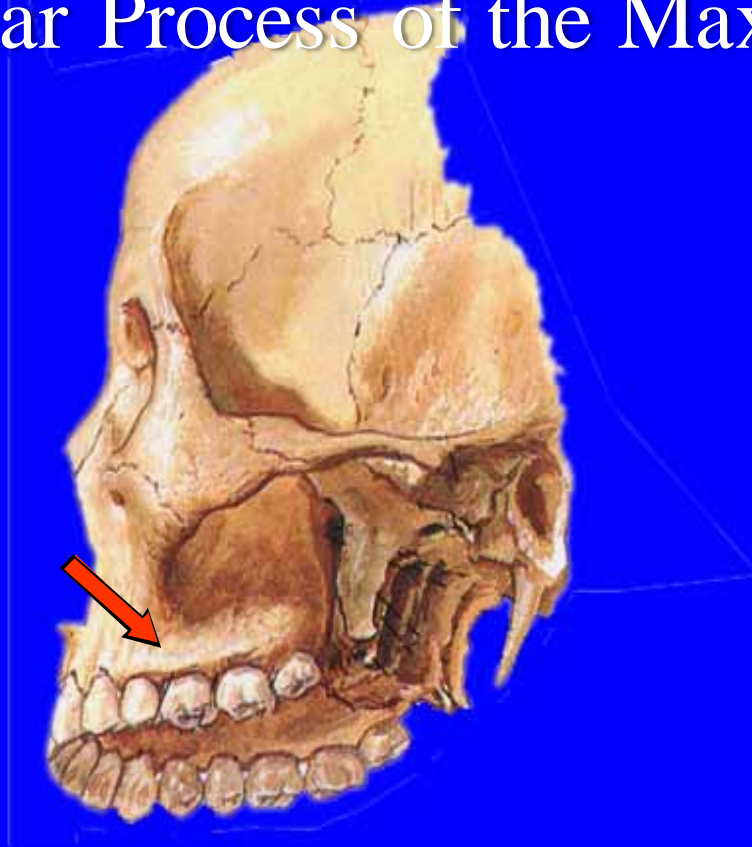
Zygomatic Process



Menu



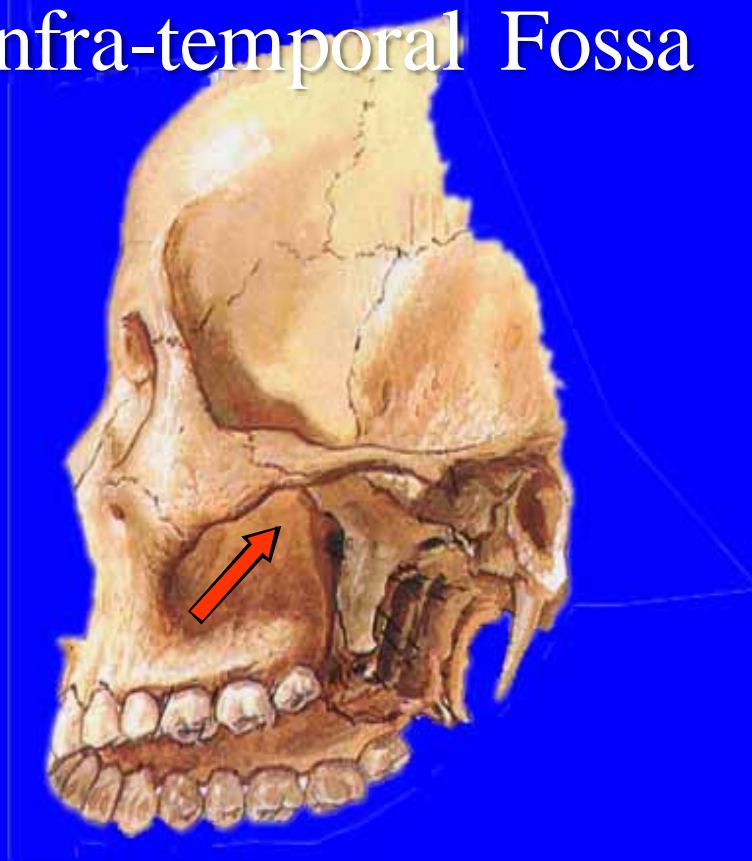
Alveolar Process of the Maxilla



Menu



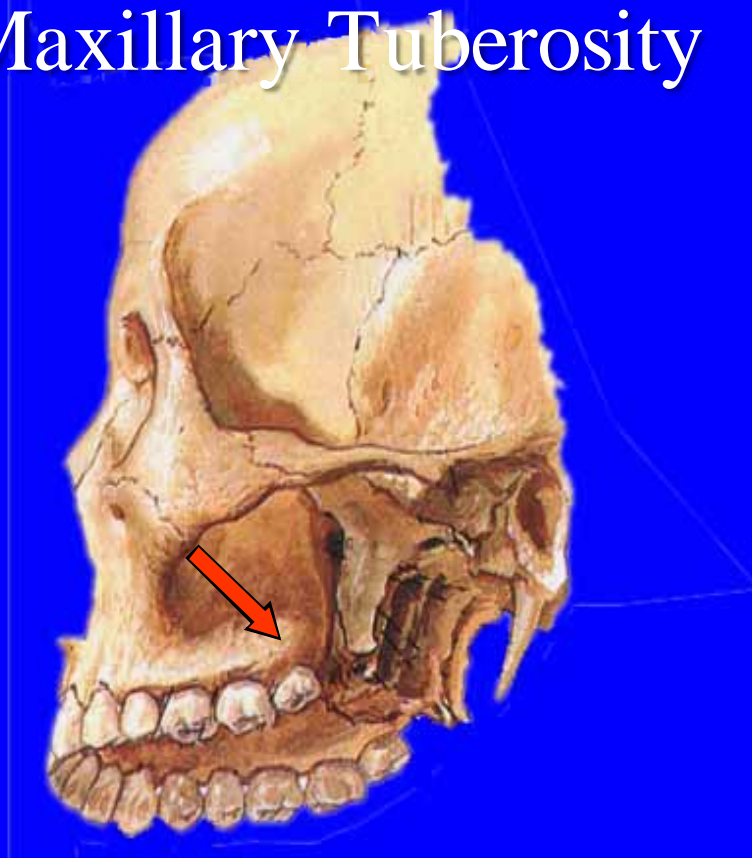
Infra-temporal Fossa



Menu



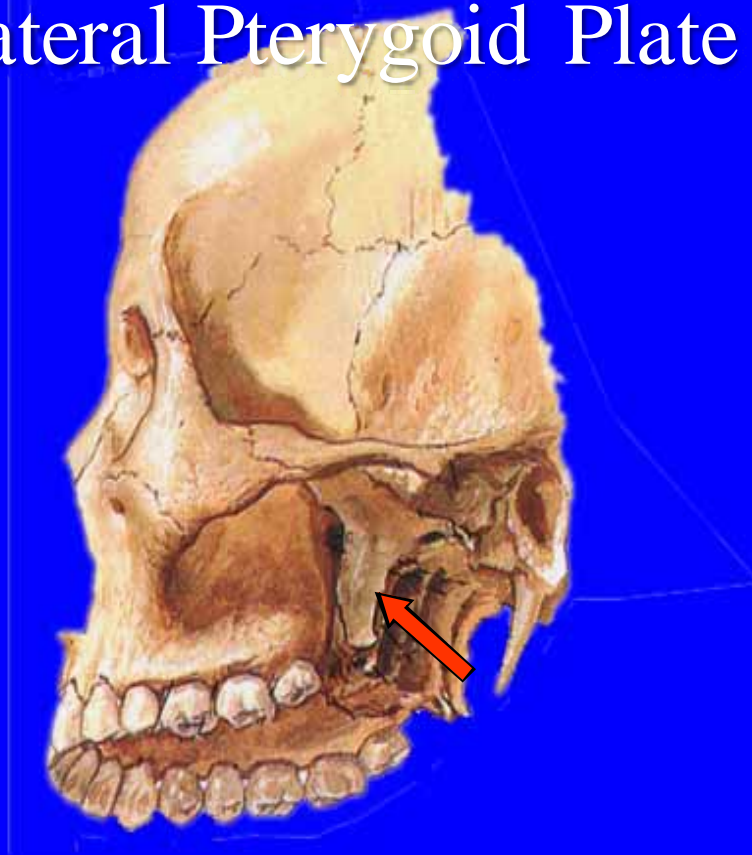
Maxillary Tuberosity



Menu



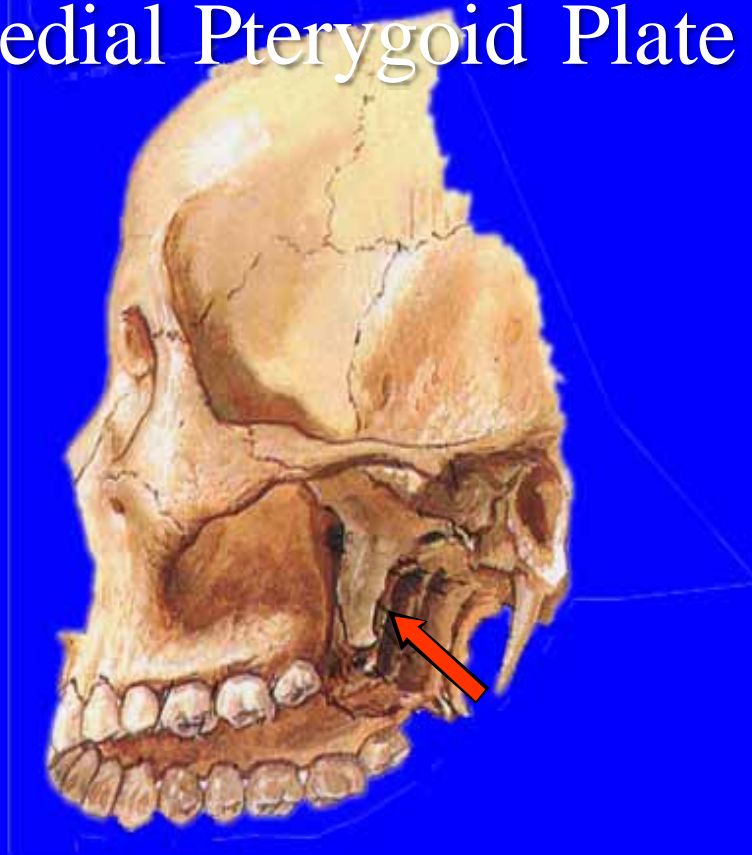
Lateral Pterygoid Plate



Menu



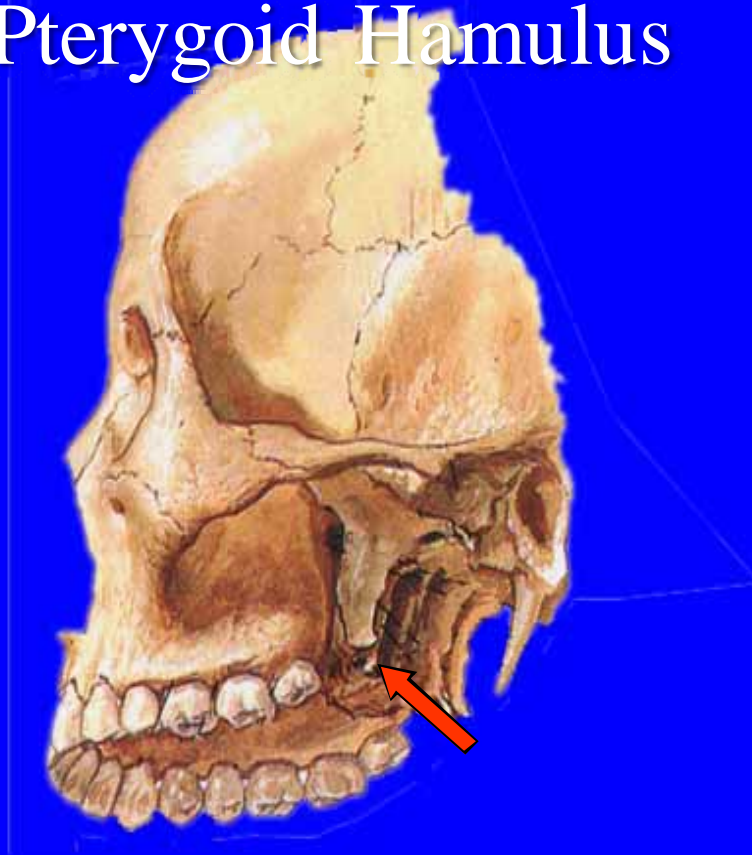
Medial Pterygoid Plate



Menu



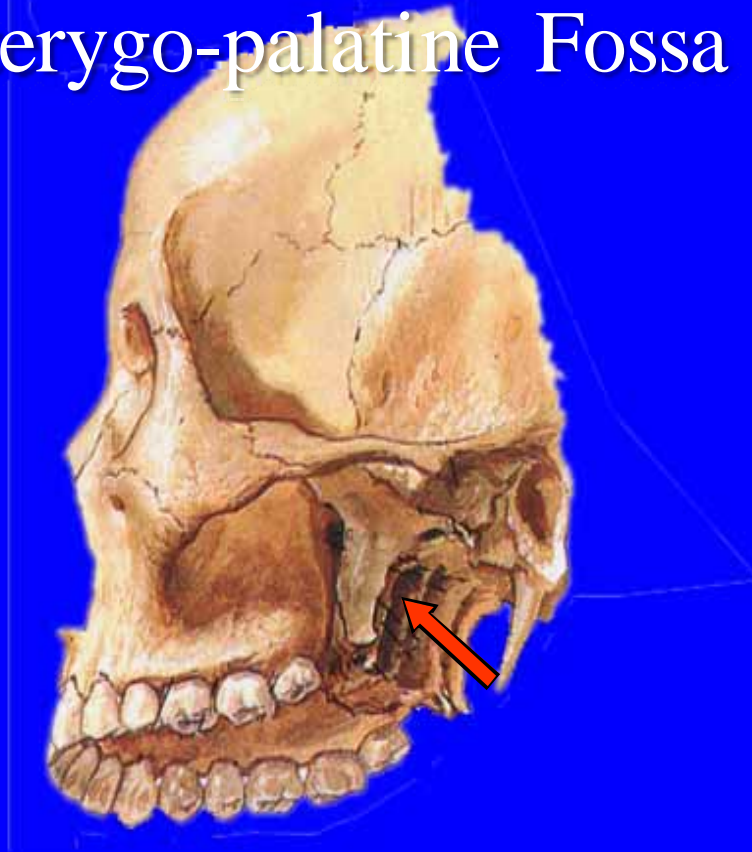
Pterygoid Hamulus



Menu



Pterygo-palatine Fossa



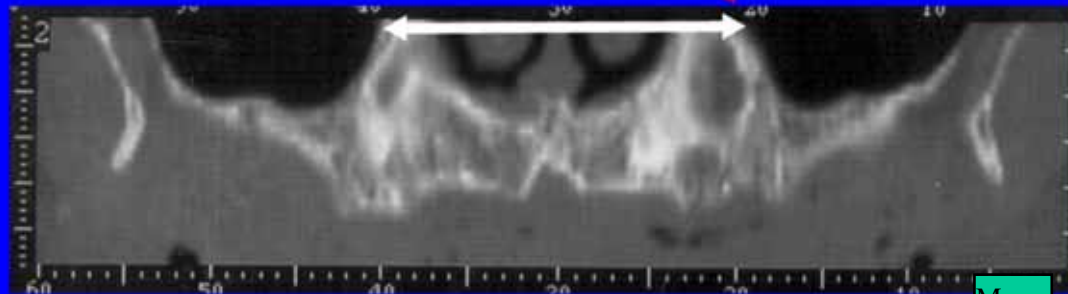
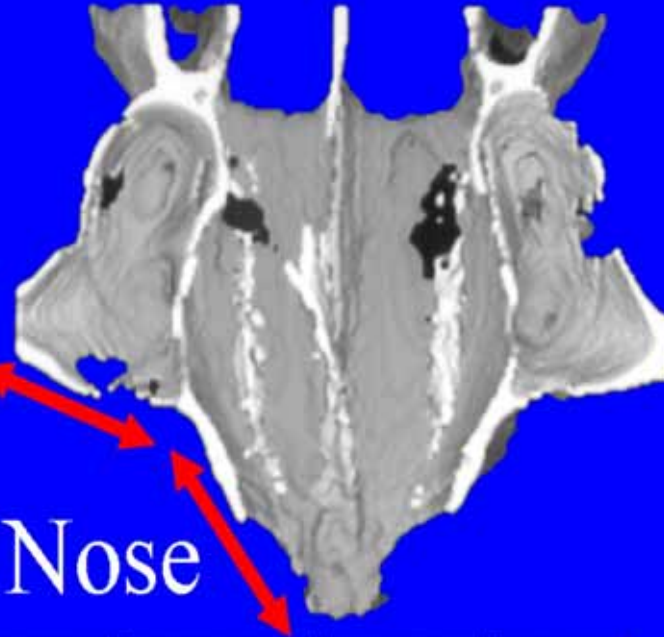
Menu



Narrow
Long Face

Sinus Wall

Wall of Nose



Menu





The End

Menu

