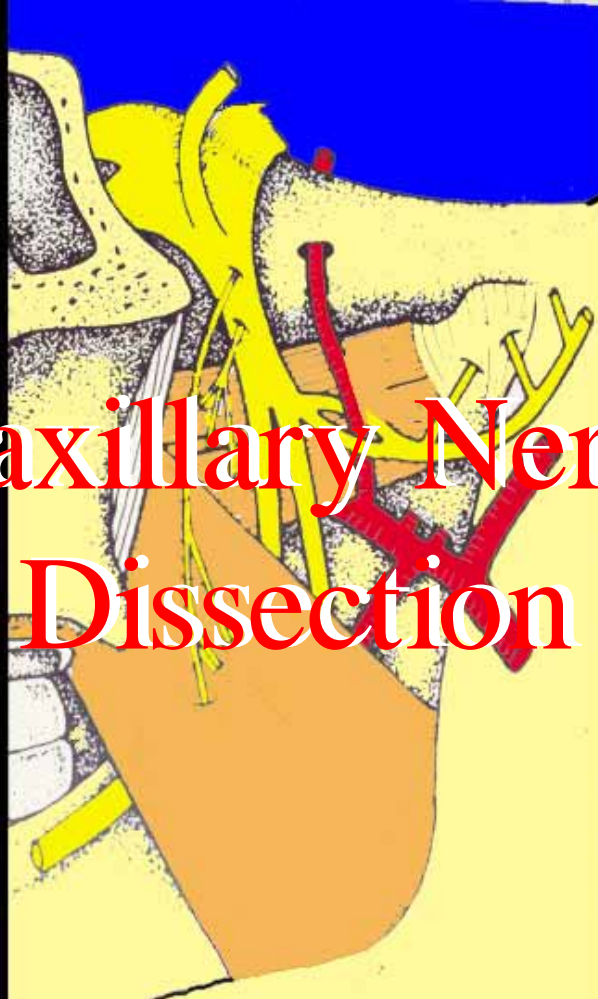


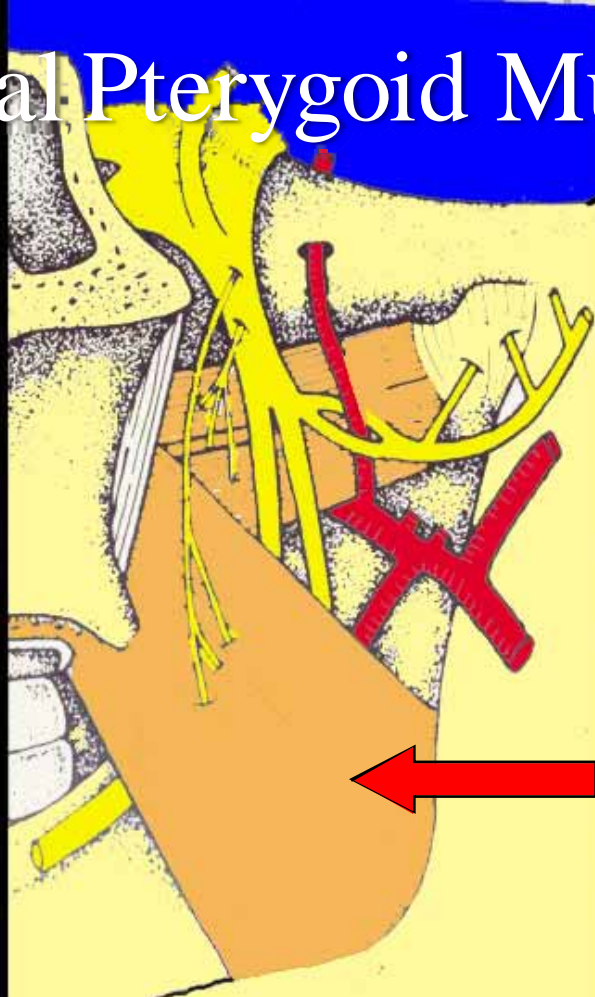
Maxillary Nerve Dissection



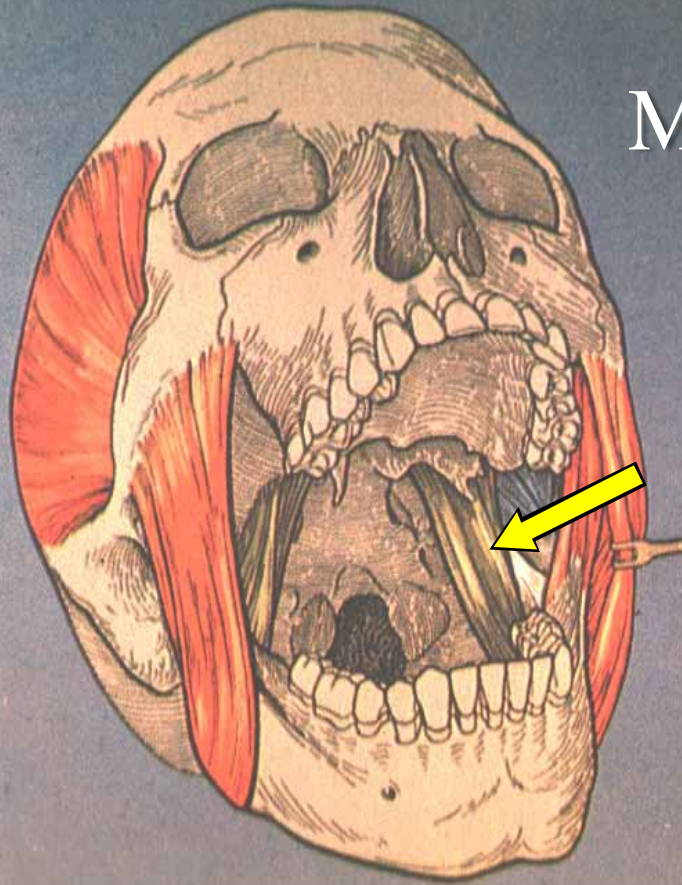
Menu



Medial Pterygoid Muscle



Medial Pterygoid Muscle



masseter

temporalis

lateral pterygoid

medial pterygoid

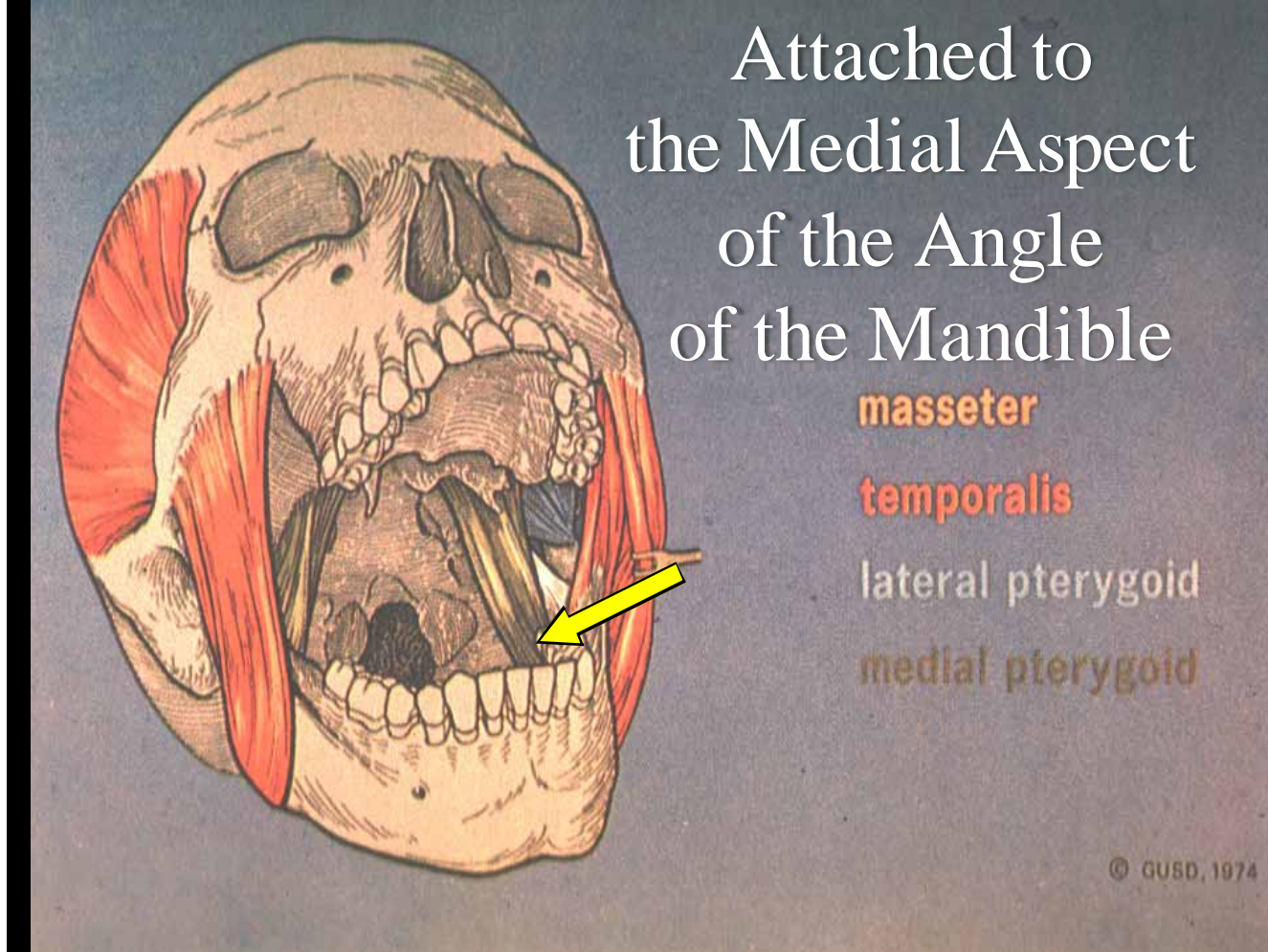
Attached to
the Medial Aspect
of the Angle
of the Mandible

masseter

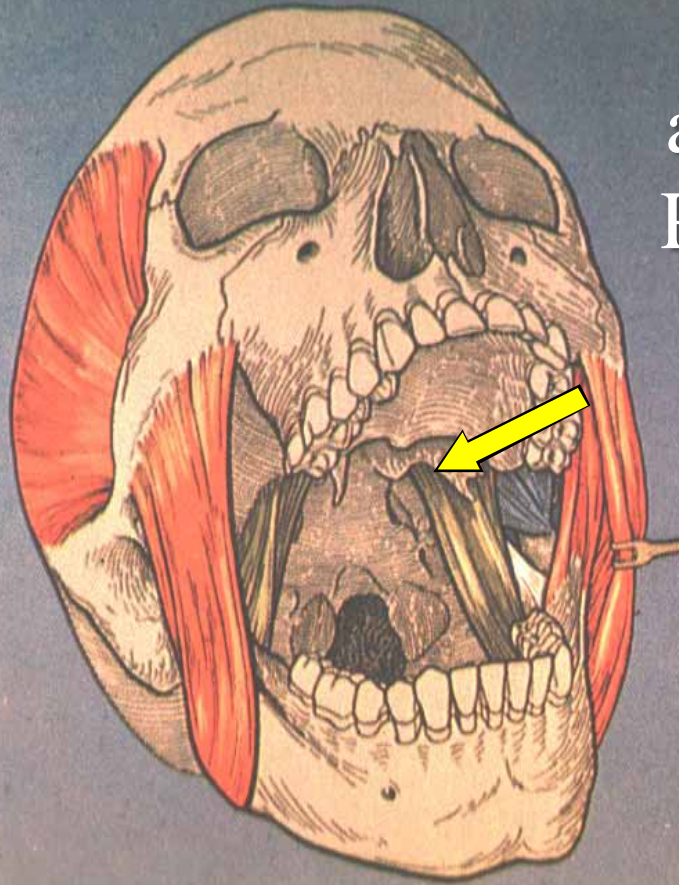
temporalis

lateral pterygoid

medial pterygoid



and the Medial Pterygoid Plate



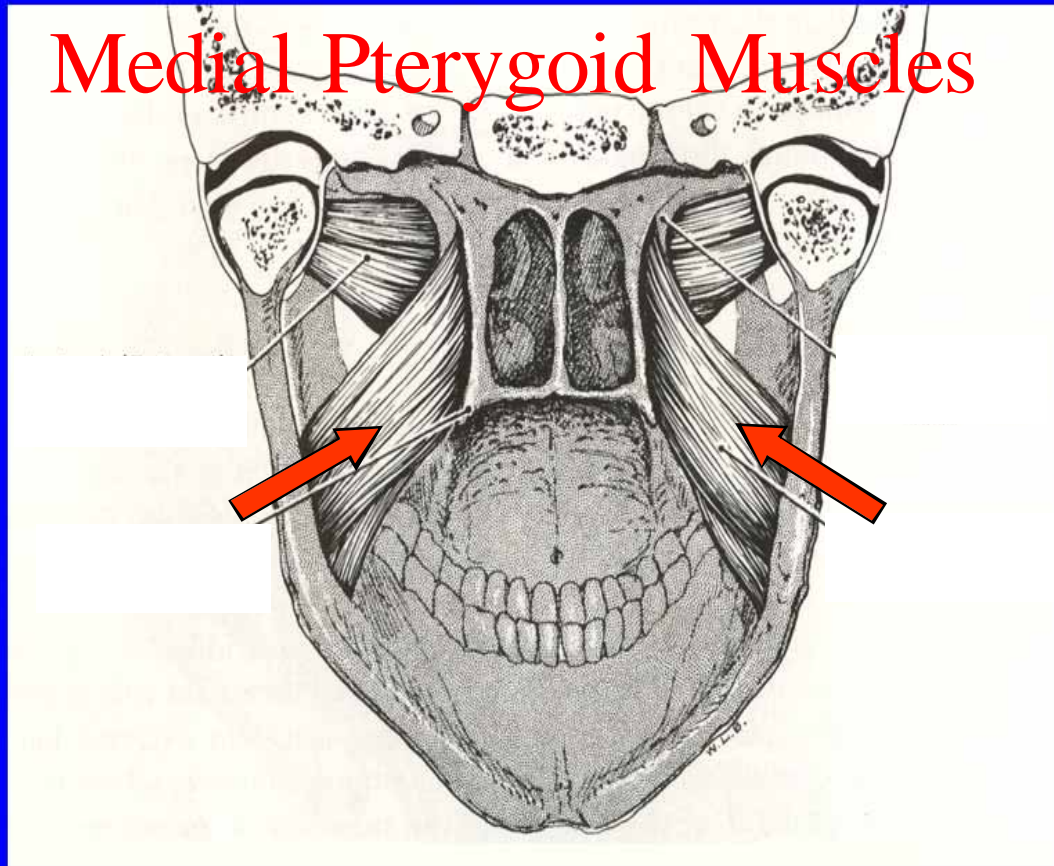
masseter

temporalis

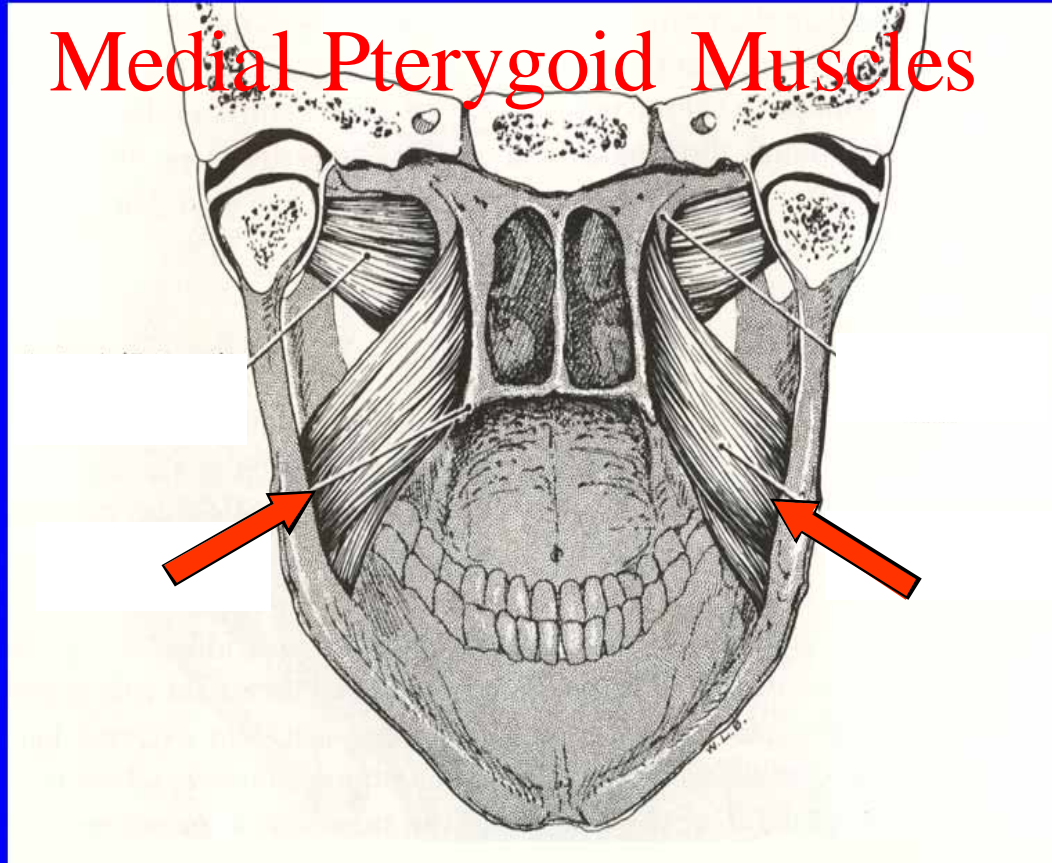
lateral pterygoid

medial pterygoid

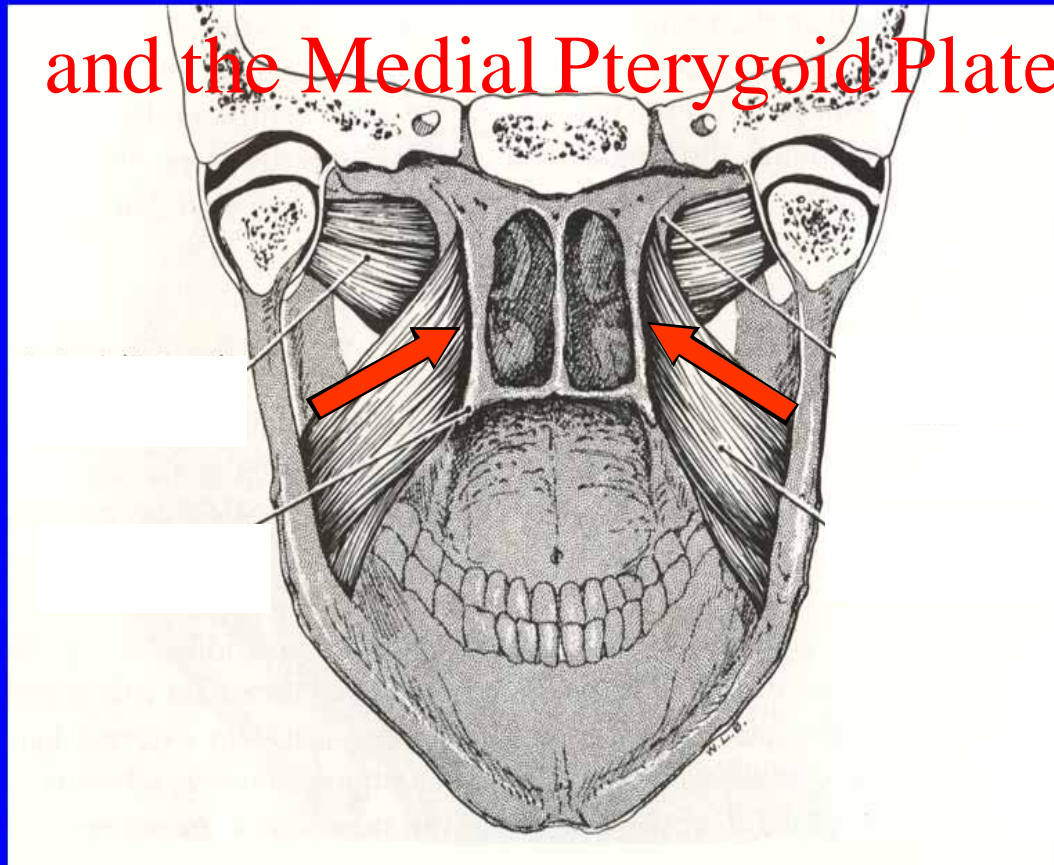
Medial Pterygoid Muscles



Medial Pterygoid Muscles



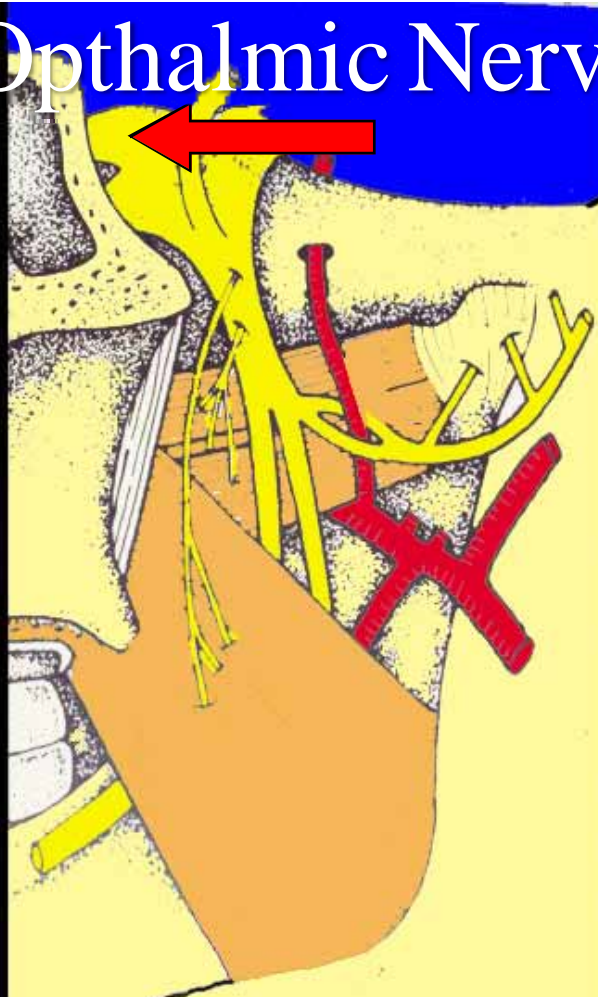and the Medial Pterygoid Plate



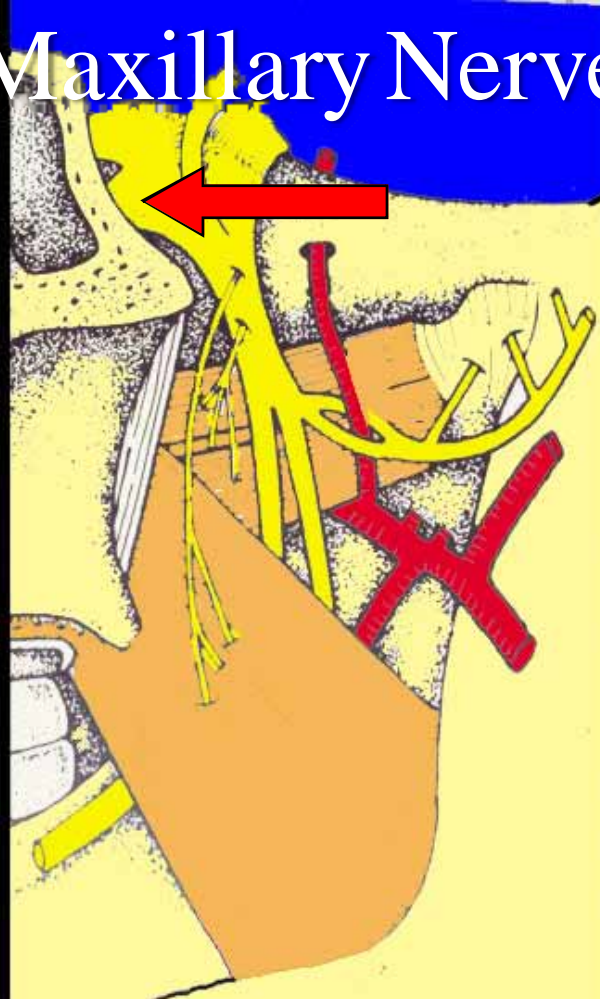
Trigeminal Nerve



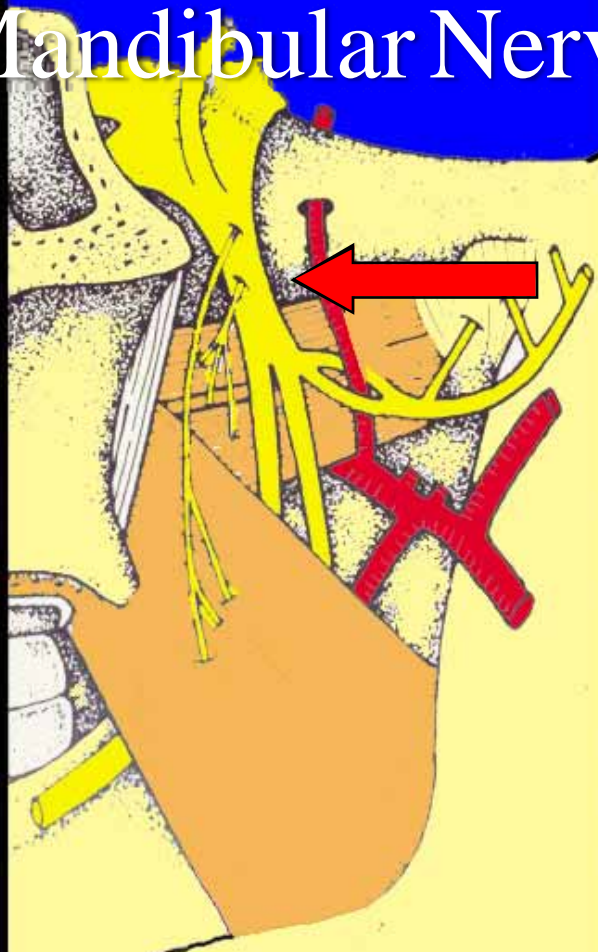Ophthalmic Nerve



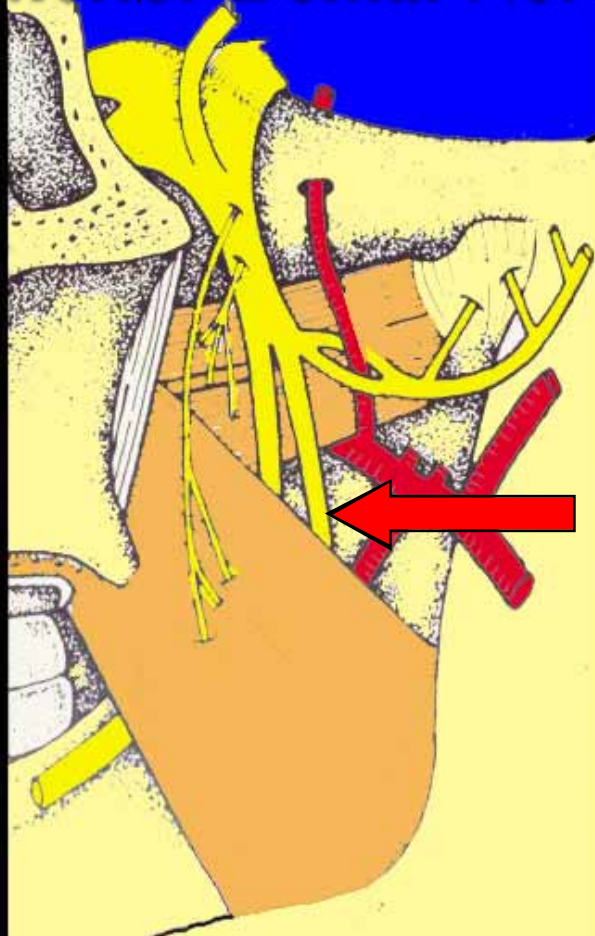
Maxillary Nerve



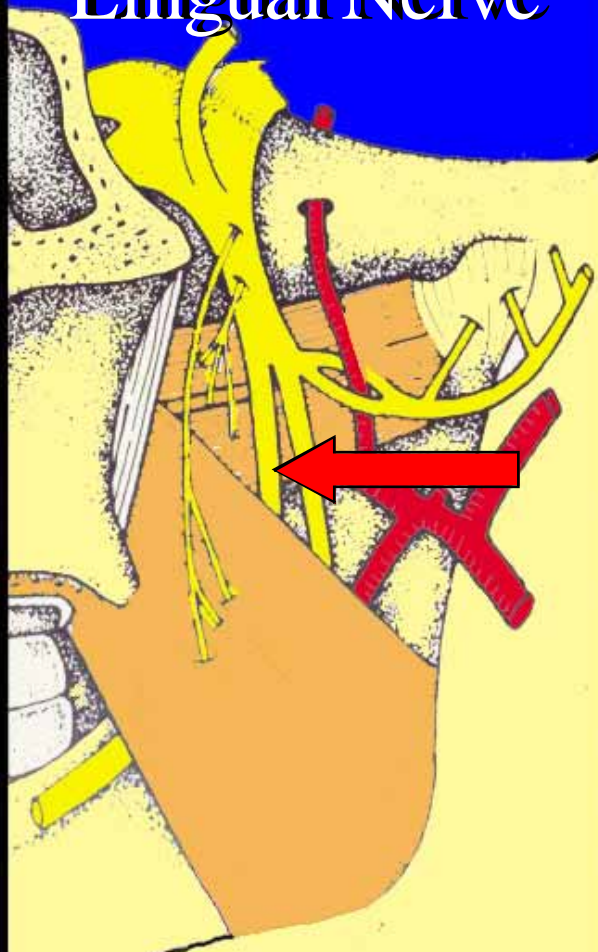
Mandibular Nerve



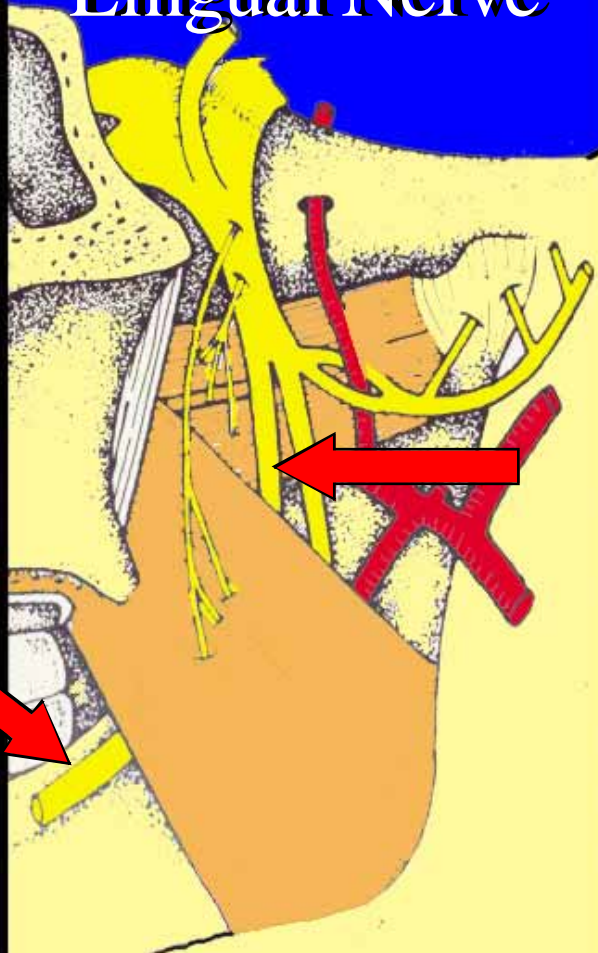
Inferior Dental Nerve



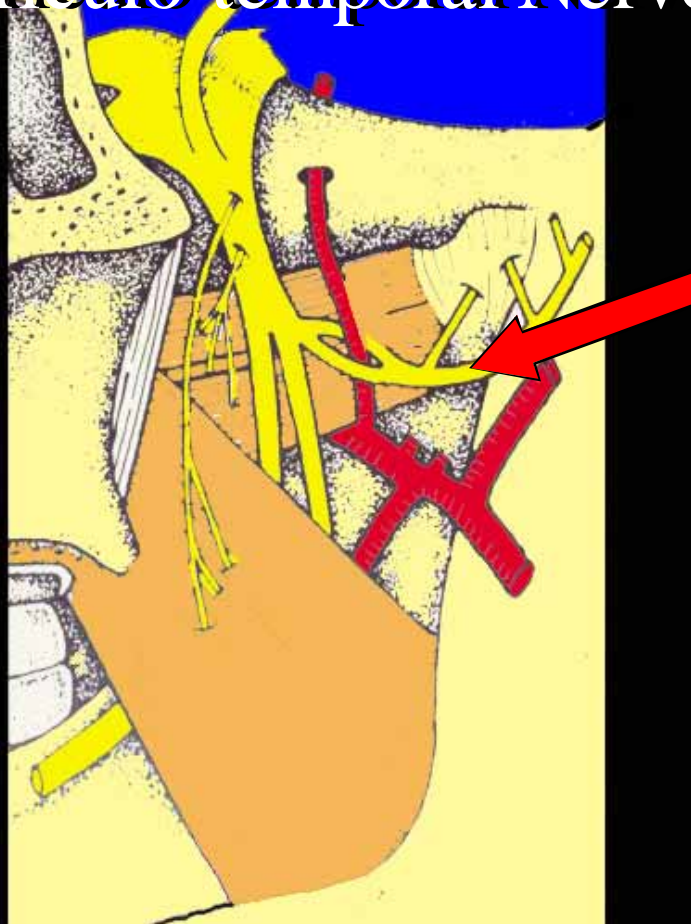
Lingual Nerve



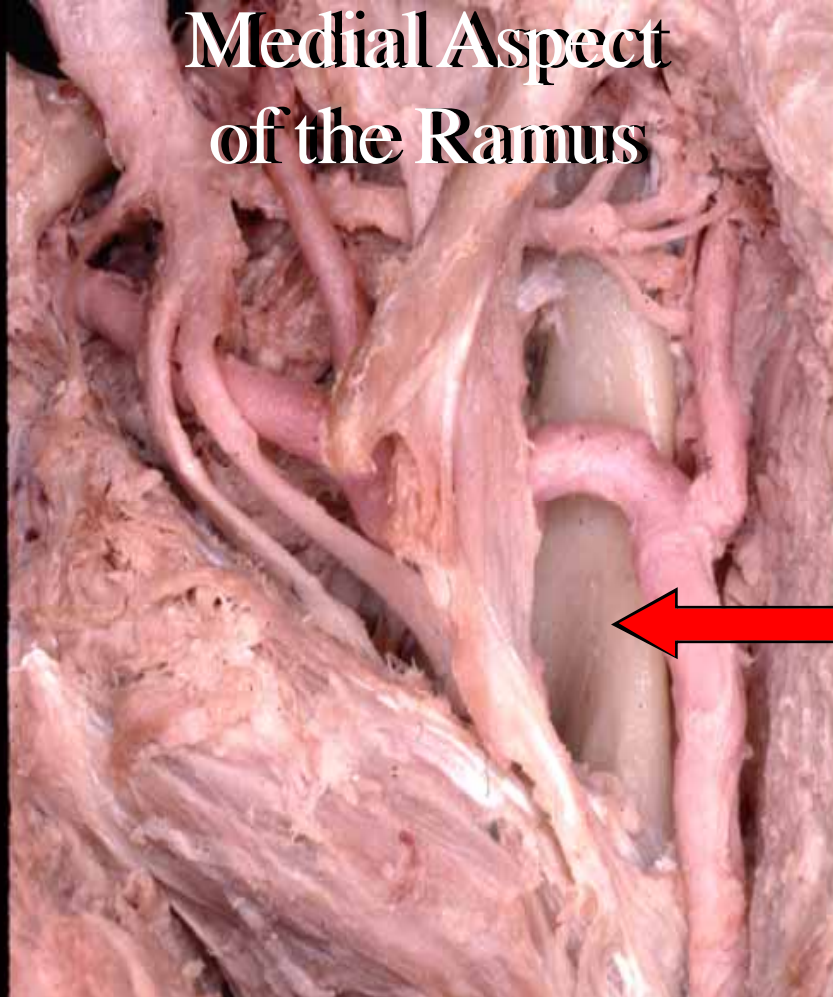
Lingual Nerve



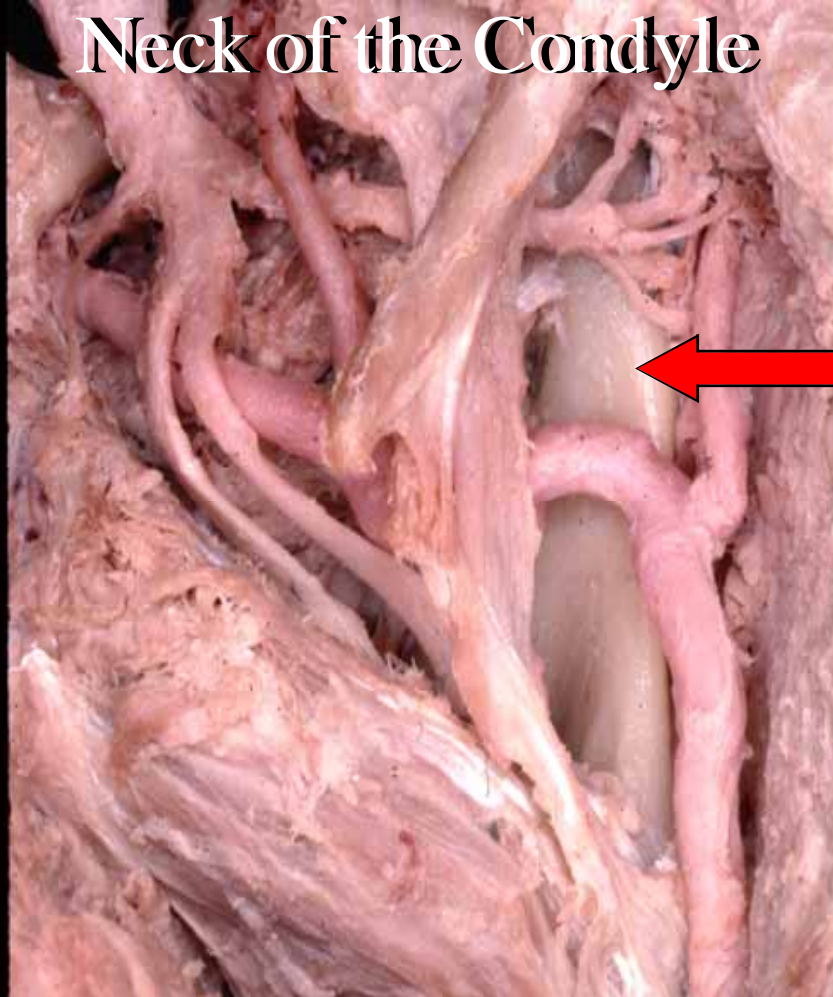
Auriculo-temporal Nerve



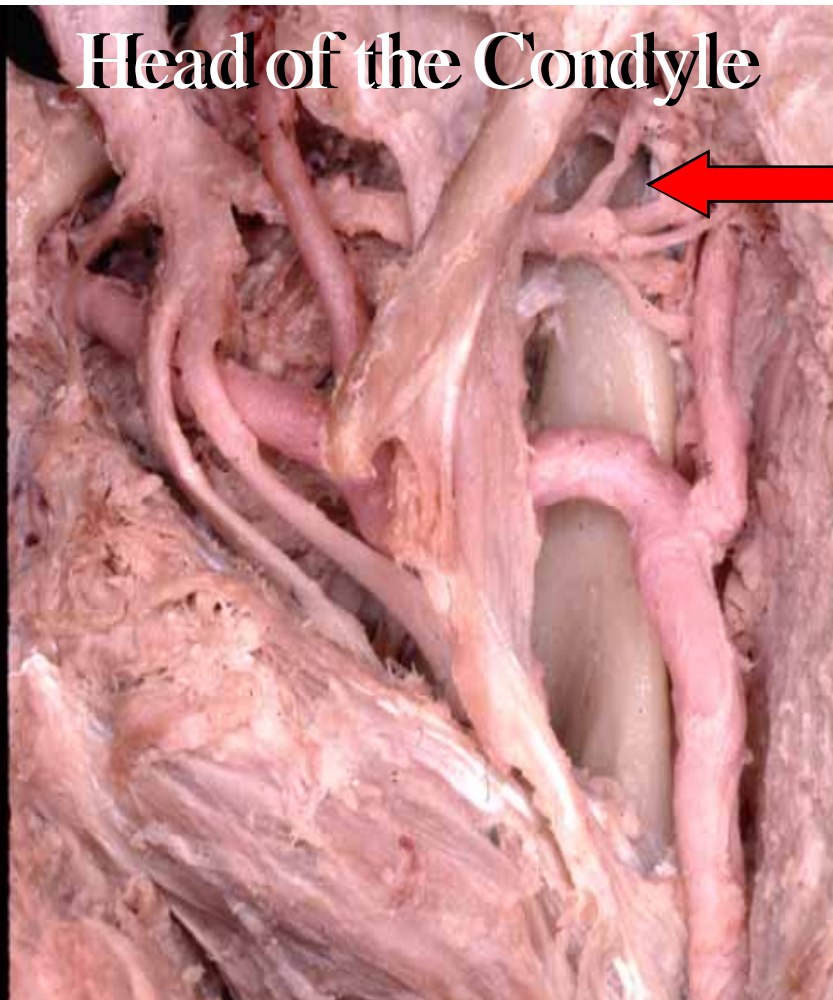
**Medial Aspect
of the Ramus**



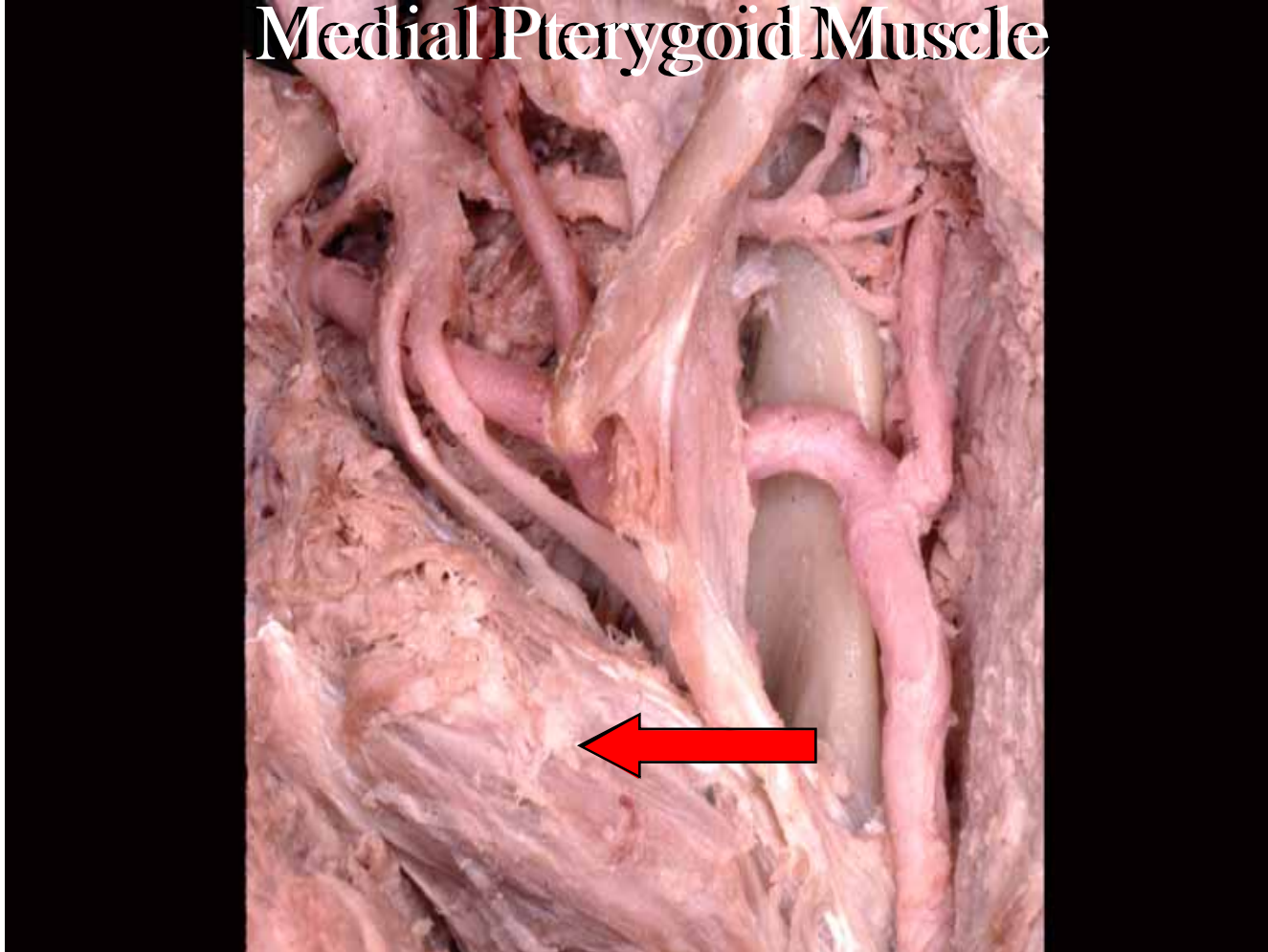
Neck of the Condyle



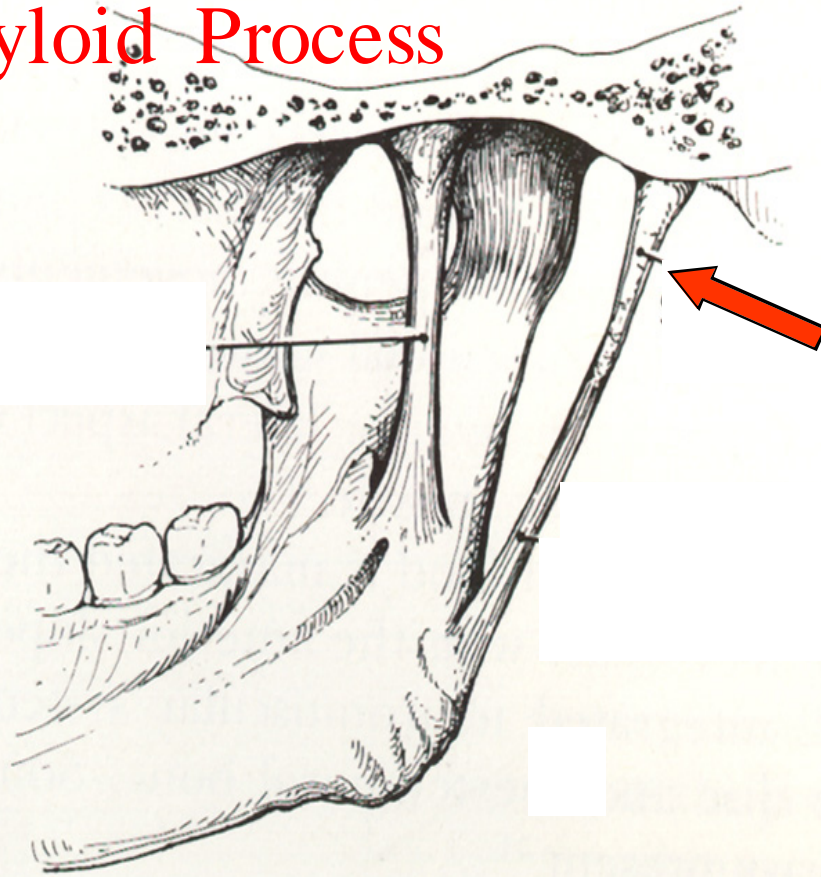
Head of the Condyle



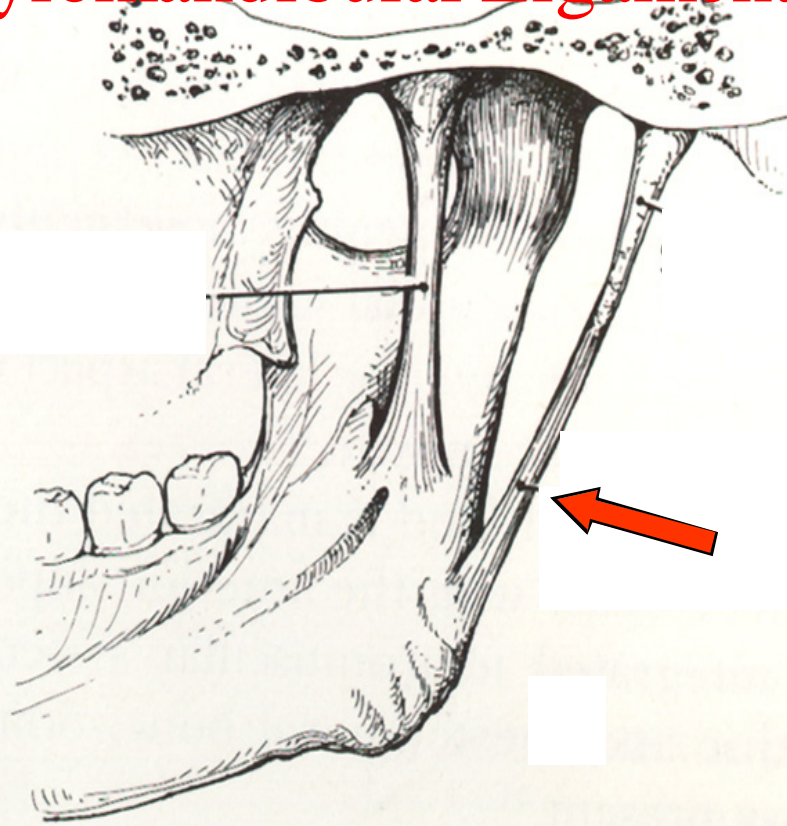
Medial Pterygoid Muscle



Styloid Process



Stylomandibular Ligament





linked image cannot be displayed. The file may have been moved, renamed, or deleted. Verify the link points to the correct file and location.

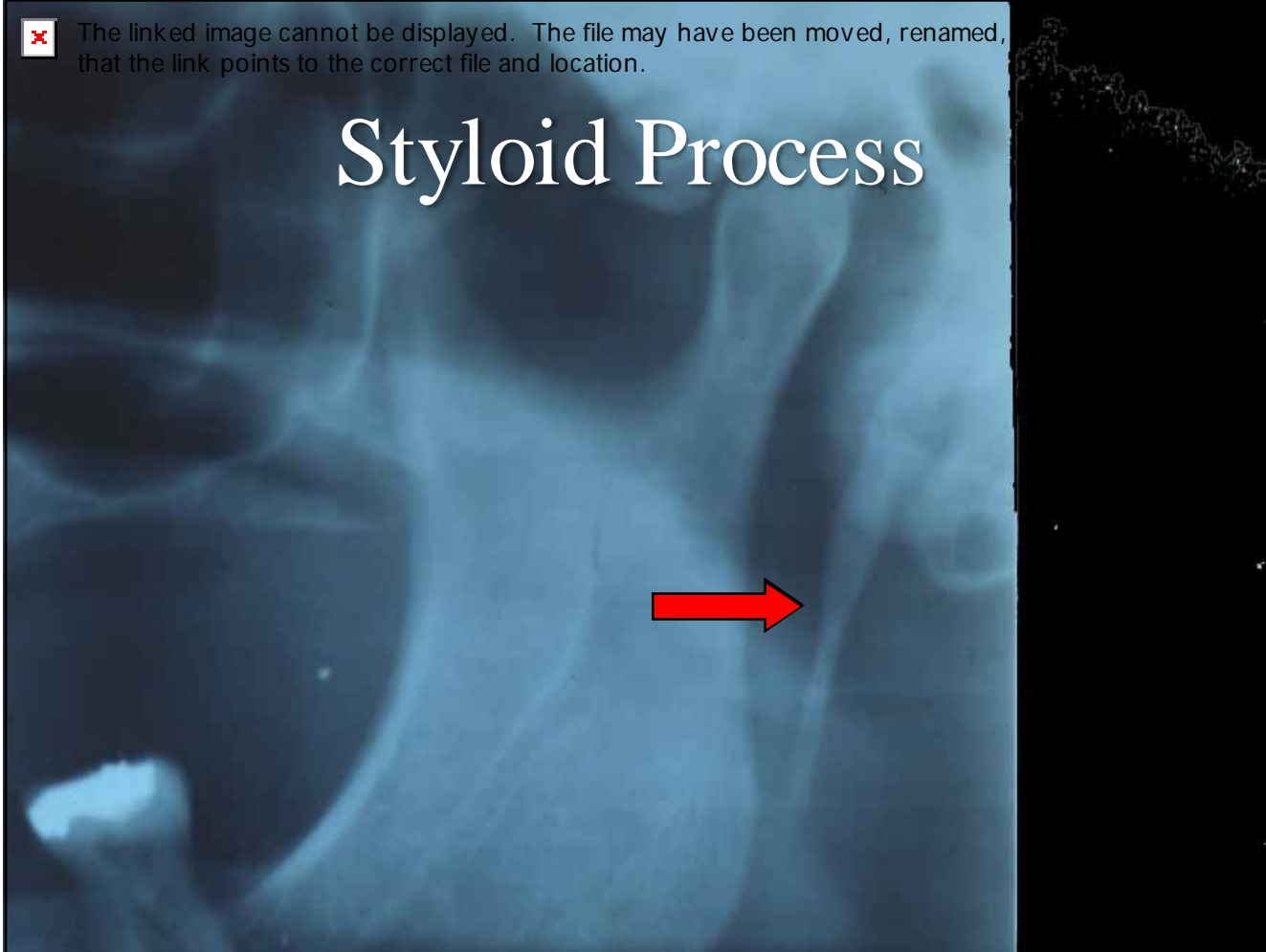
Styloid Process



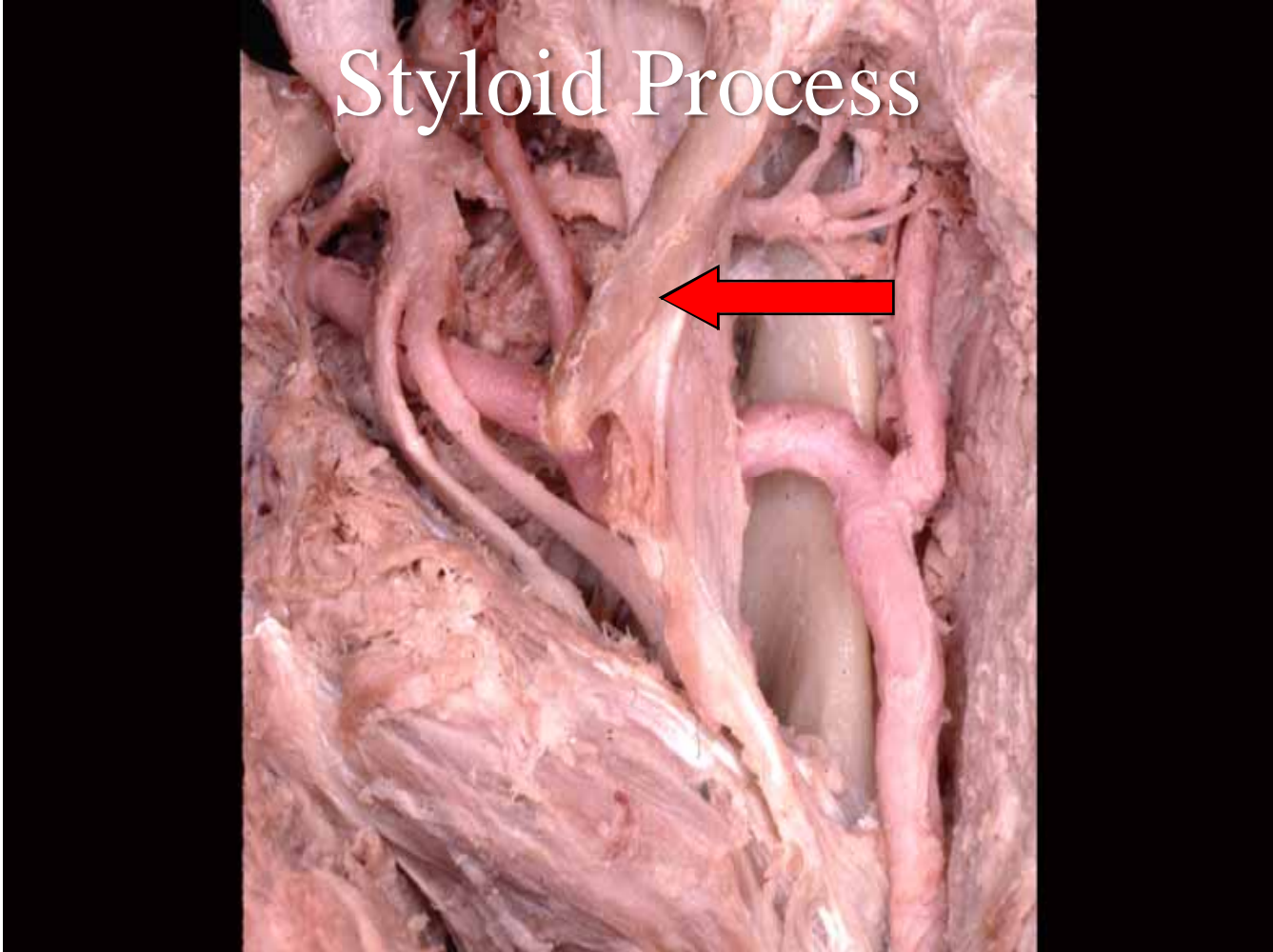


The linked image cannot be displayed. The file may have been moved, renamed, or deleted. Verify that the link points to the correct file and location.

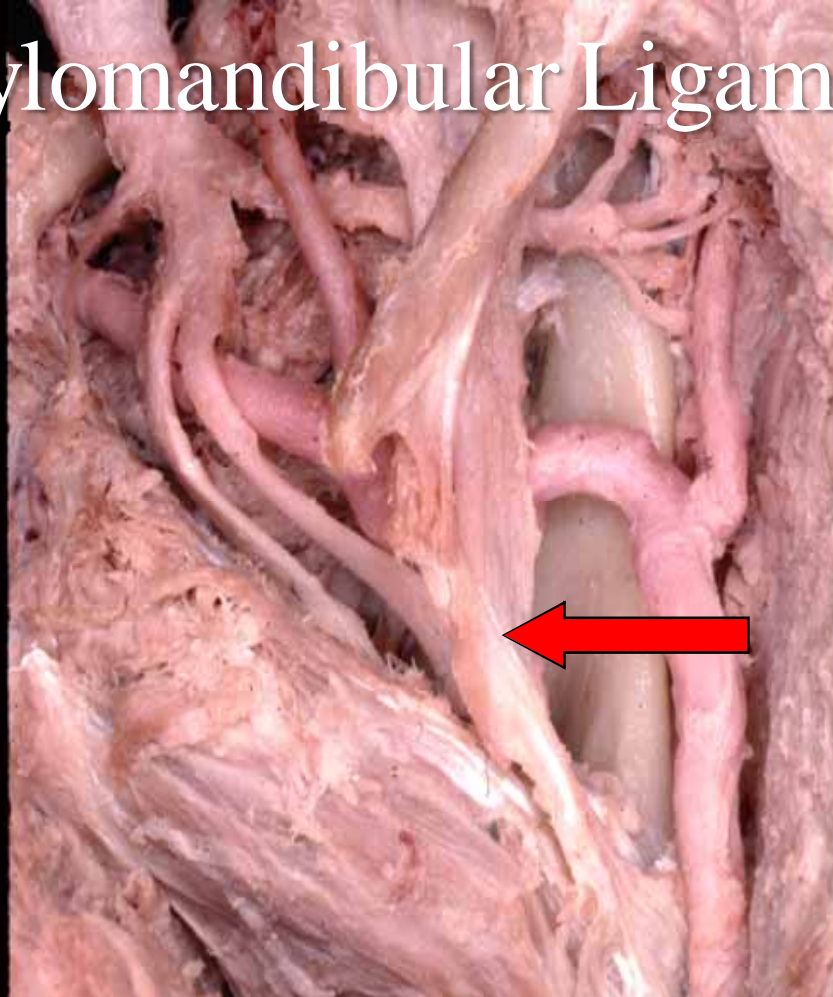
Styloid Process



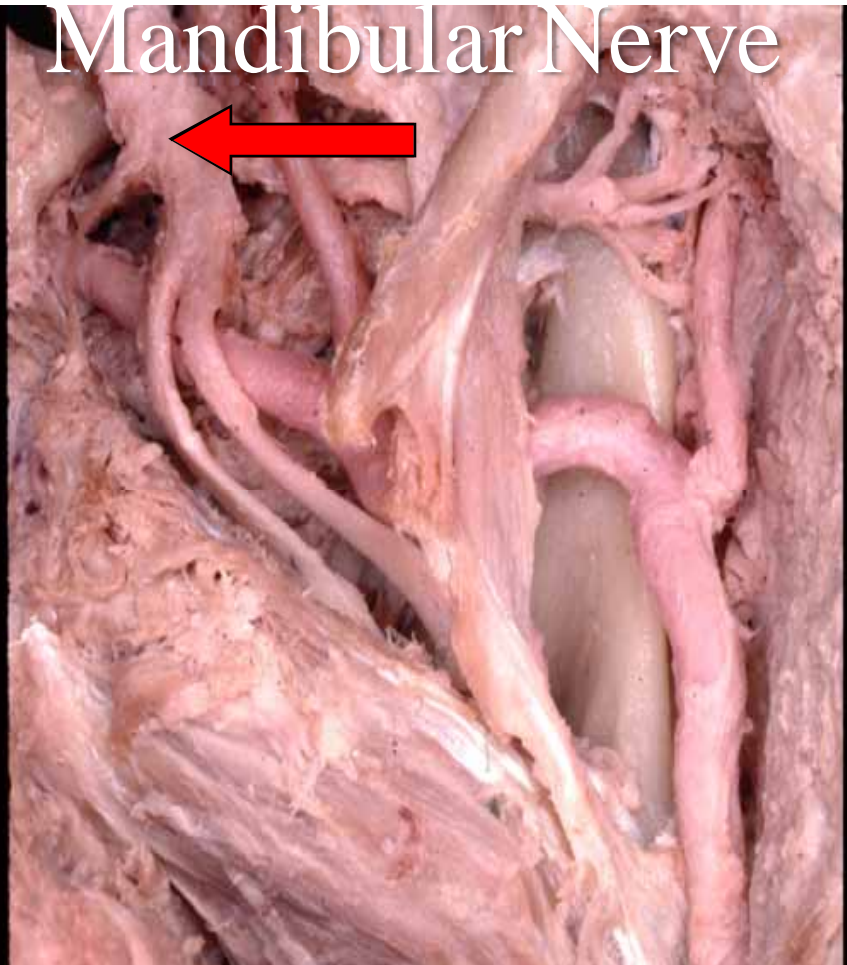
Styloid Process



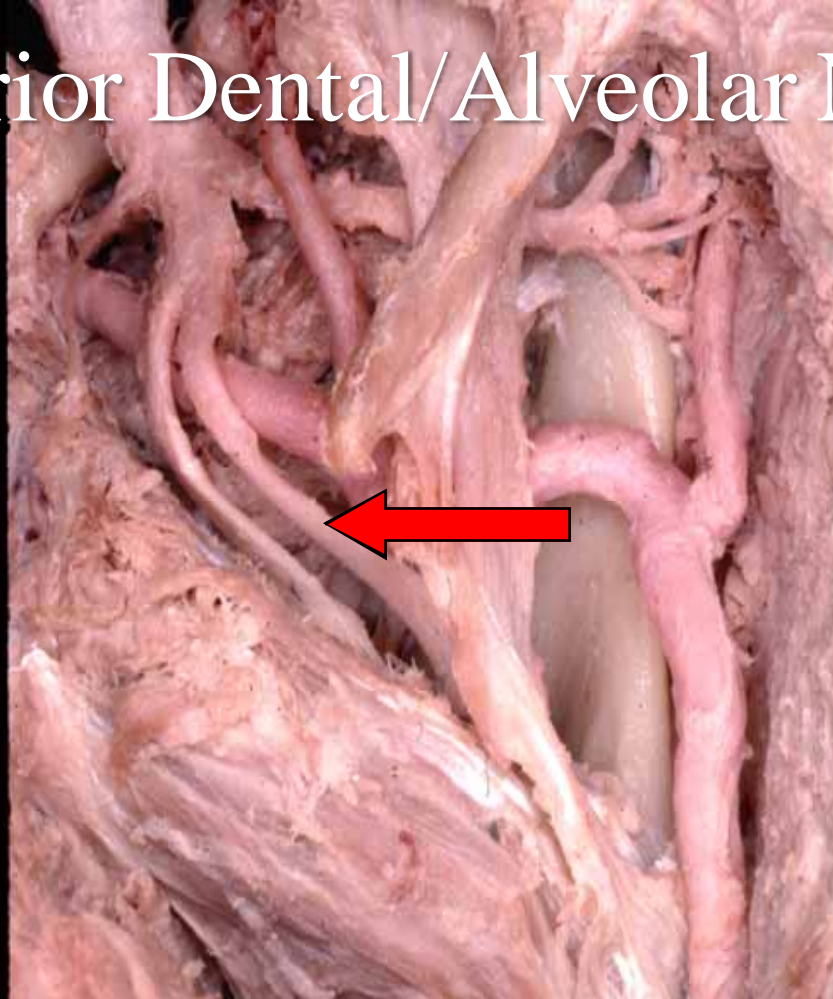
Stylomandibular Ligament



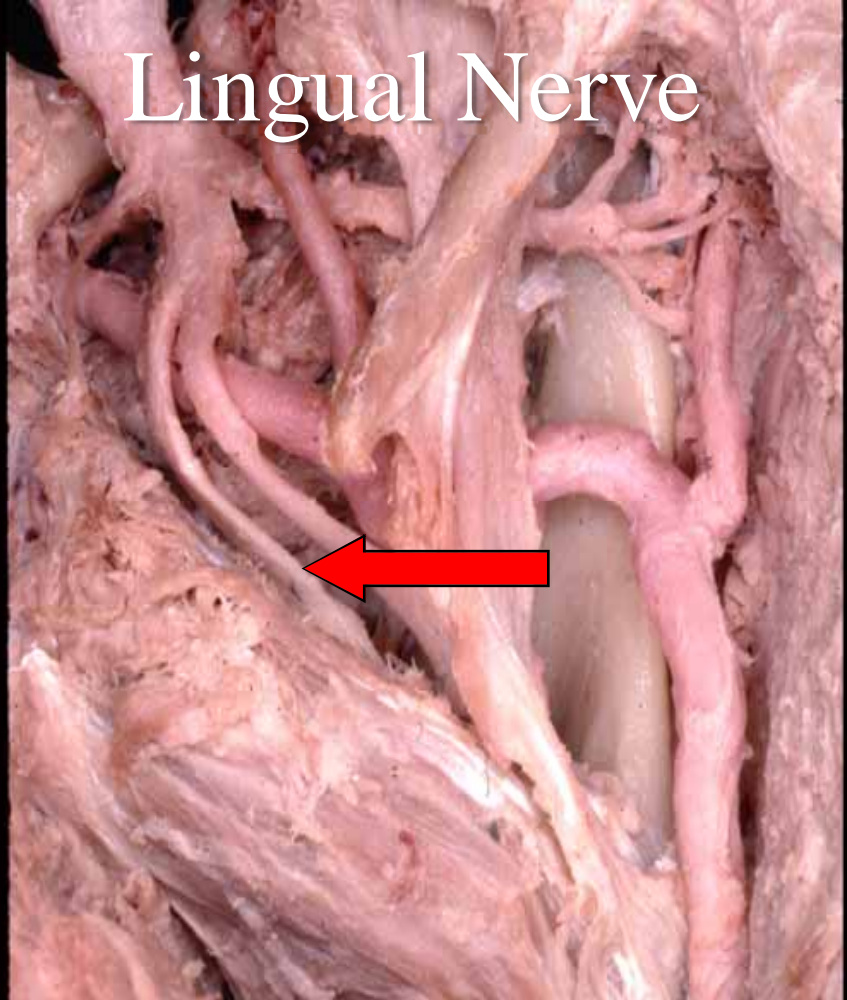
Mandibular Nerve



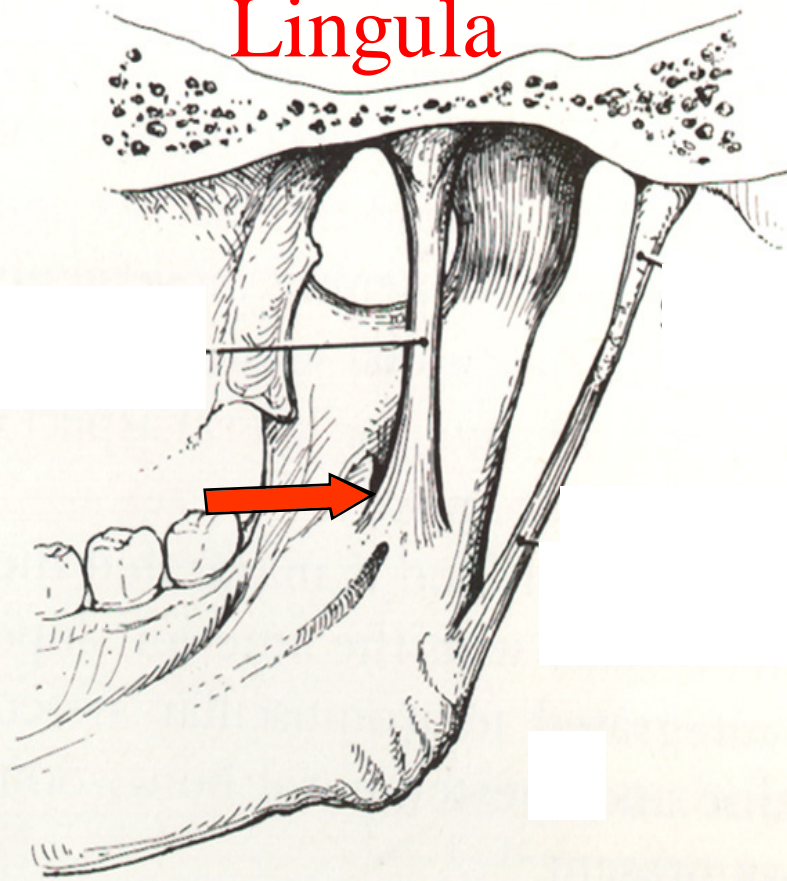
Inferior Dental/Alveolar Nerve



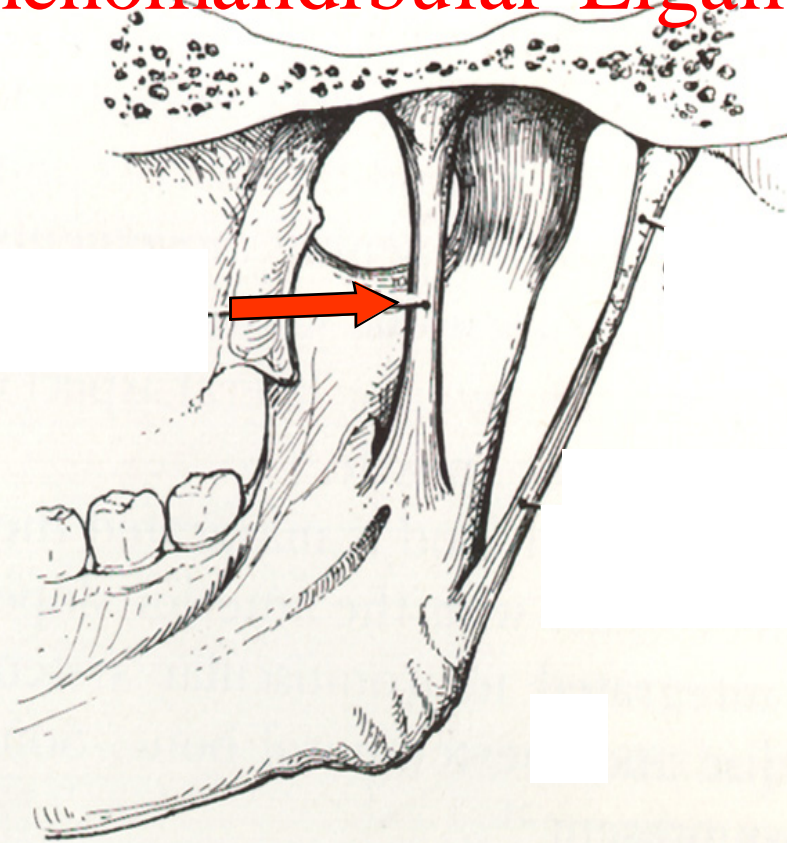
Lingual Nerve



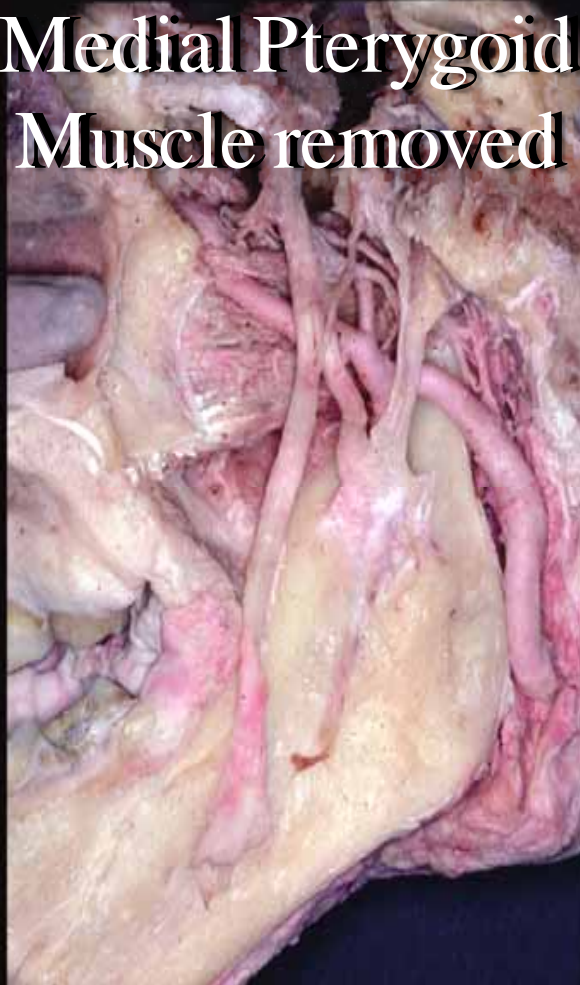Lingula



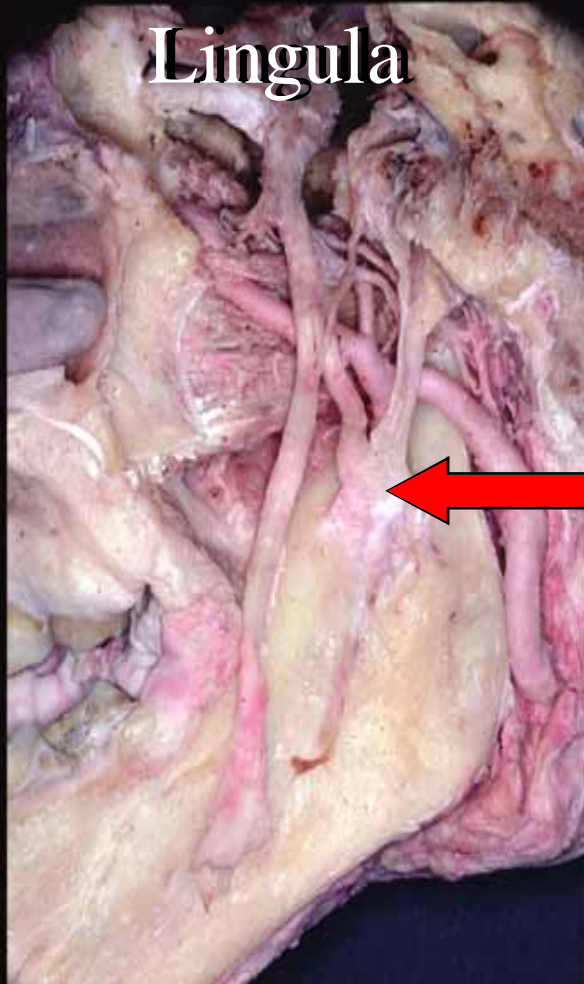
Sphenomandibular Ligament



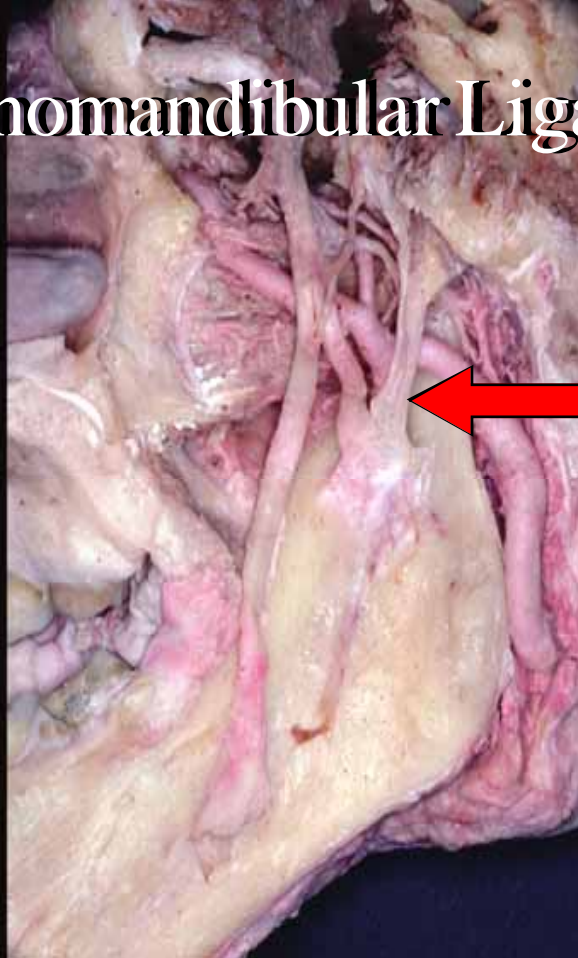
**Medial Pterygoid
Muscle removed**



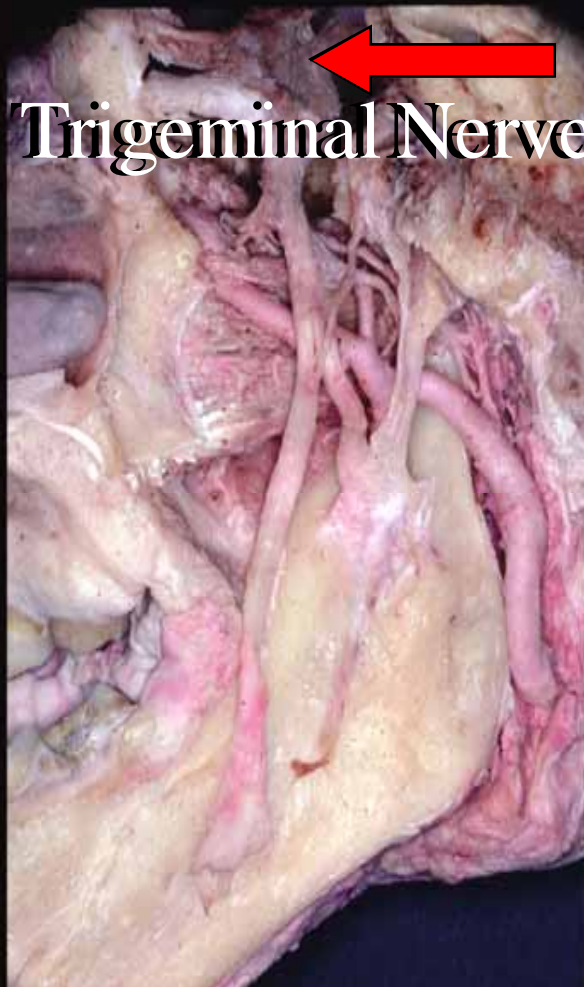

Lingula



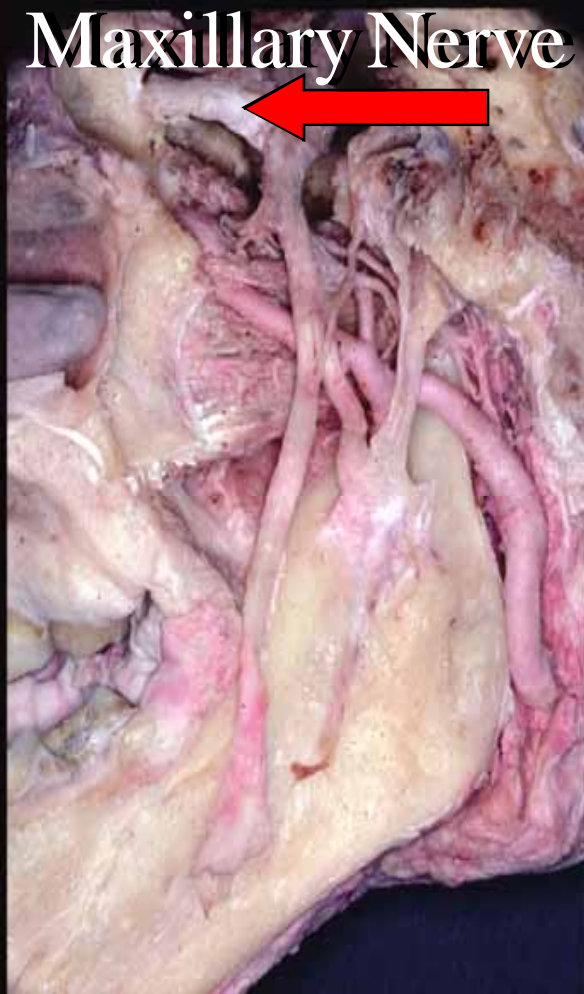

Sphenomandibular Ligament



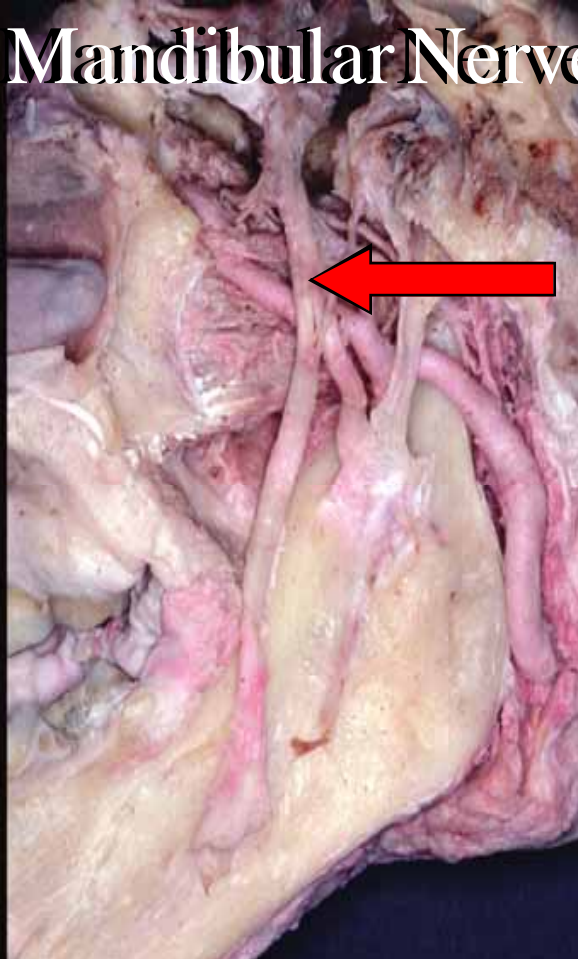
Trigeminal Nerve



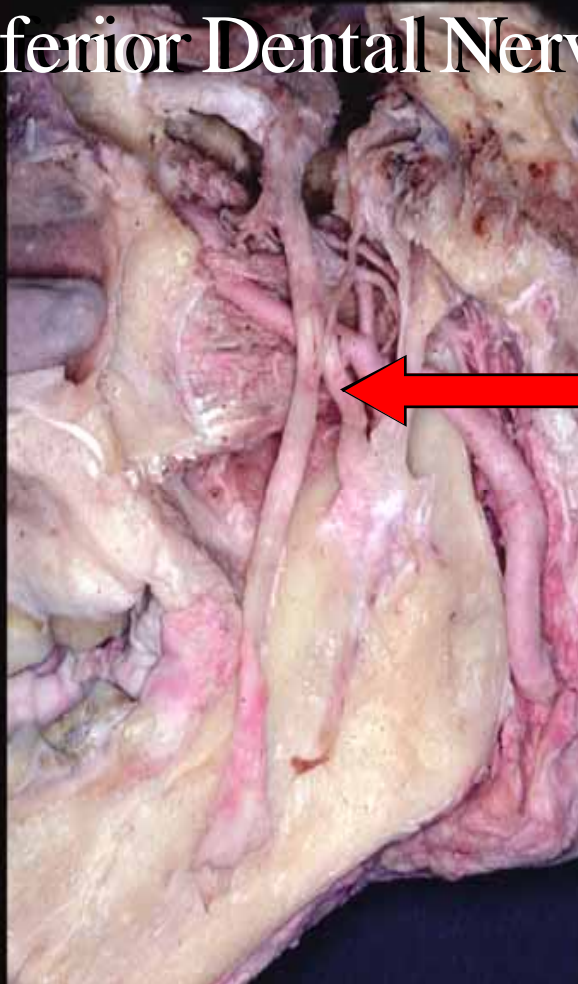
Maxillary Nerve



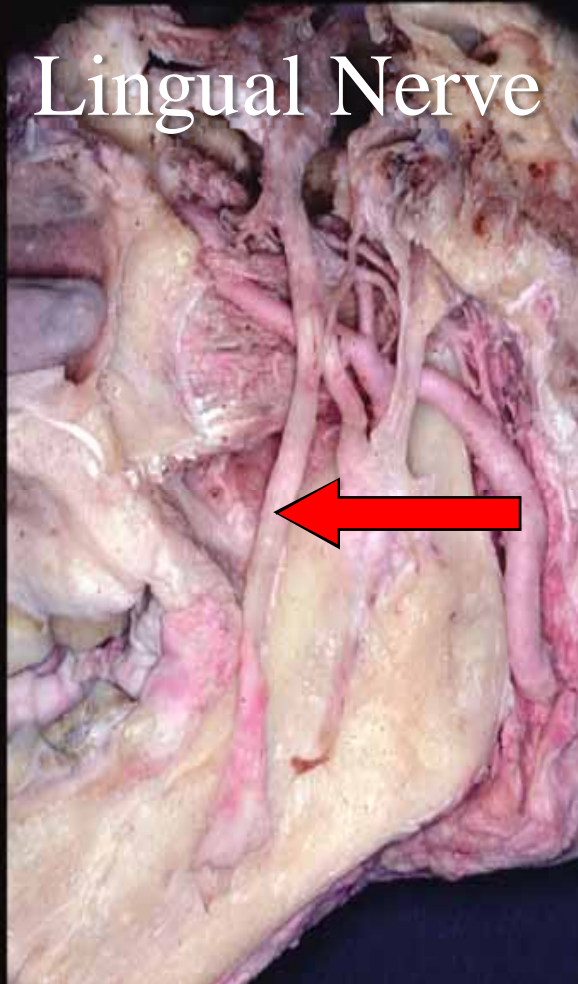
Mandibular Nerve

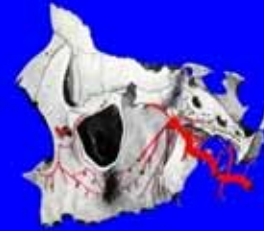
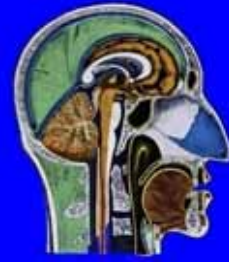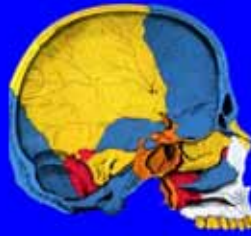

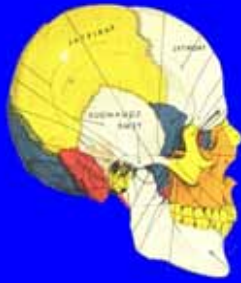
Inferior Dental Nerve



Lingual Nerve





The End

