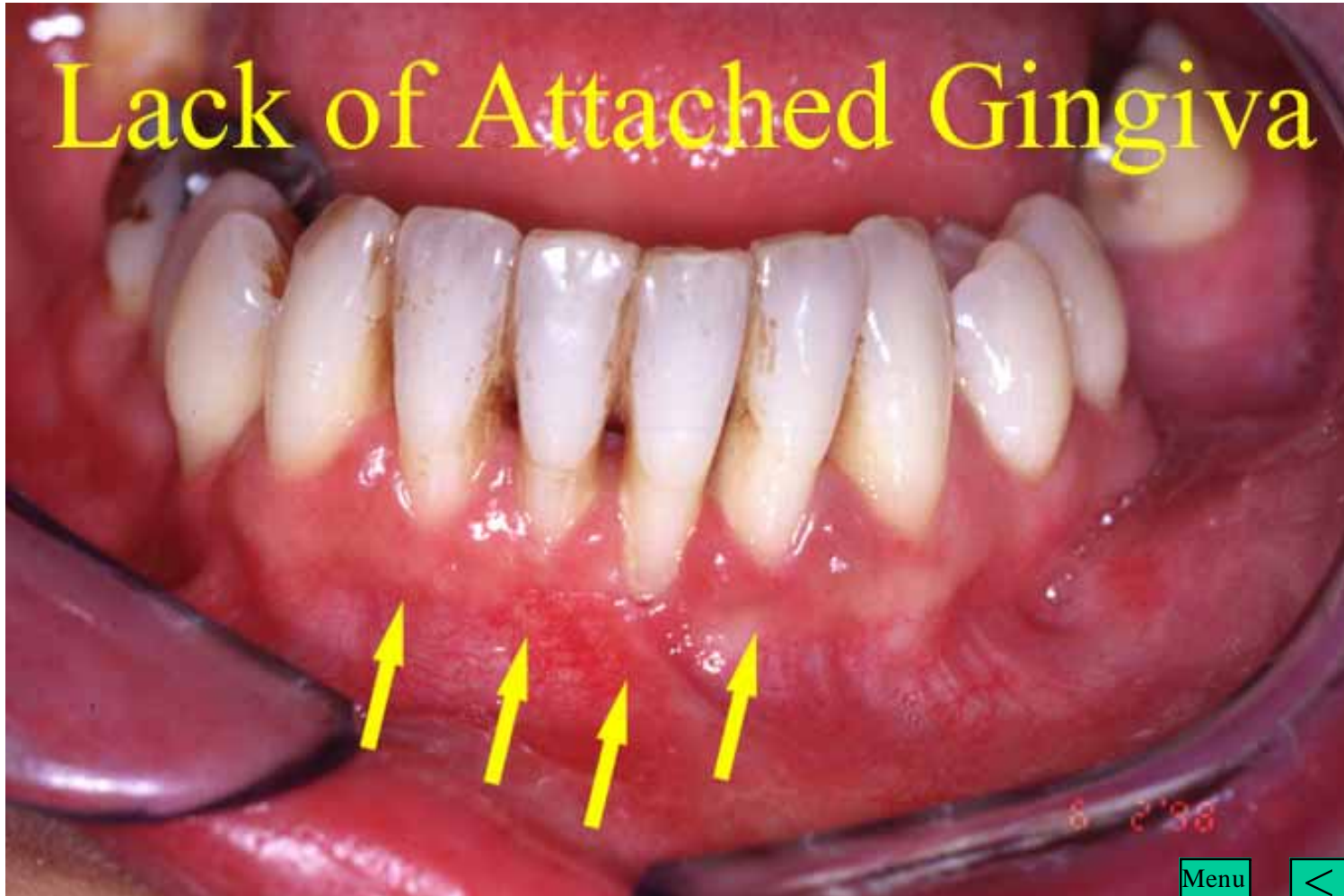

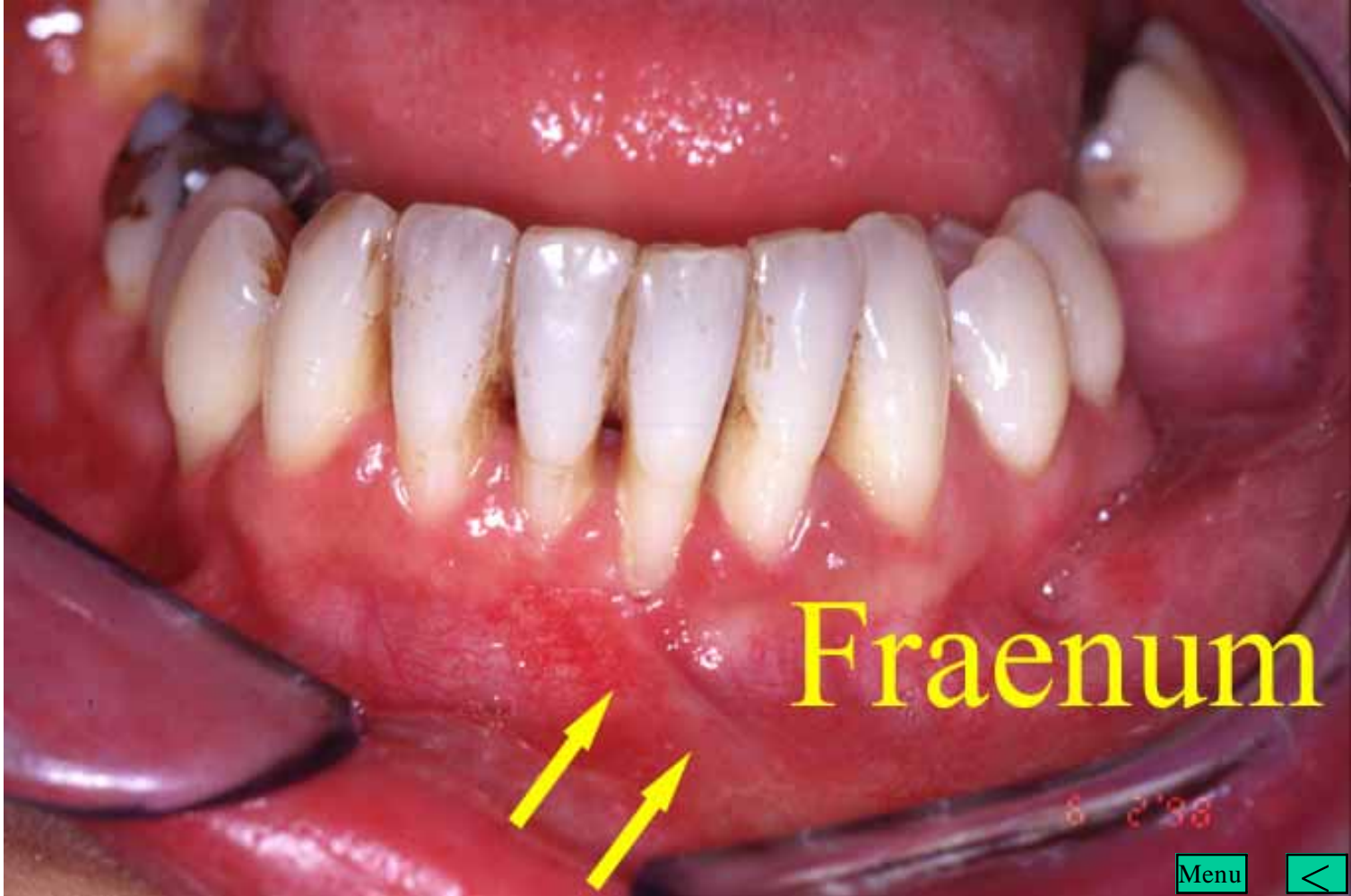
Mucogingival Surgery

Menu



Lack of Attached Gingiva



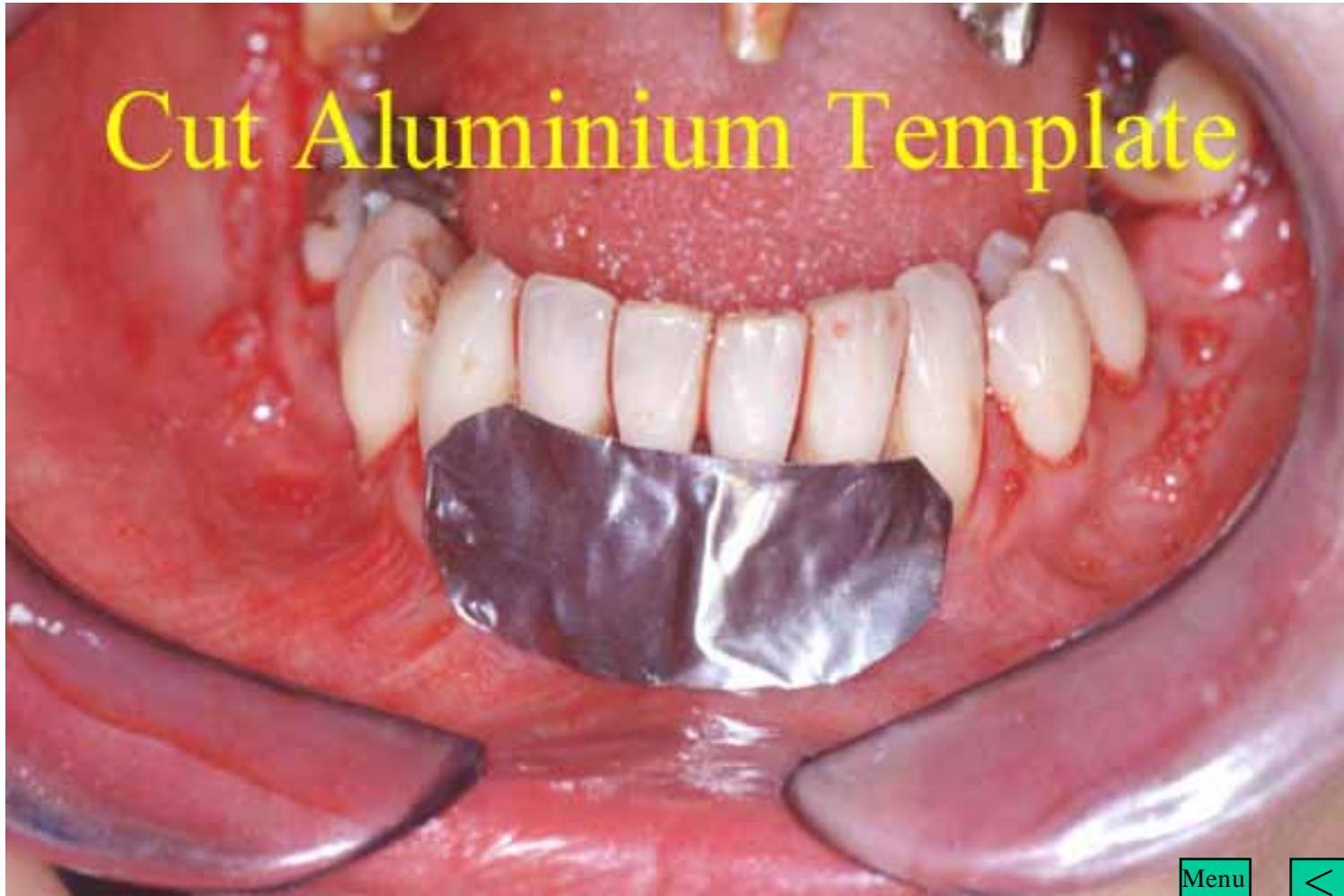

Fraenum

Menu



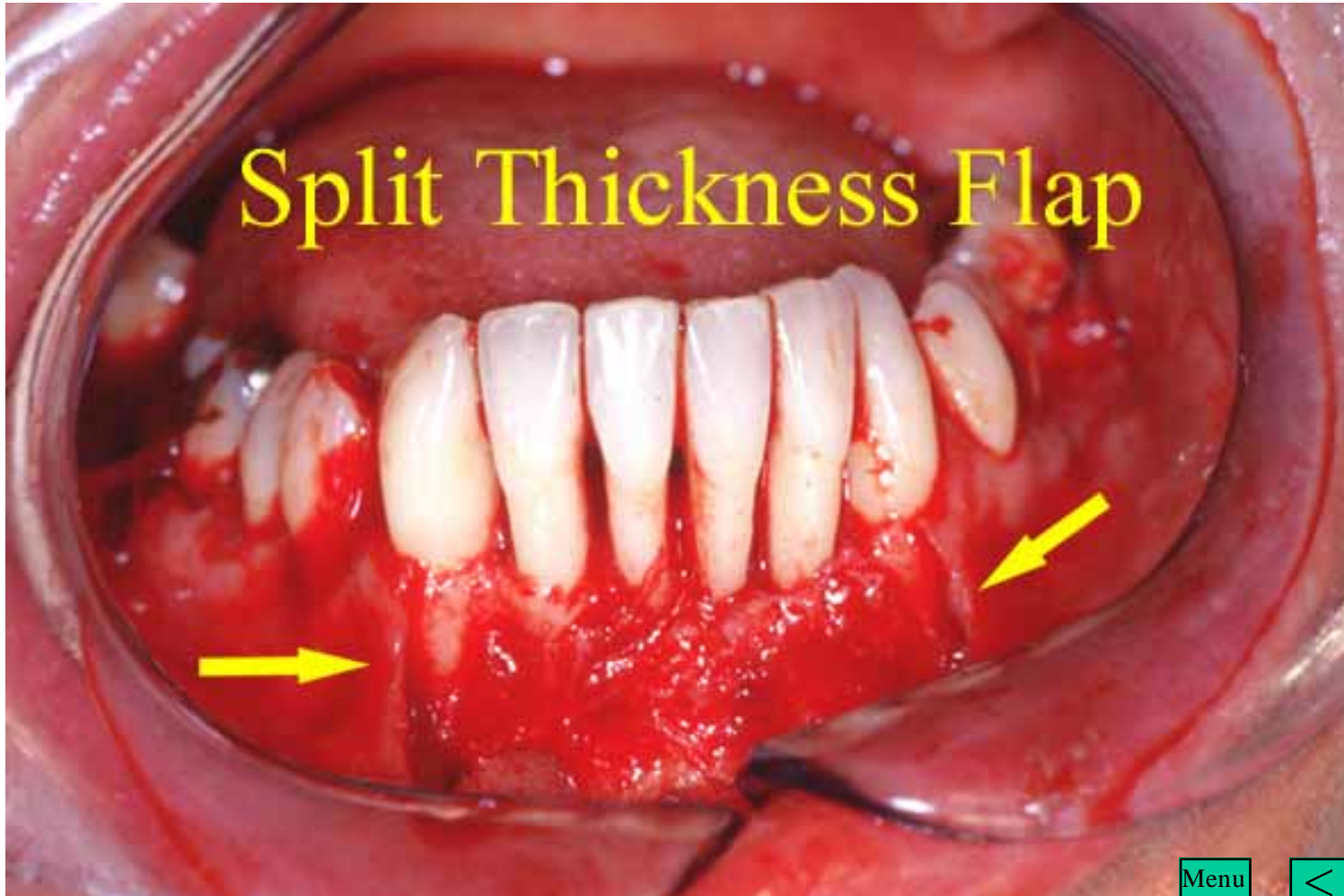
Cut Aluminium Template



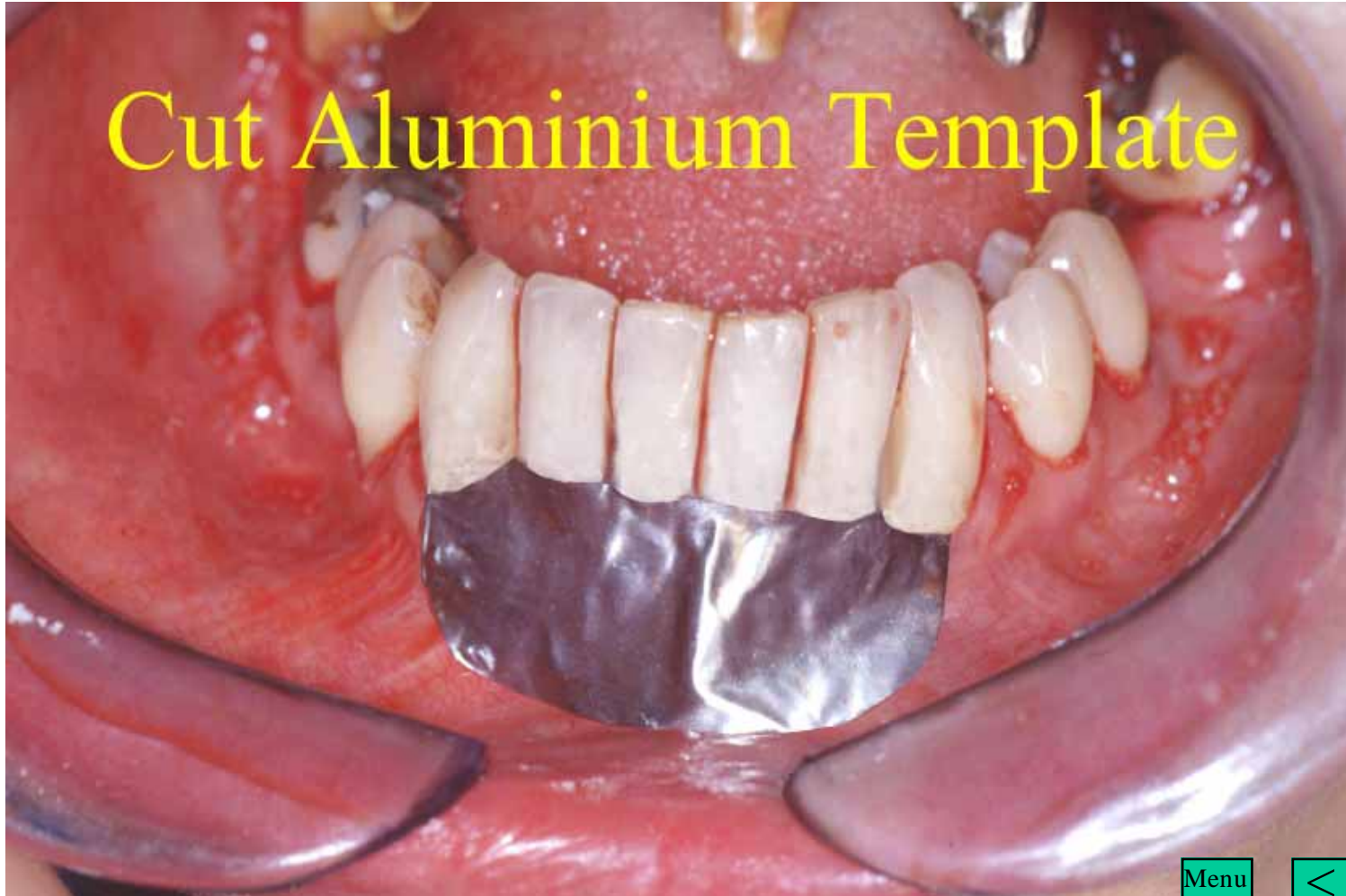Menu



Split Thickness Flap



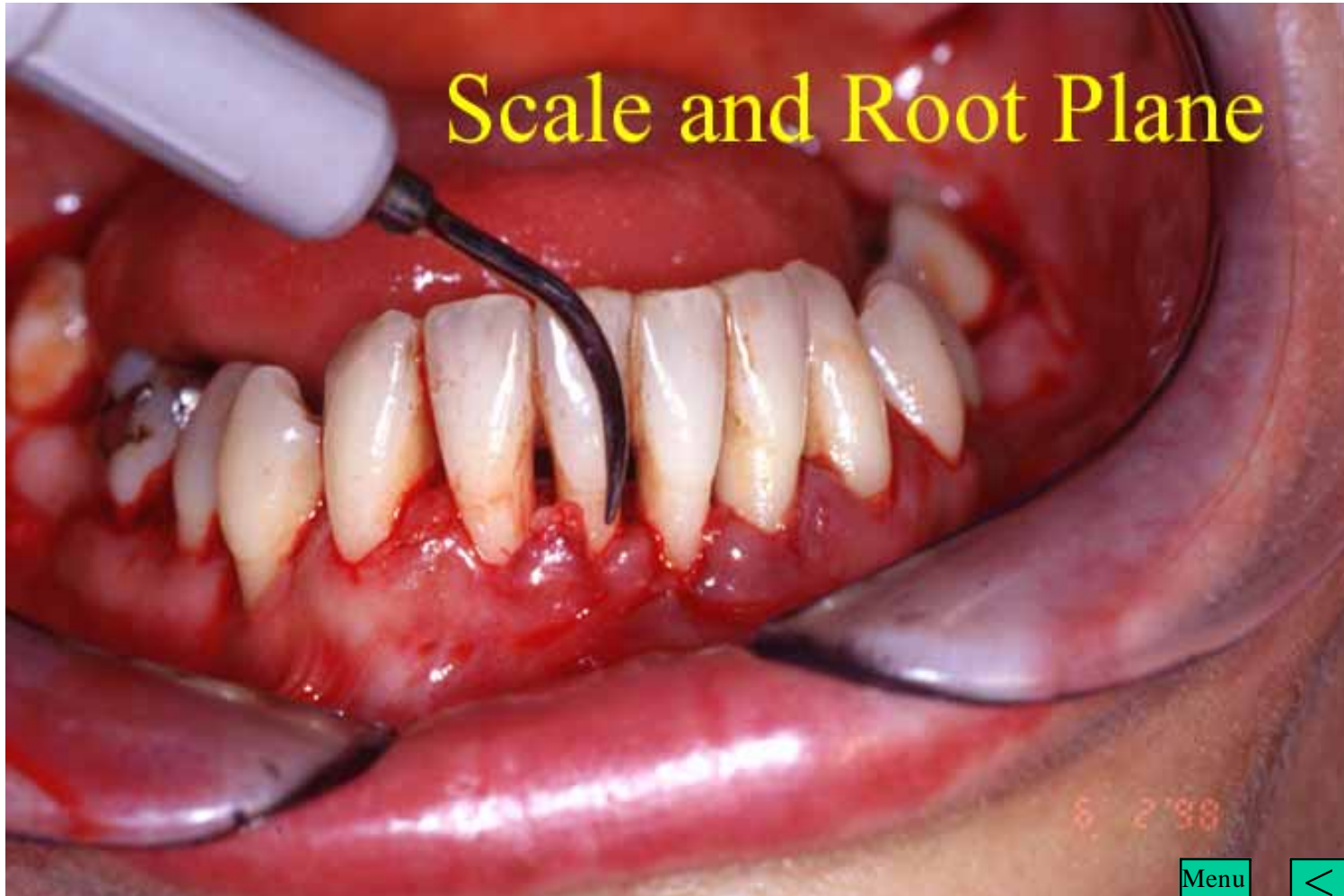Cut Aluminium Template



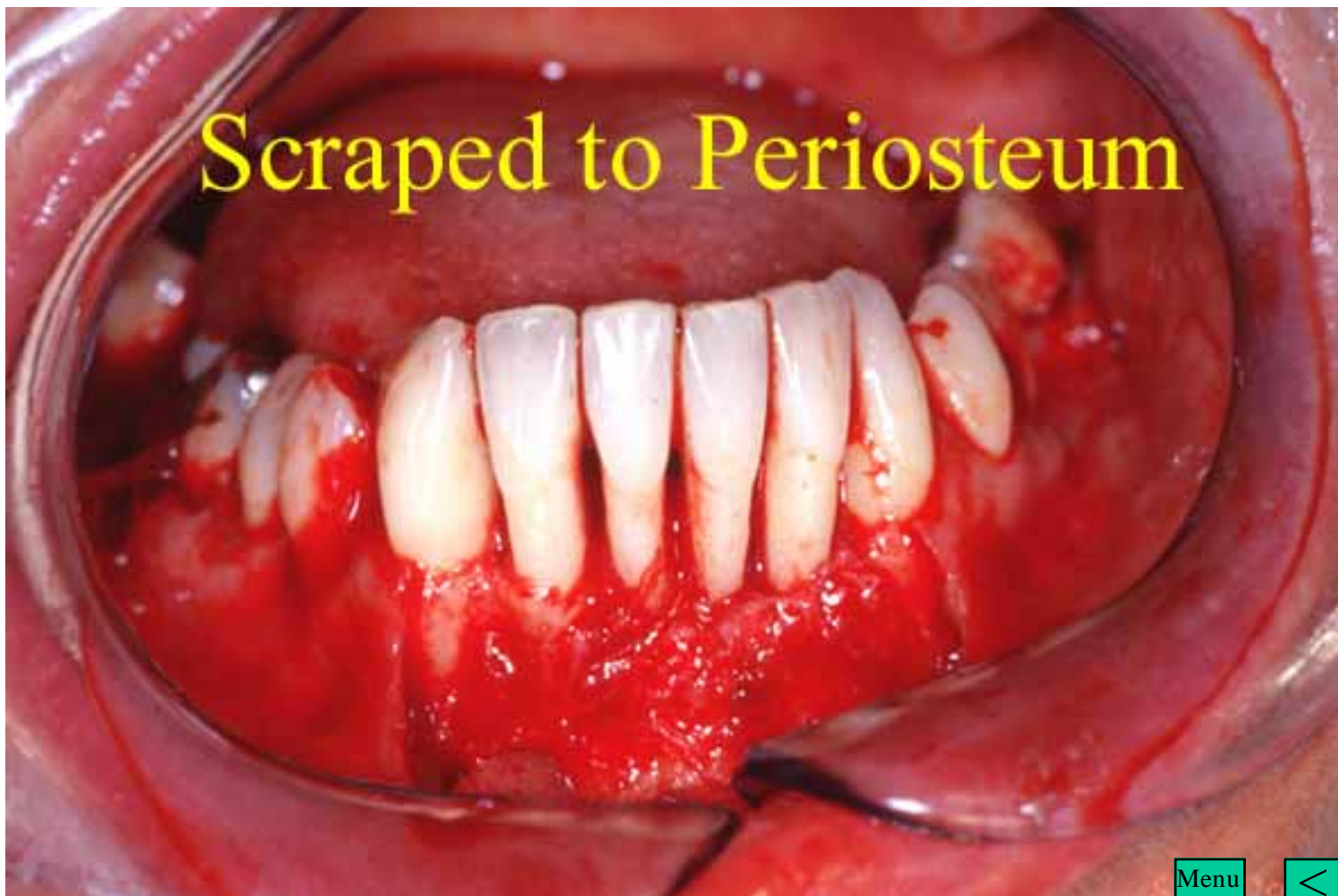
Menu



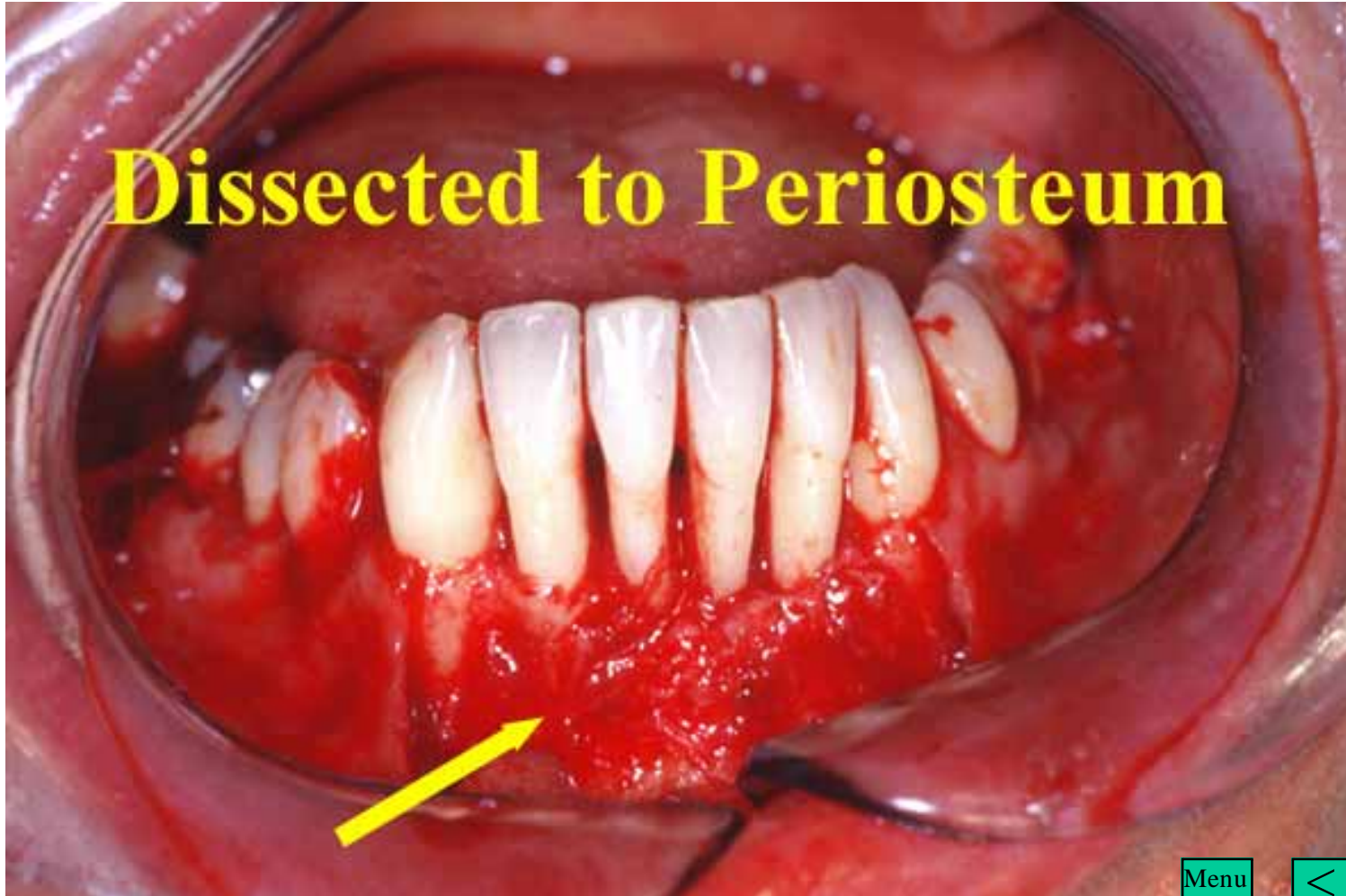
Scale and Root Plane



Scraped to Periosteum

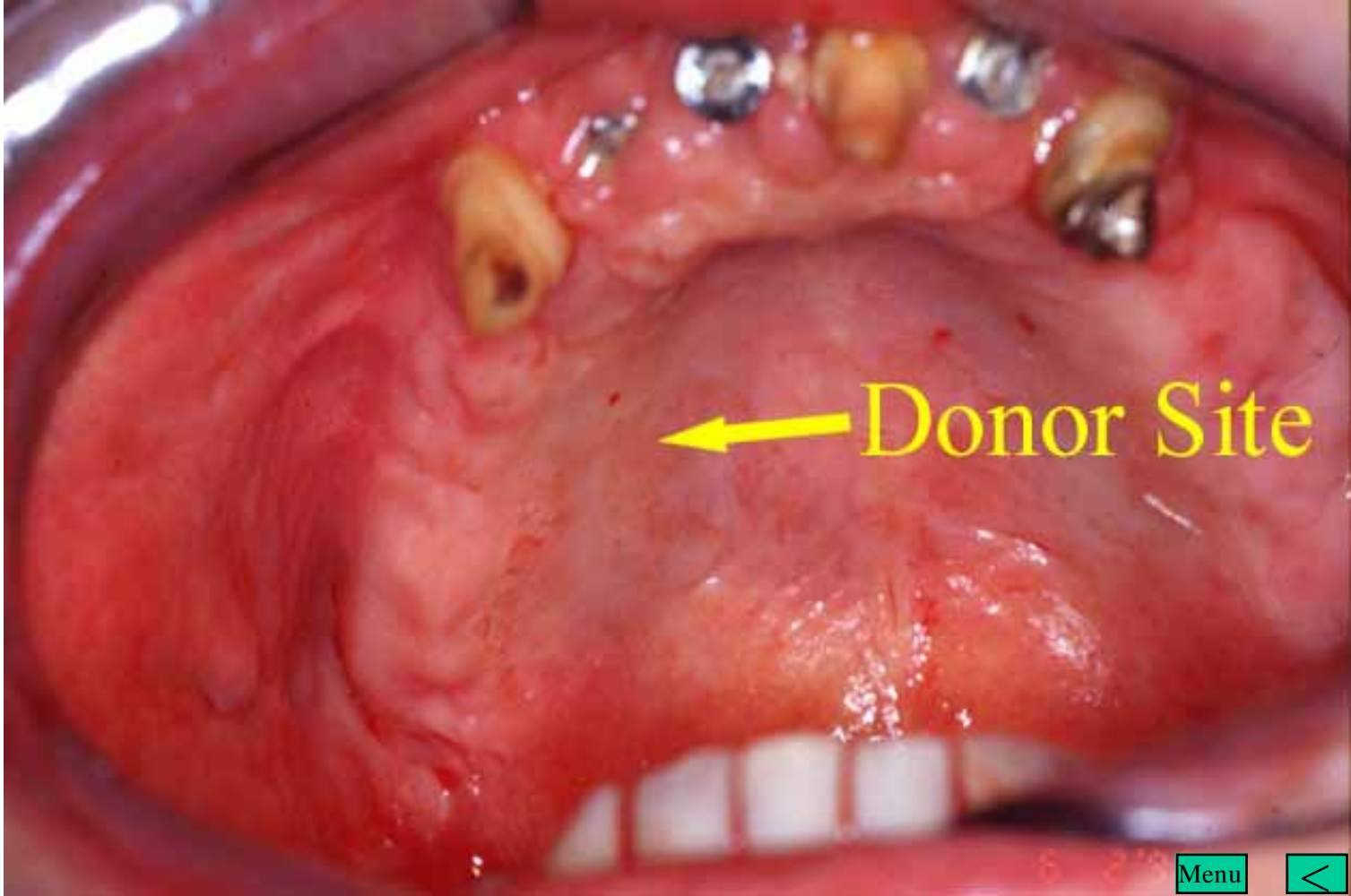


Dissected to Periosteum



Menu

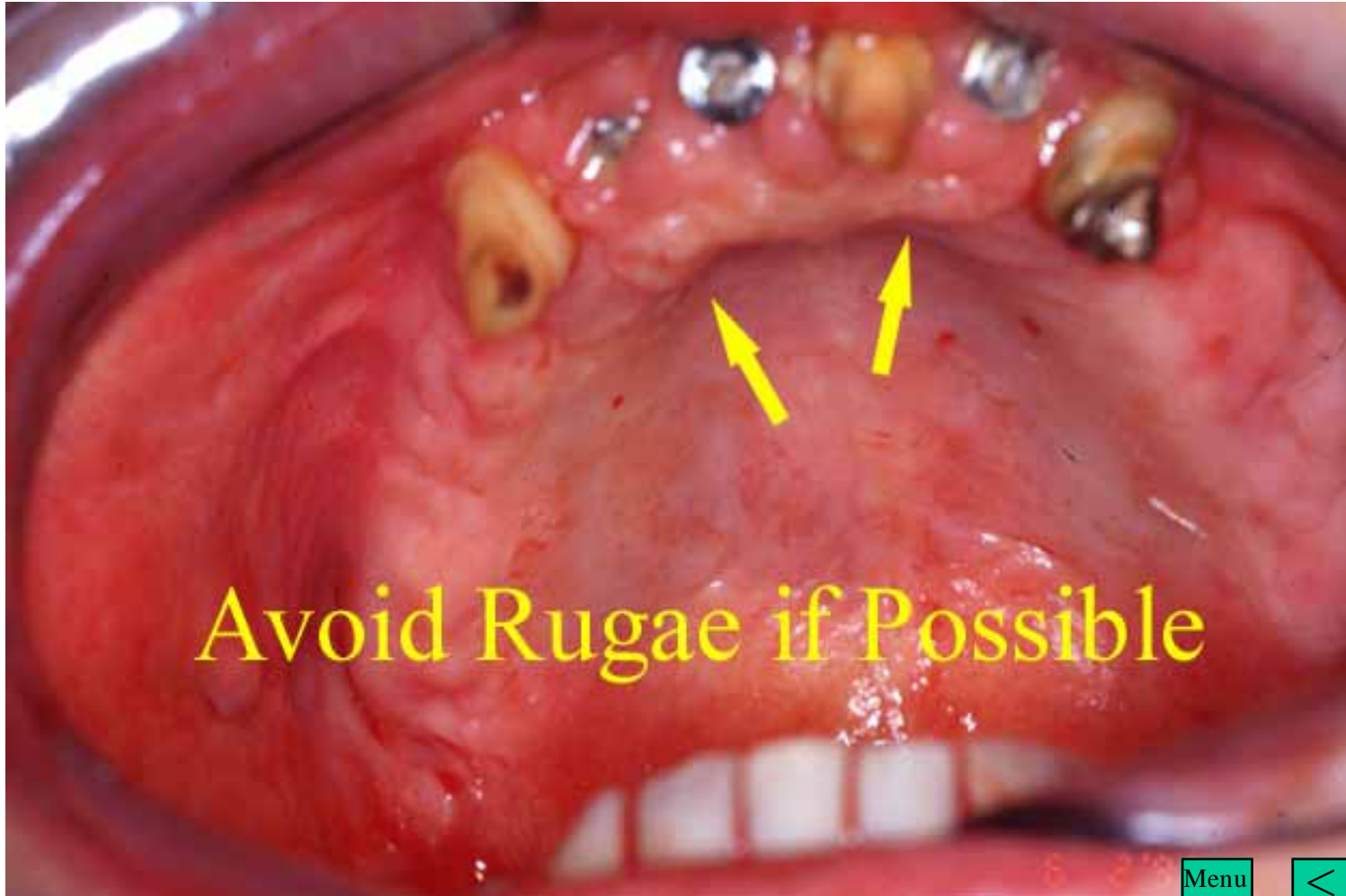




← Donor Site

Menu

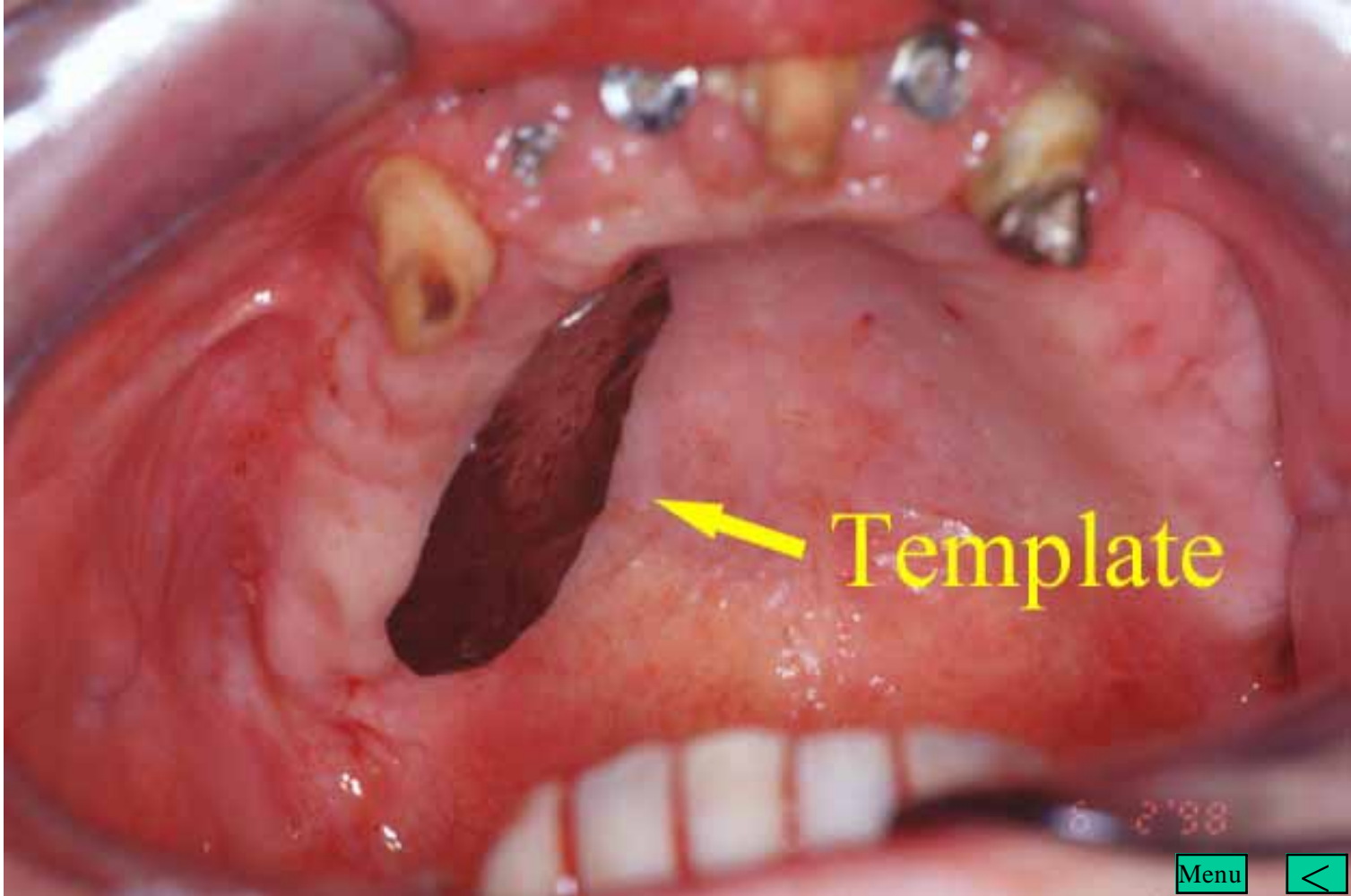


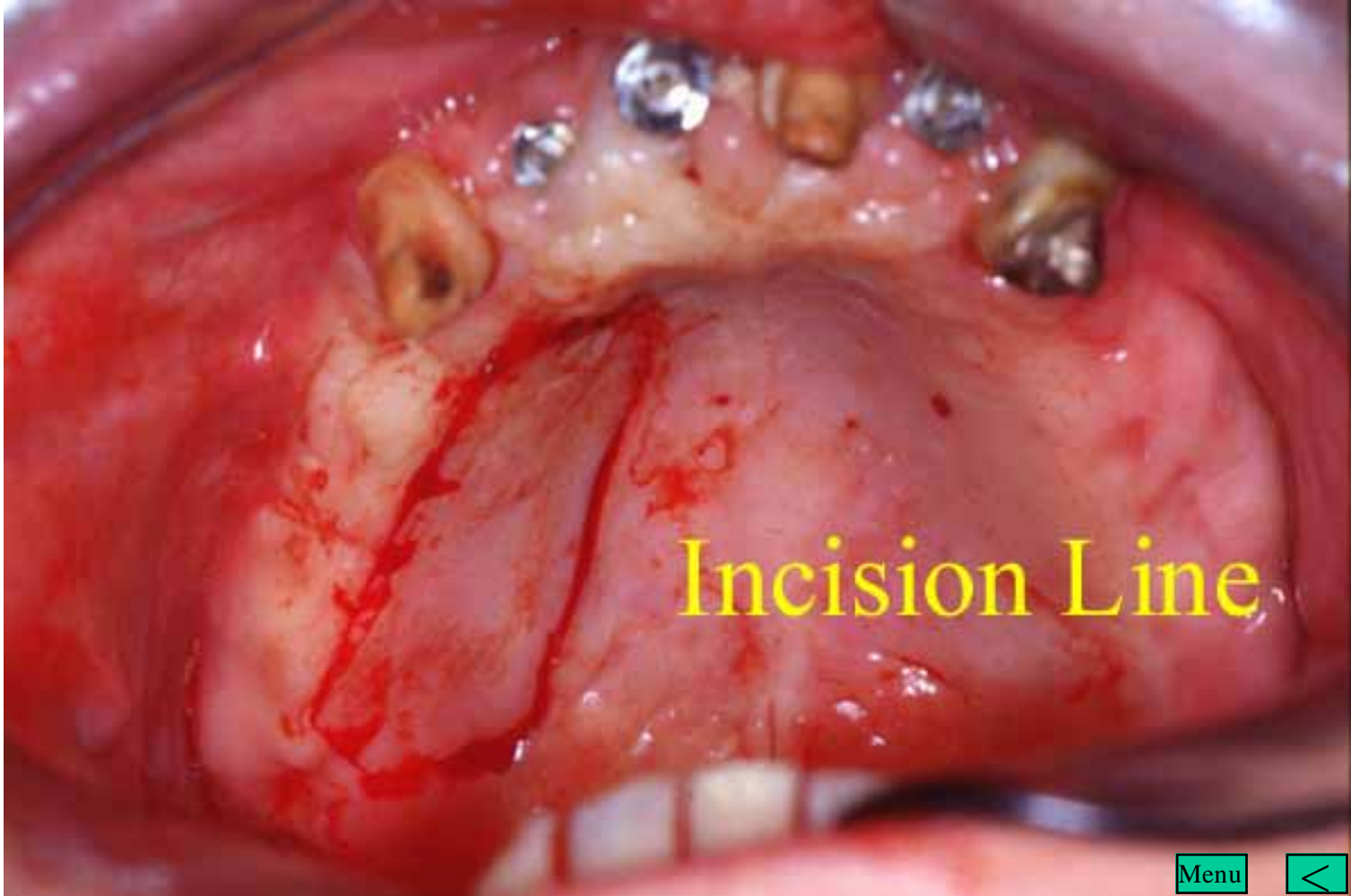

Avoid Rugae if Possible

Menu



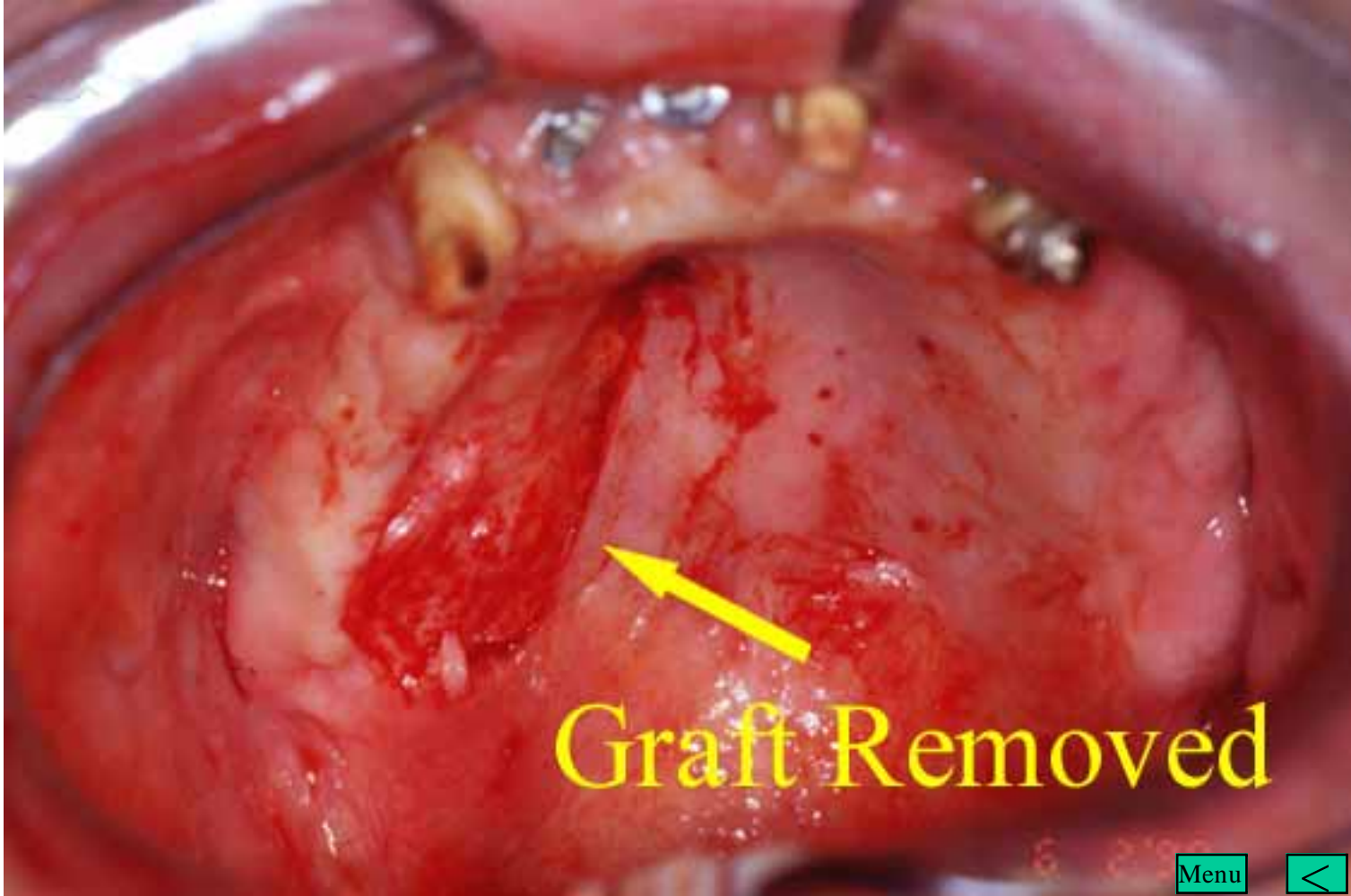




Incision Line

Menu



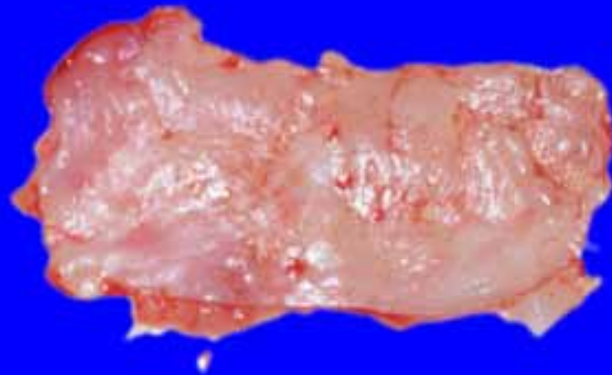


Graft Removed

Menu



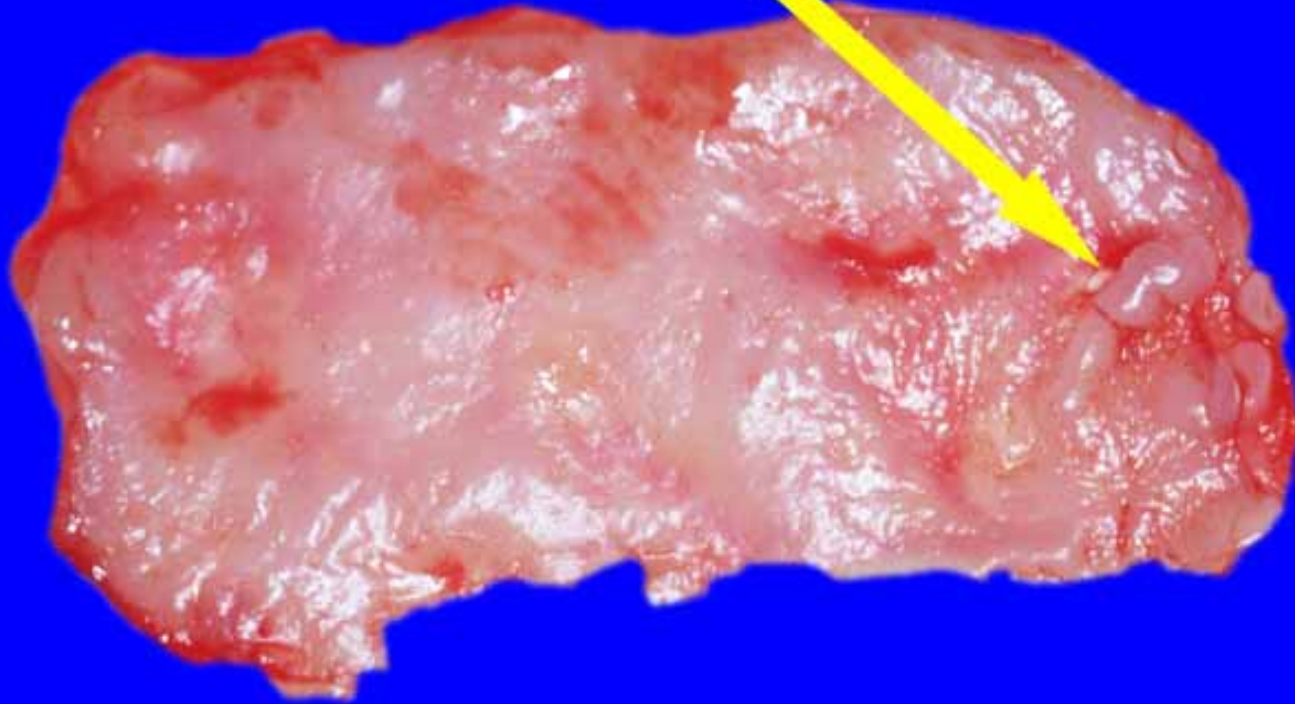
Graft with Rugae Upwards



Menu



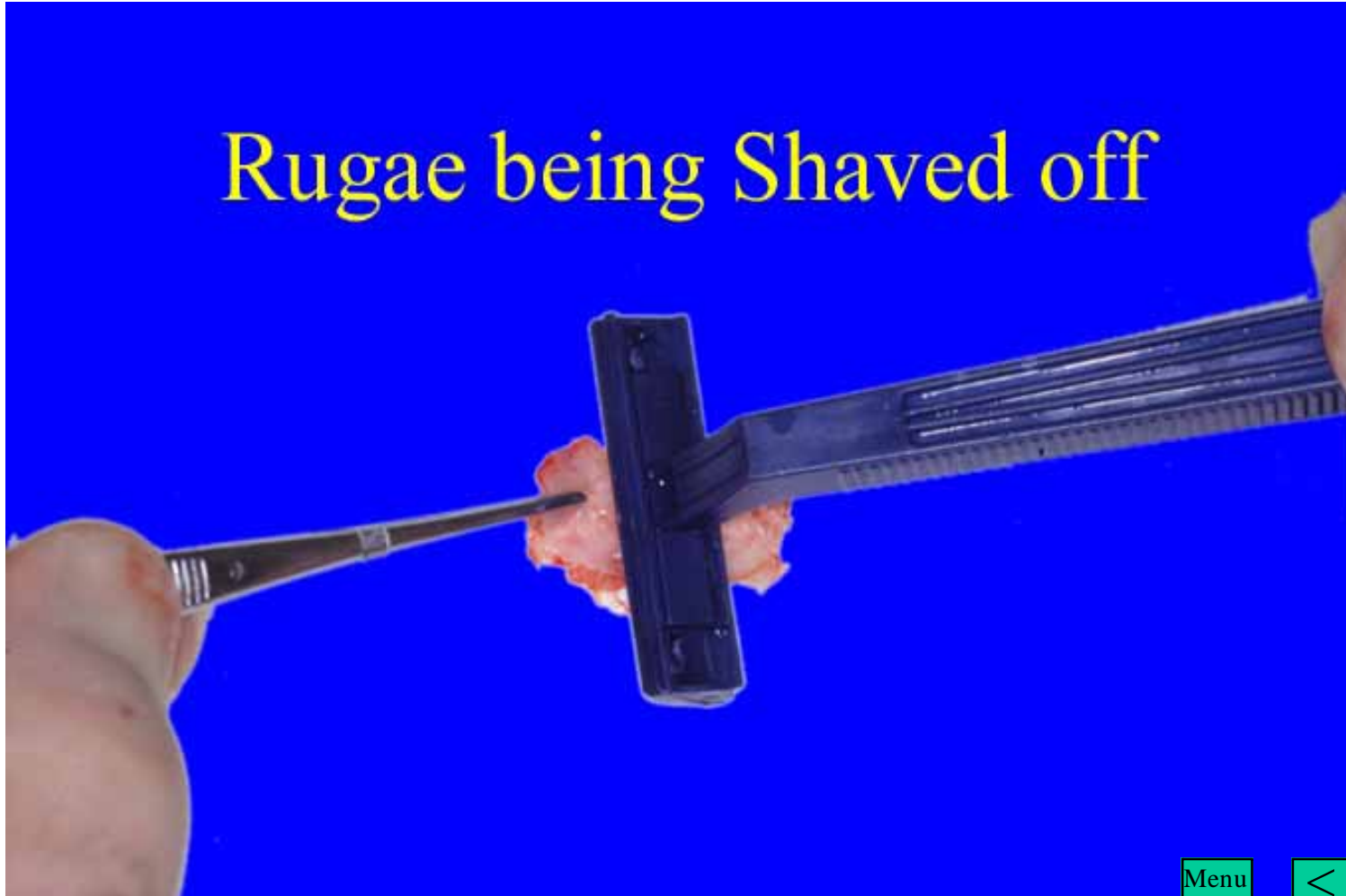Rugae



Menu



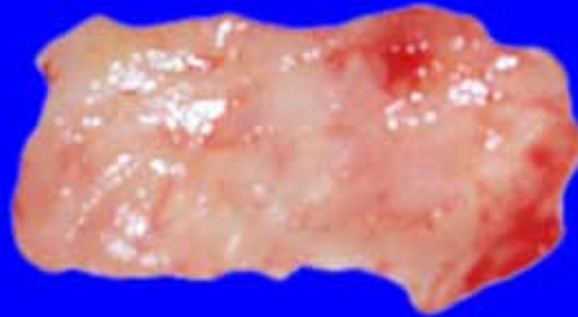Rugae being Shaved off



Menu




Under-surface of Graft



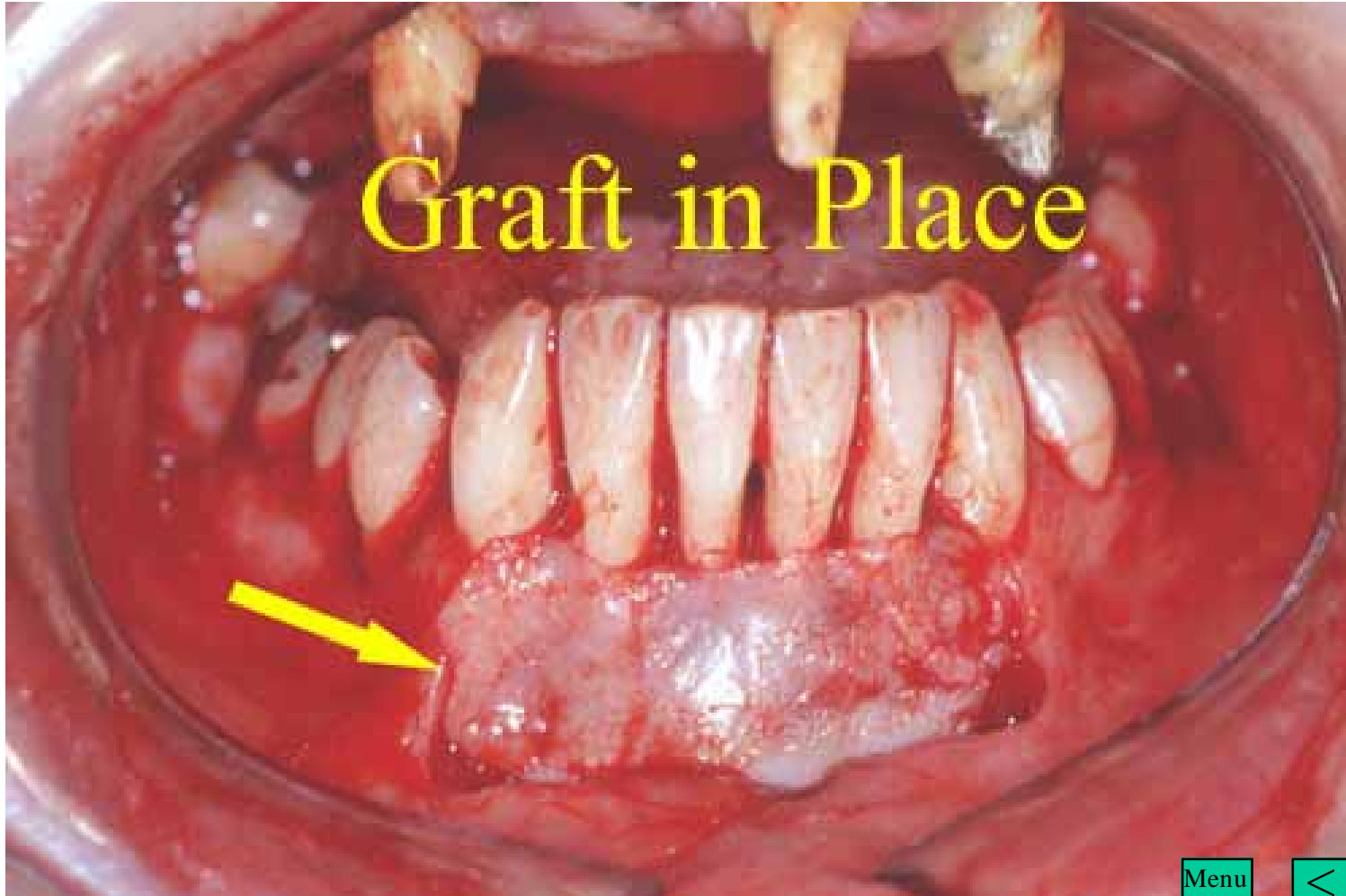
Menu



Fat and Connective Tissue being Shaved



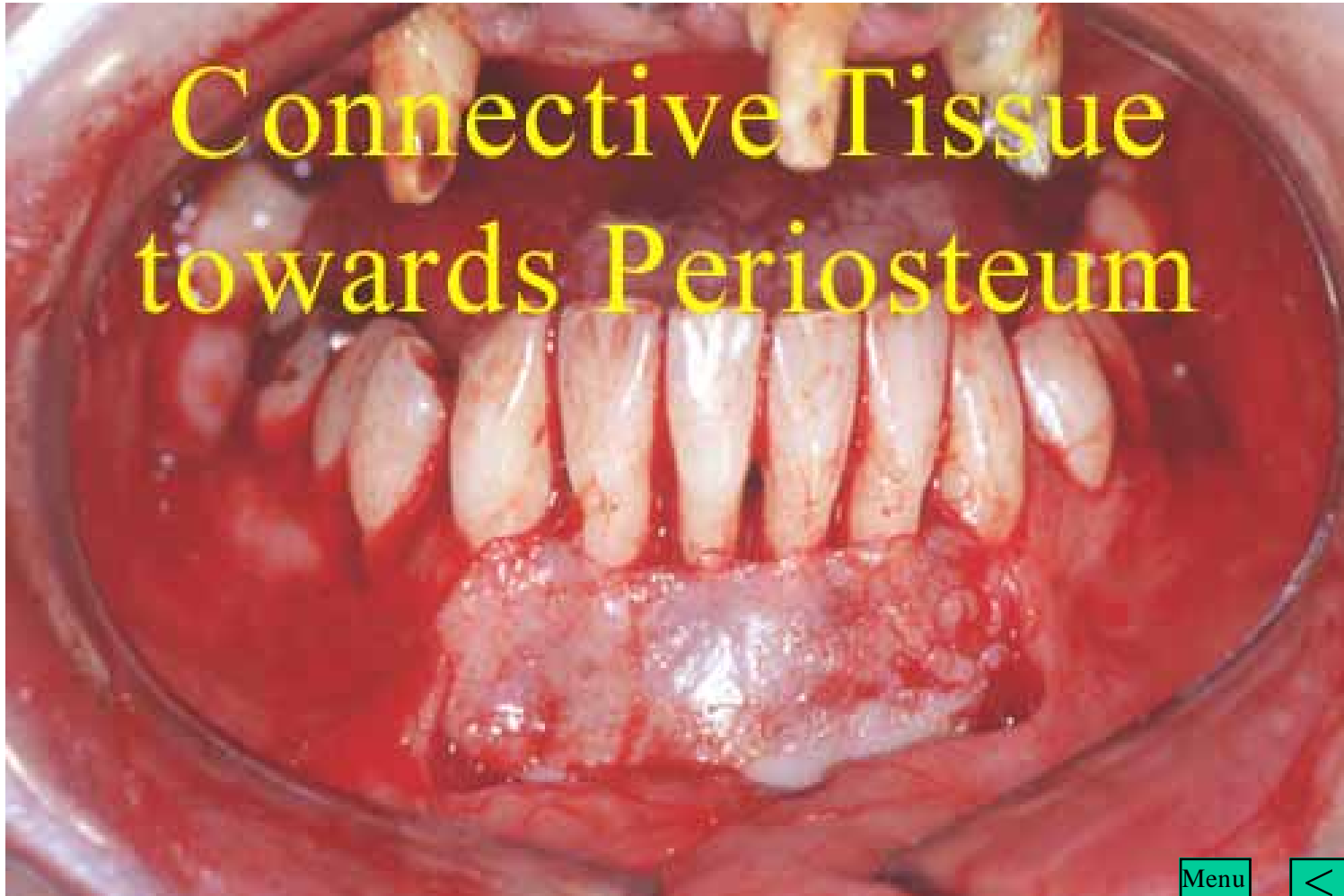Graft in Place



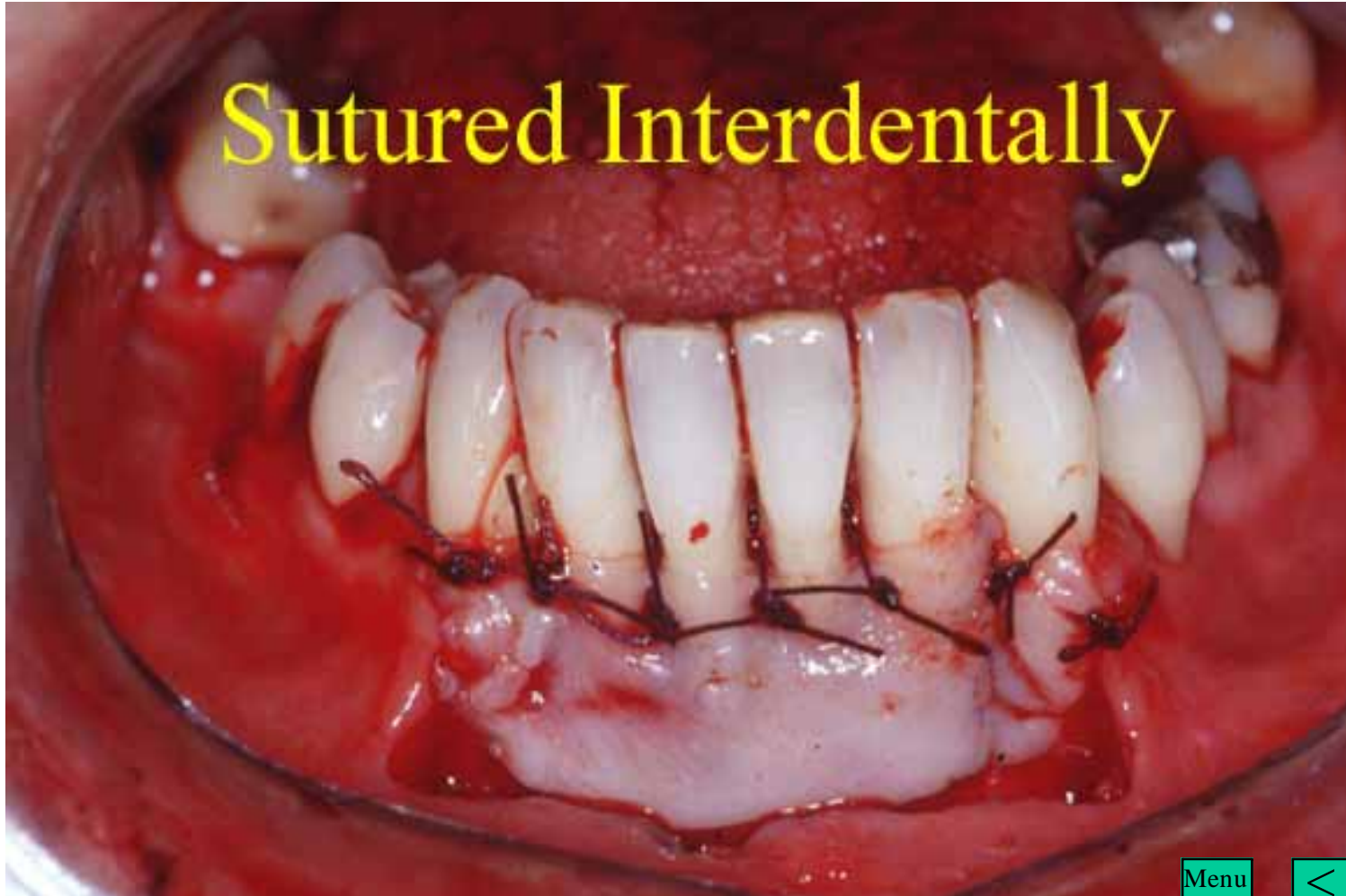Menu



Connective Tissue towards Periosteum



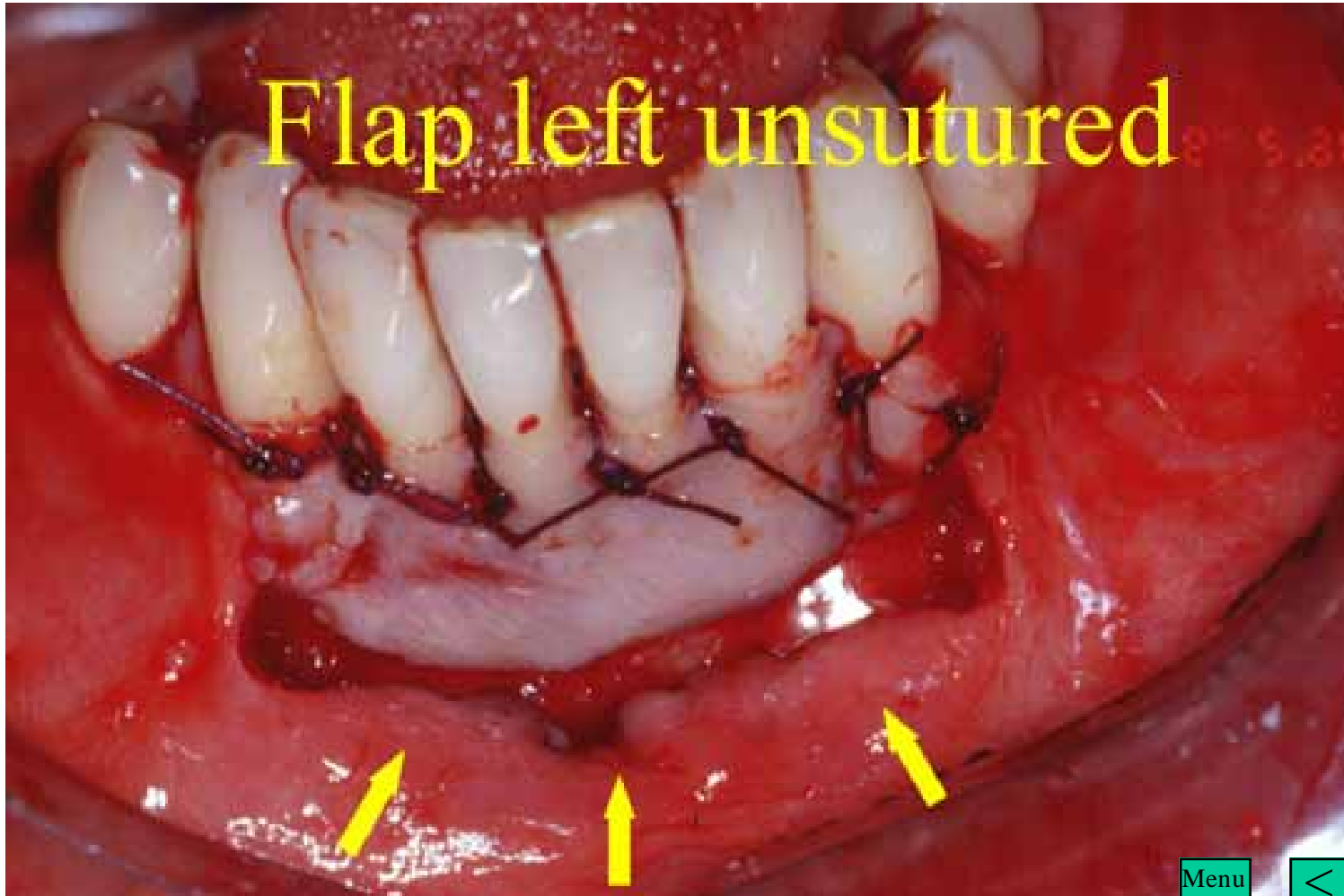
Sutured Interdentally



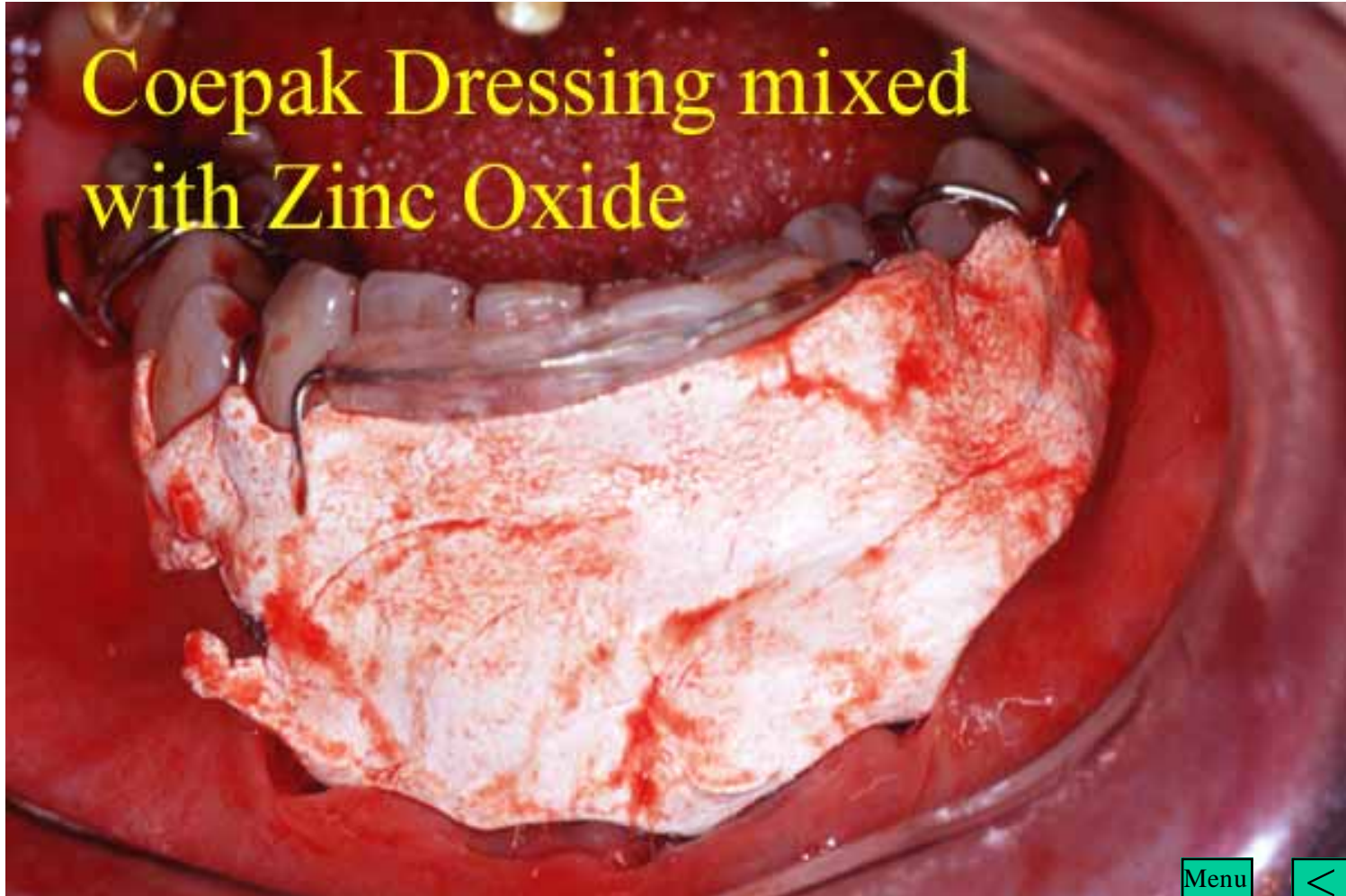Menu



Flap left unsutured

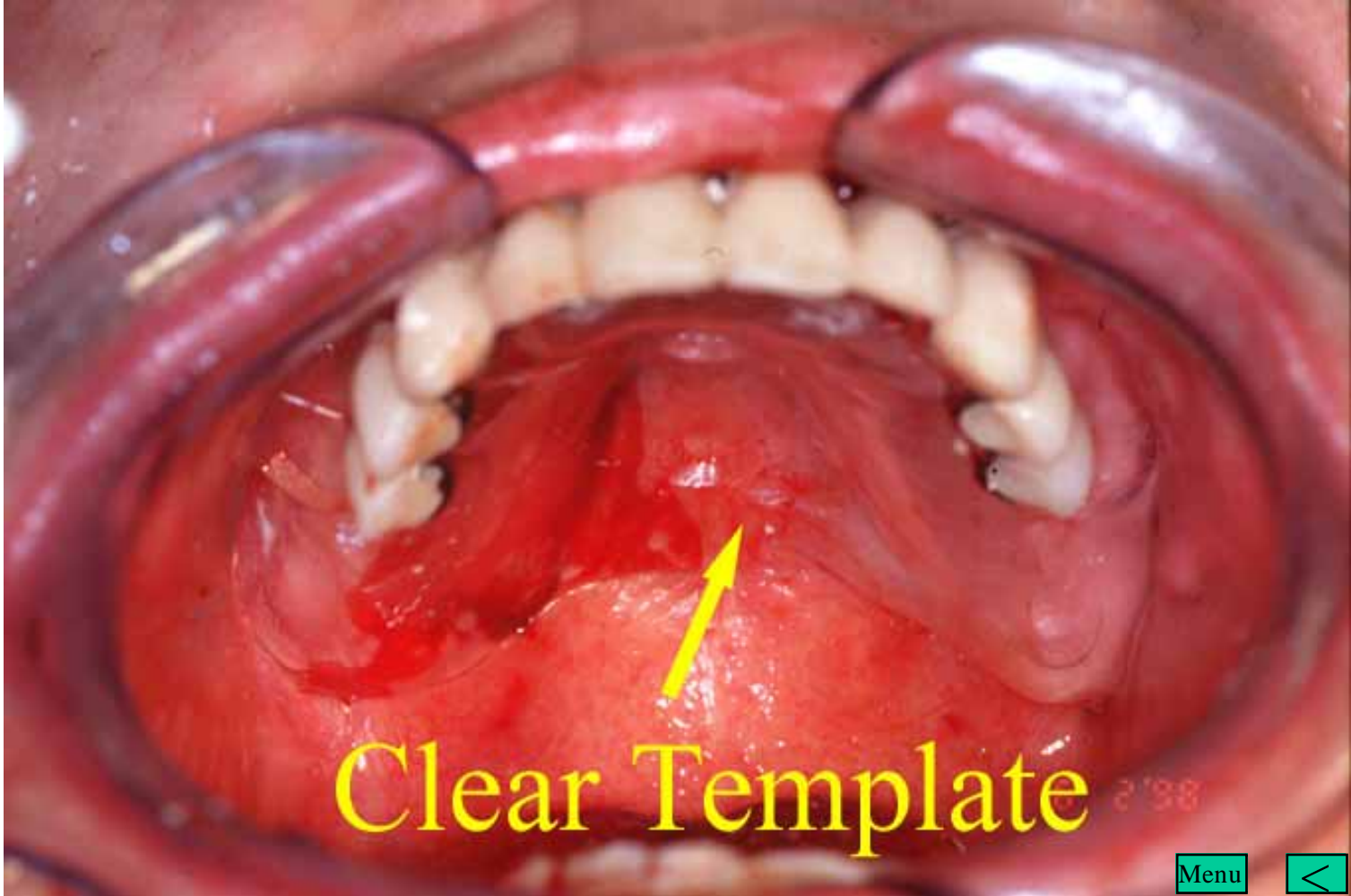


Coepak Dressing mixed with Zinc Oxide



Menu



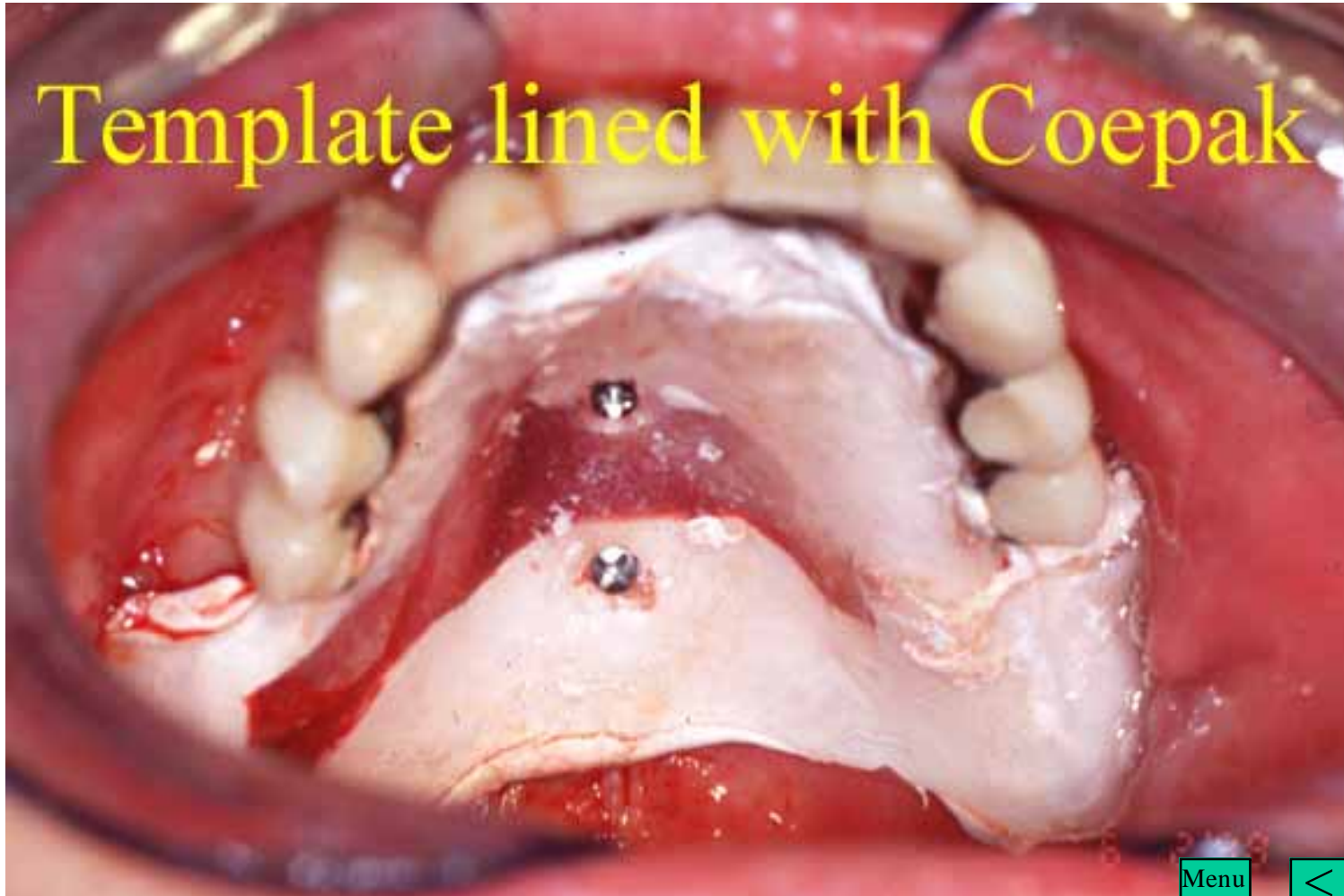


Clear Template

Menu



Template lined with Coepak



Menu



Bone Screws

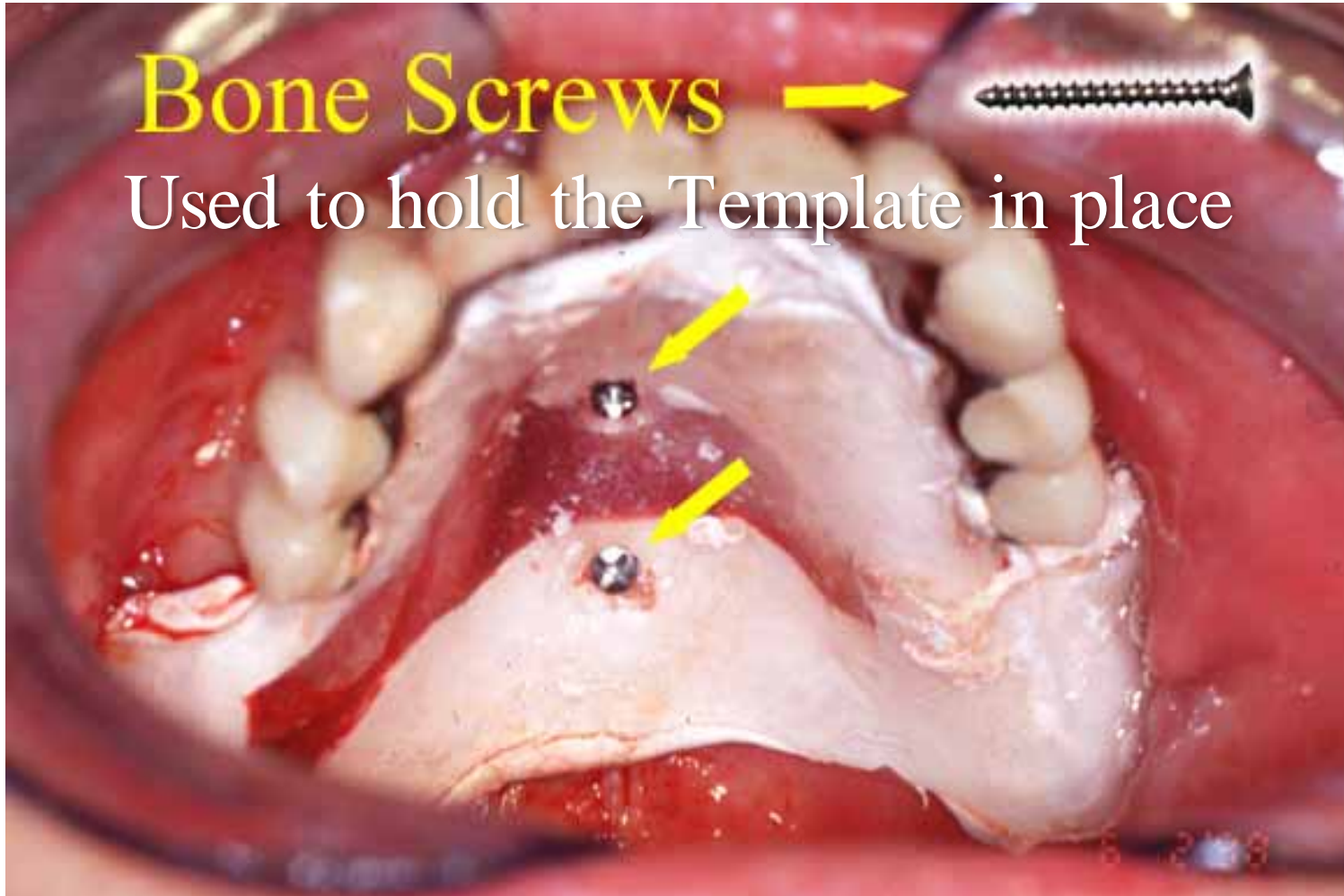


Menu



Bone Screws

Used to hold the Template in place



Bone Screws



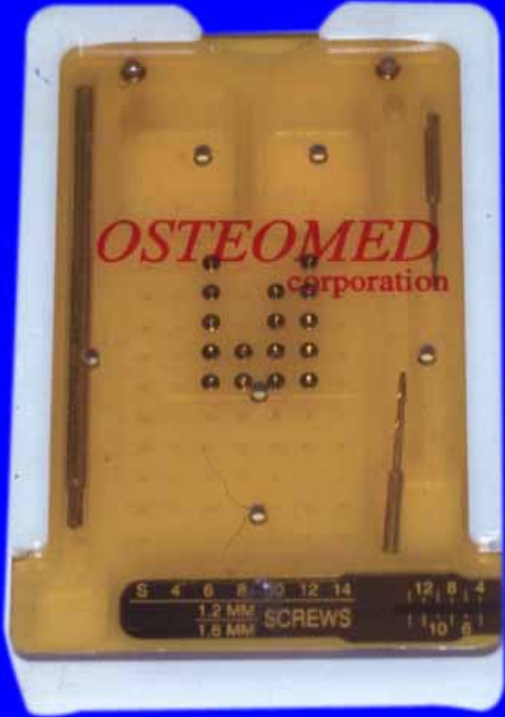Menu






Menu





Menu







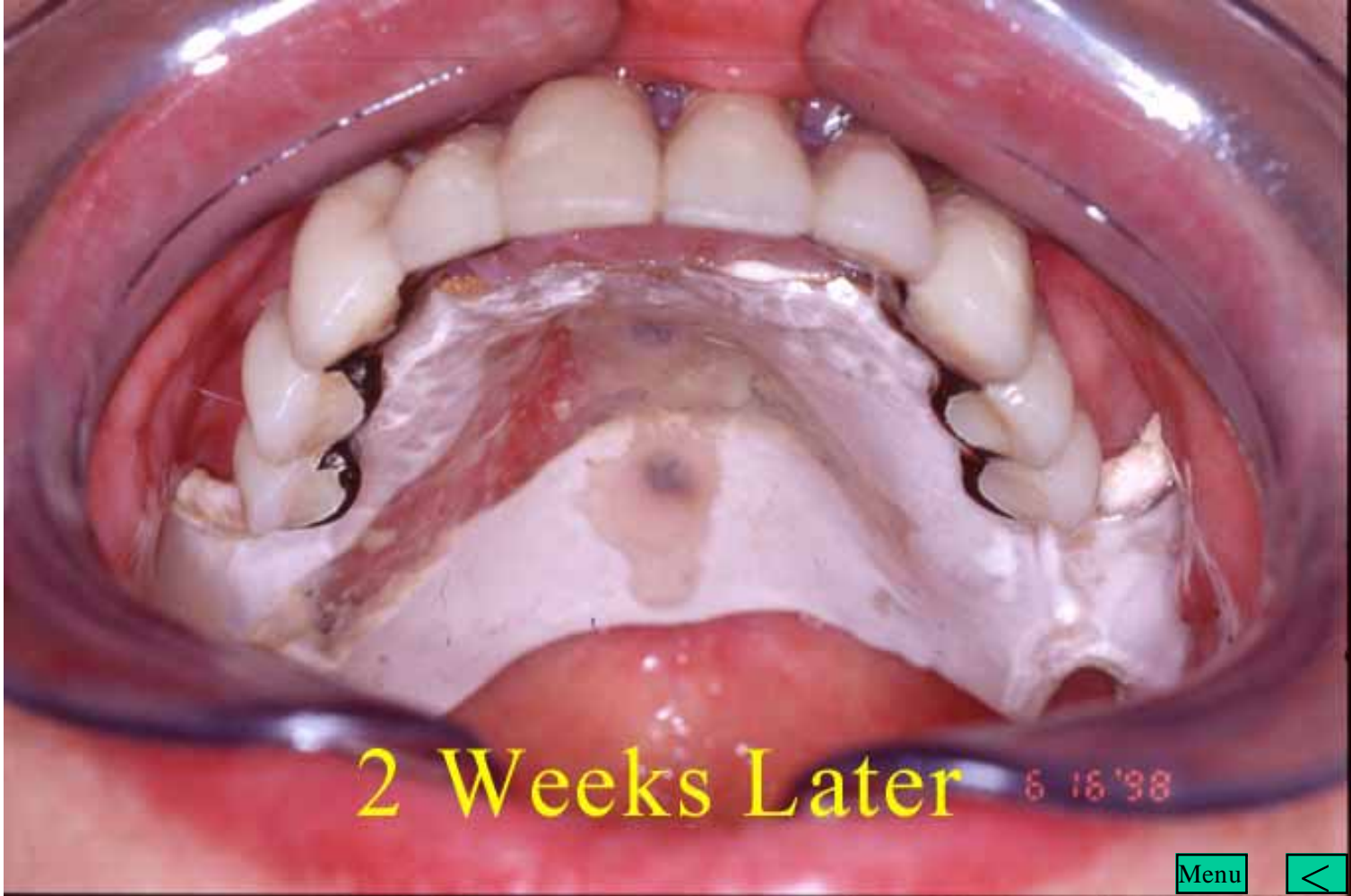Menu





Menu



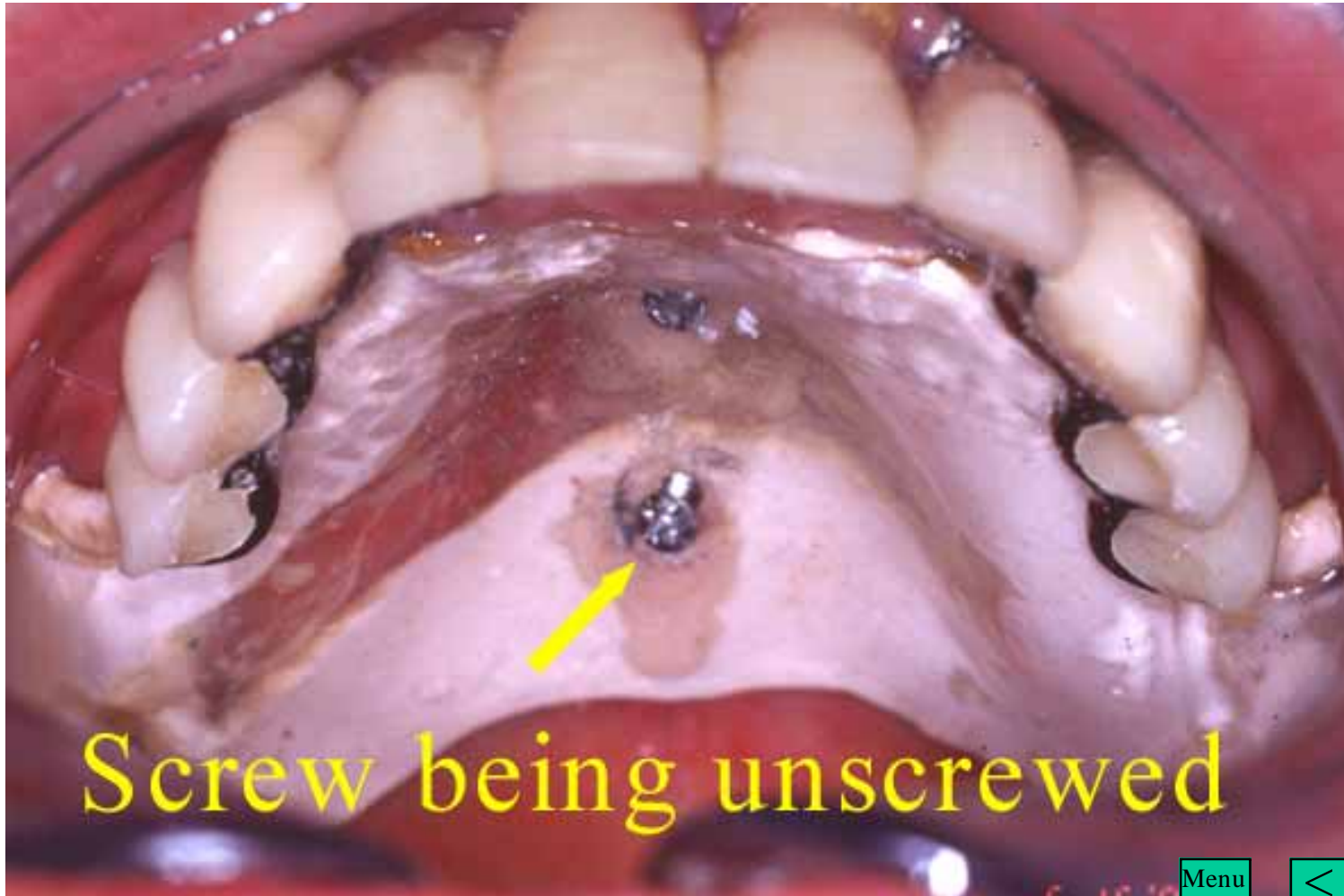

2 Weeks Later

6 16 '98

Menu

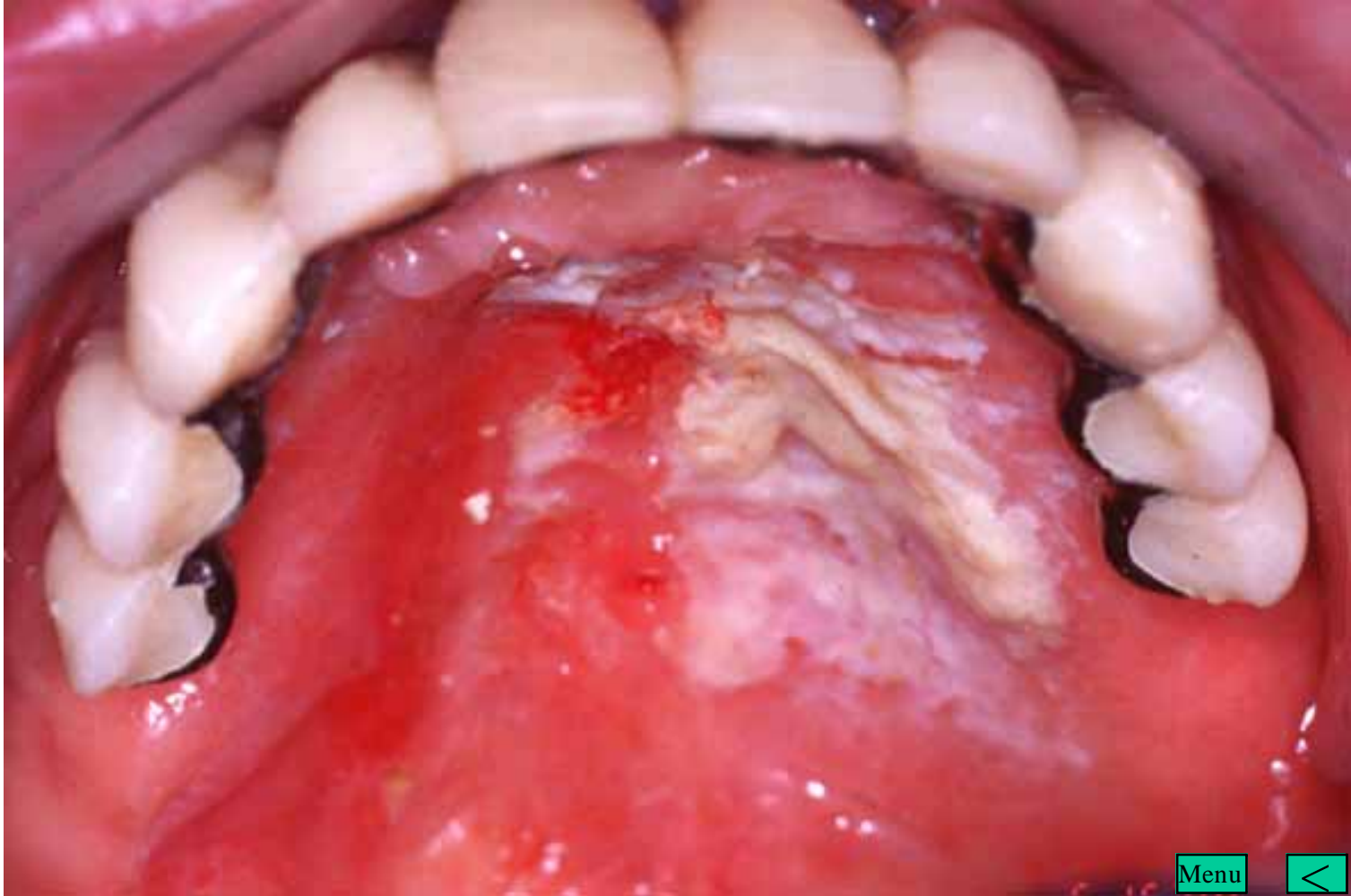



Screw being unscrewed

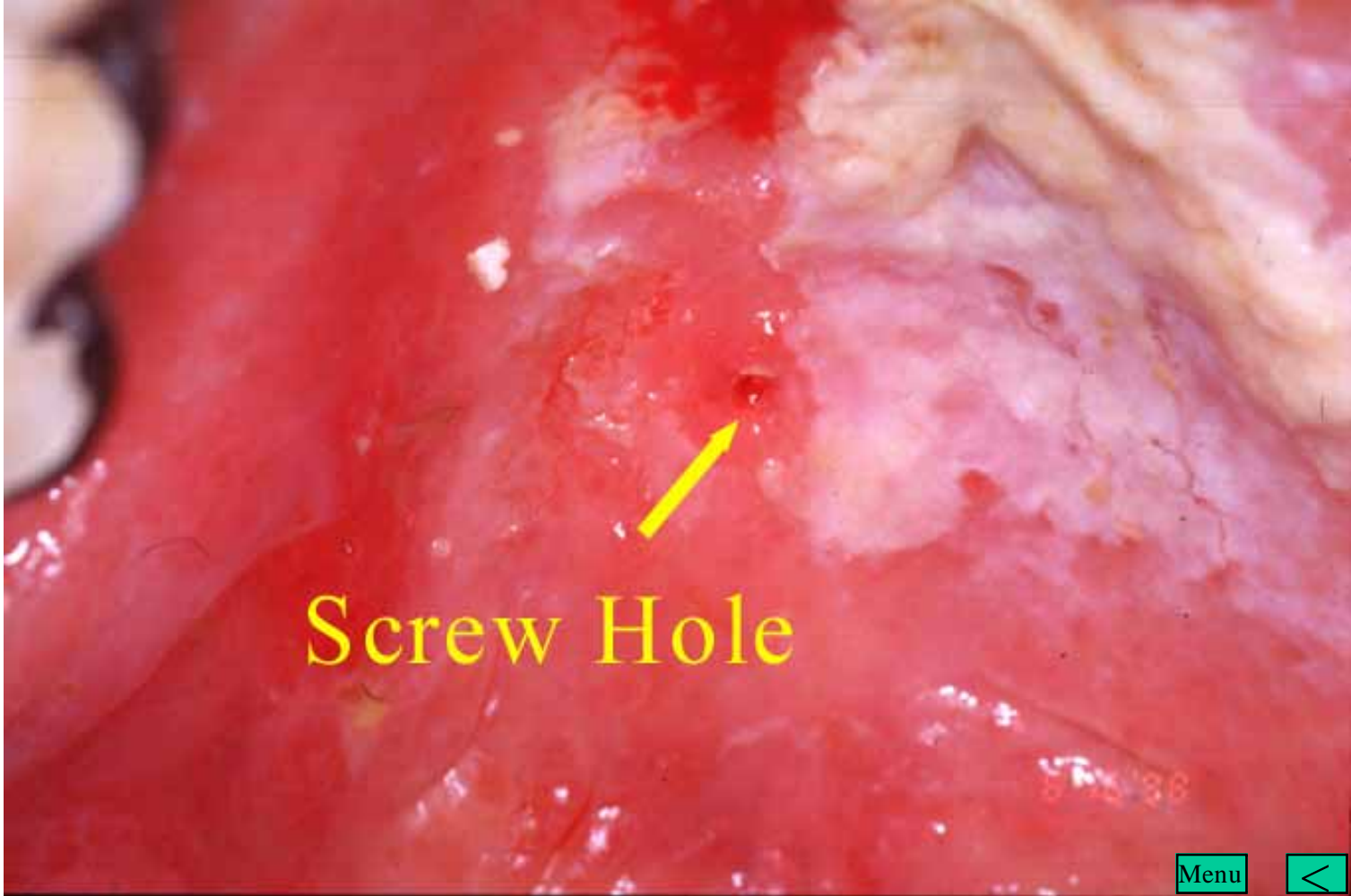
Menu





Menu

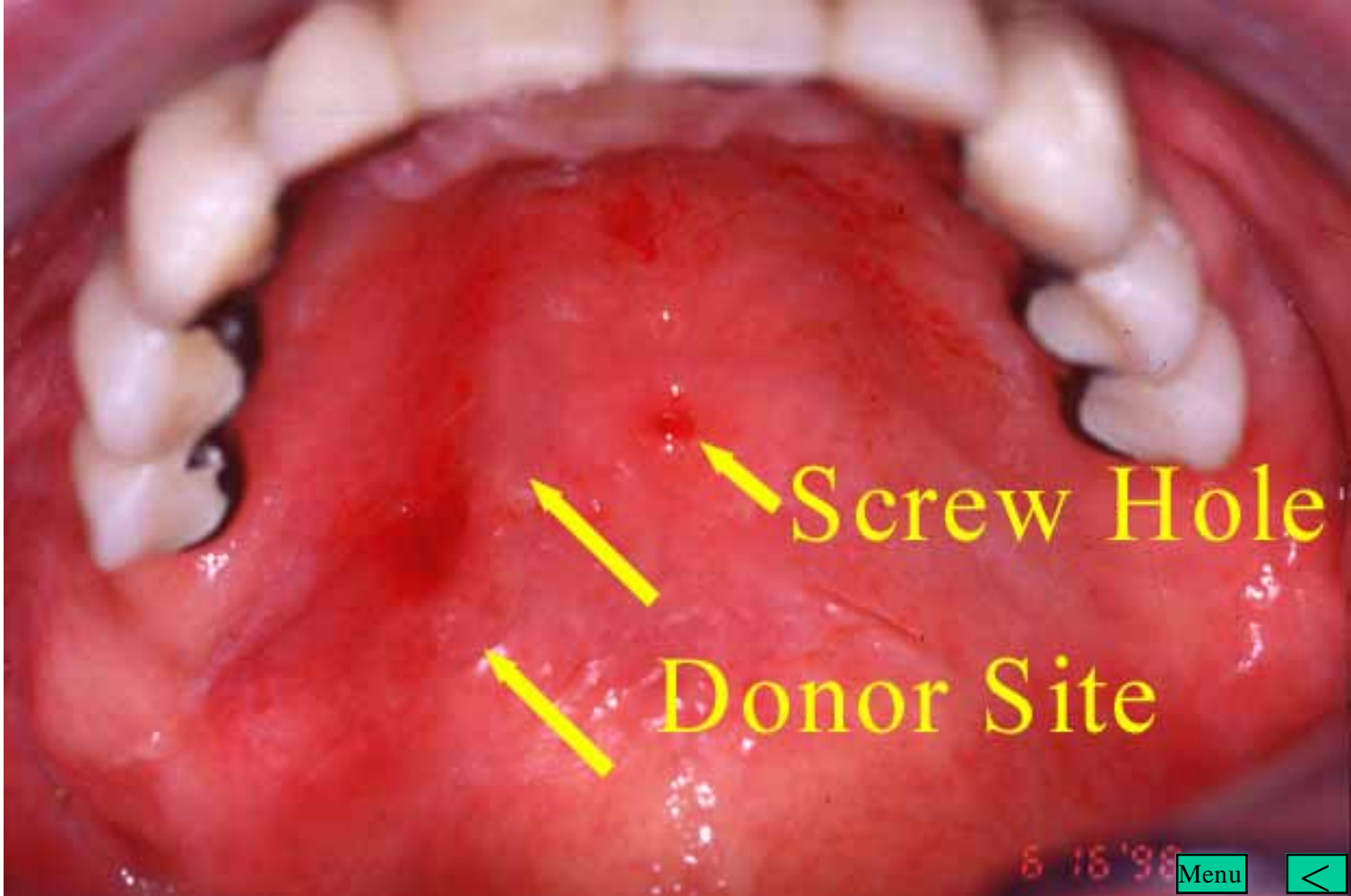




Screw Hole

Menu





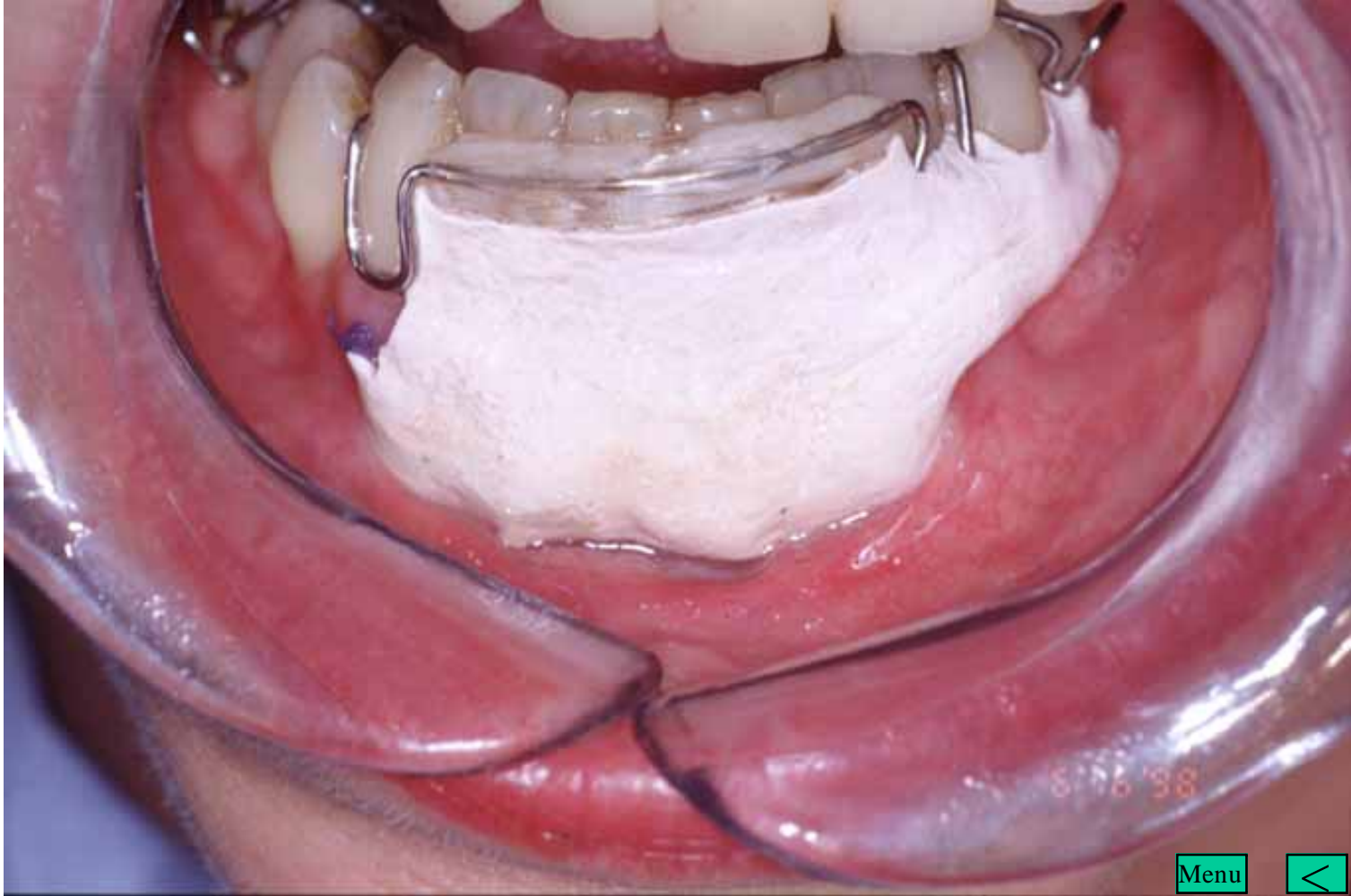Screw Hole

Donor Site

6 16 '96

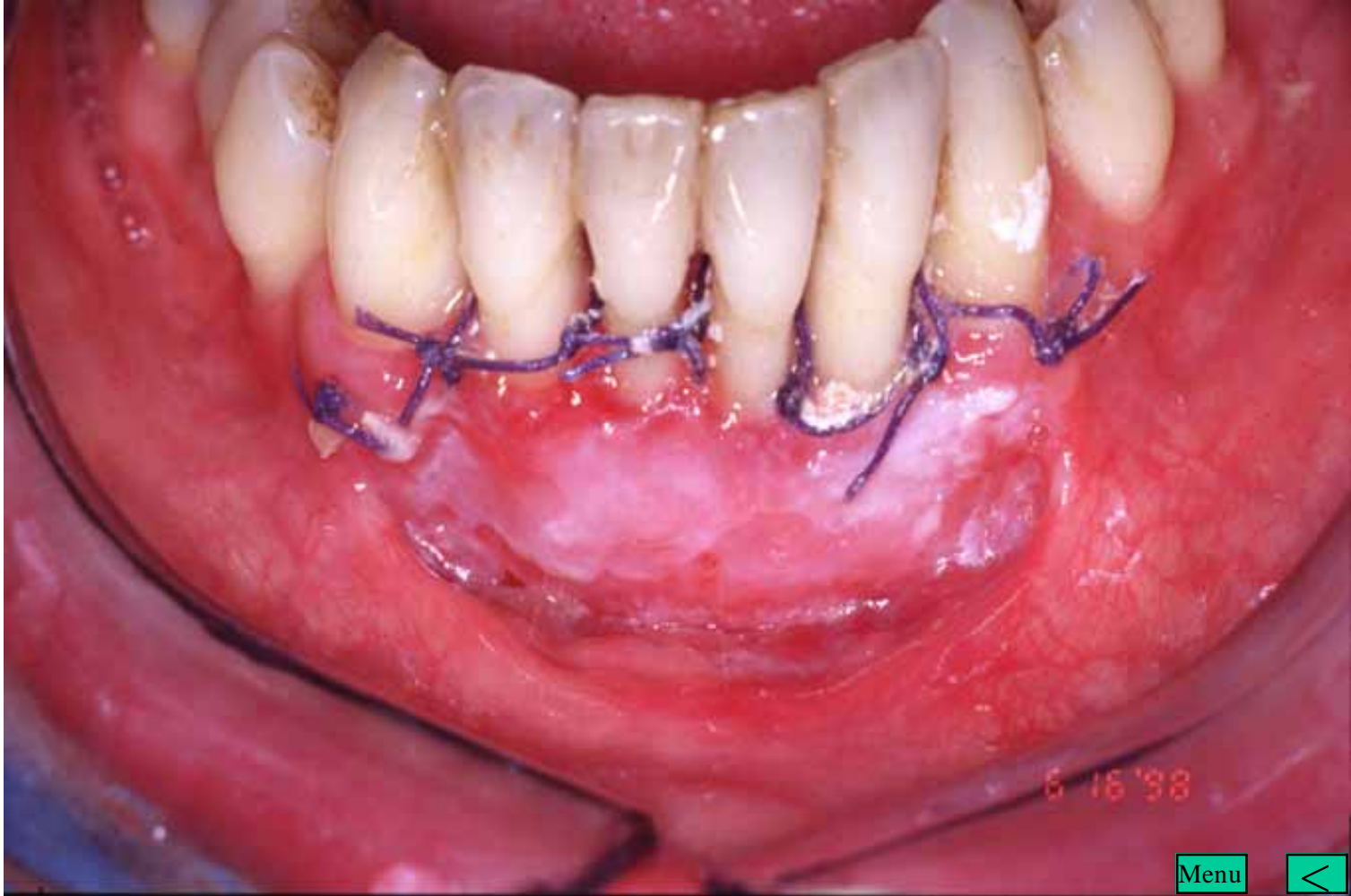Menu





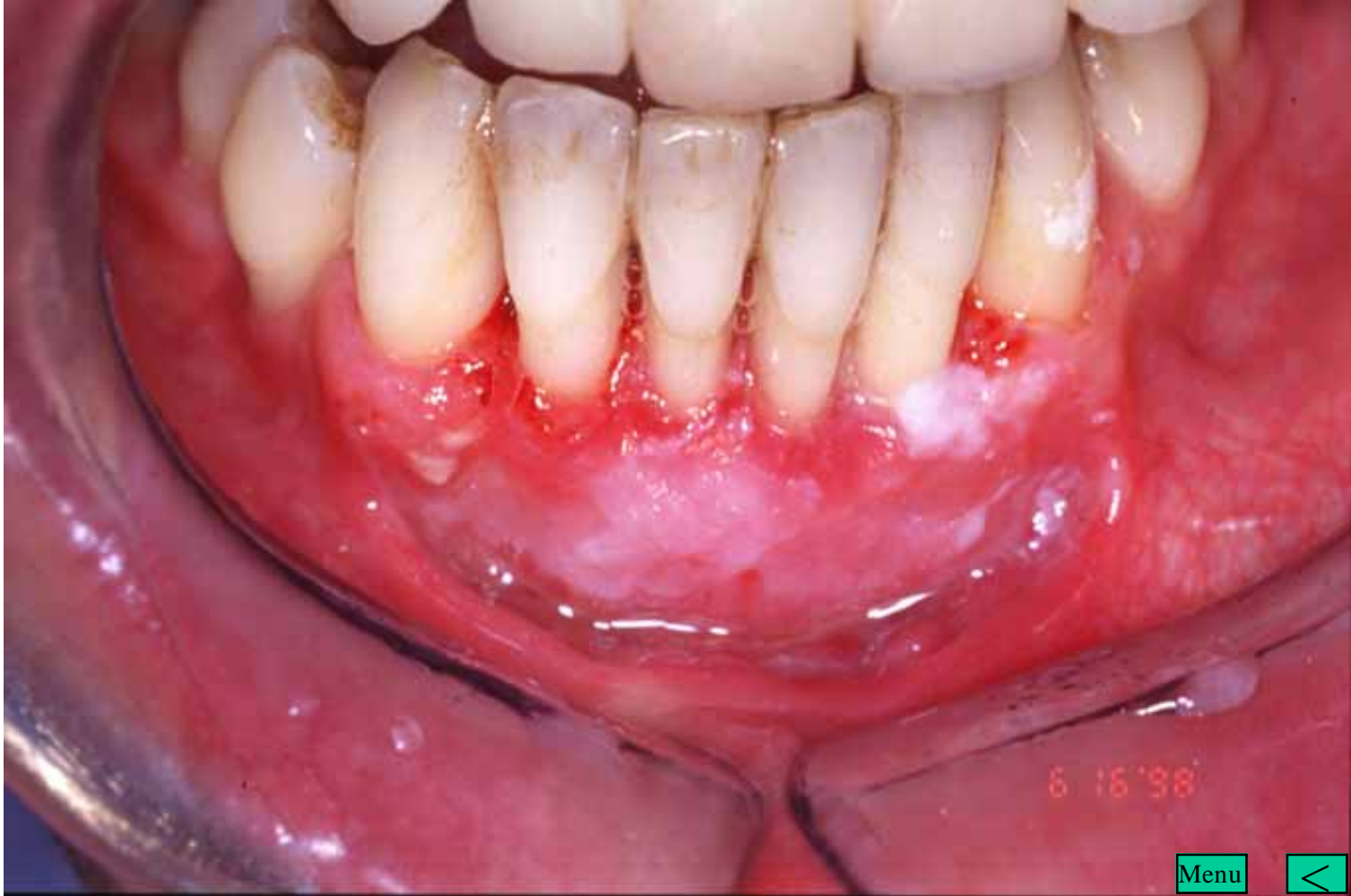Menu





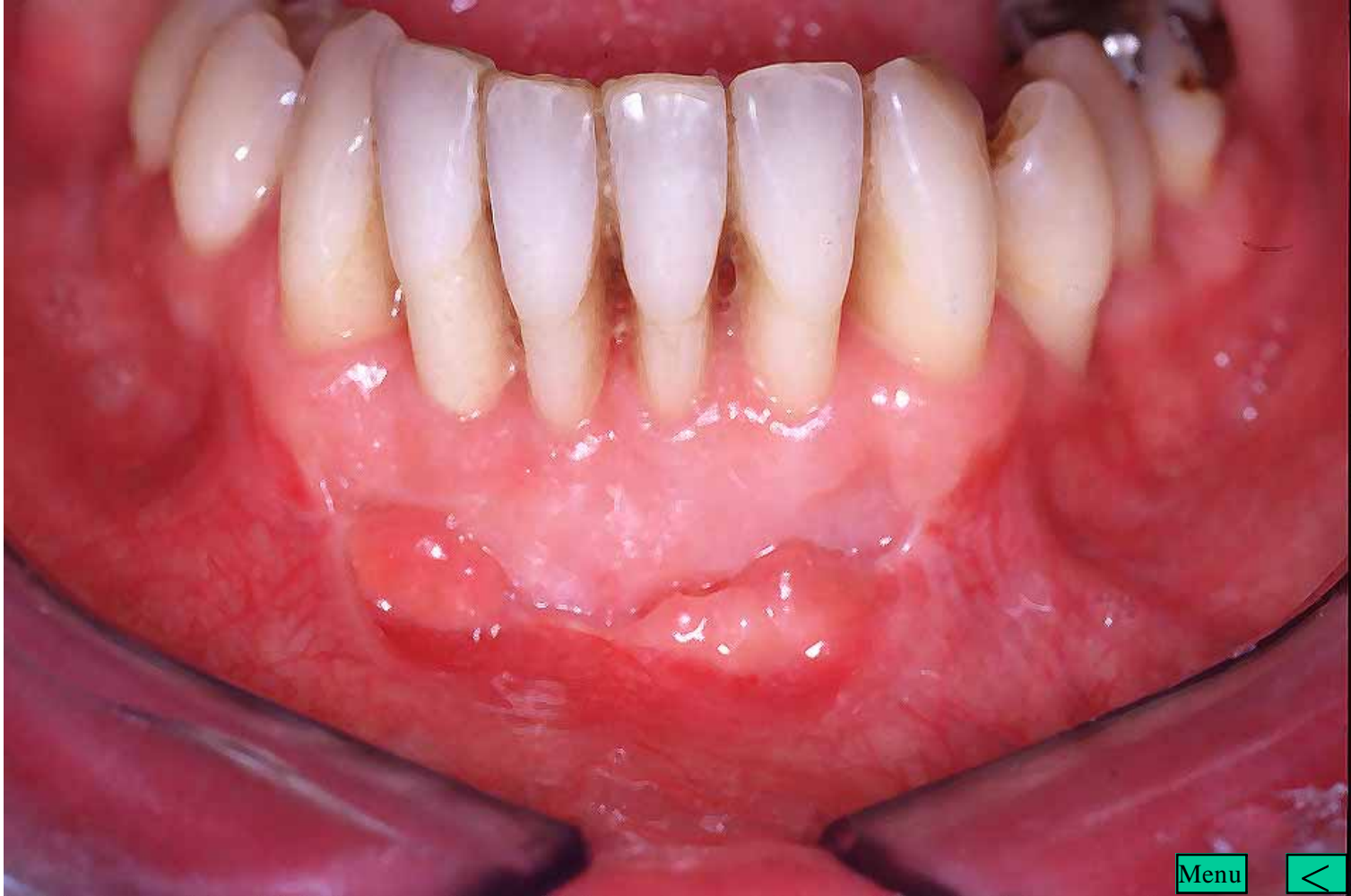Menu





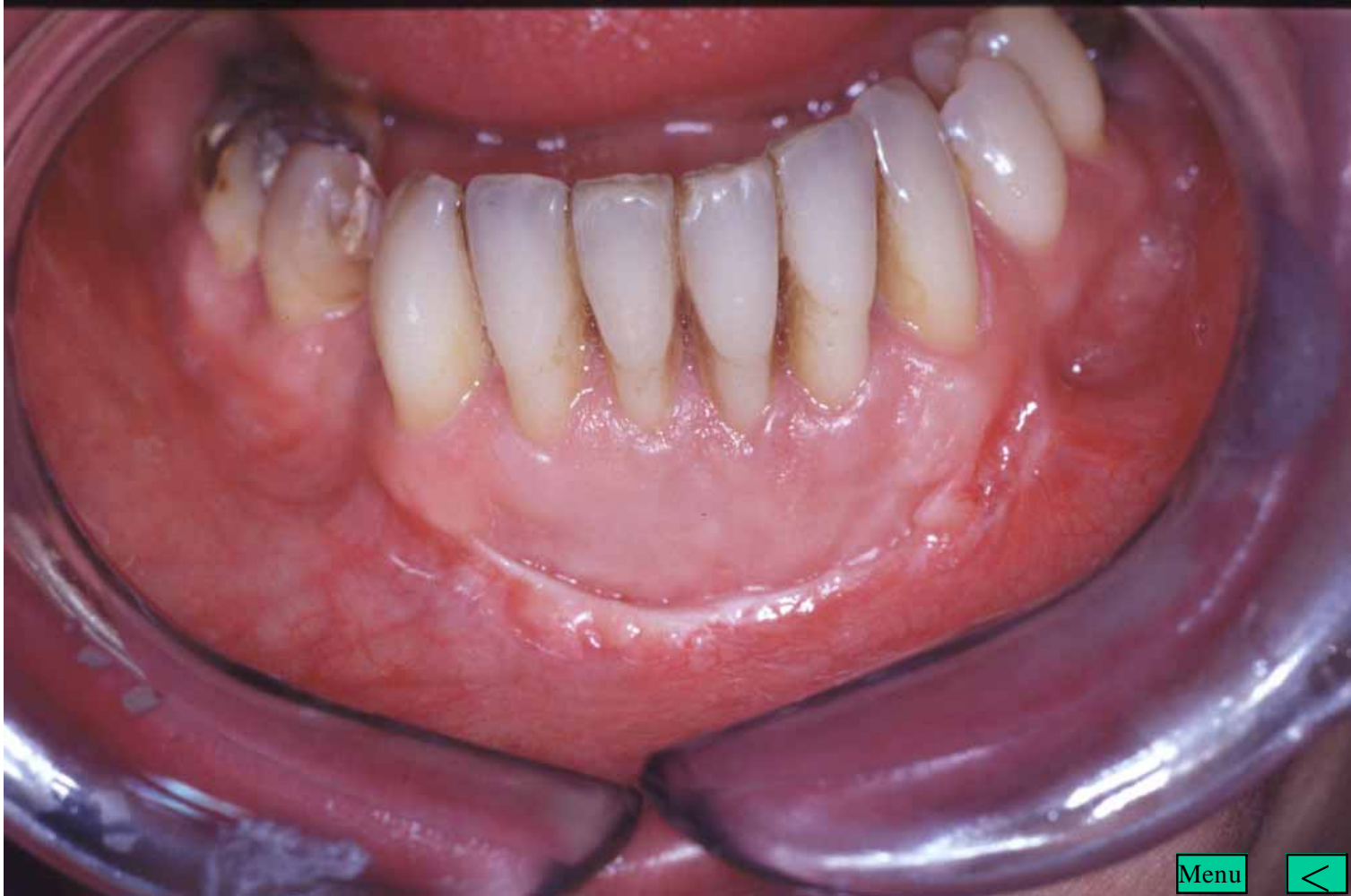Menu





Menu





Menu



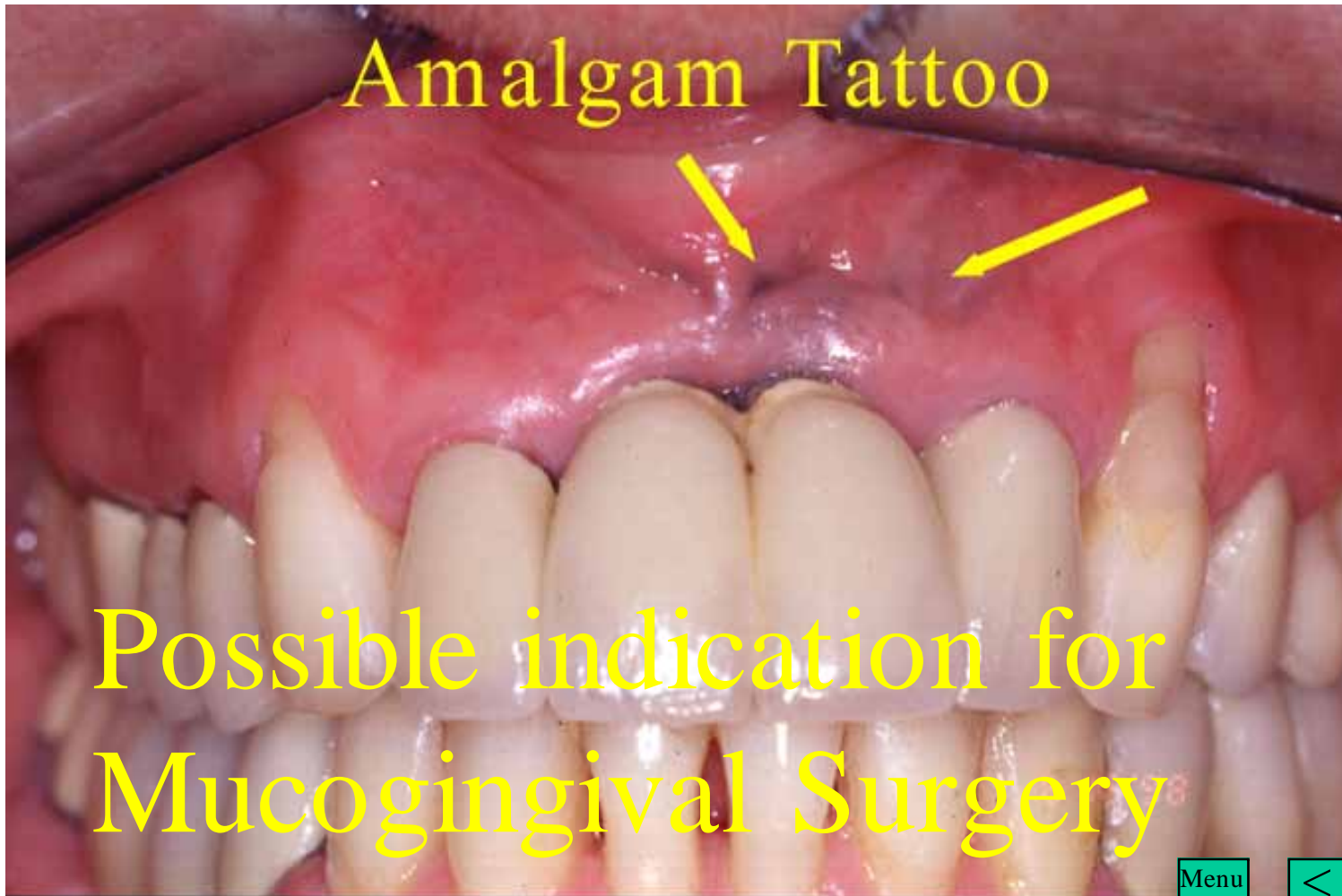
Result of not shaving the
Rugae at time of Surgery

Rugae Still Present

Menu



Amalgam Tattoo



Possible indication for
Mucogingival Surgery

Menu



Amalgam Tattoo

The End

Menu

