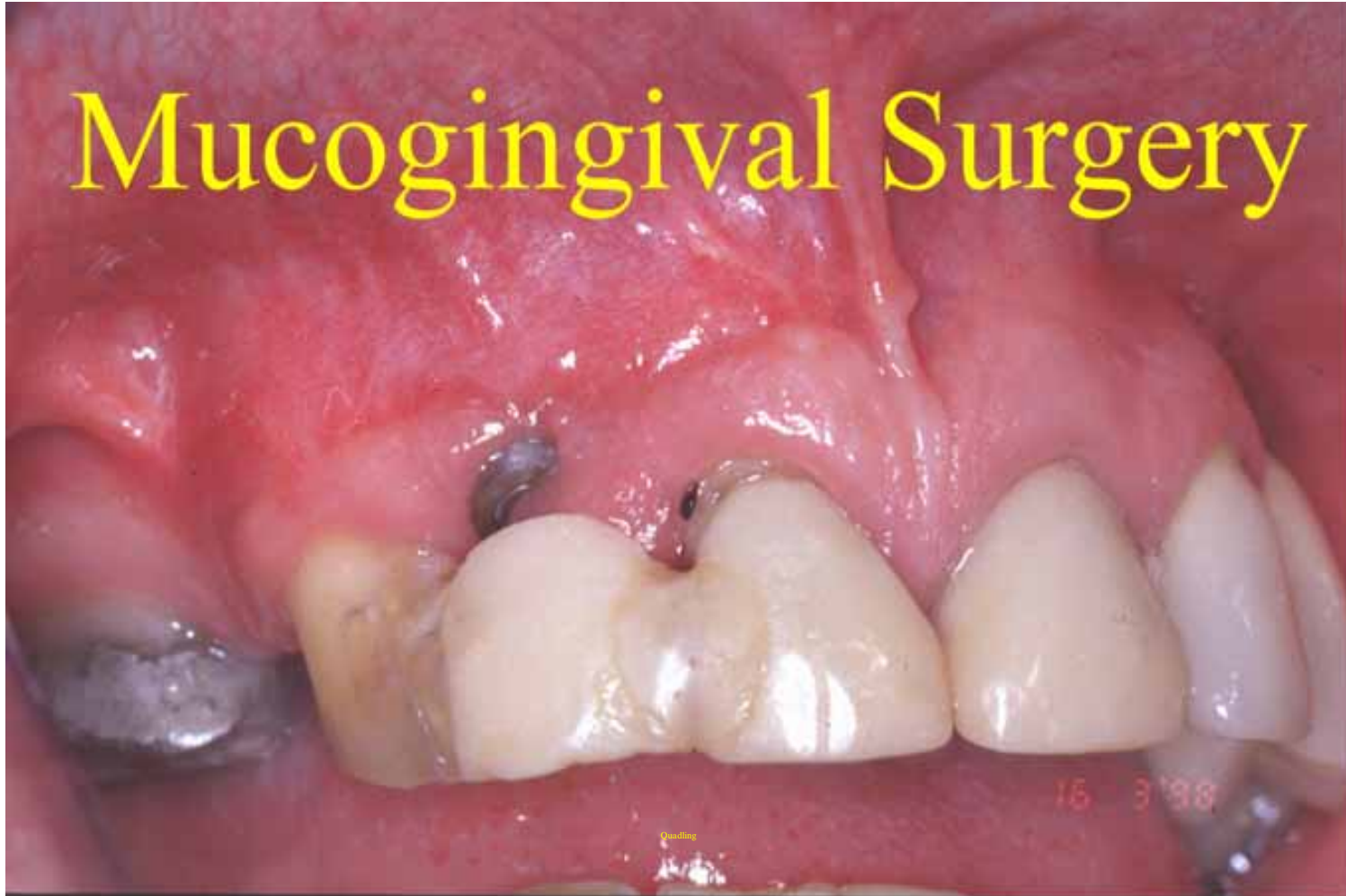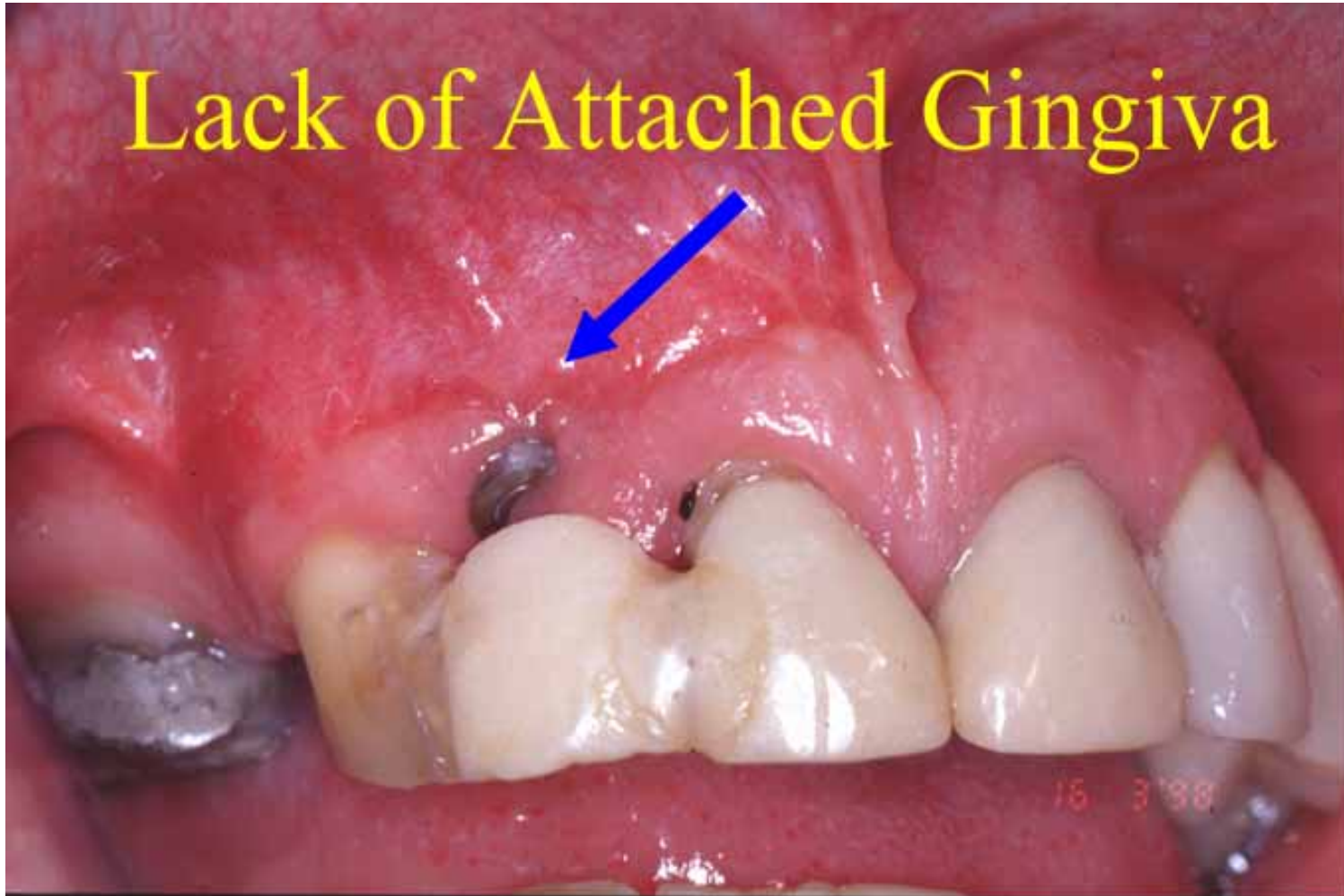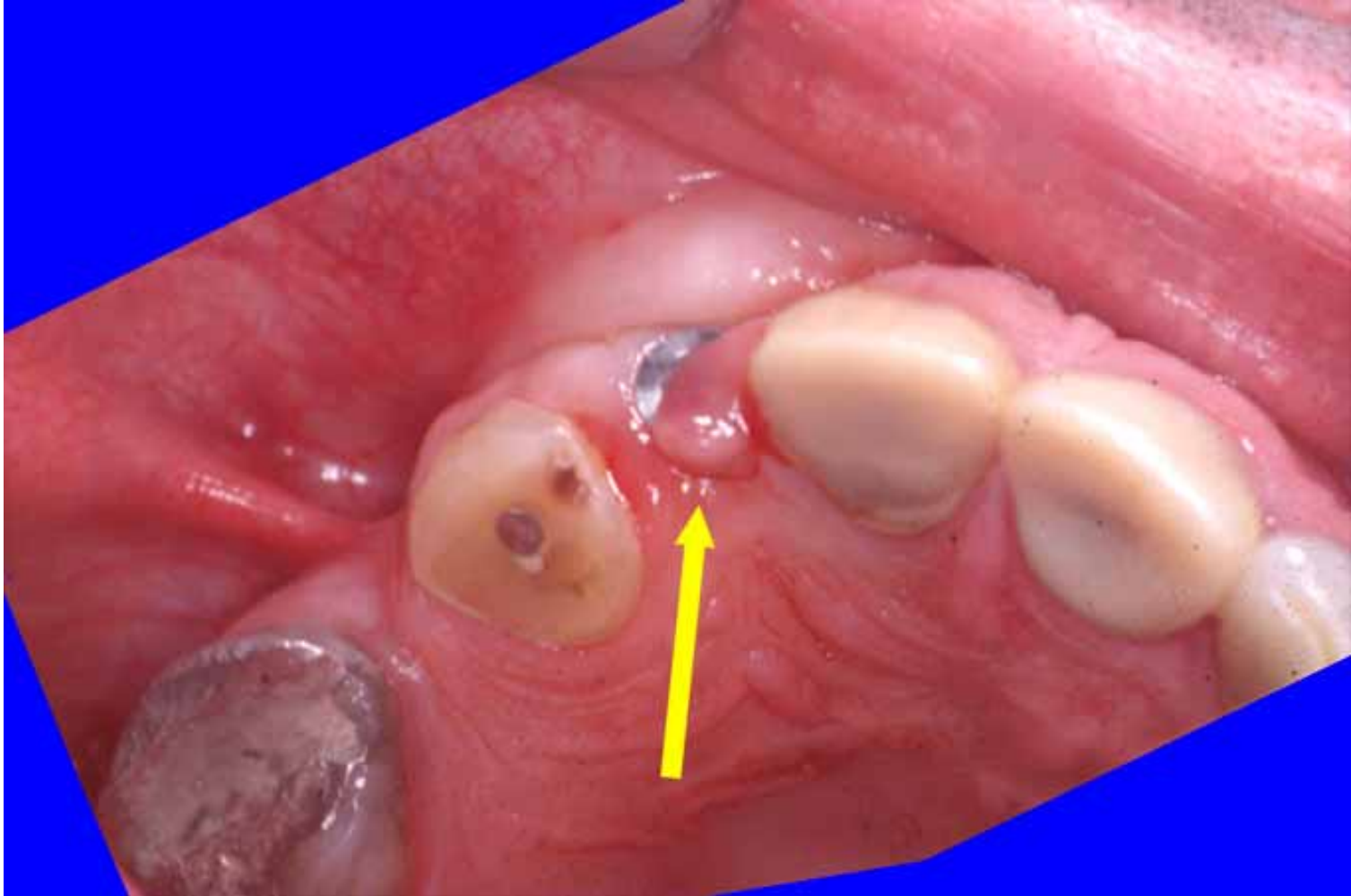


Mucogingival Surgery

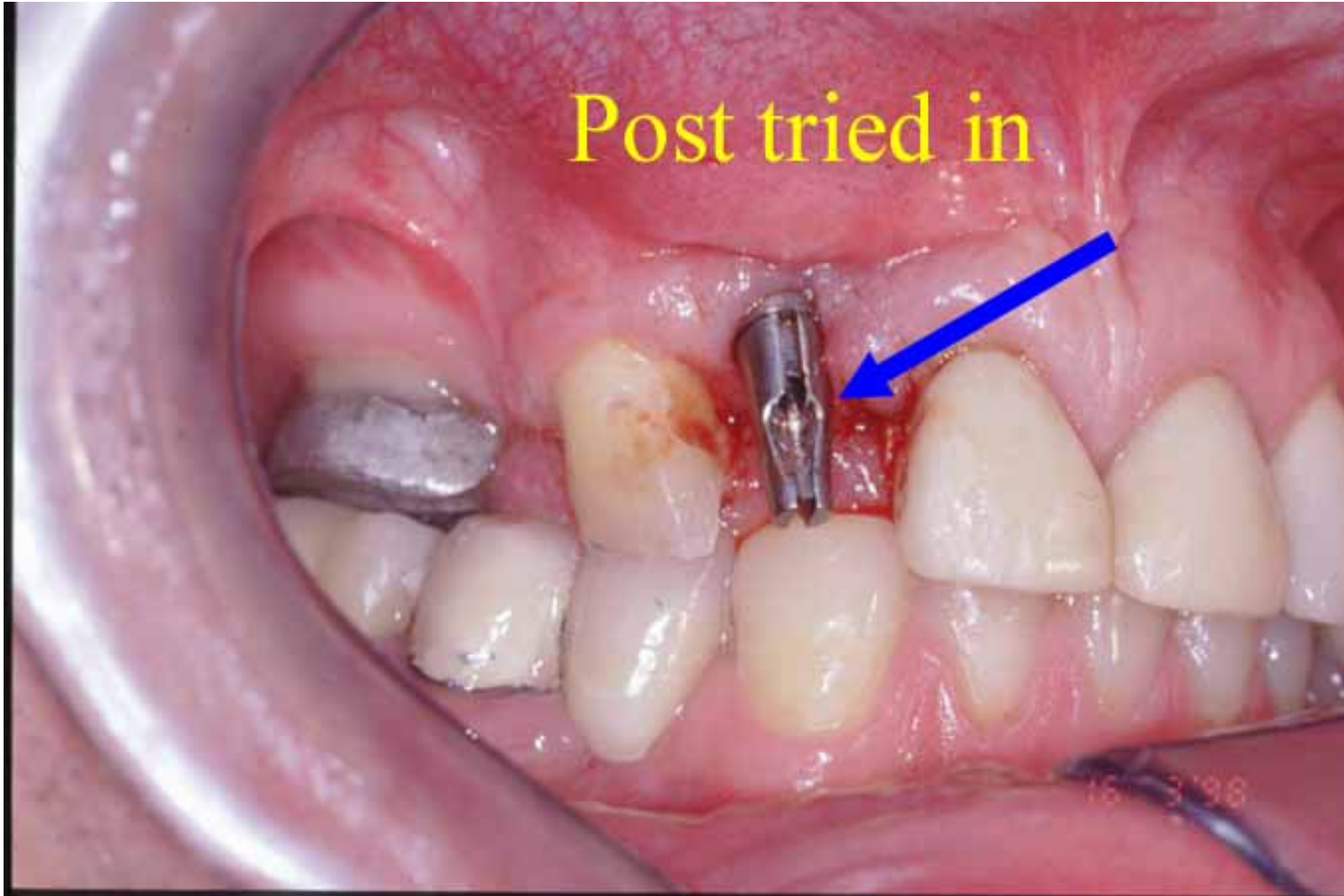


Lack of Attached Gingiva

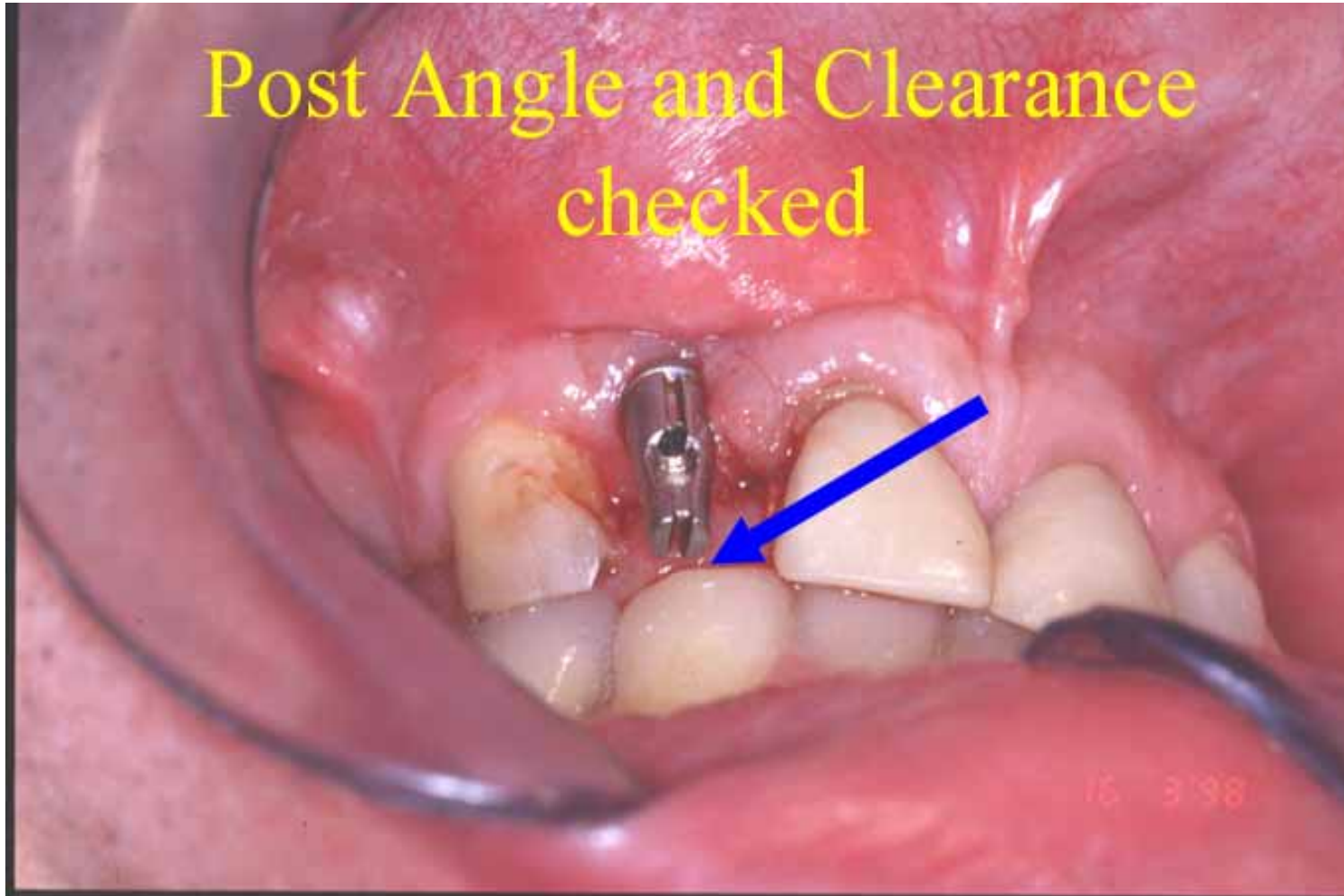


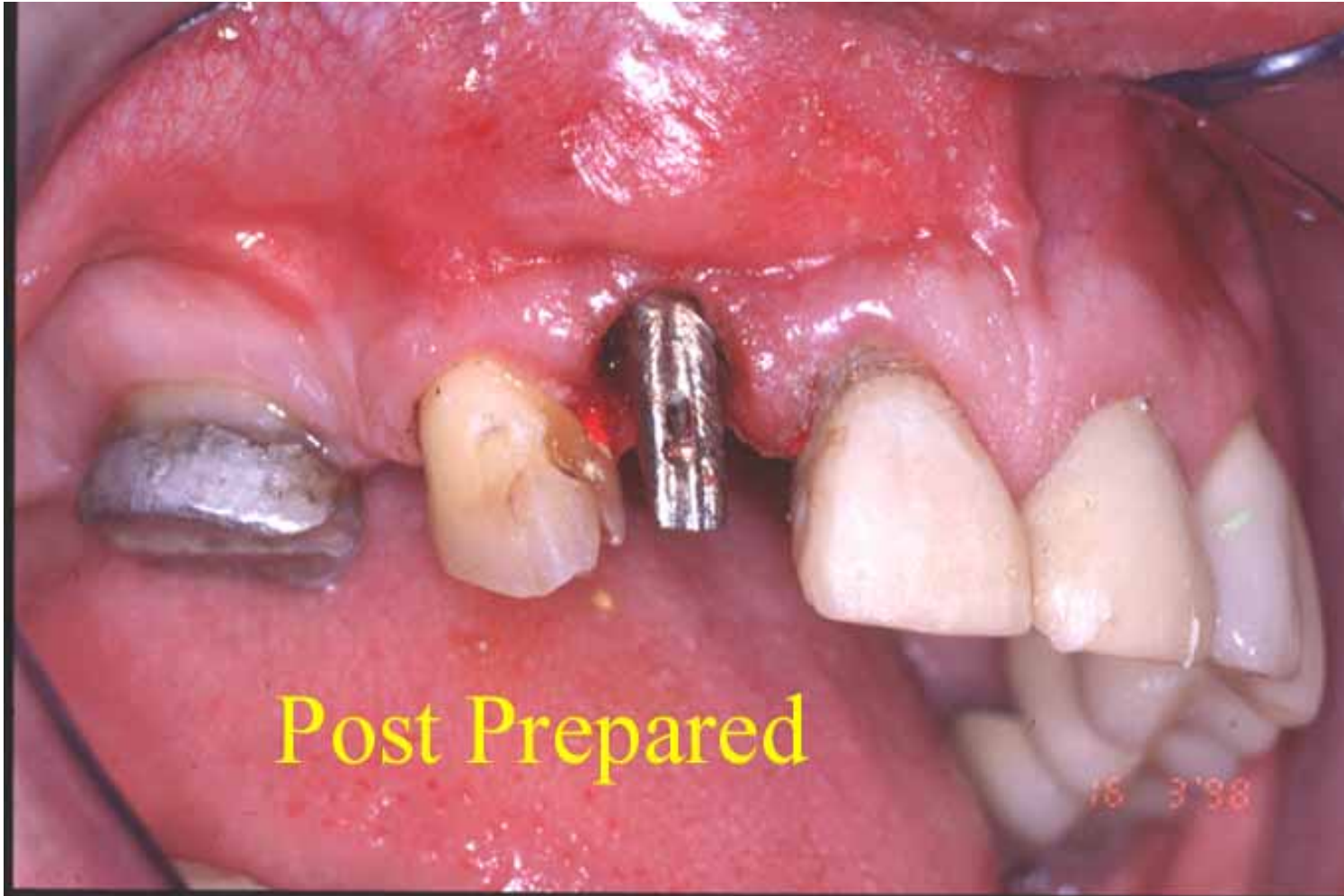


Post tried in



Post Angle and Clearance
checked

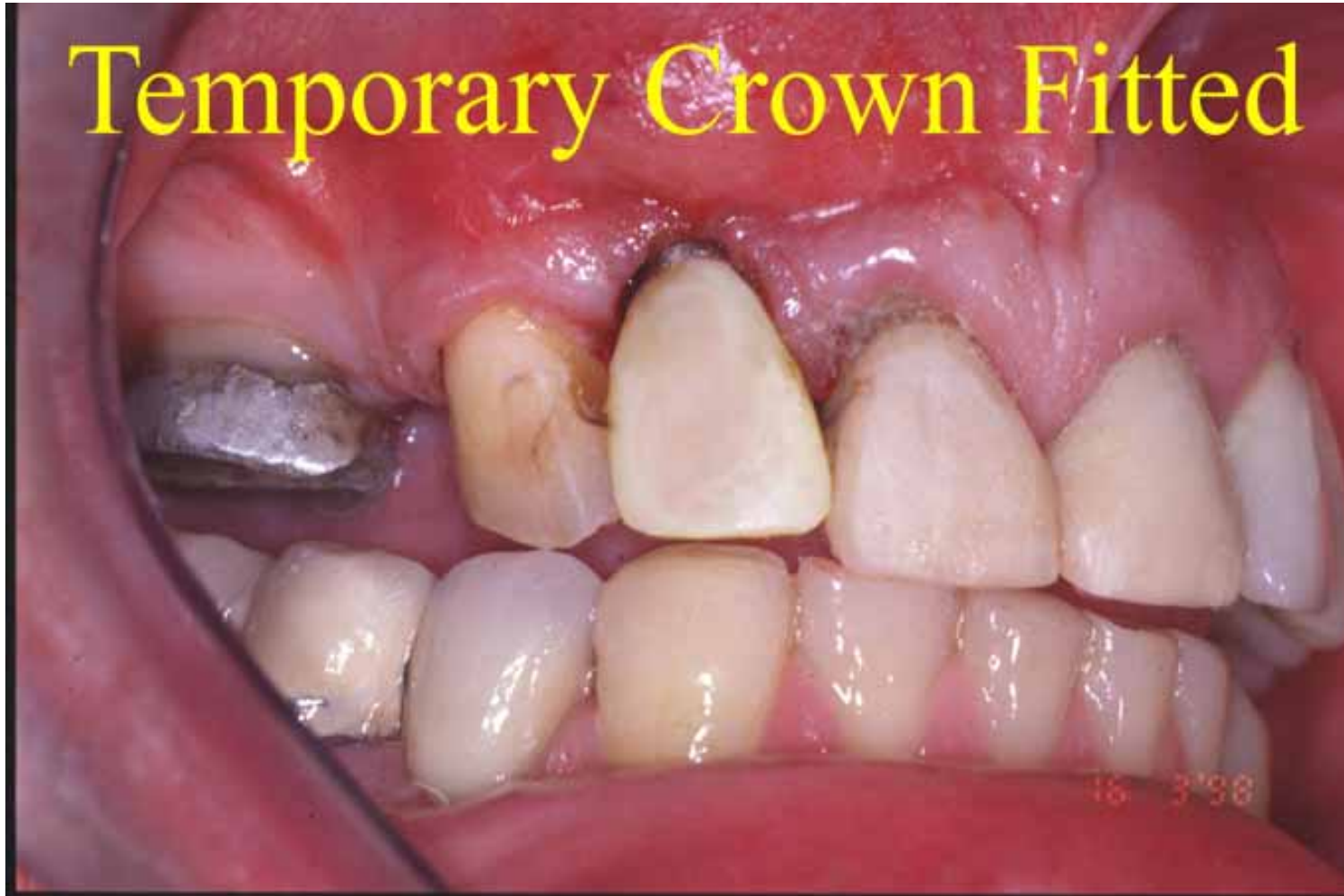



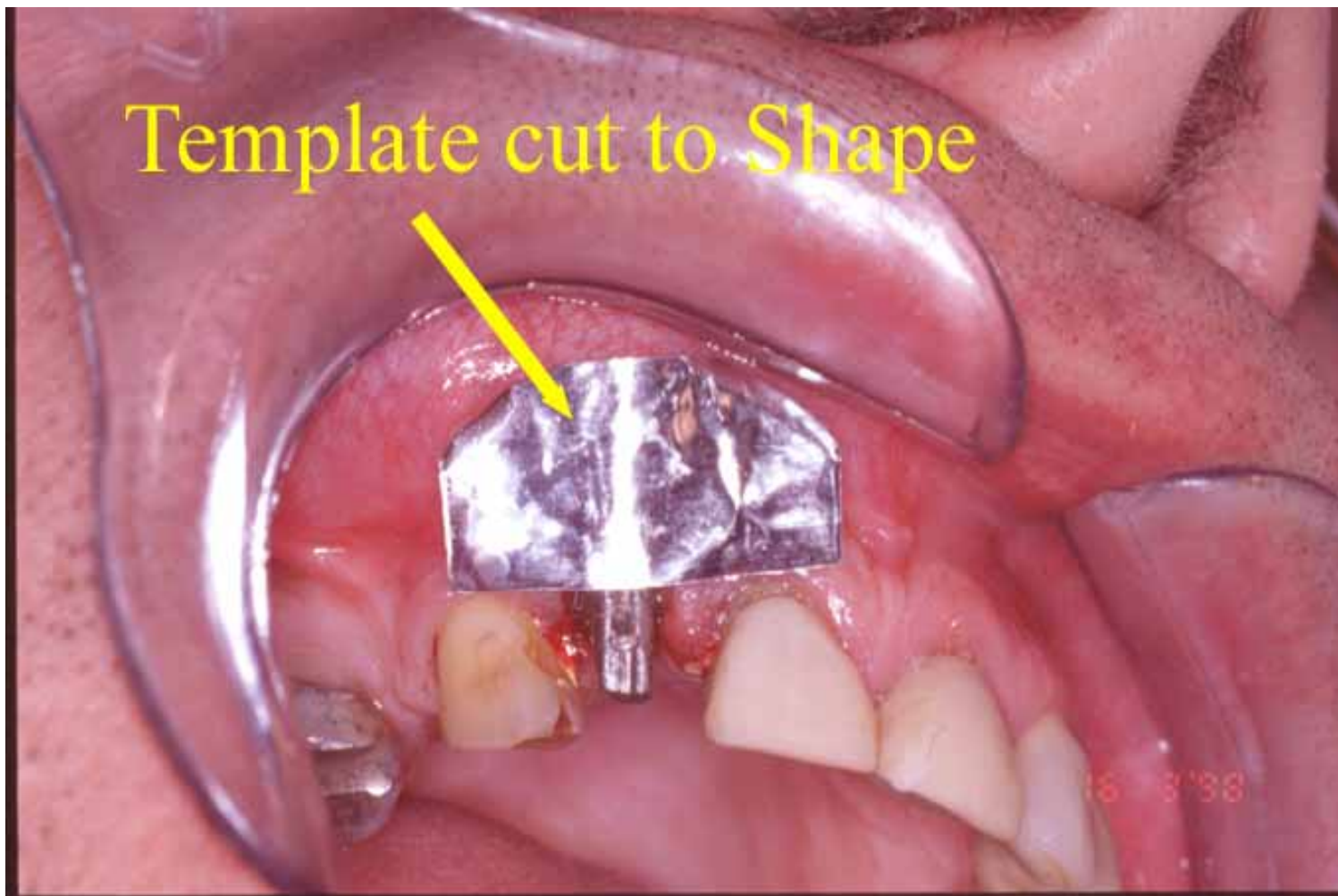
Post Prepared

16 3'98

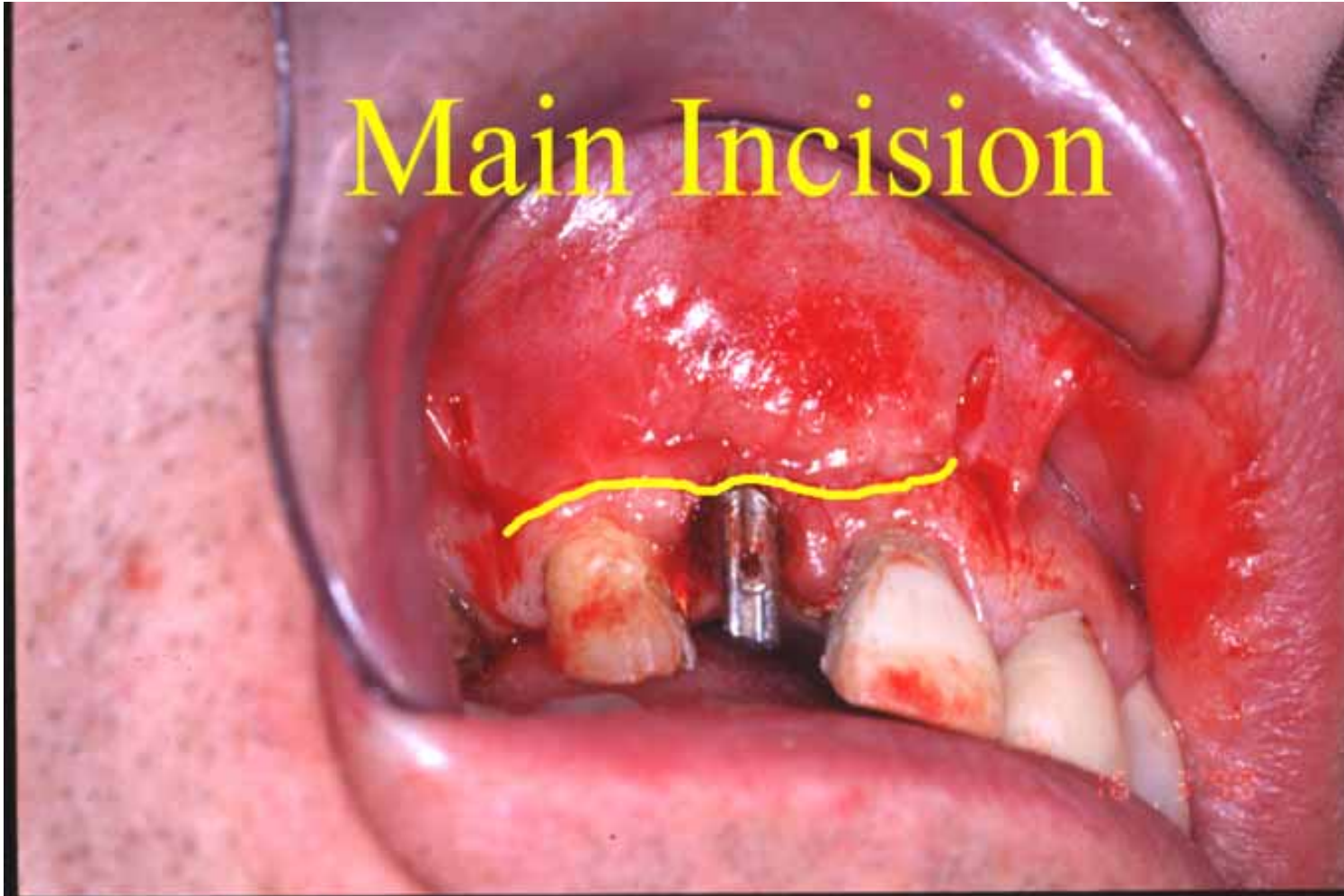Temporary Crown Fitted



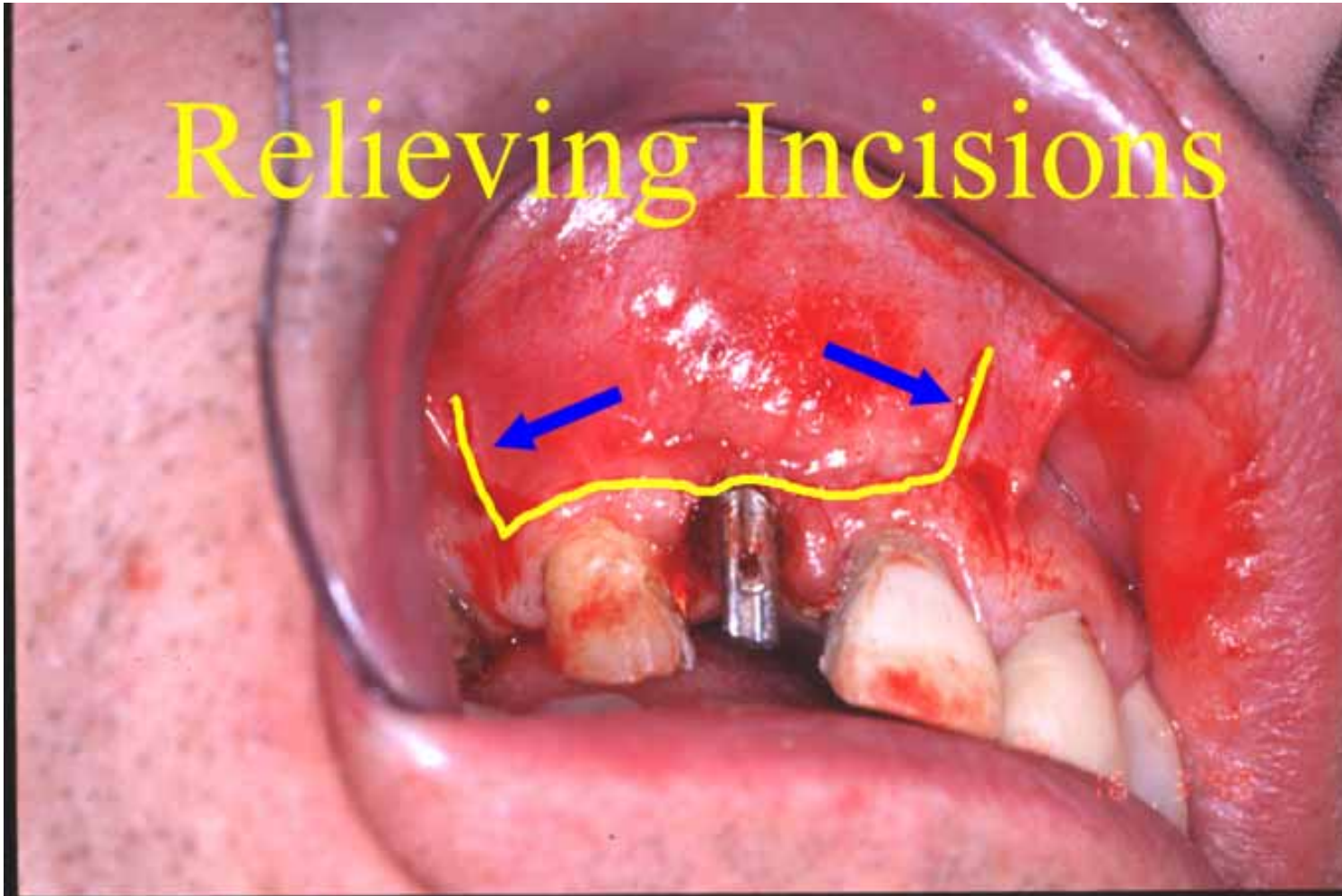
Template cut to Shape



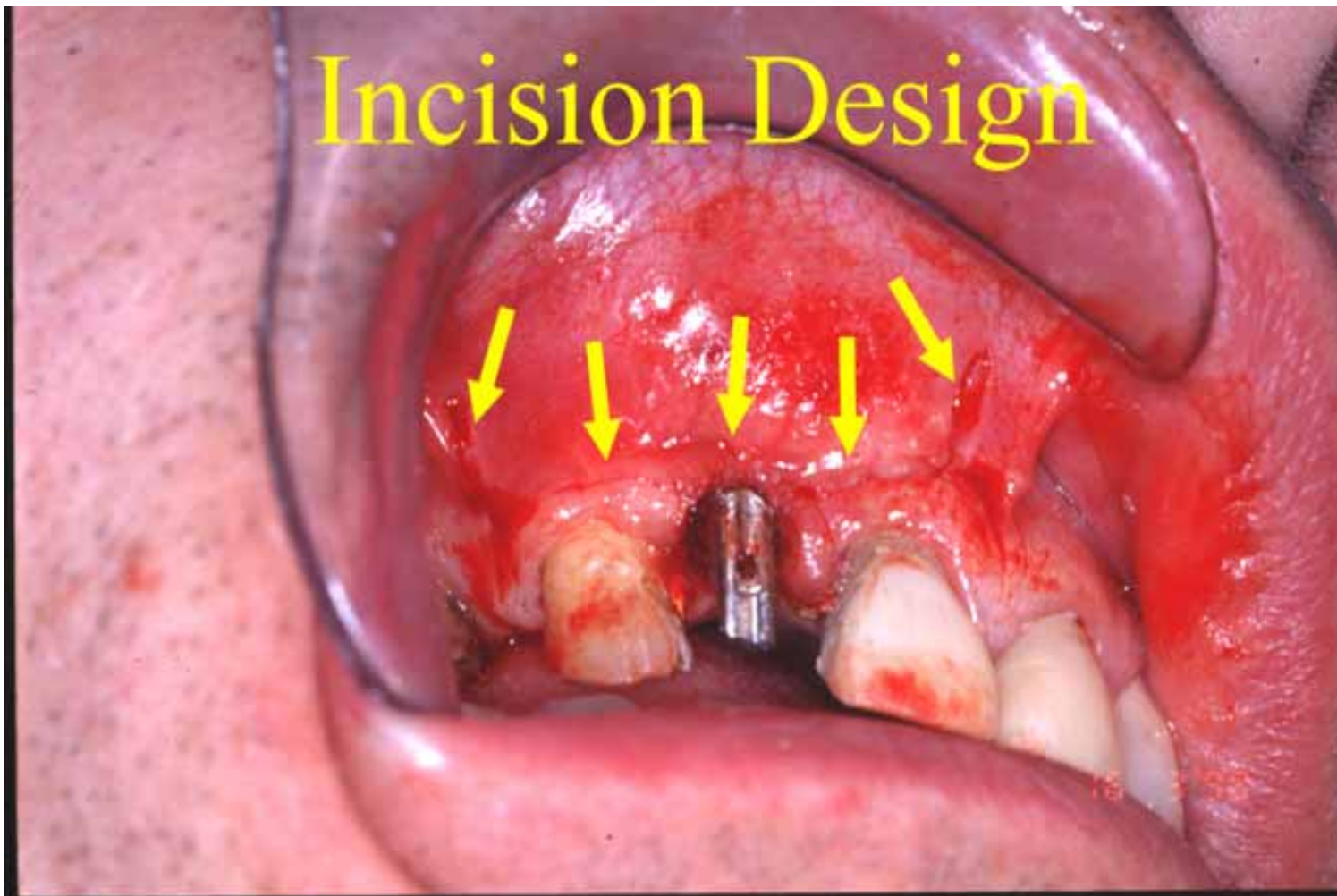
Main Incision



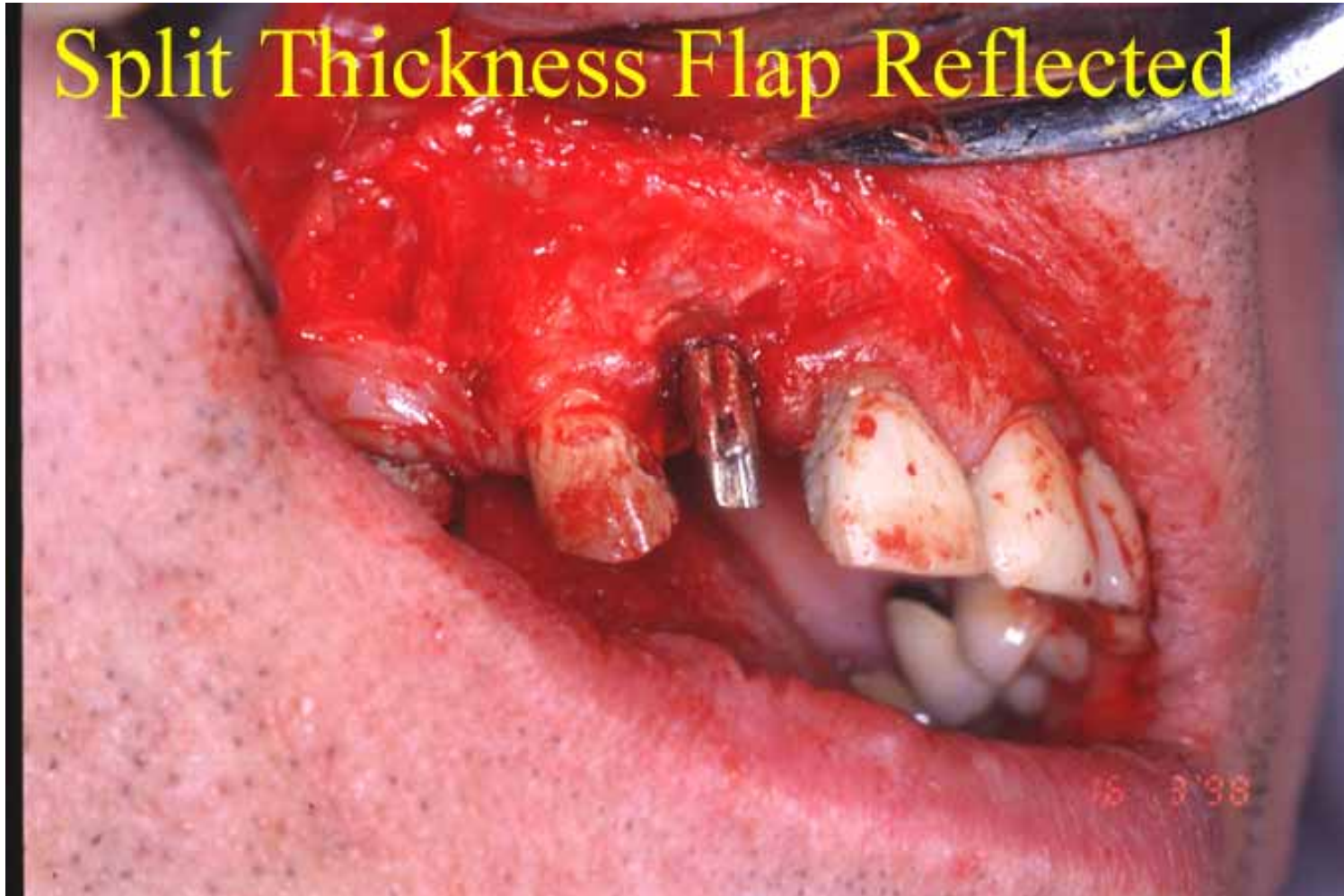Relieving Incisions



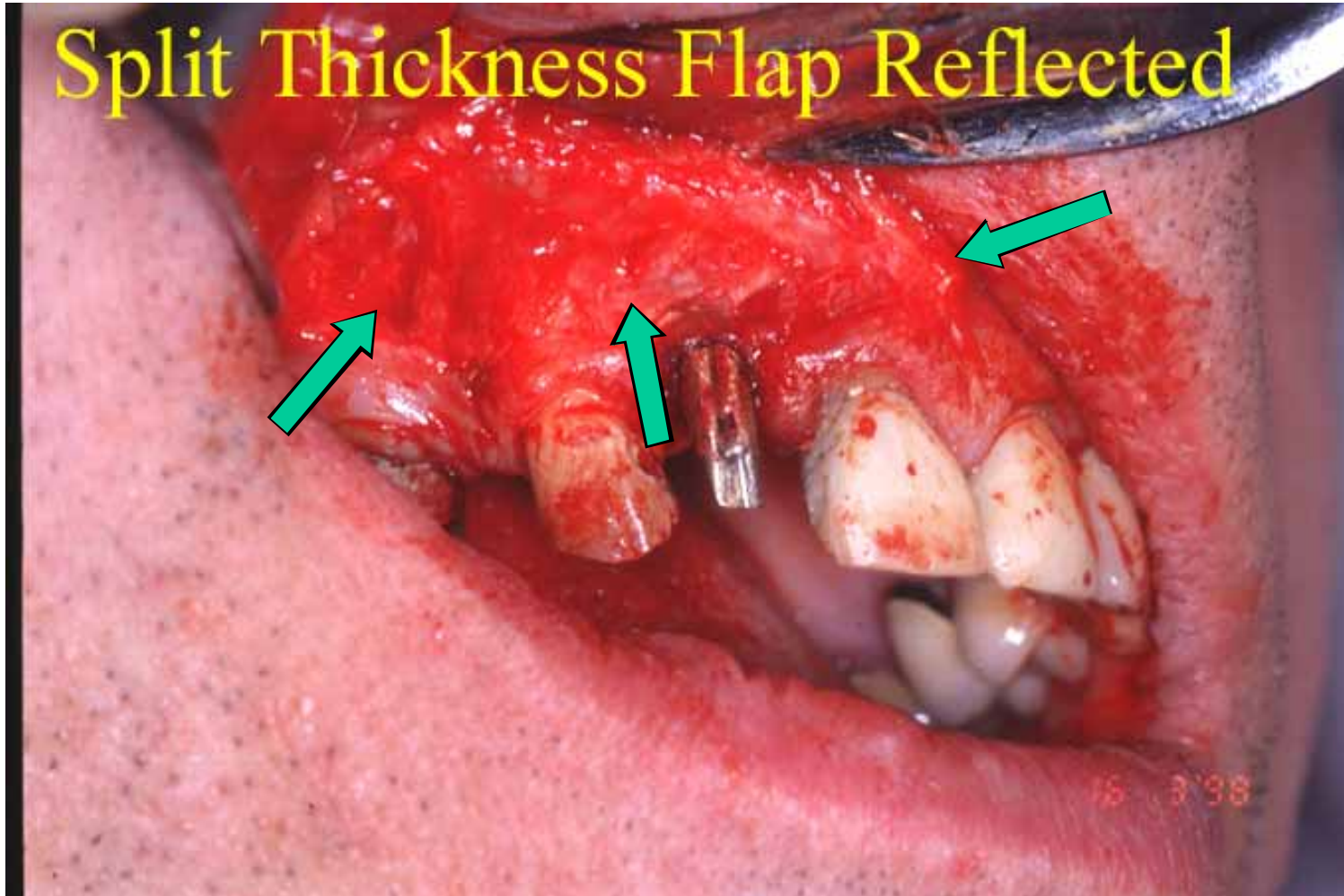
Incision Design



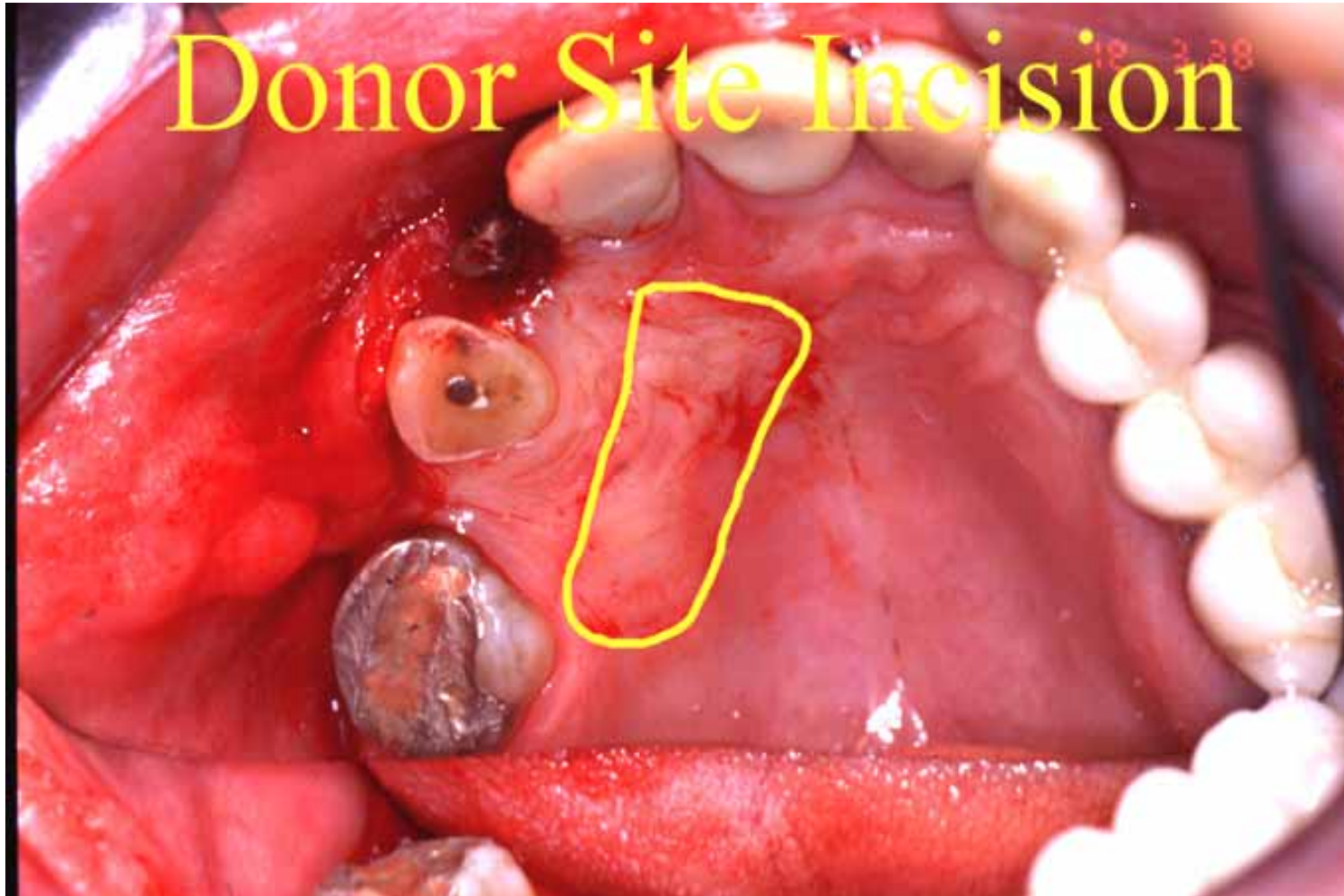
Split Thickness Flap Reflected

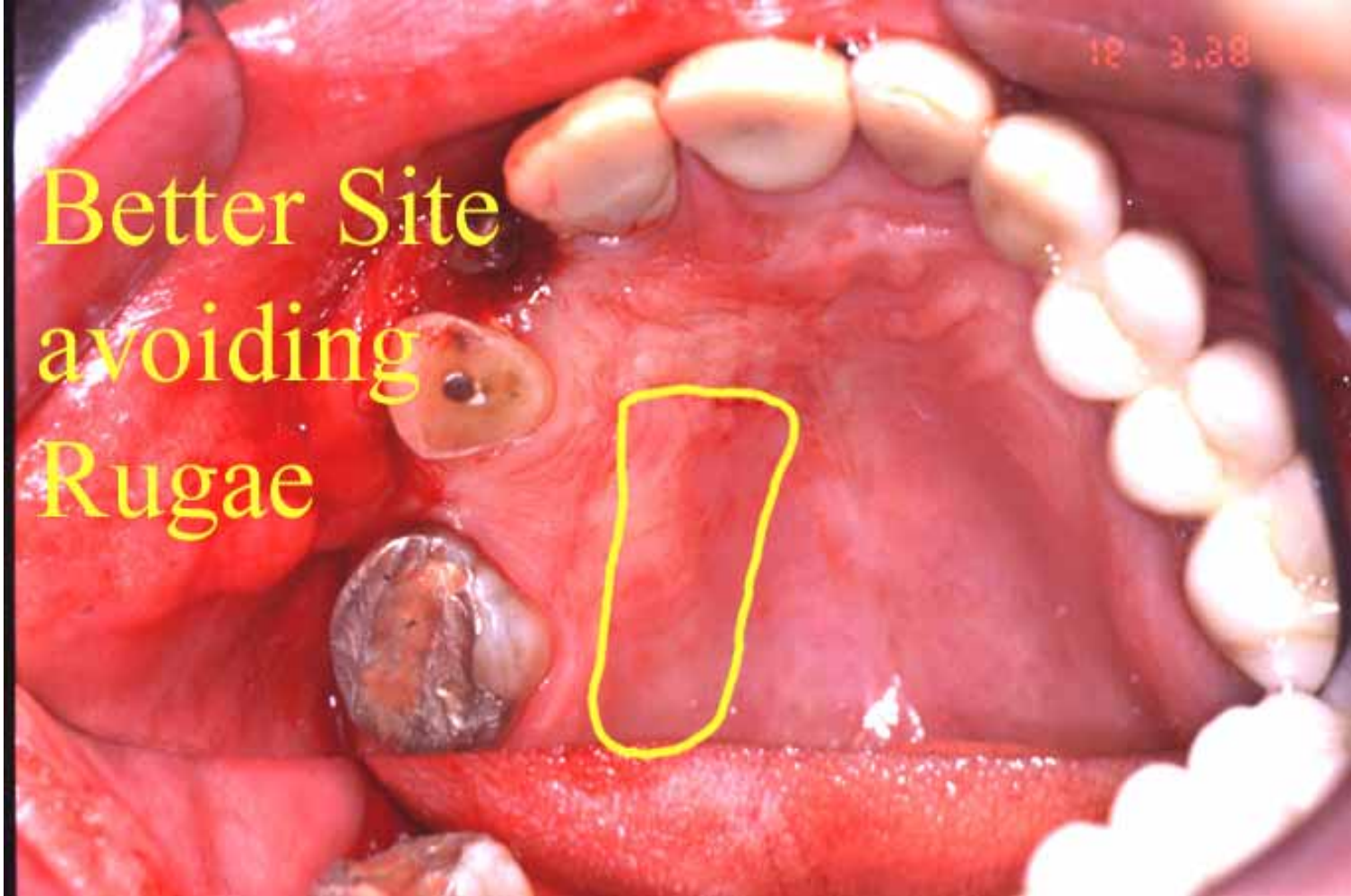

Split Thickness Flap Reflected

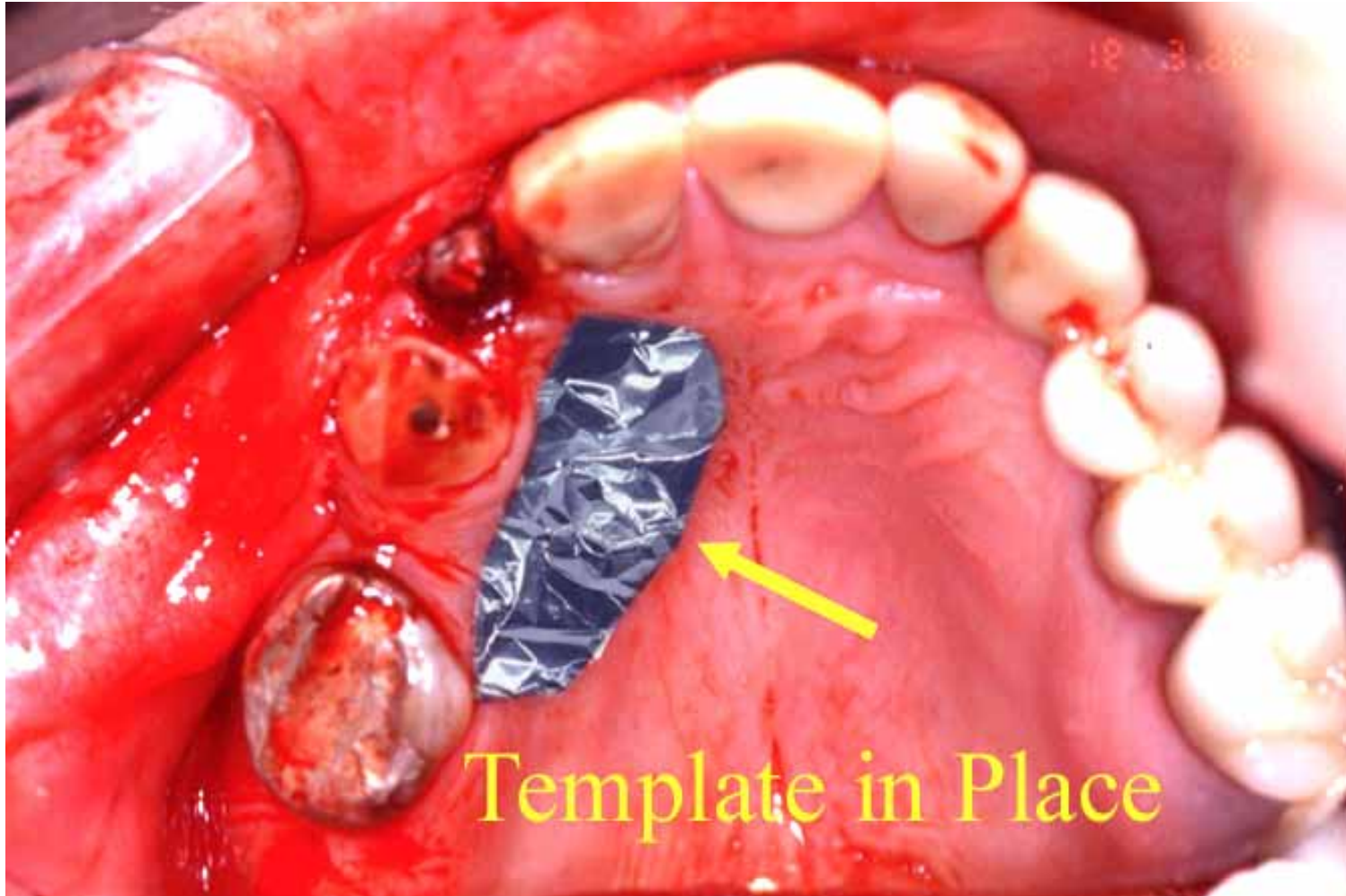


Donor Site Incision



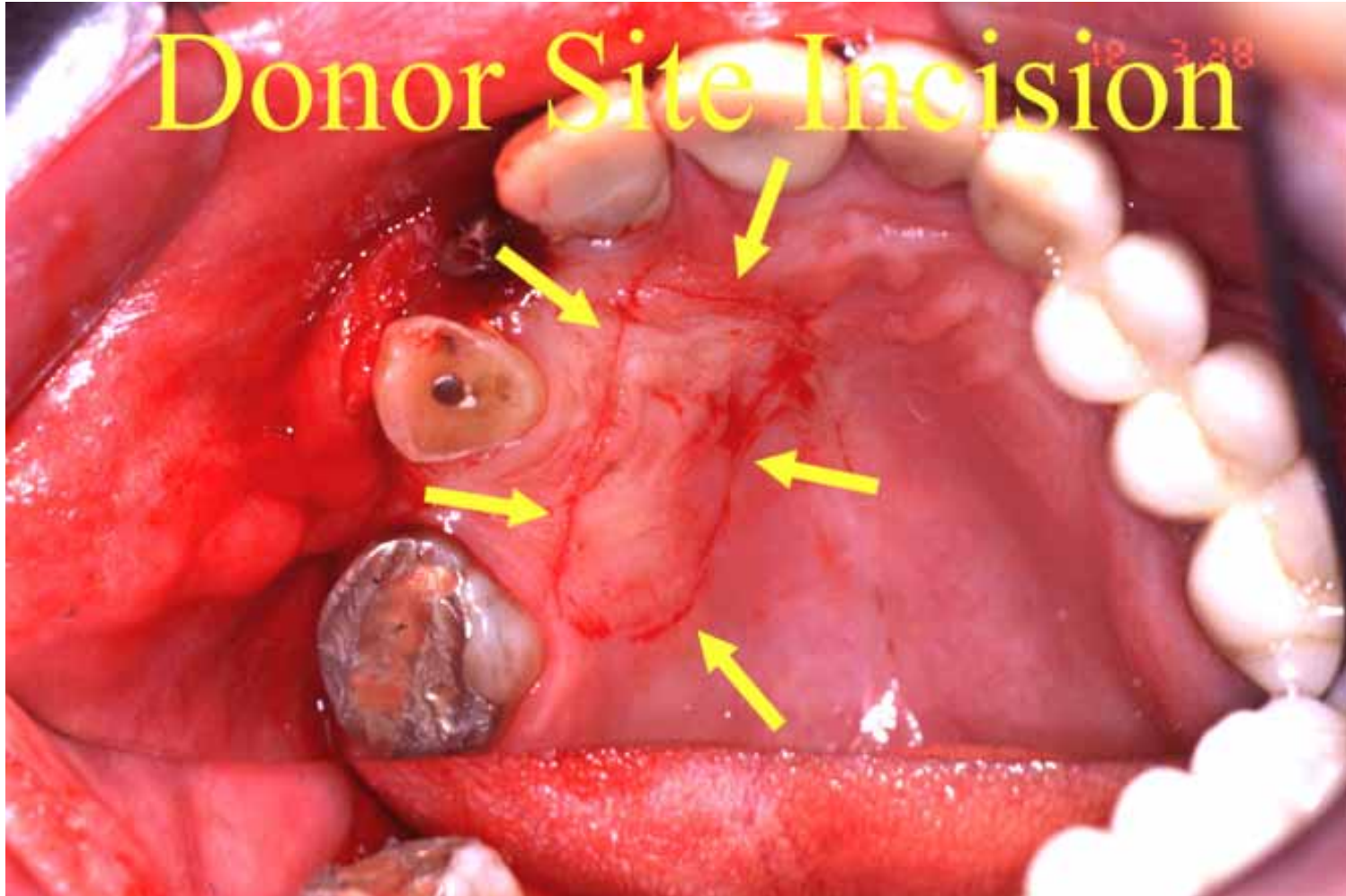


Better Site
avoiding
Rugae

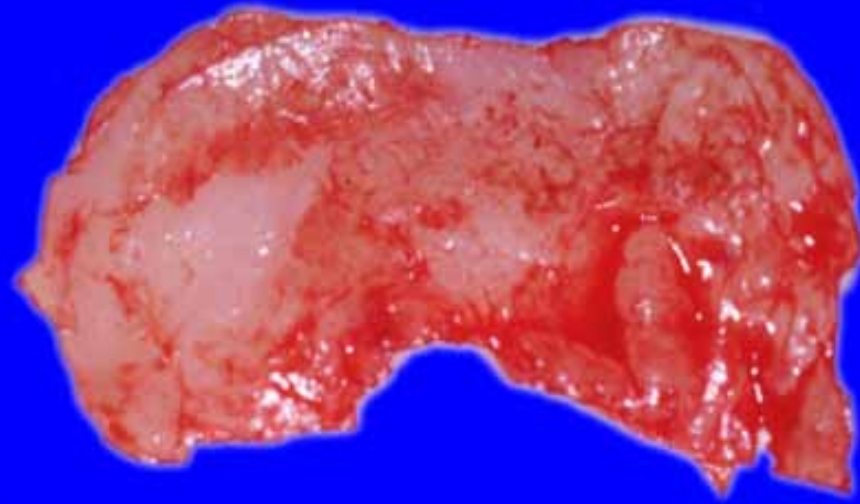


Template in Place

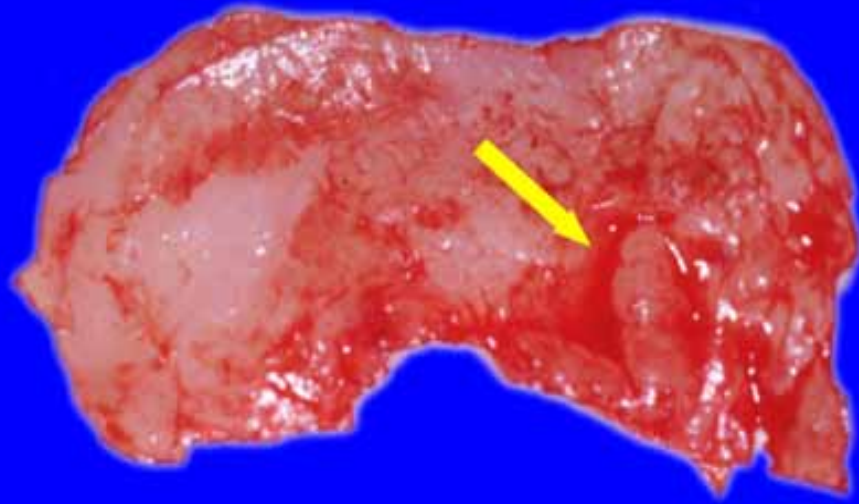
Donor Site Incision



Free Gingival Graft



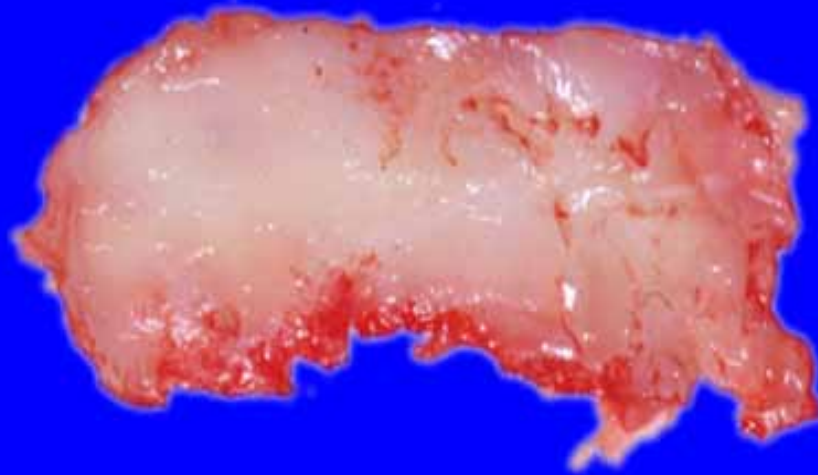Rugae



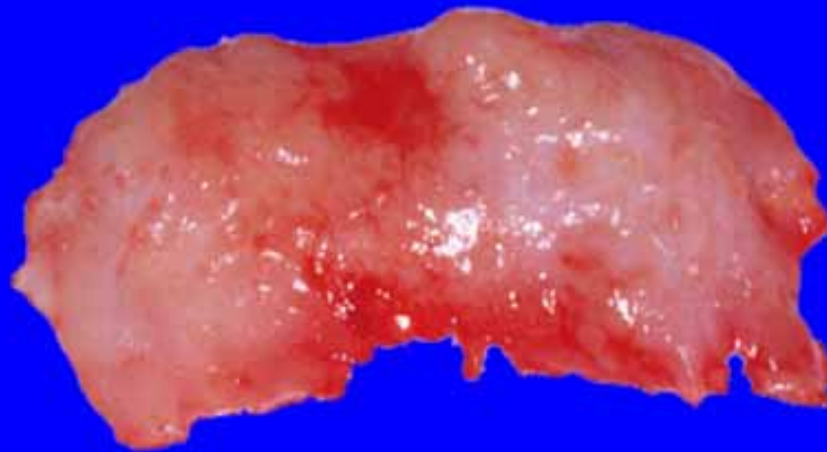
Rugae being Shaved



Rugae shaved



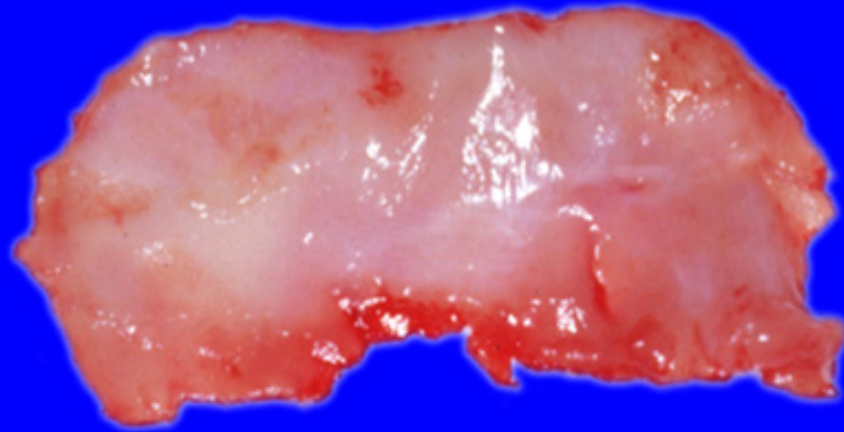
Under Surface of Graft

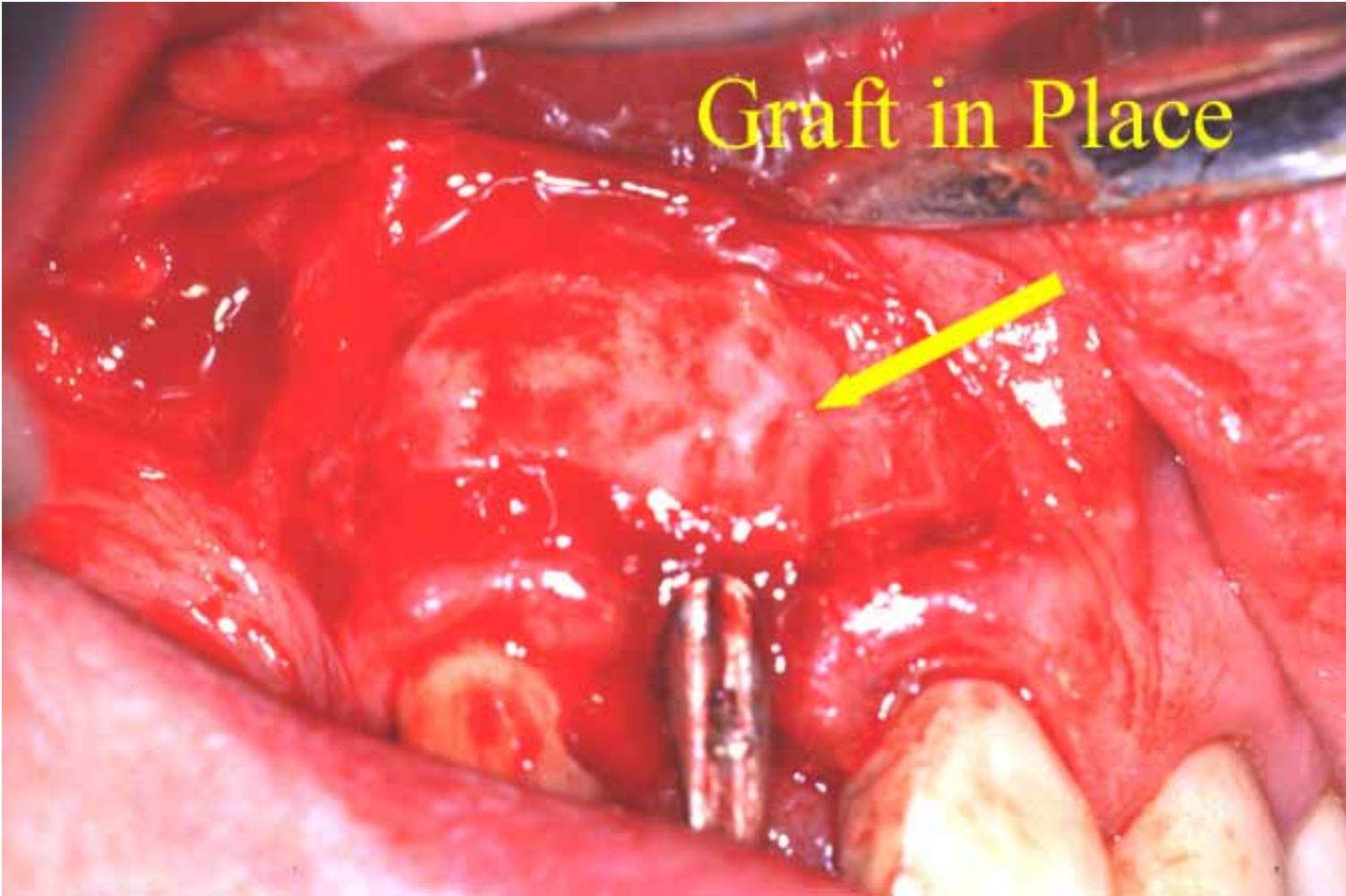


Fat and Connective Tissue
being shaved



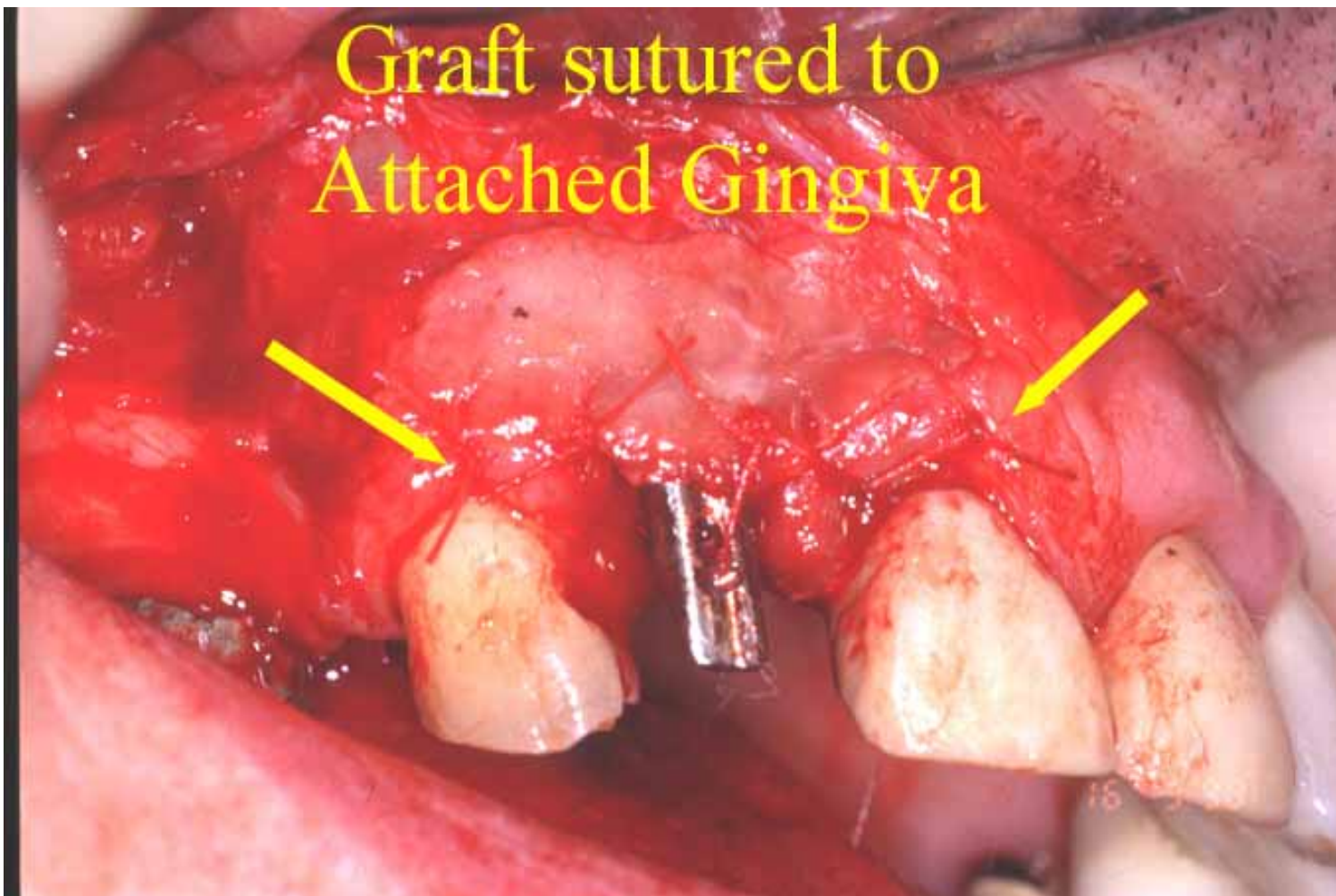
Fat and Connective Tissue shaved

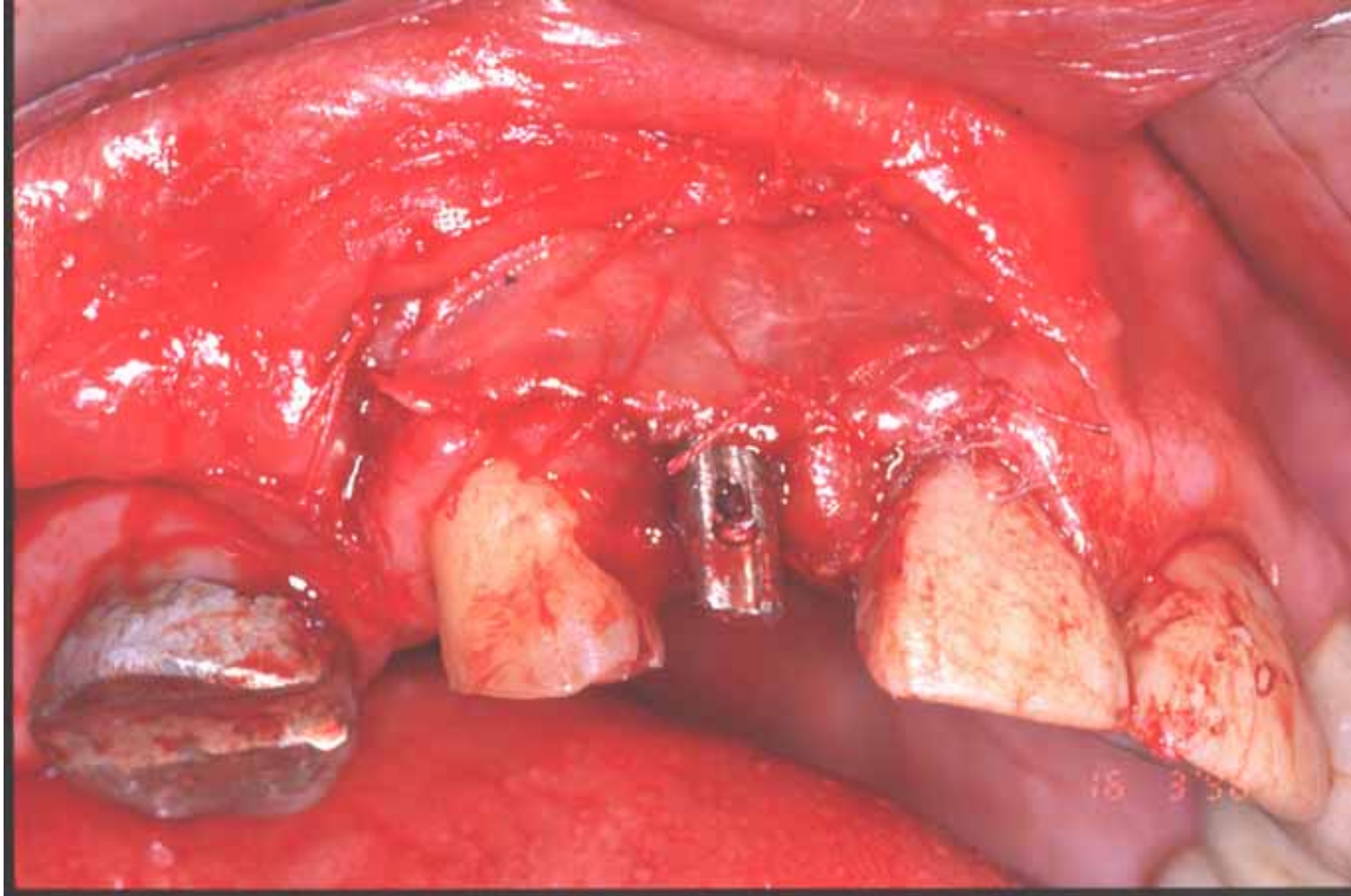


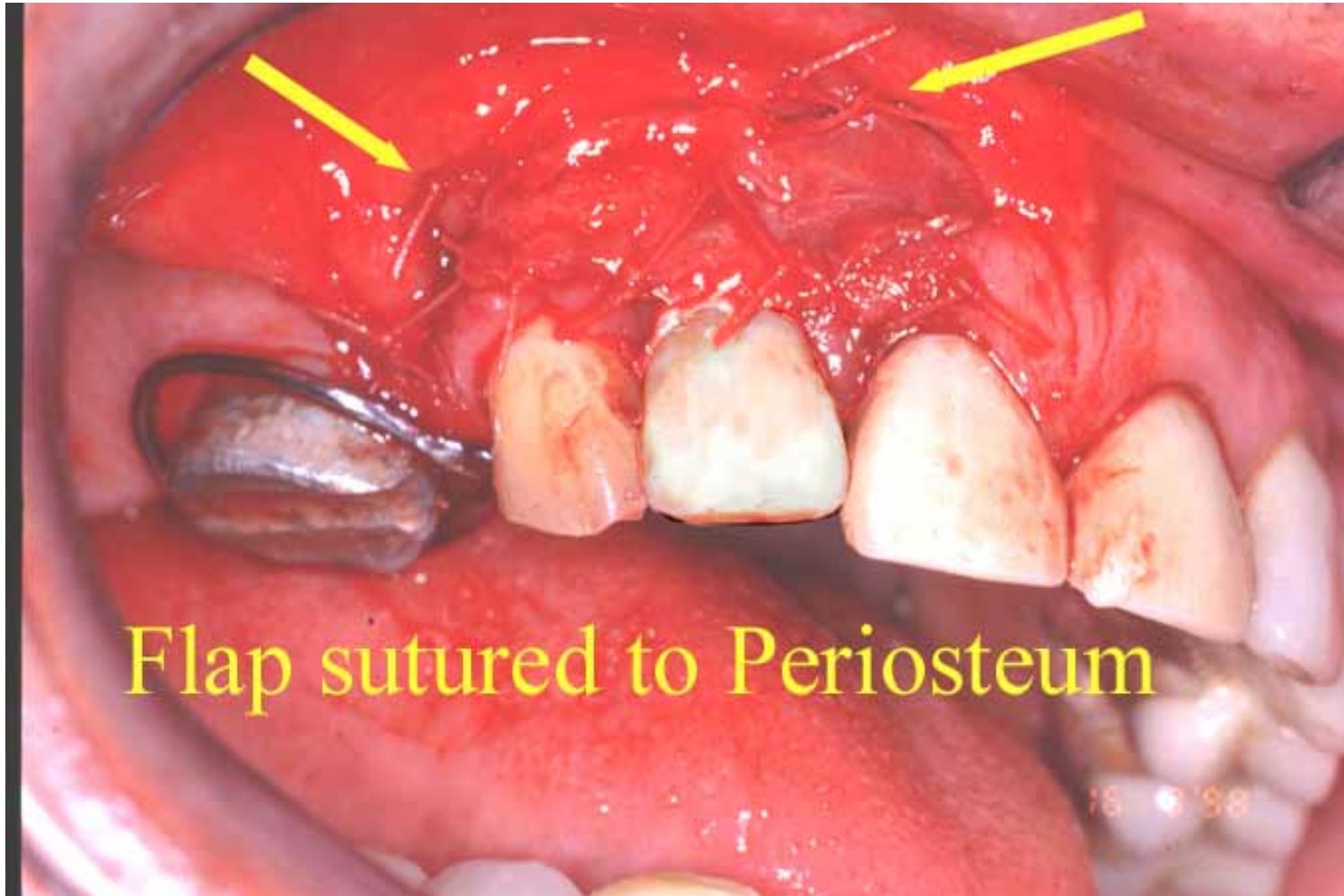


Graft in Place

Graft sutured to
Attached Gingiva

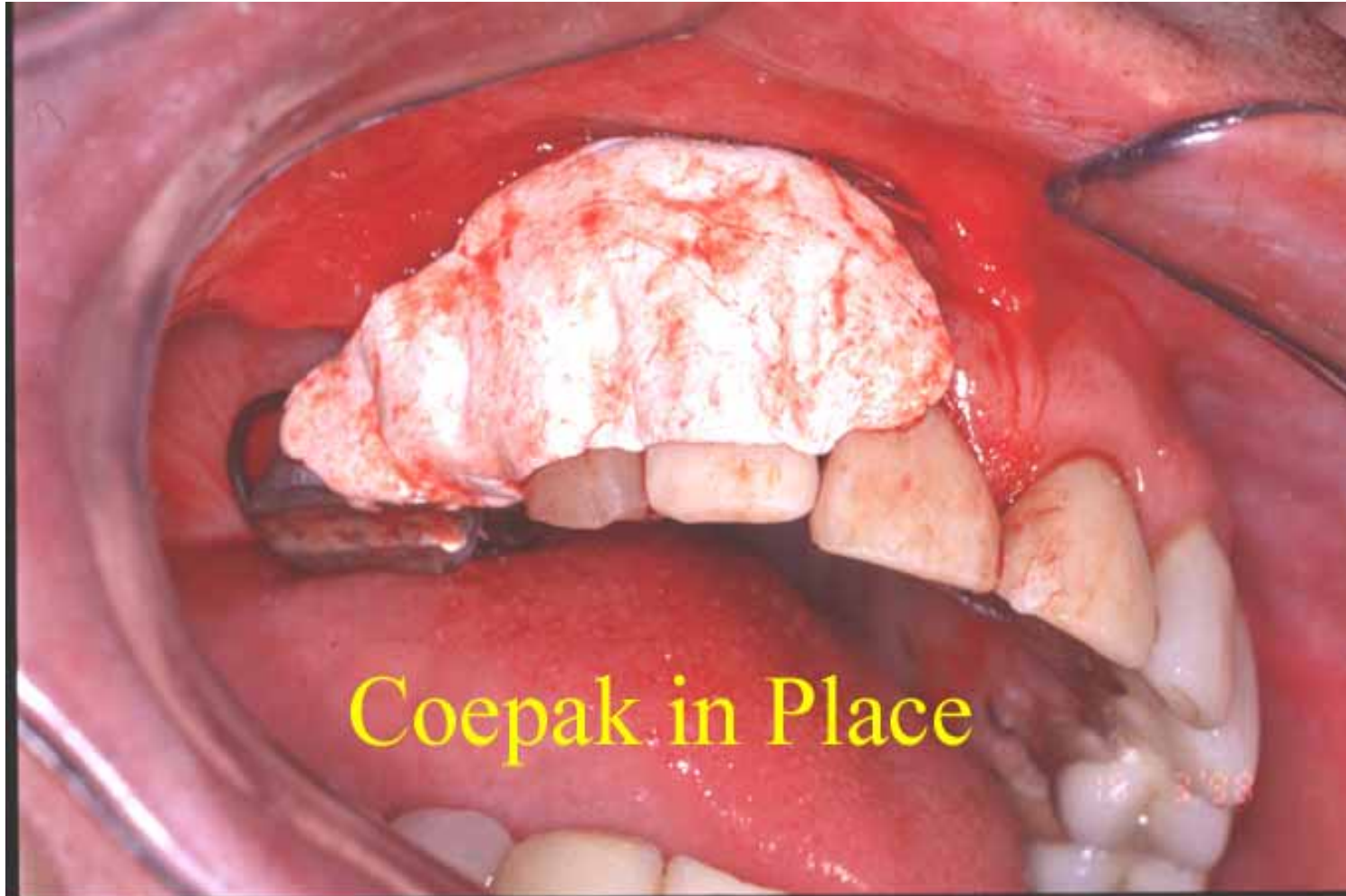



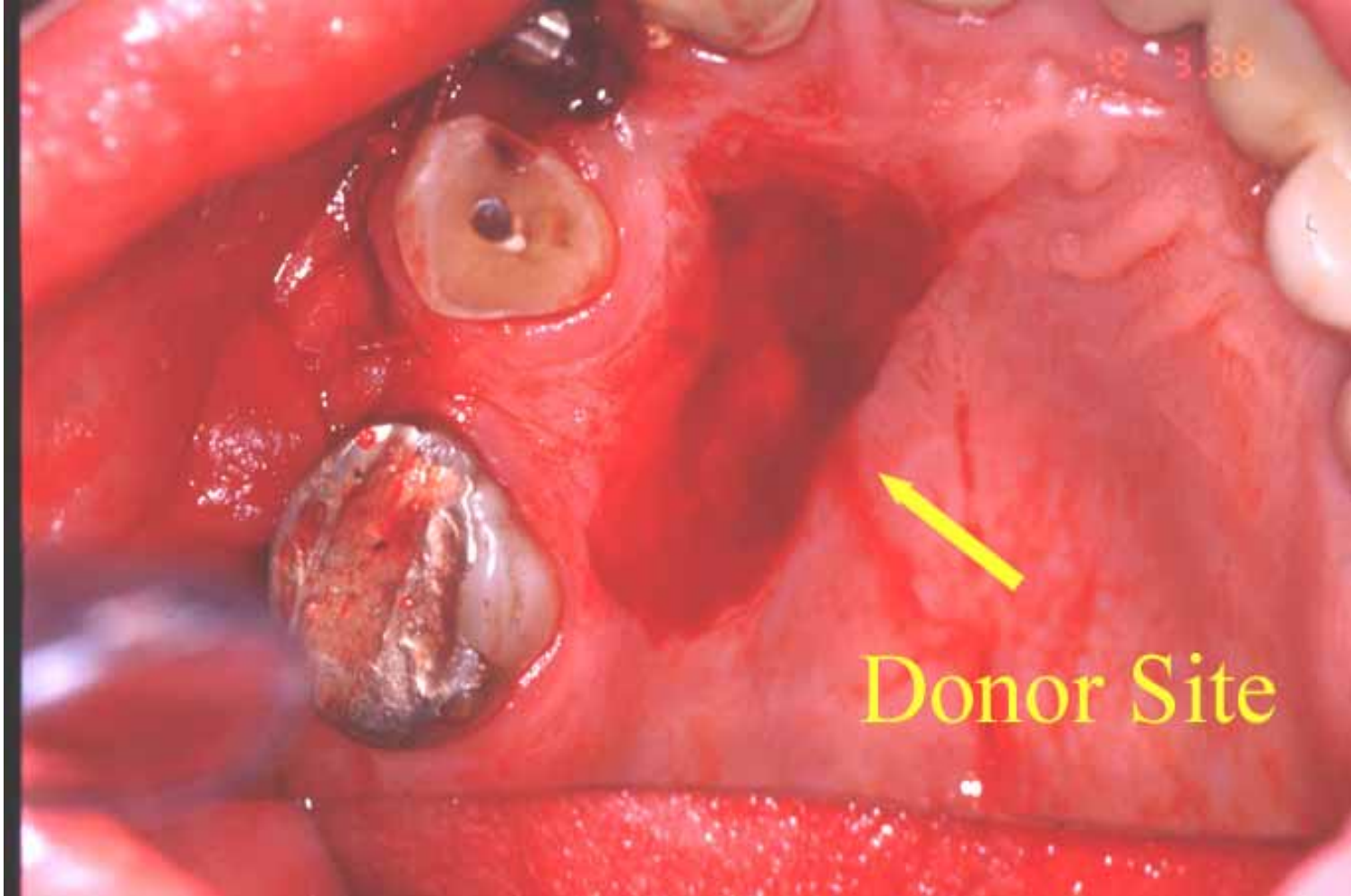


Flap sutured to Periosteum

15 9 88

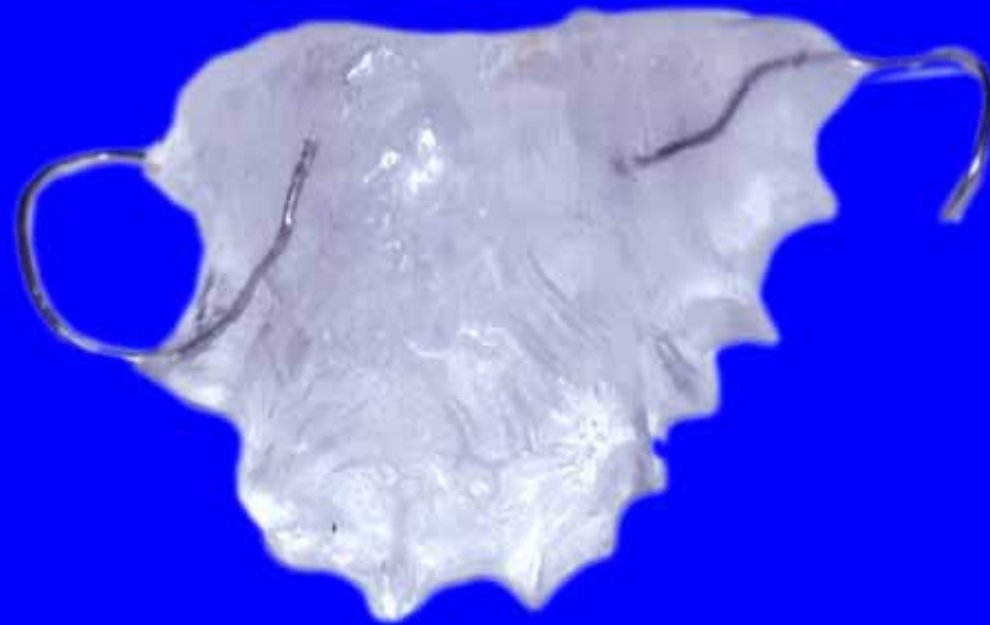

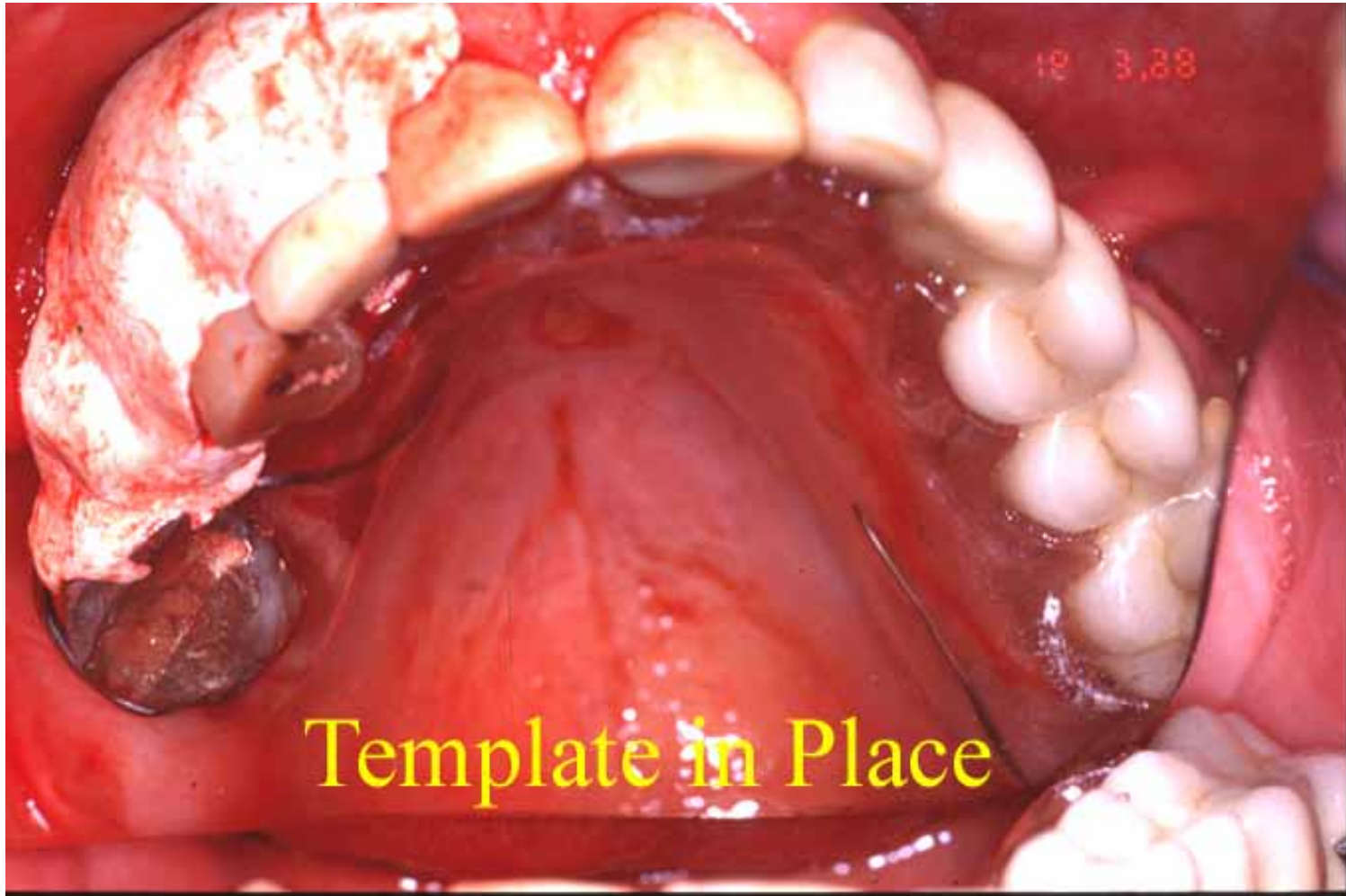
Coepak in Place



Donor Site

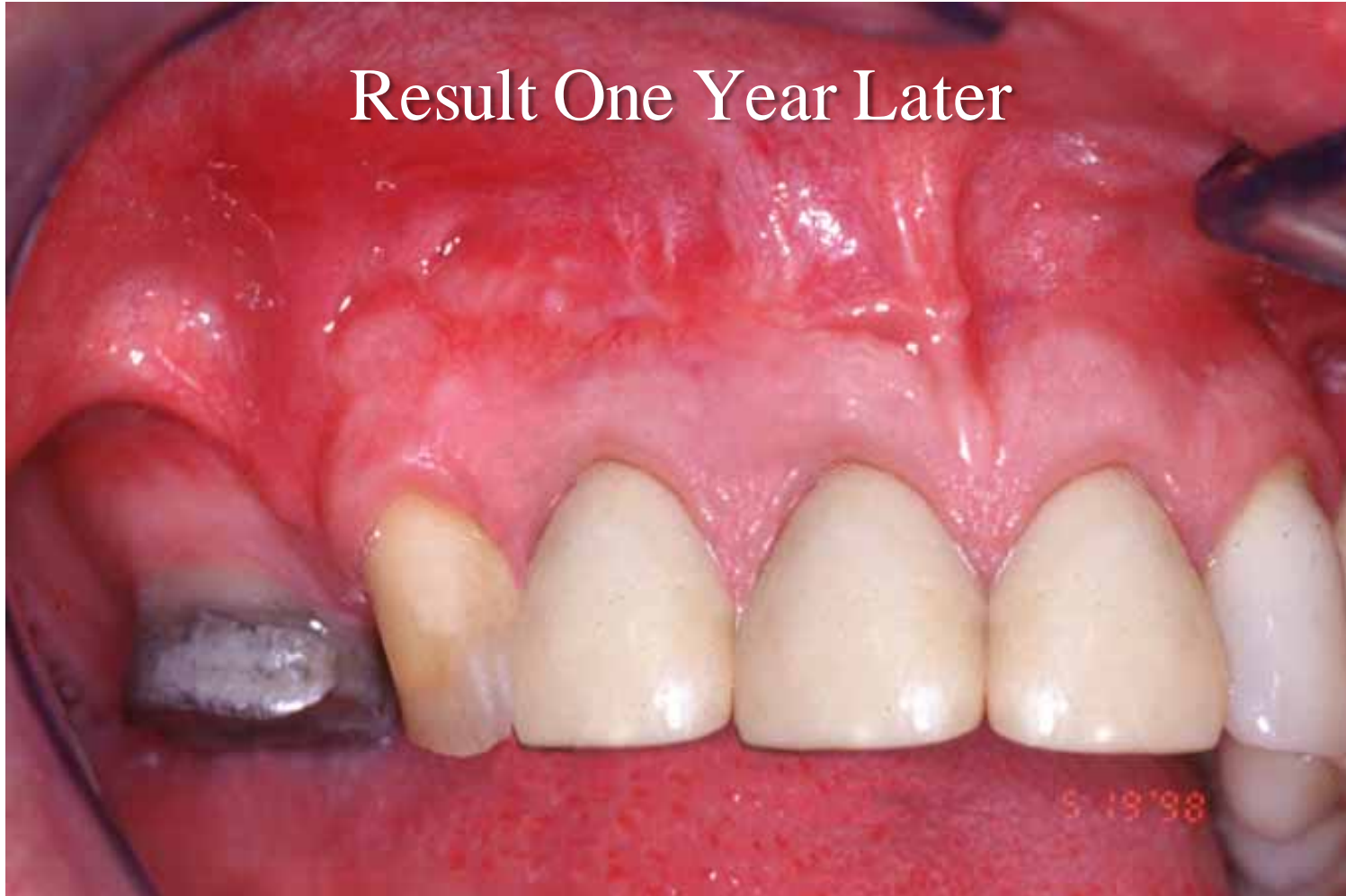Palatal Template



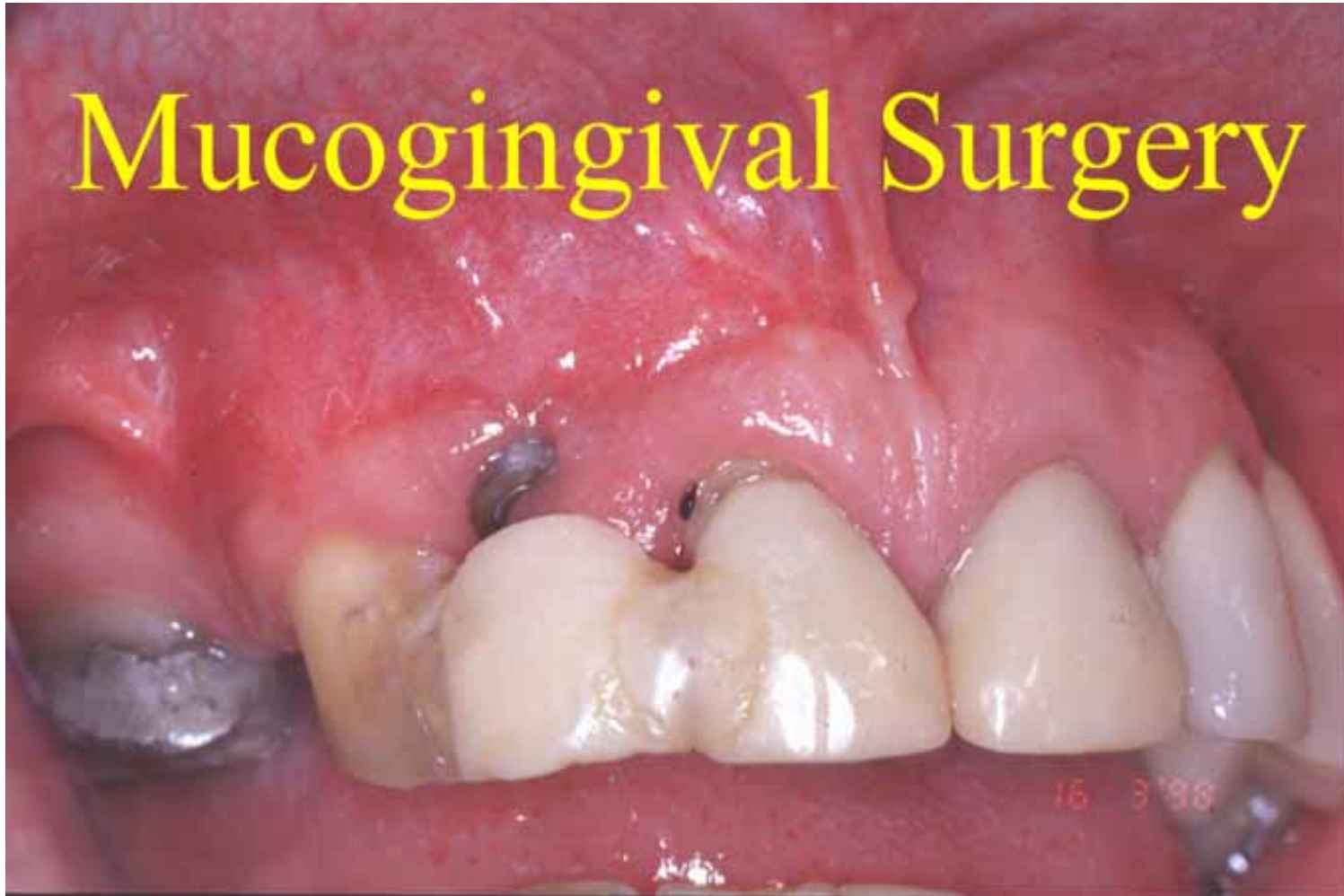

Template in Place

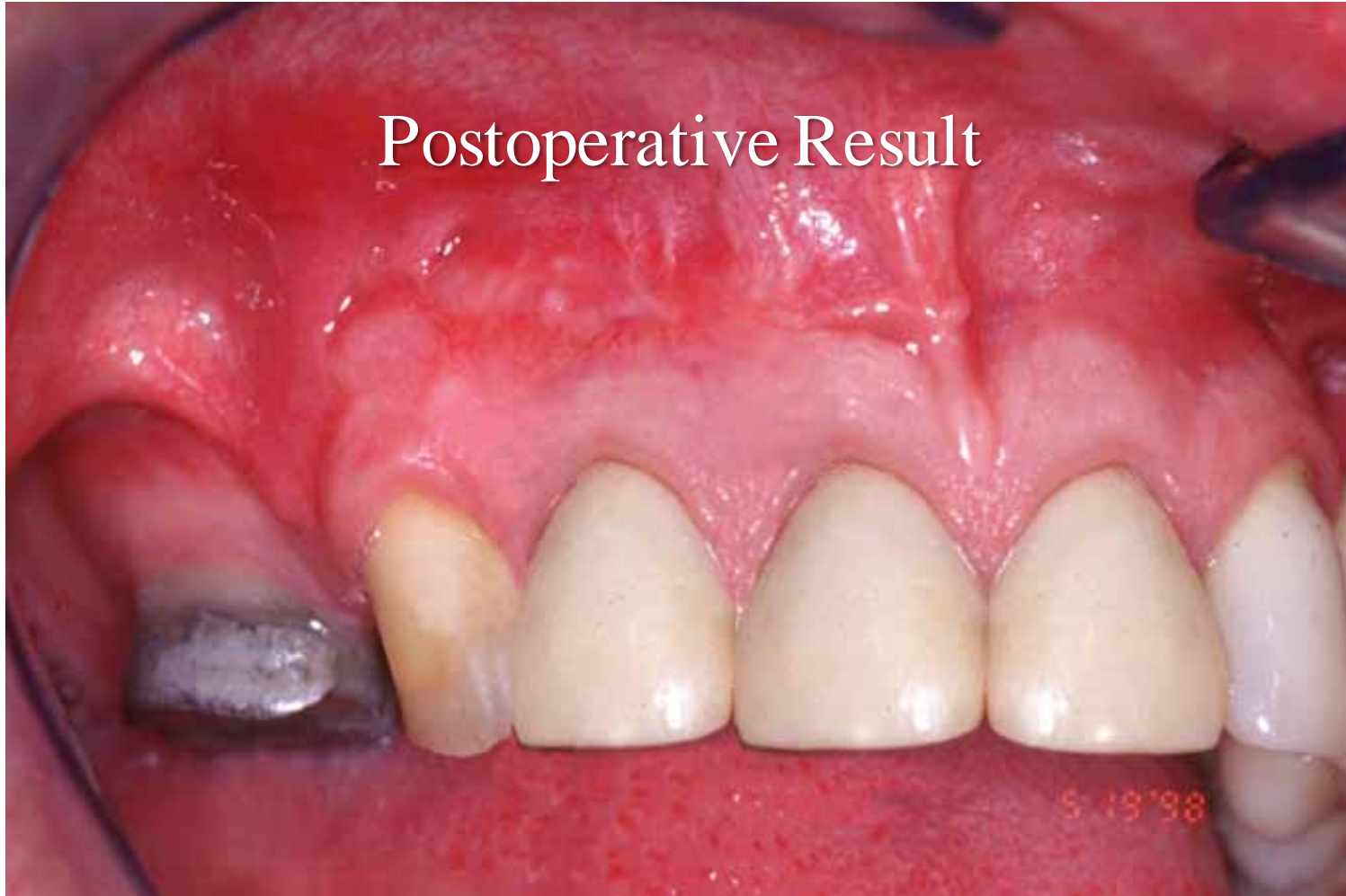Result One Year Later



Mucogingival Surgery



Postoperative Result



Postoperative Result

The End

5-19-98

