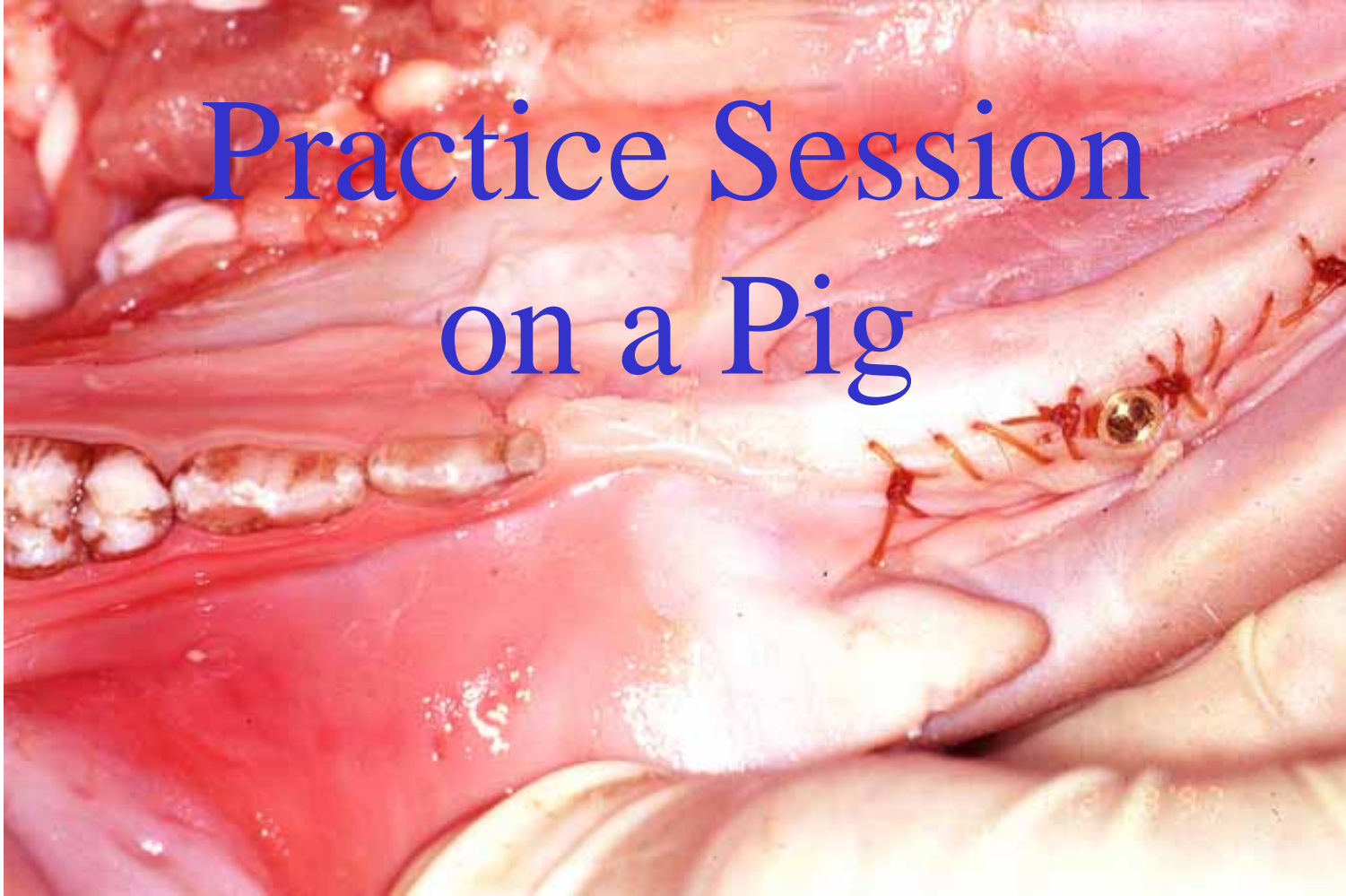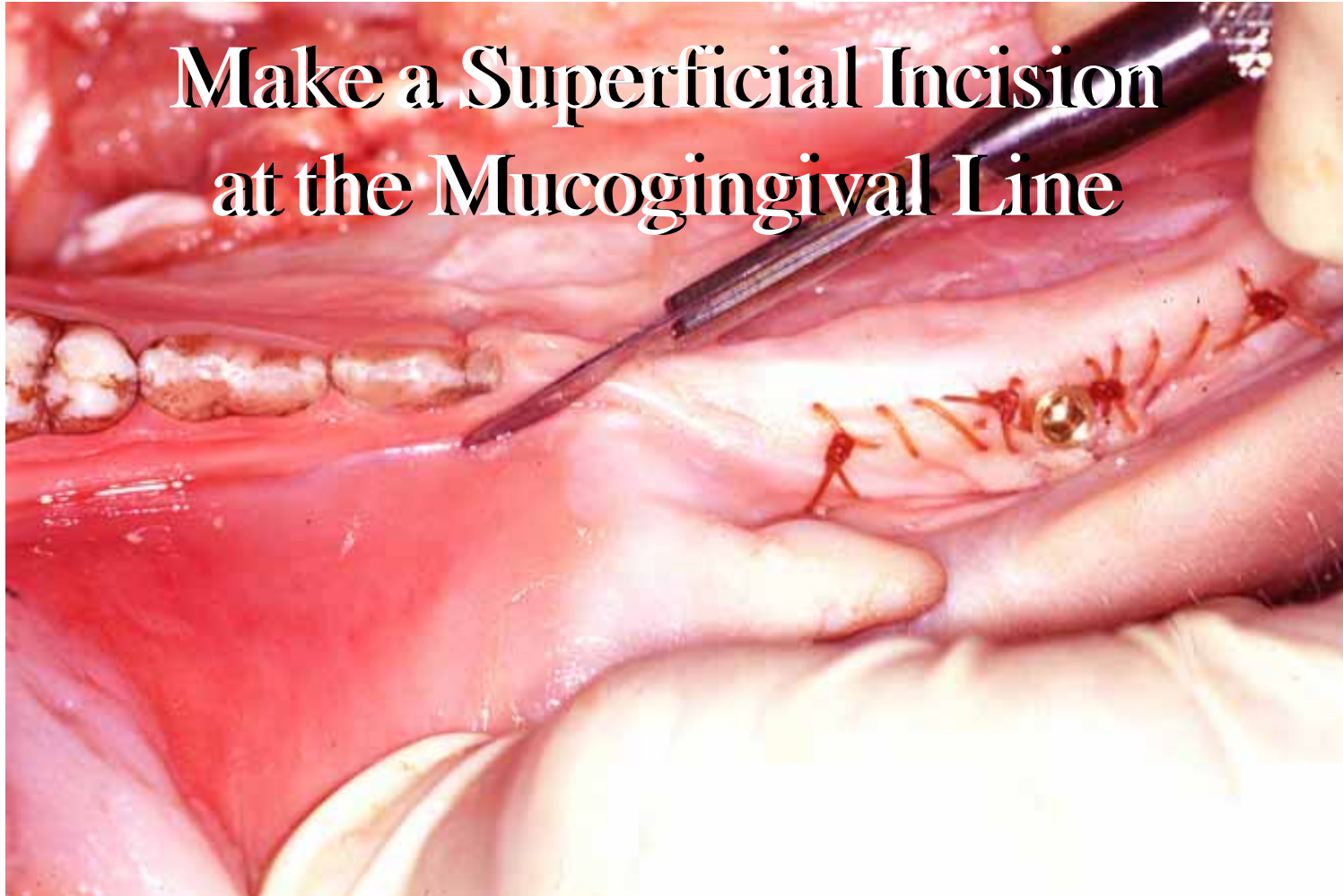An intraoperative photograph showing a surgical procedure on the gingiva. The image displays a flap of tissue being repositioned and secured with several sutures. The underlying bone and teeth are visible. The text 'Mucogingival Procedure Practice Procedure' is overlaid in white serif font on the central part of the image.

**Mucogingival
Procedure Practice
Procedure**

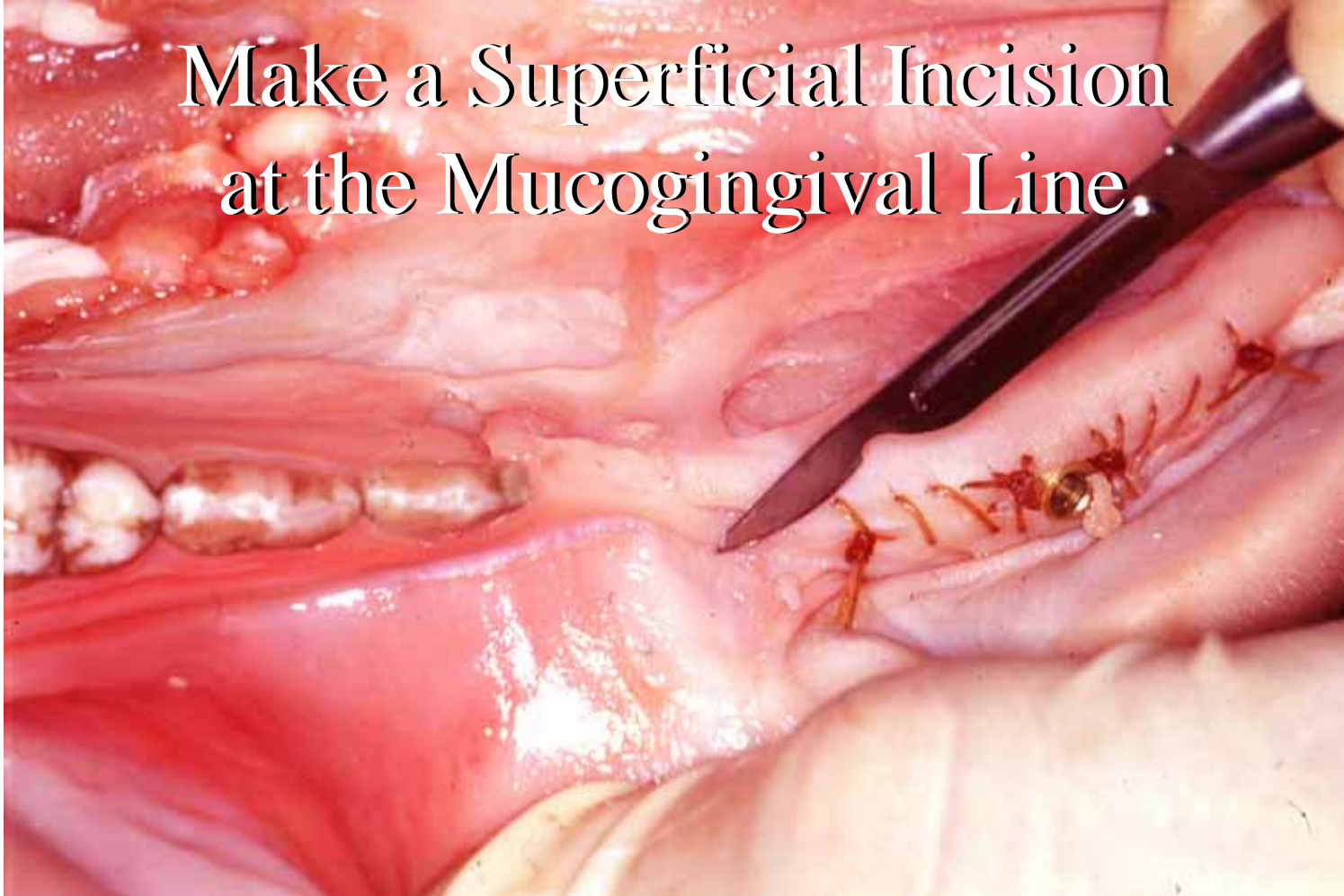Practice Session on a Pig



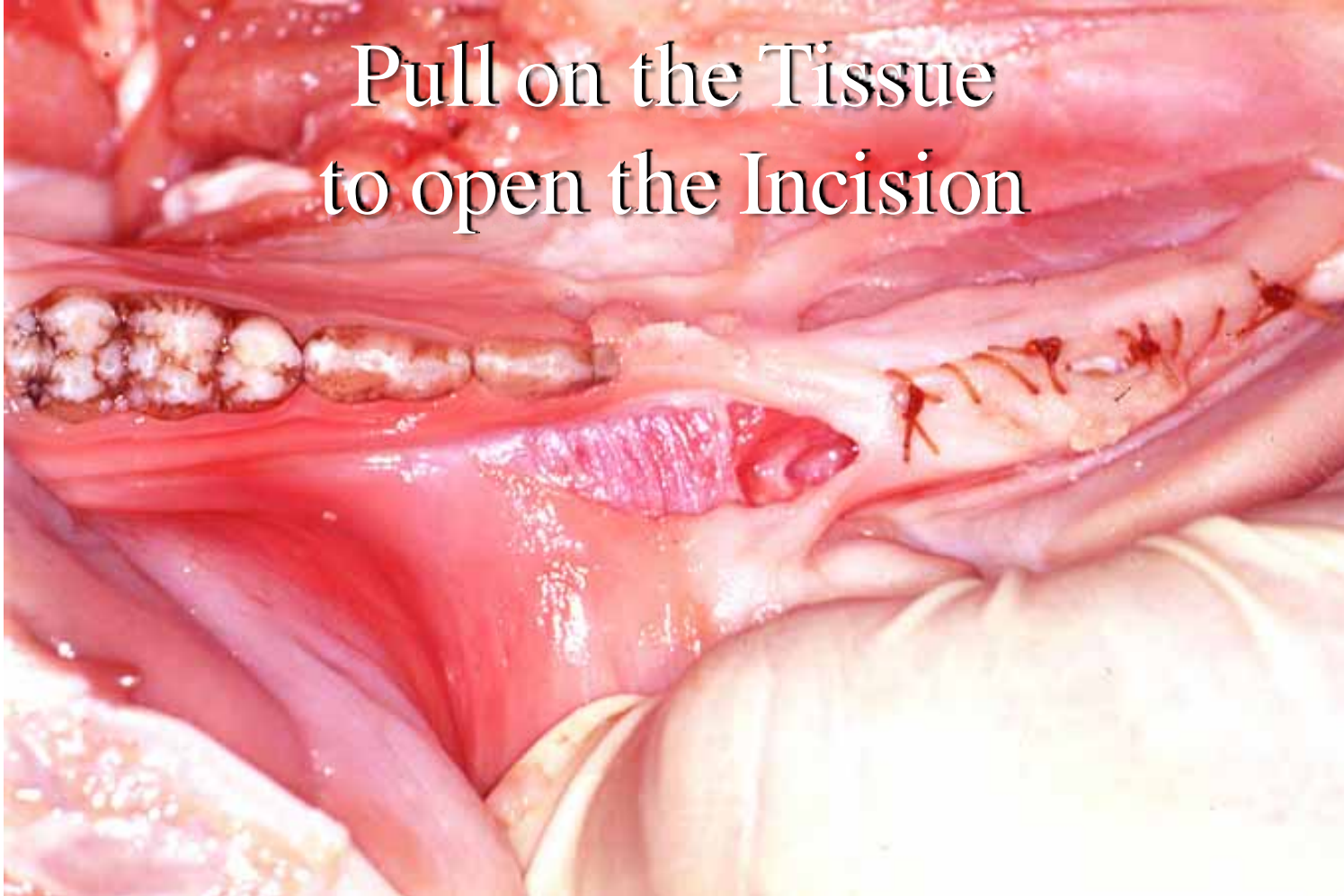
**Make a Superficial Incision
at the Mucogingival Line**



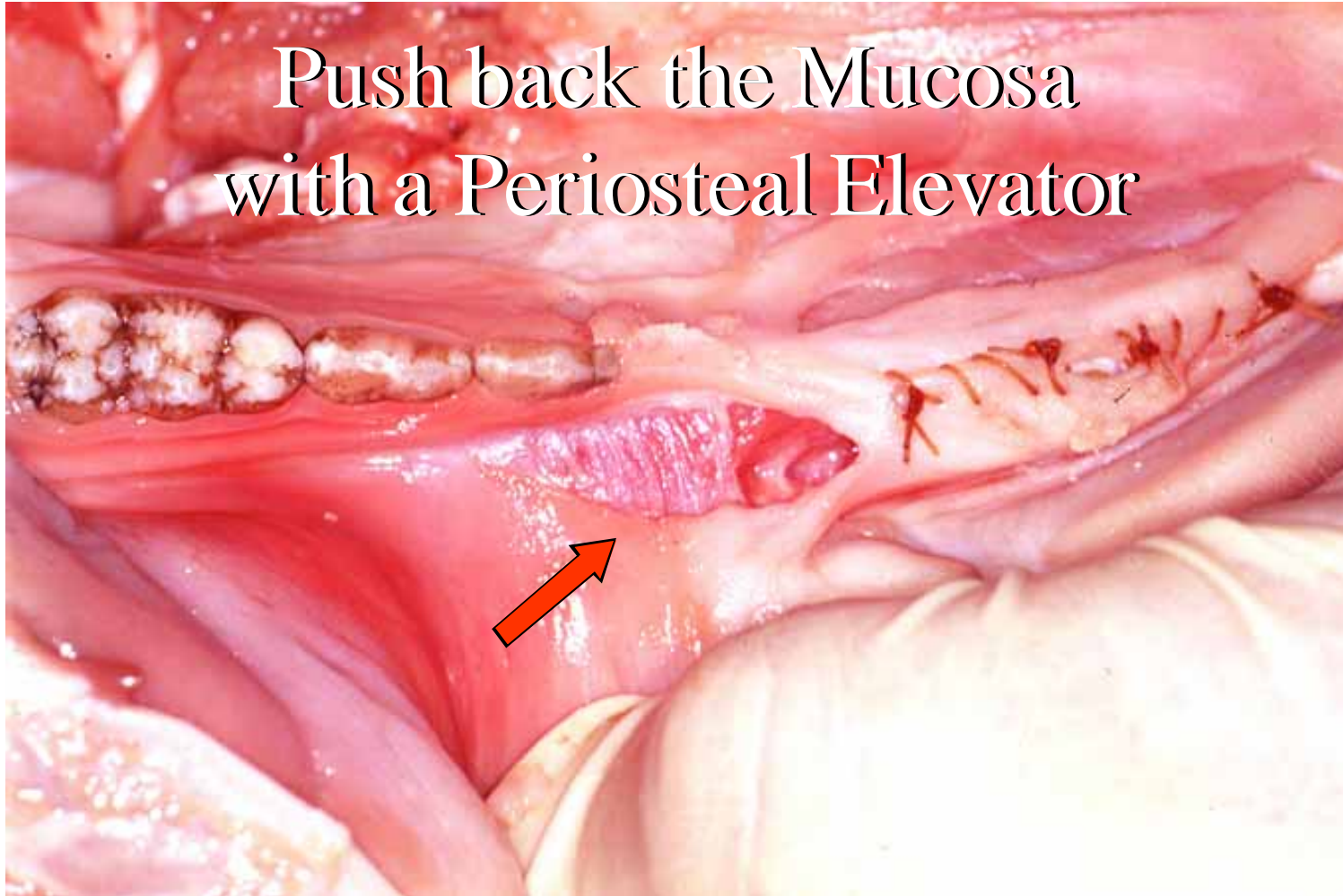
Make a Superficial Incision
at the Mucogingival Line



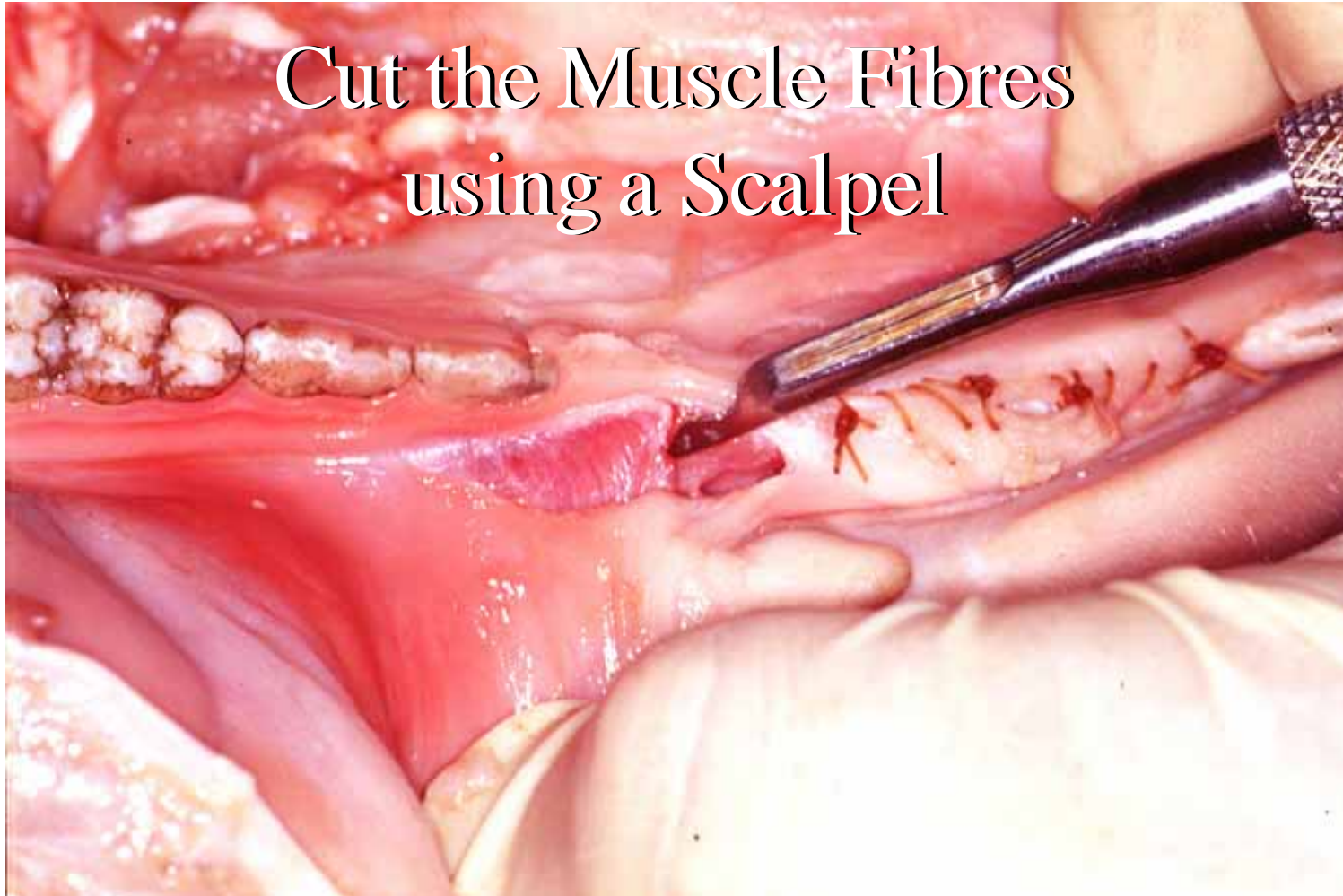
Pull on the Tissue
to open the Incision



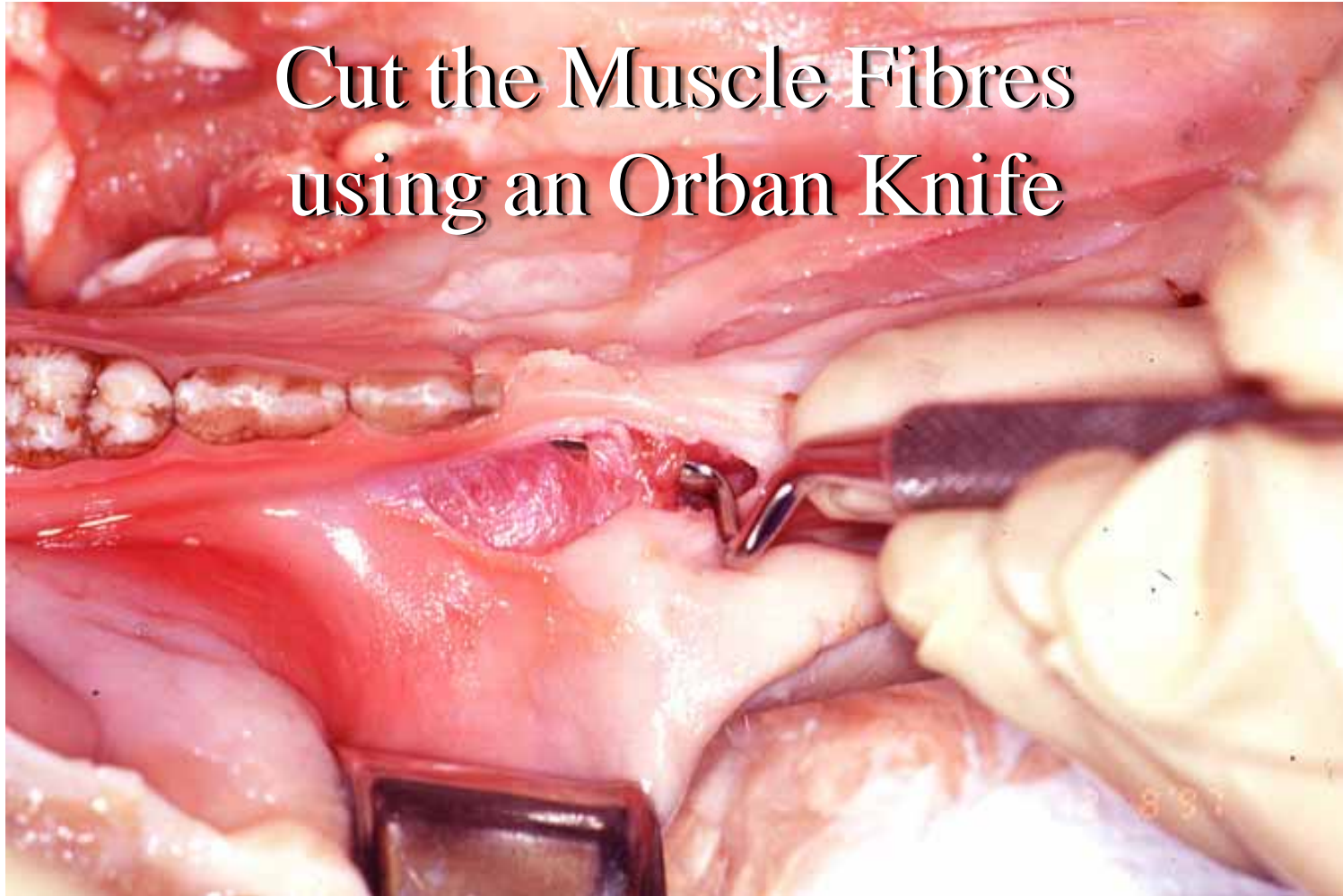Push back the Mucosa
with a Periosteal Elevator



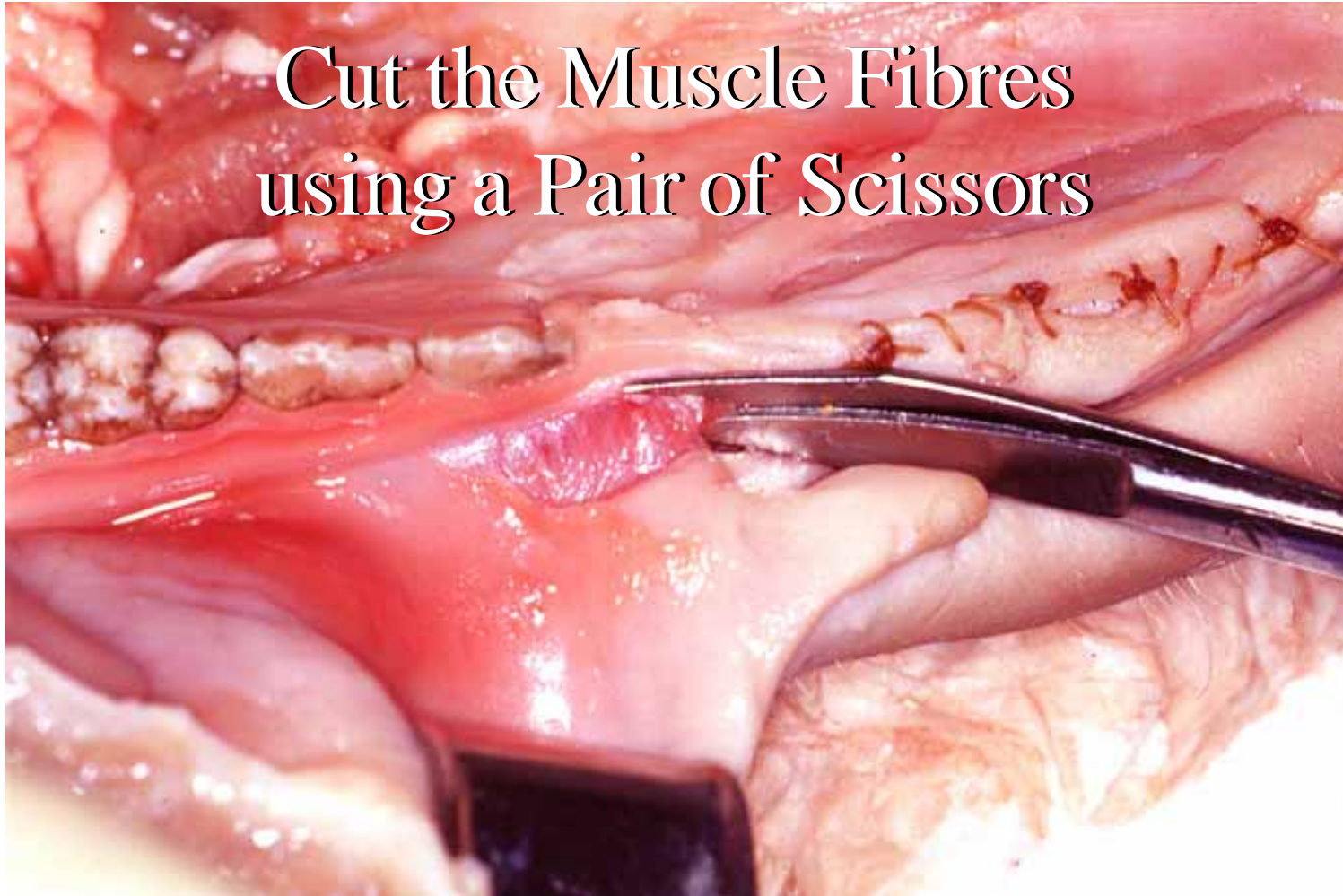
Cut the Muscle Fibres
using a Scalpel



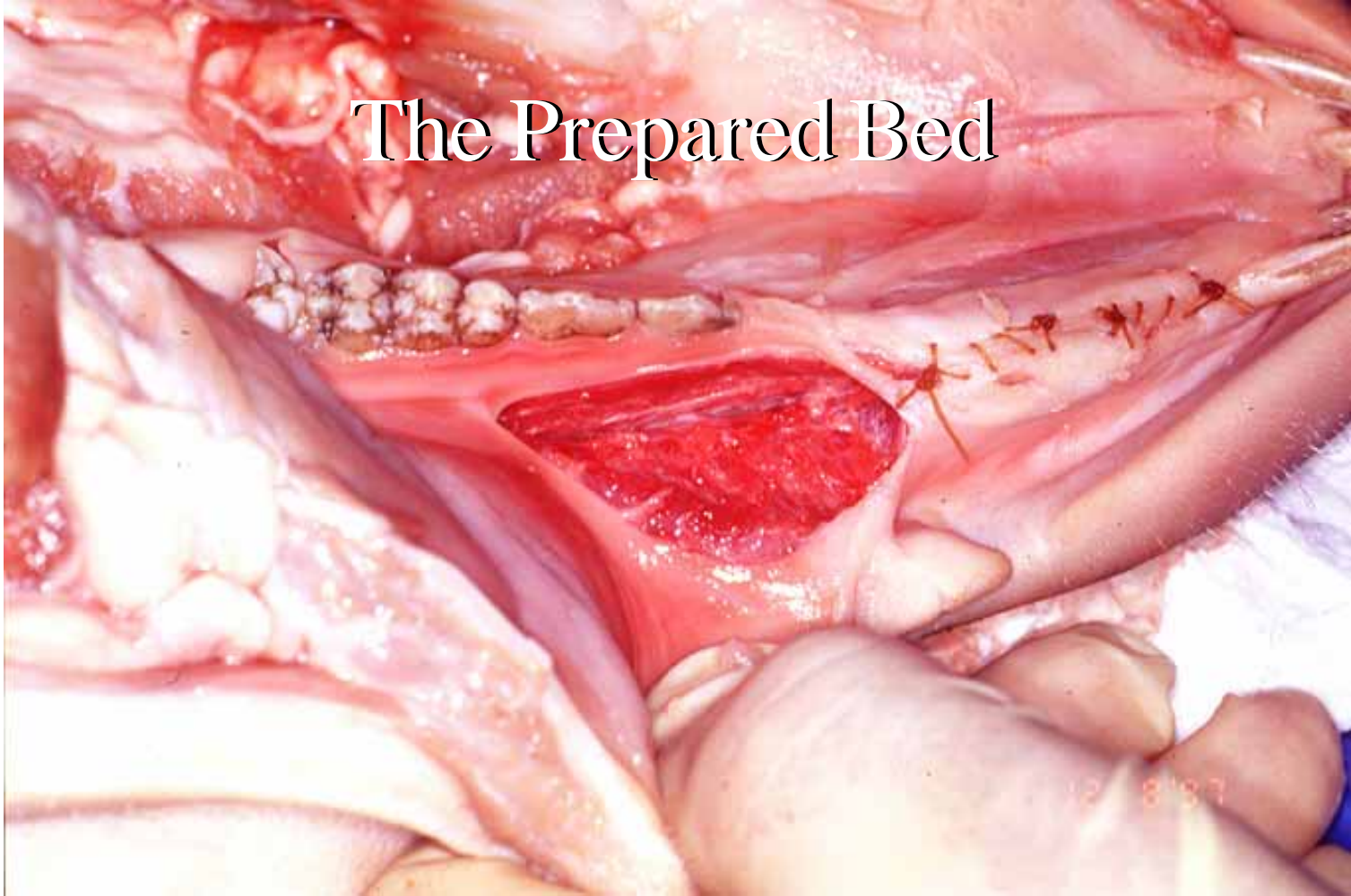
Cut the Muscle Fibres
using an Orban Knife



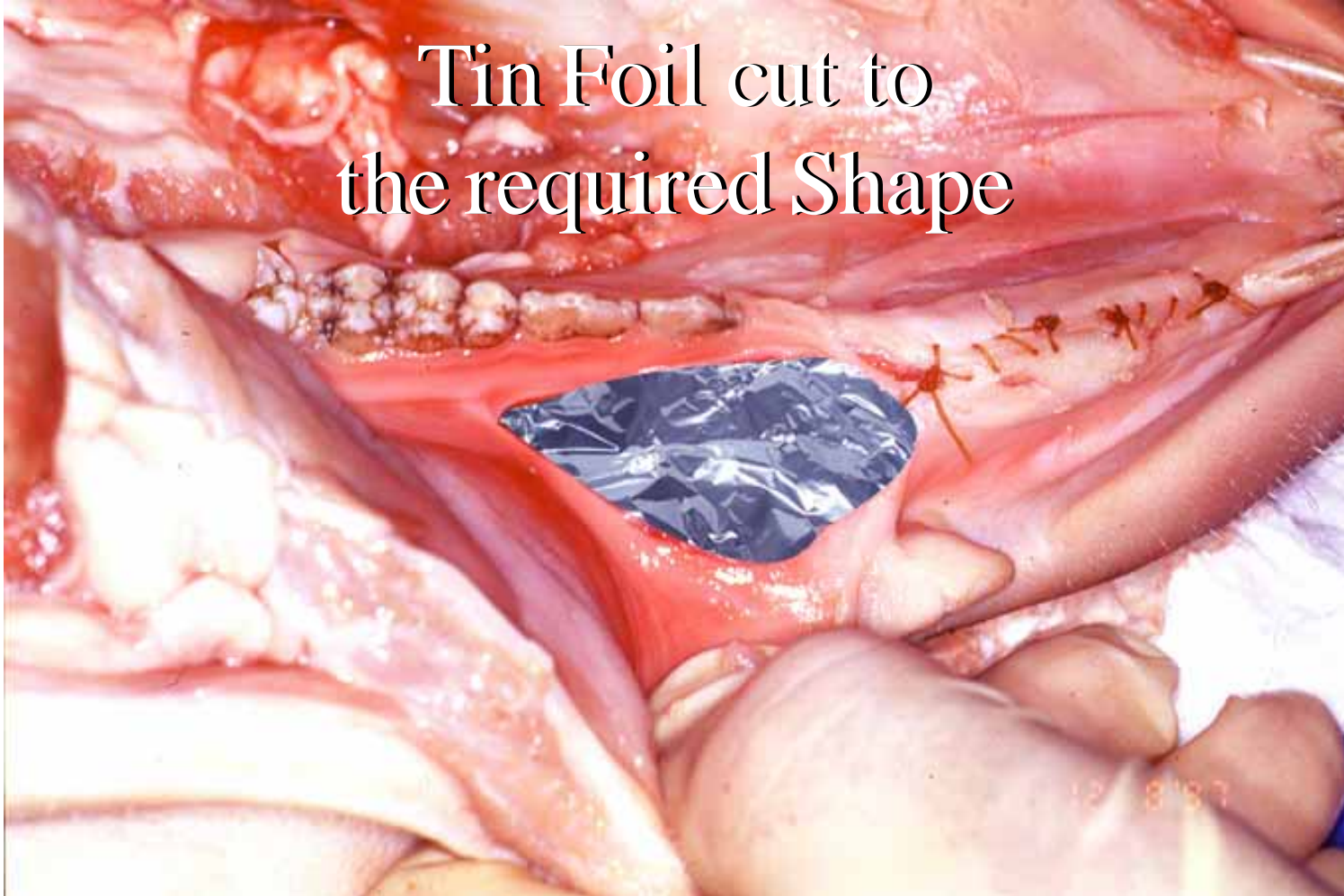
Cut the Muscle Fibres
using a Pair of Scissors



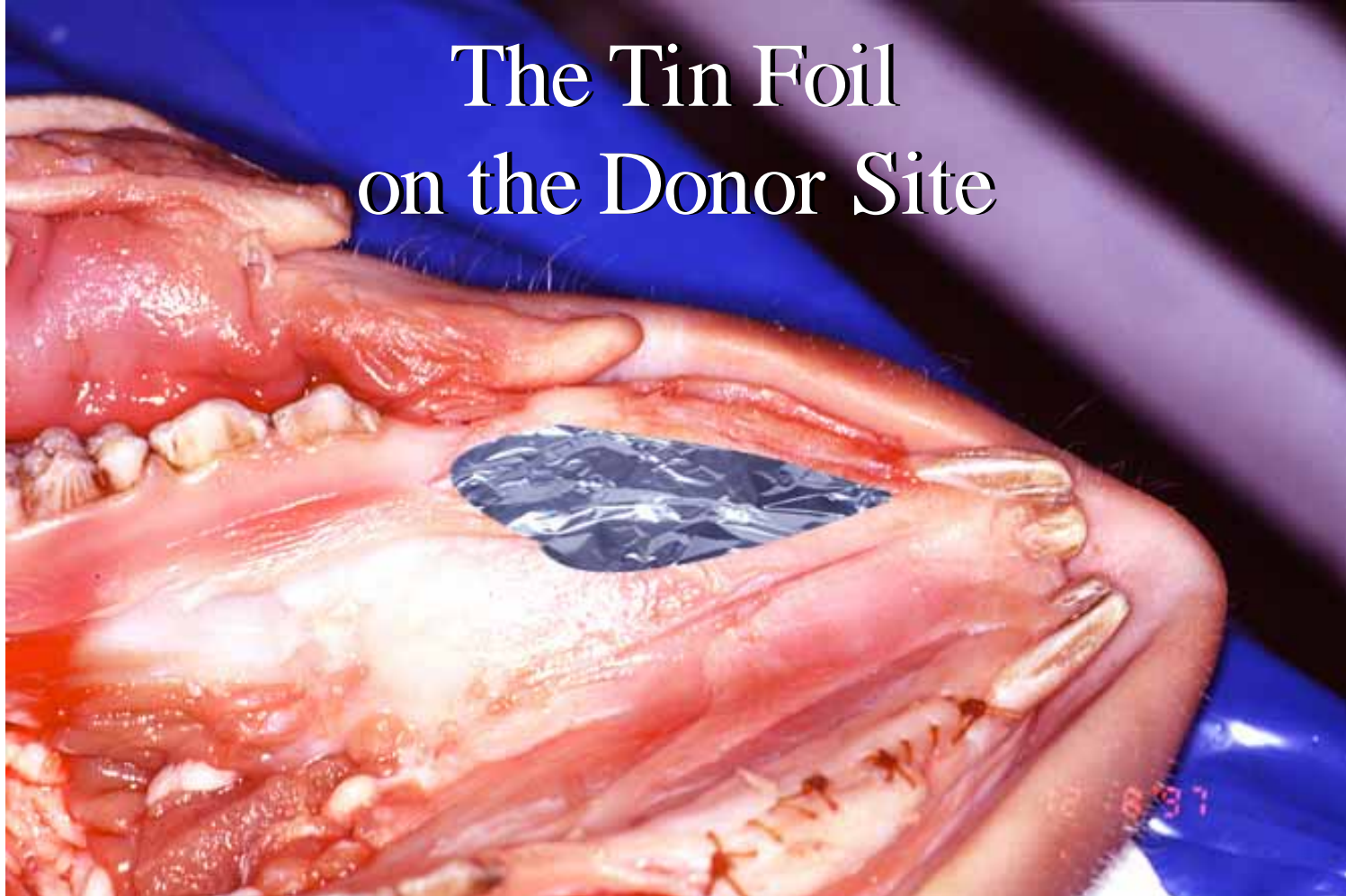
The Prepared Bed



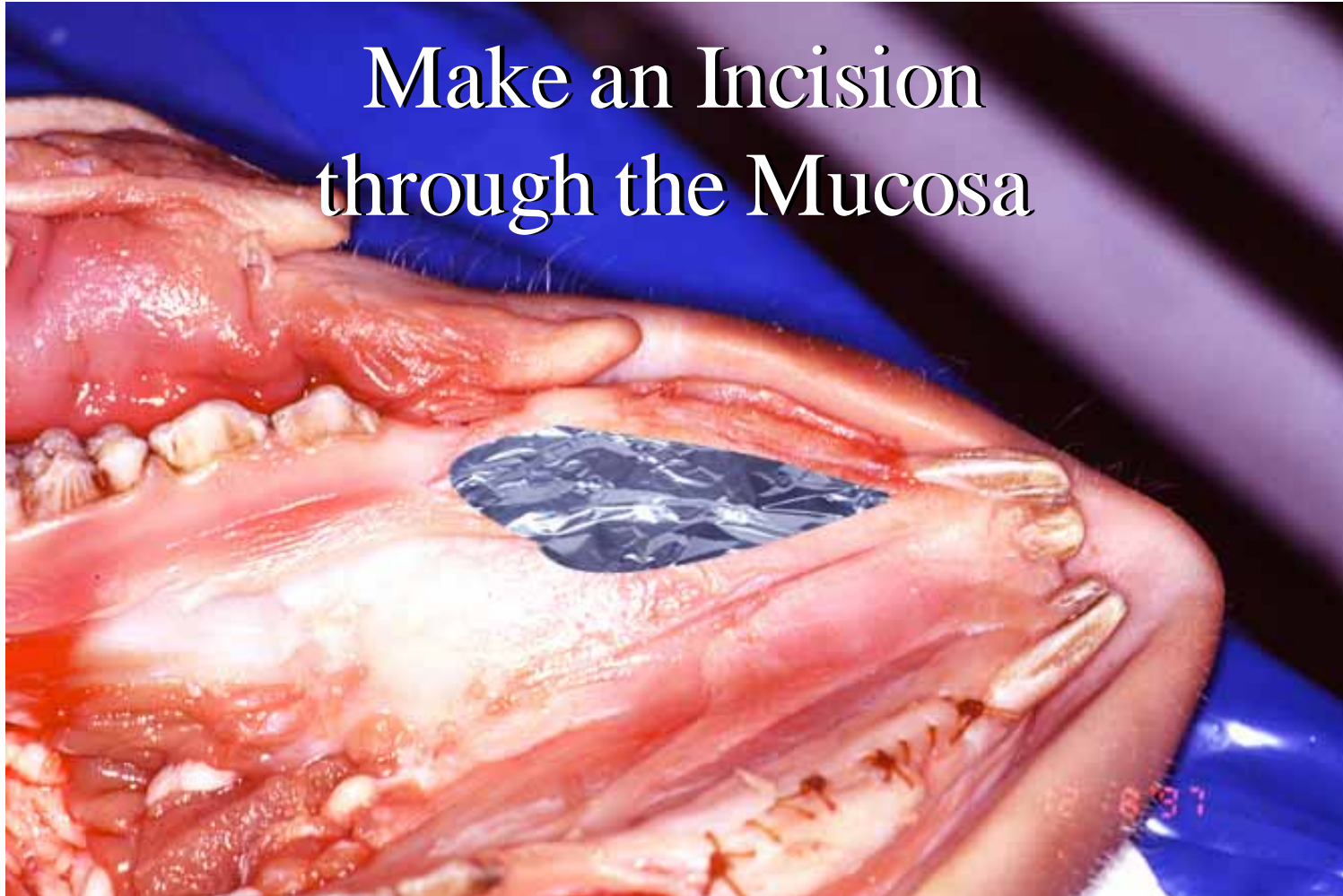
Tin Foil cut to
the required Shape



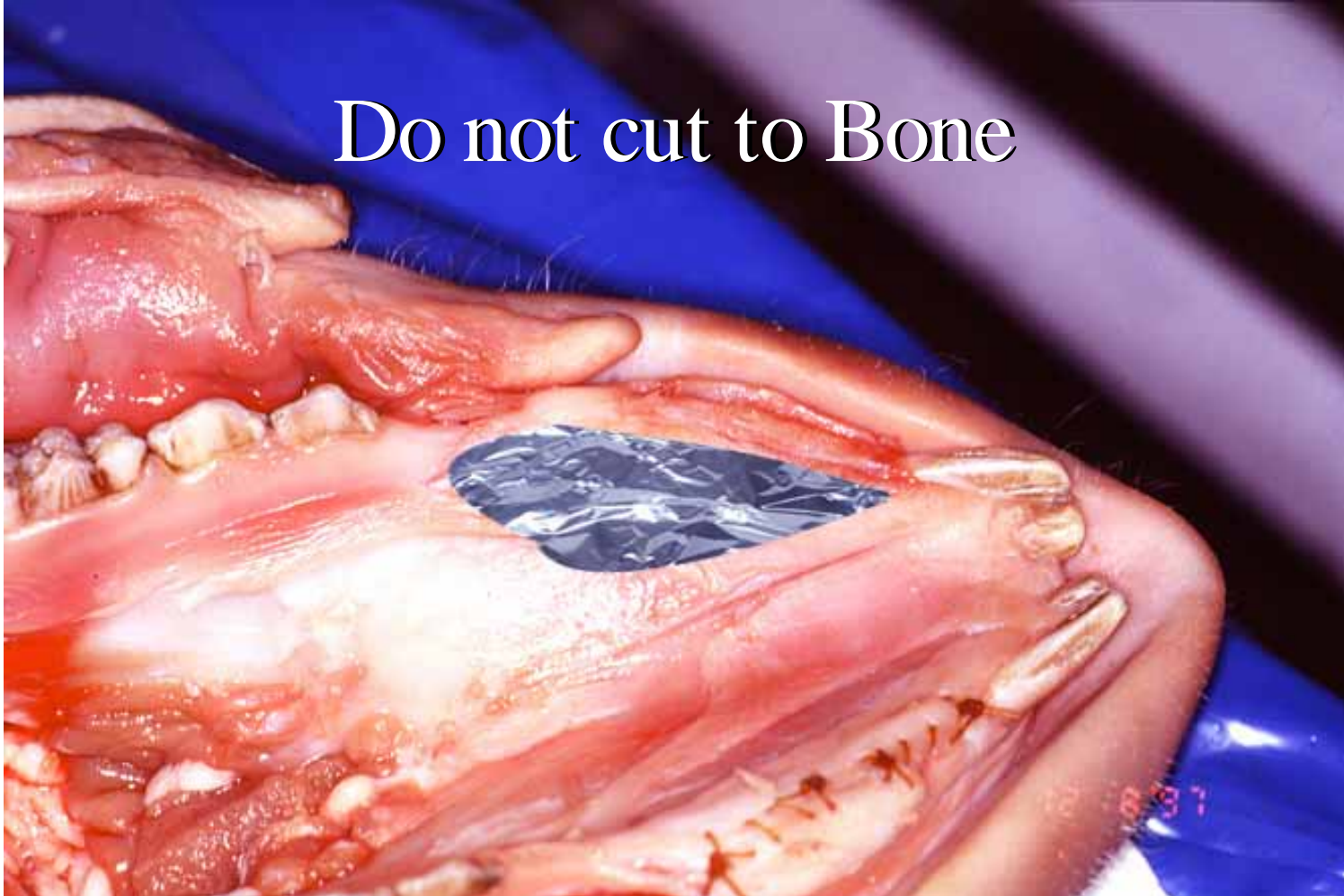
The Tin Foil on the Donor Site



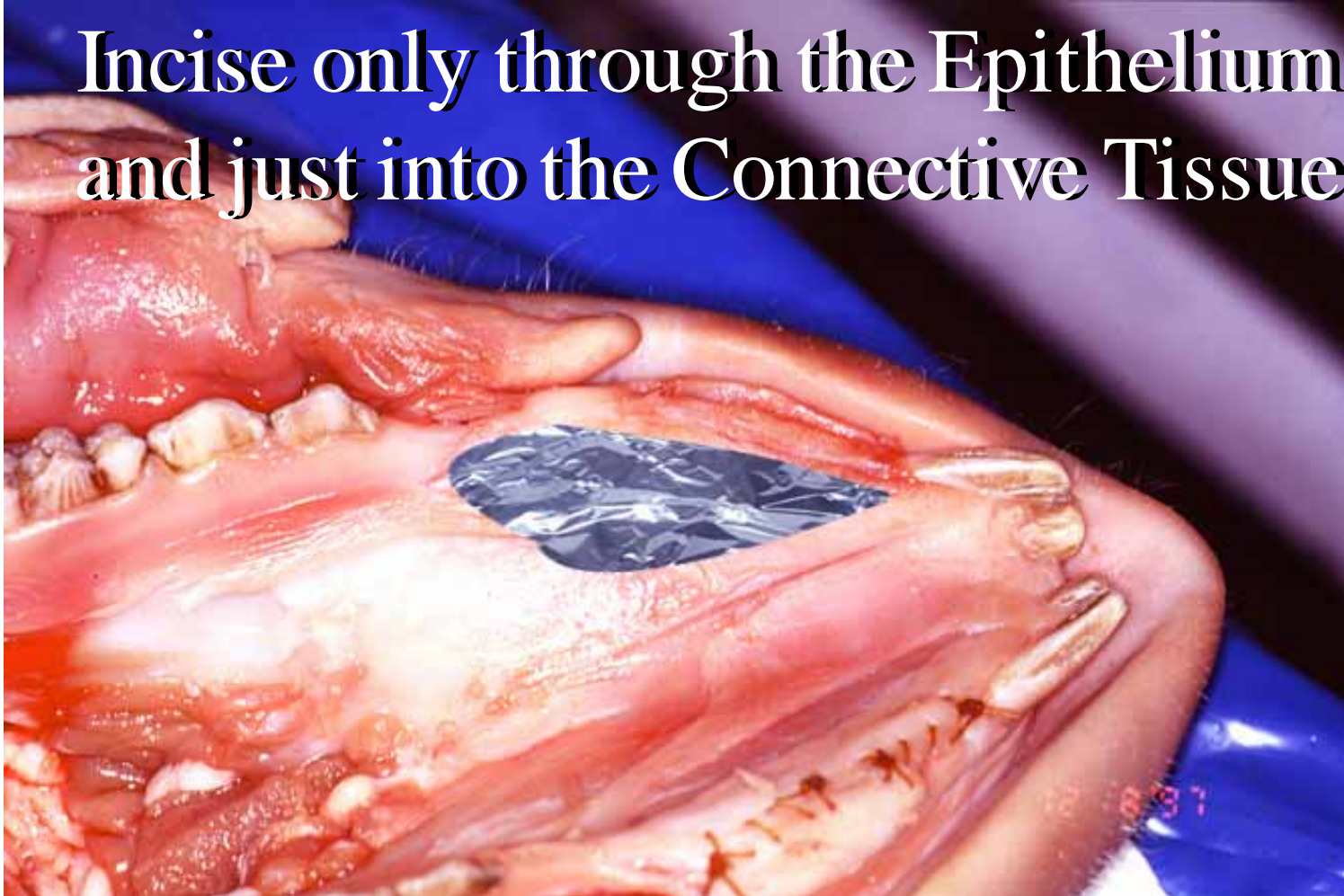
Make an Incision
through the Mucosa



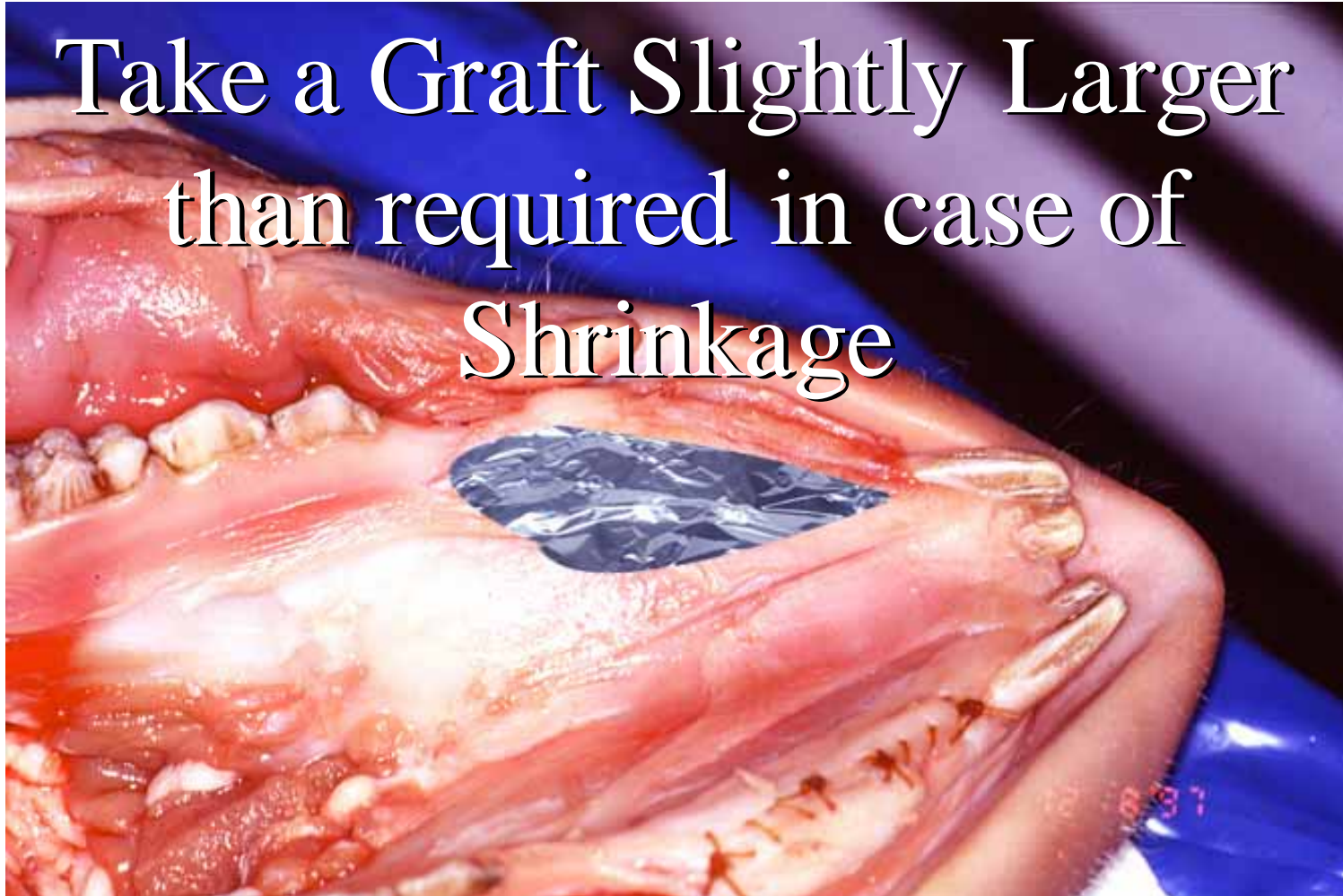Do not cut to Bone

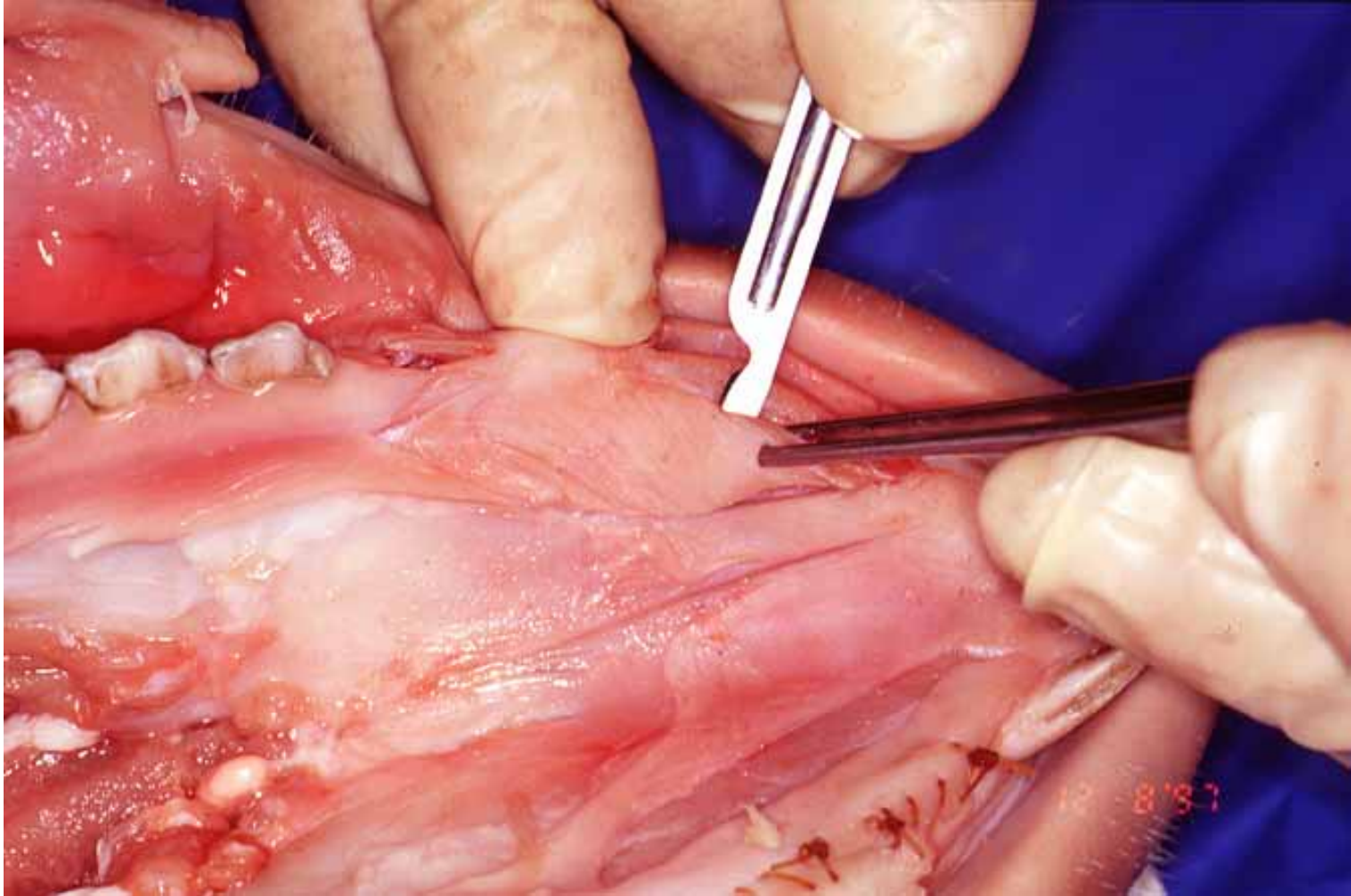


**Incise only through the Epithelium
and just into the Connective Tissue**

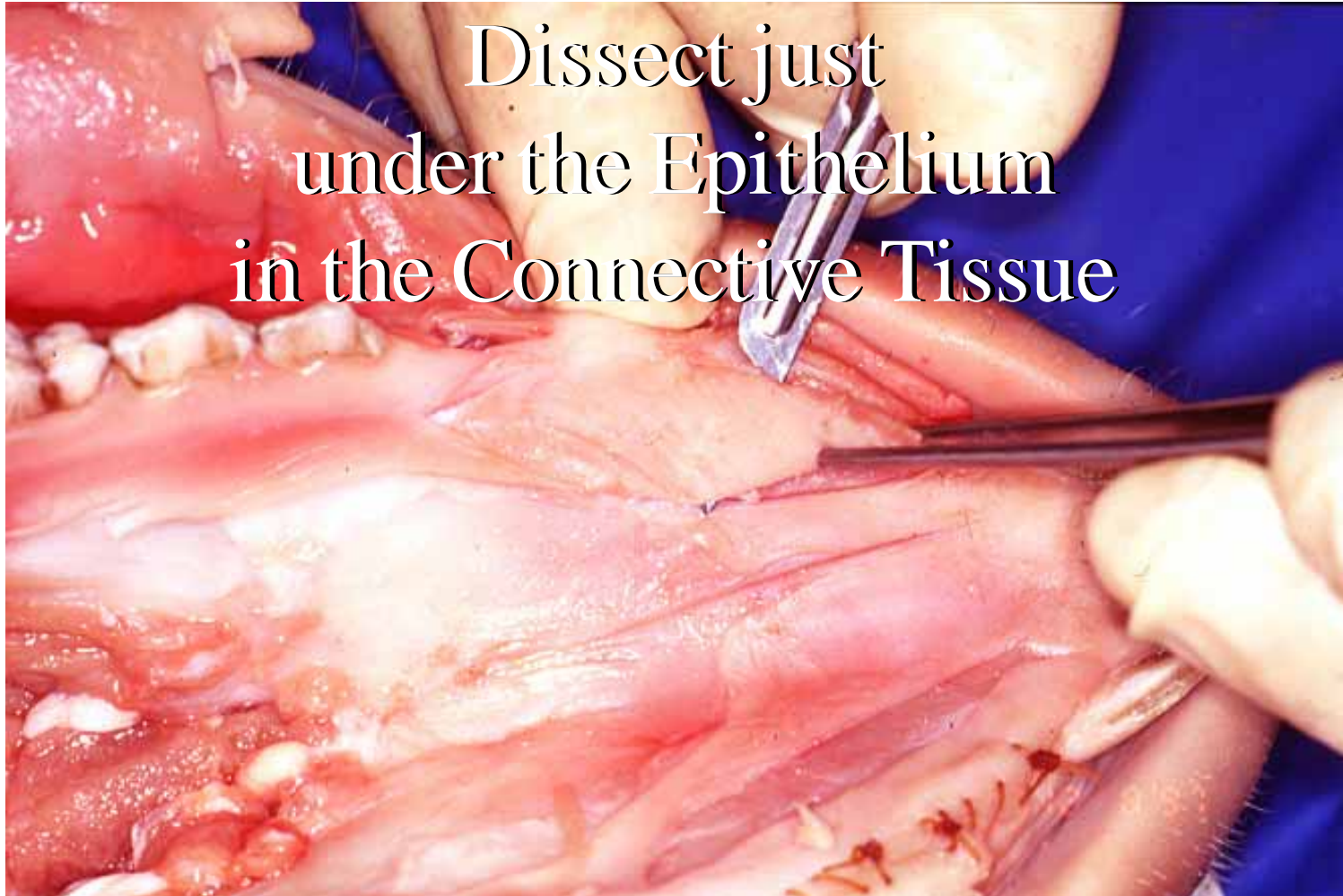

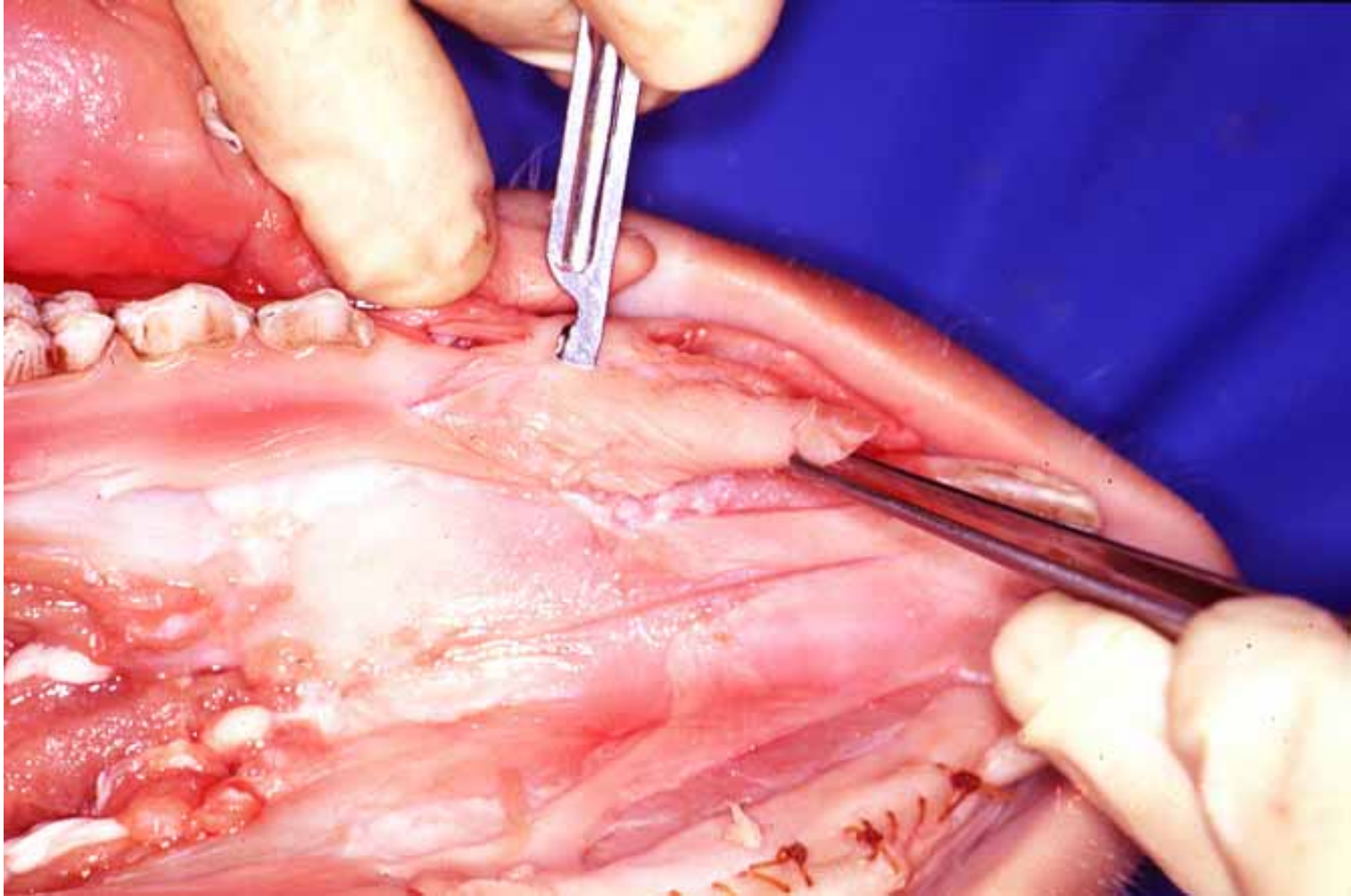
Take a Graft Slightly Larger
than required in case of
Shrinkage

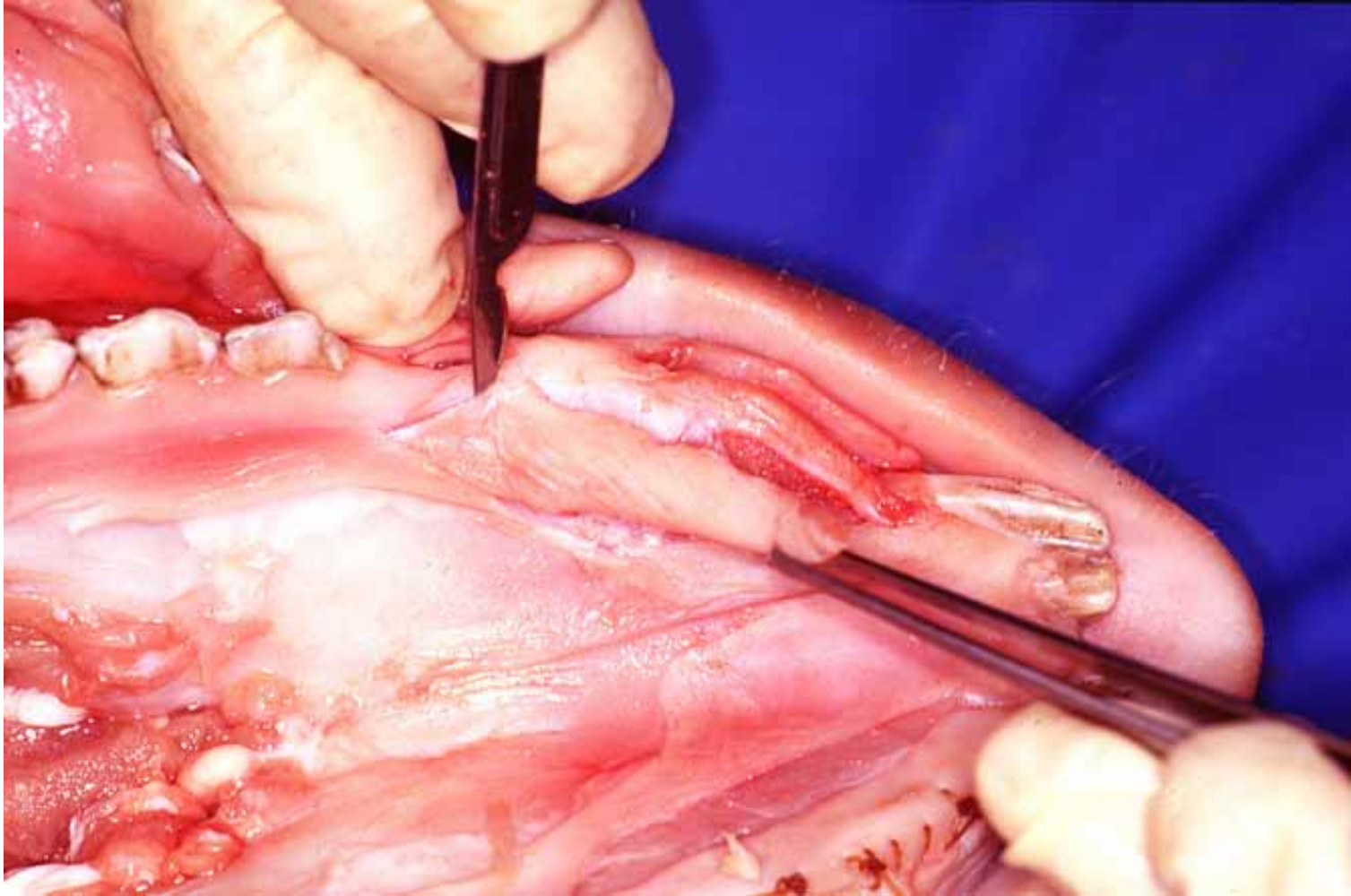


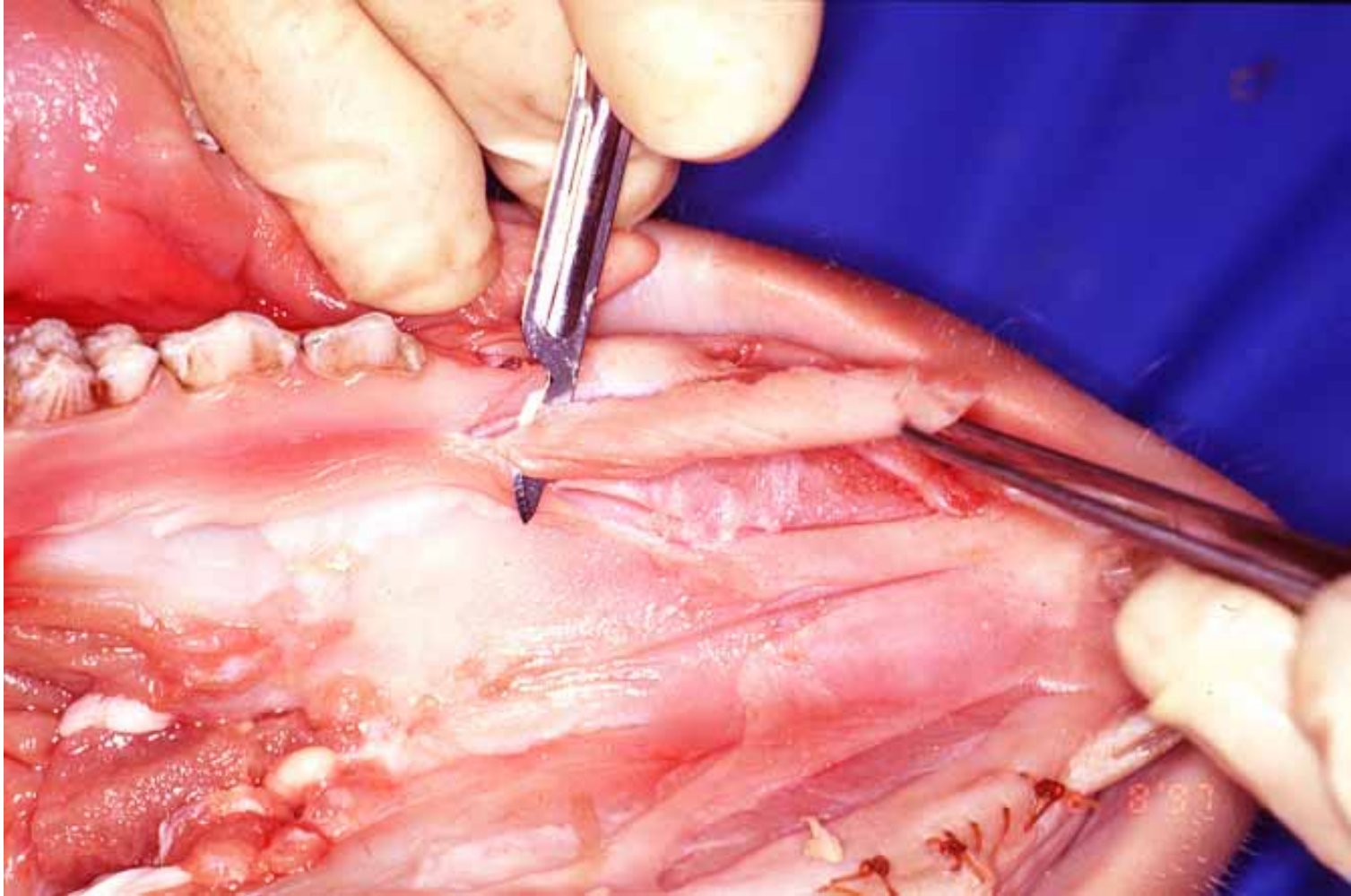


Dissect just
under the Epithelium
in the Connective Tissue

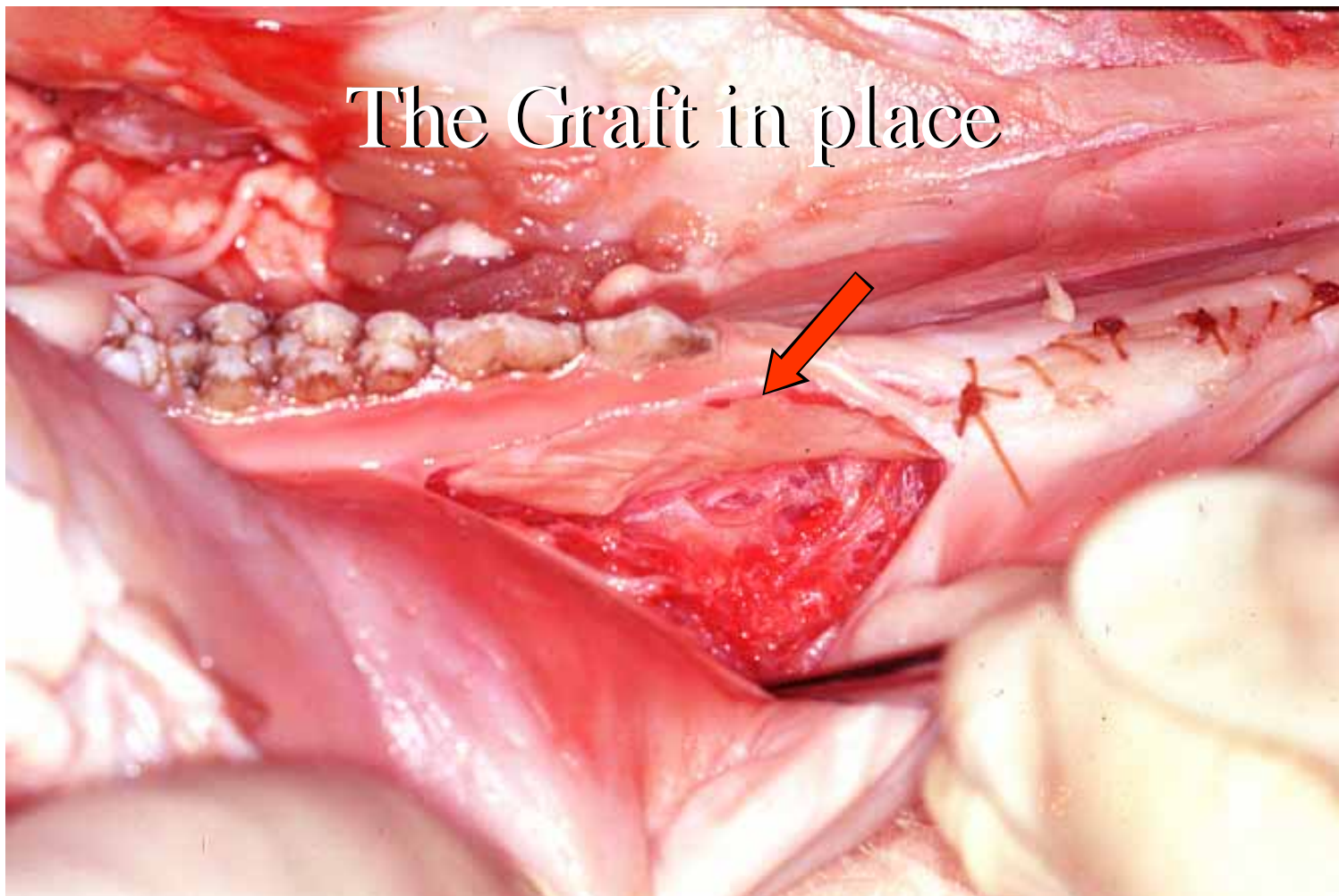




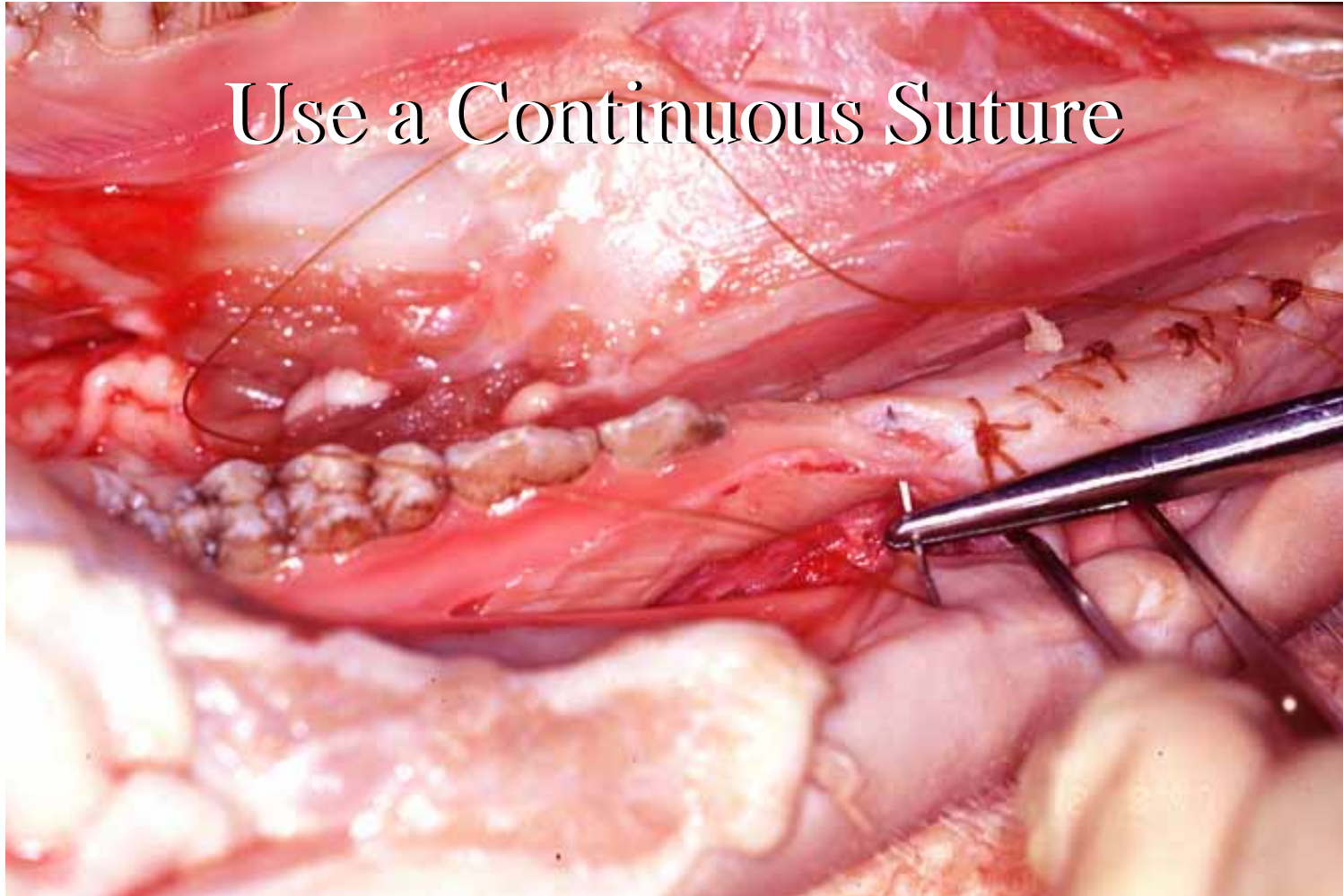




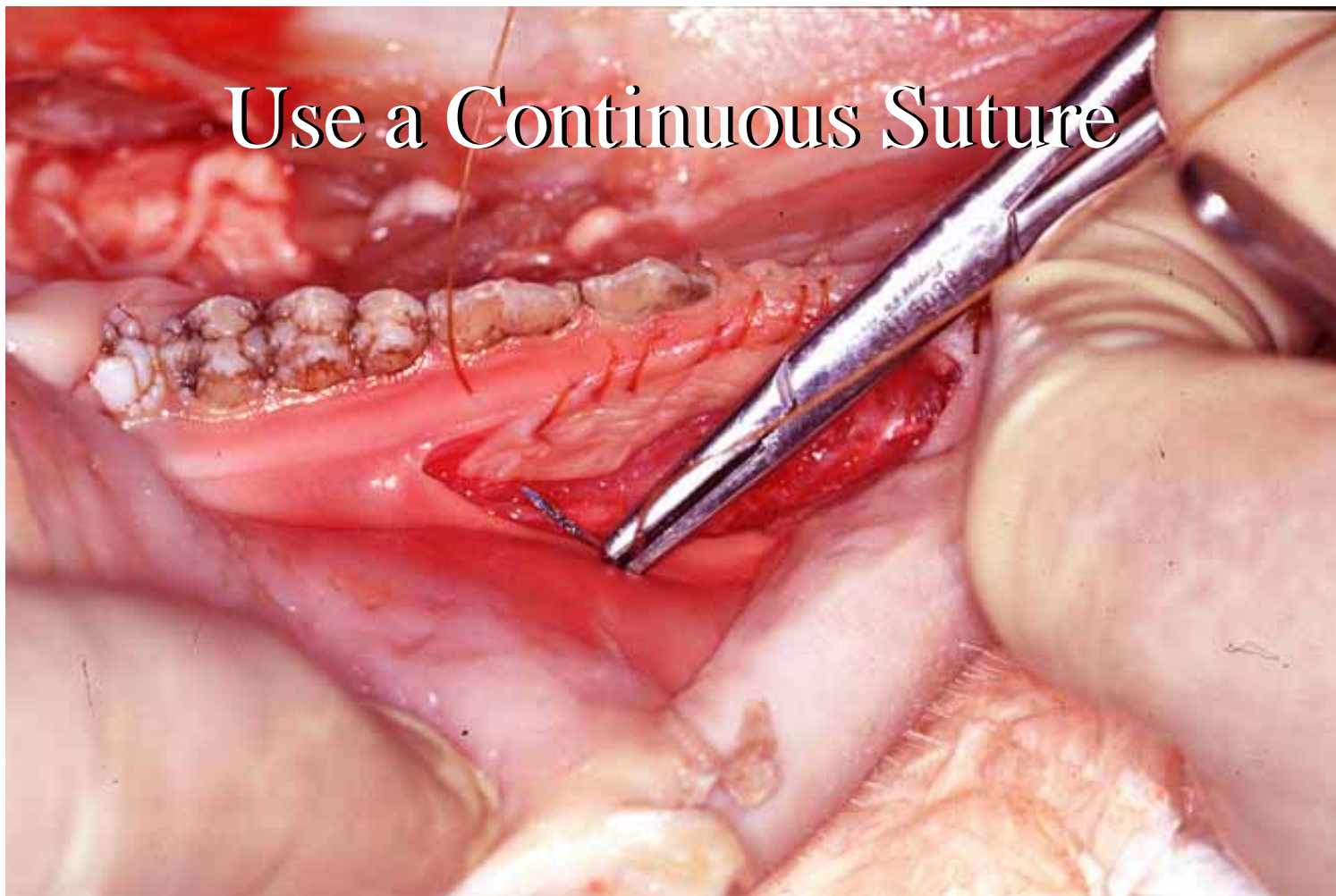
The Graft in place



Use a Continuous Suture



Use a Continuous Suture



Use a Continuous Suture

