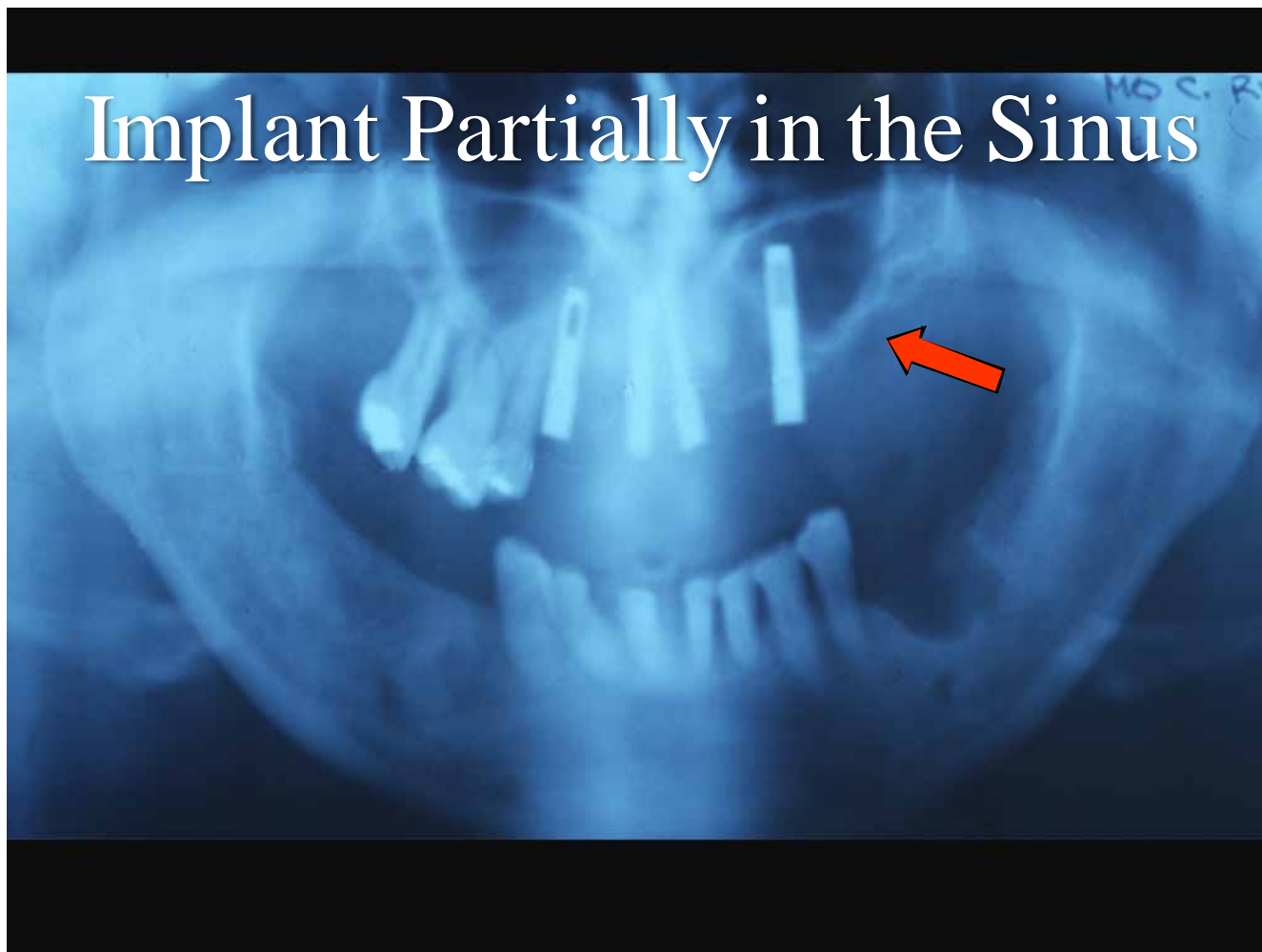
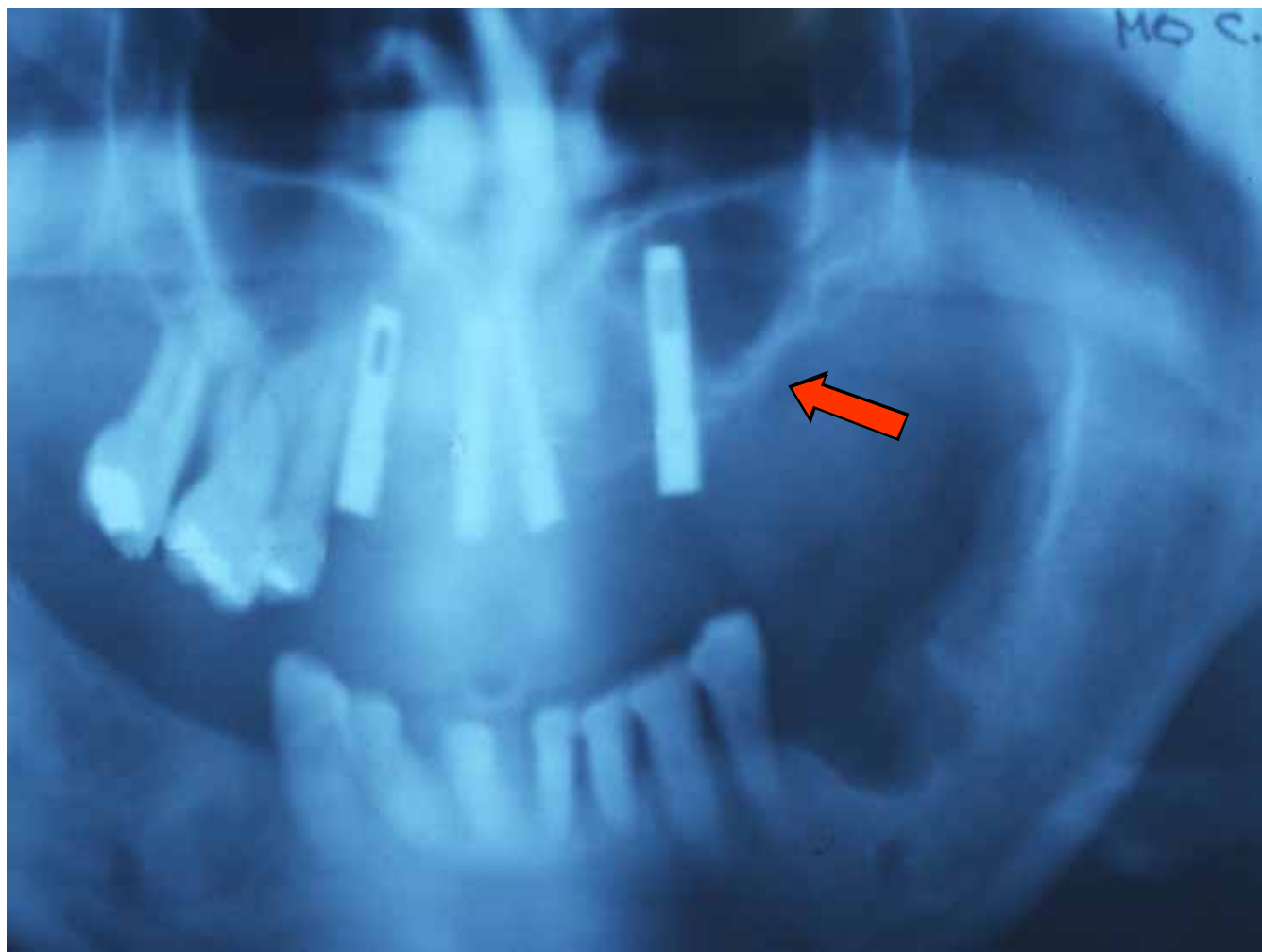
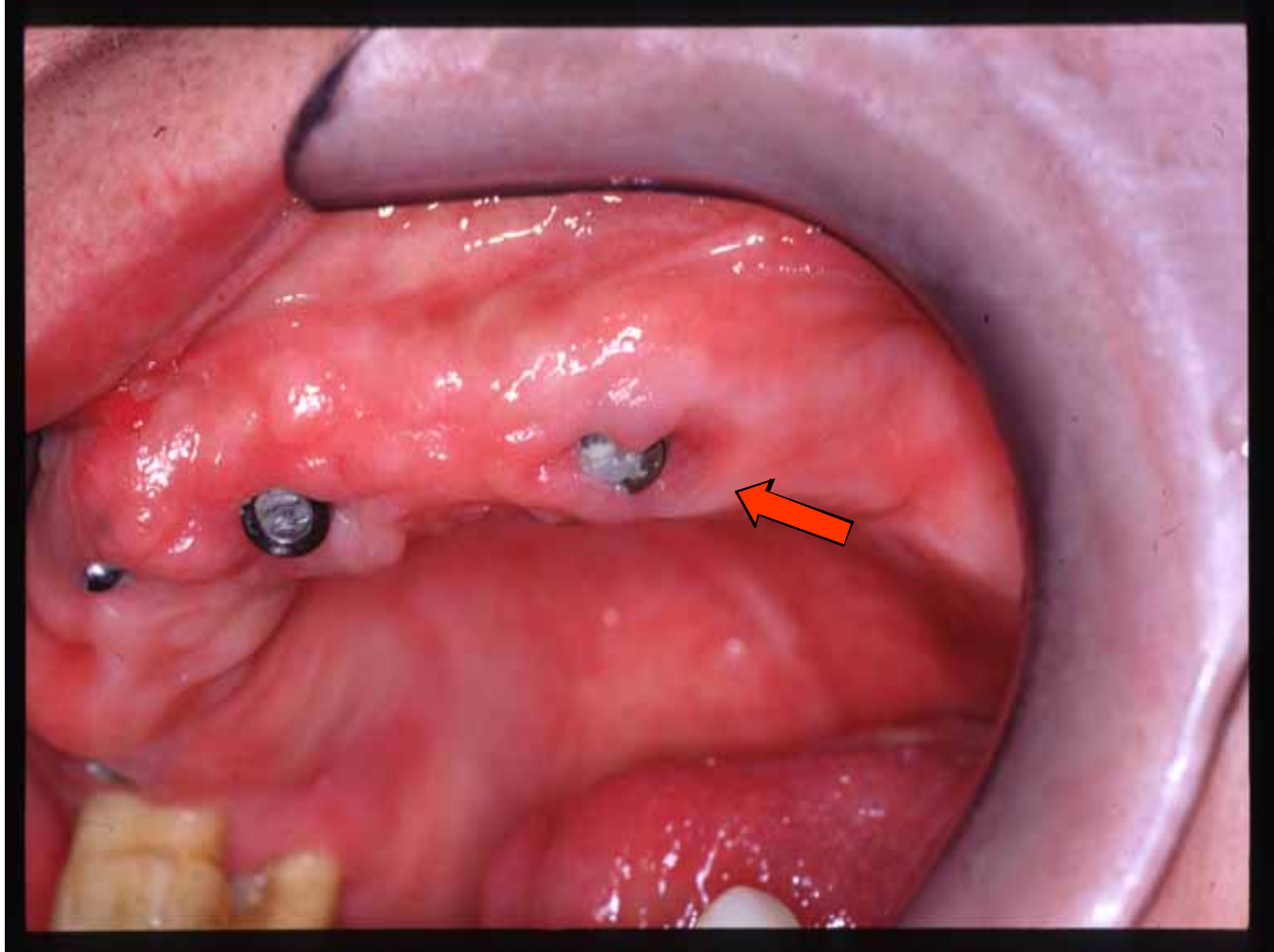


Closure
of an
Oro-antral Fistula

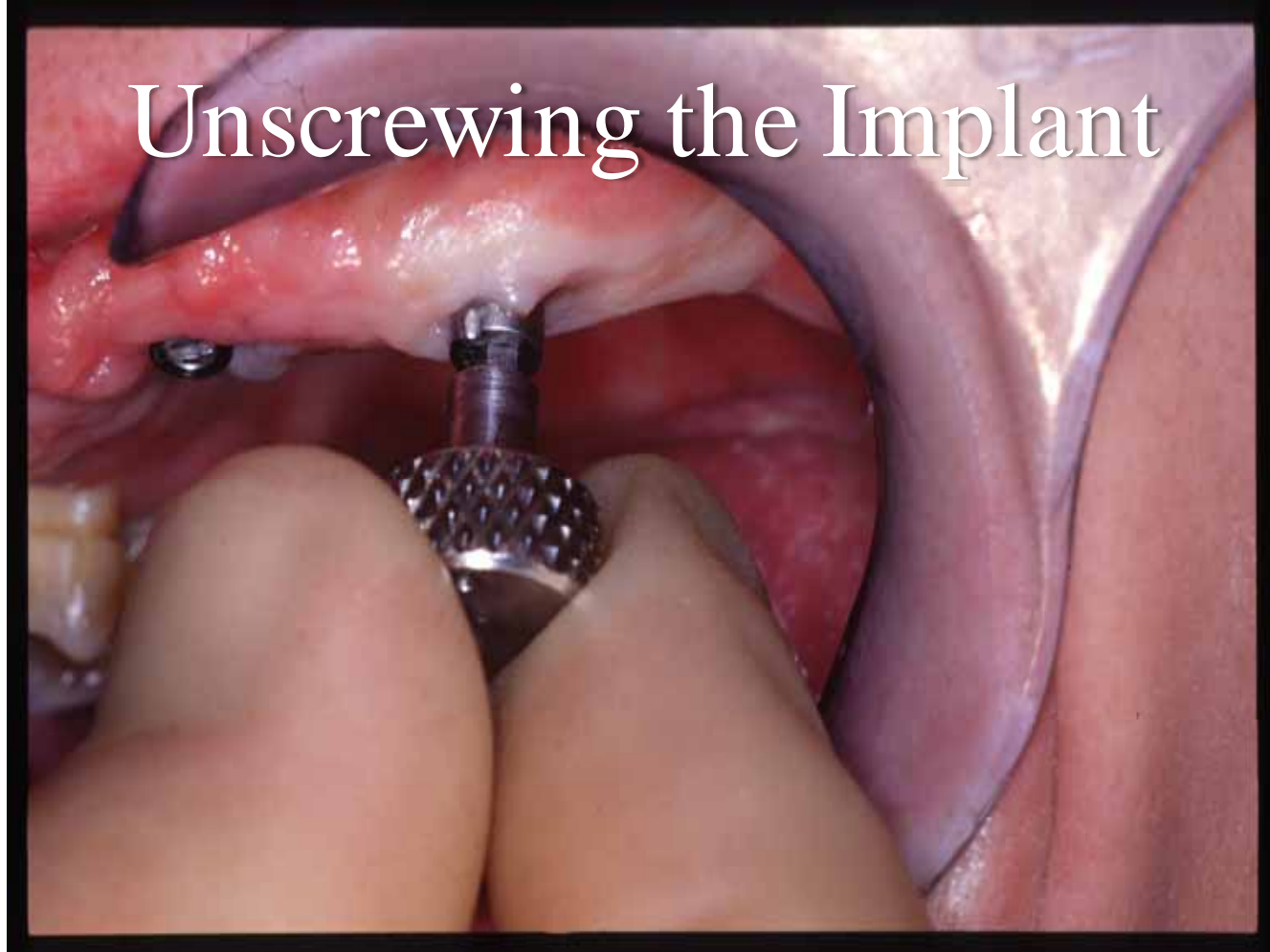
Implant Partially in the Sinus

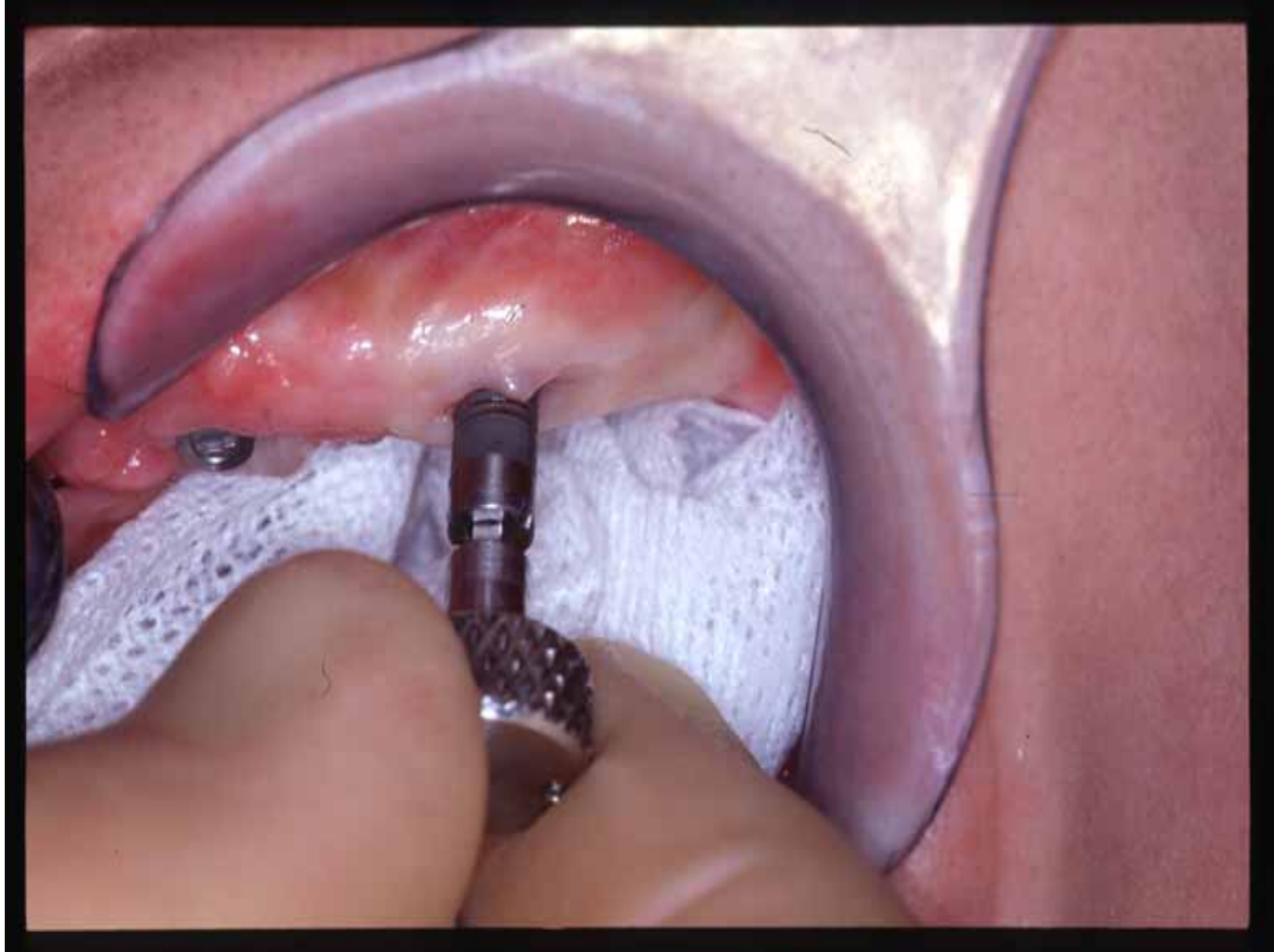

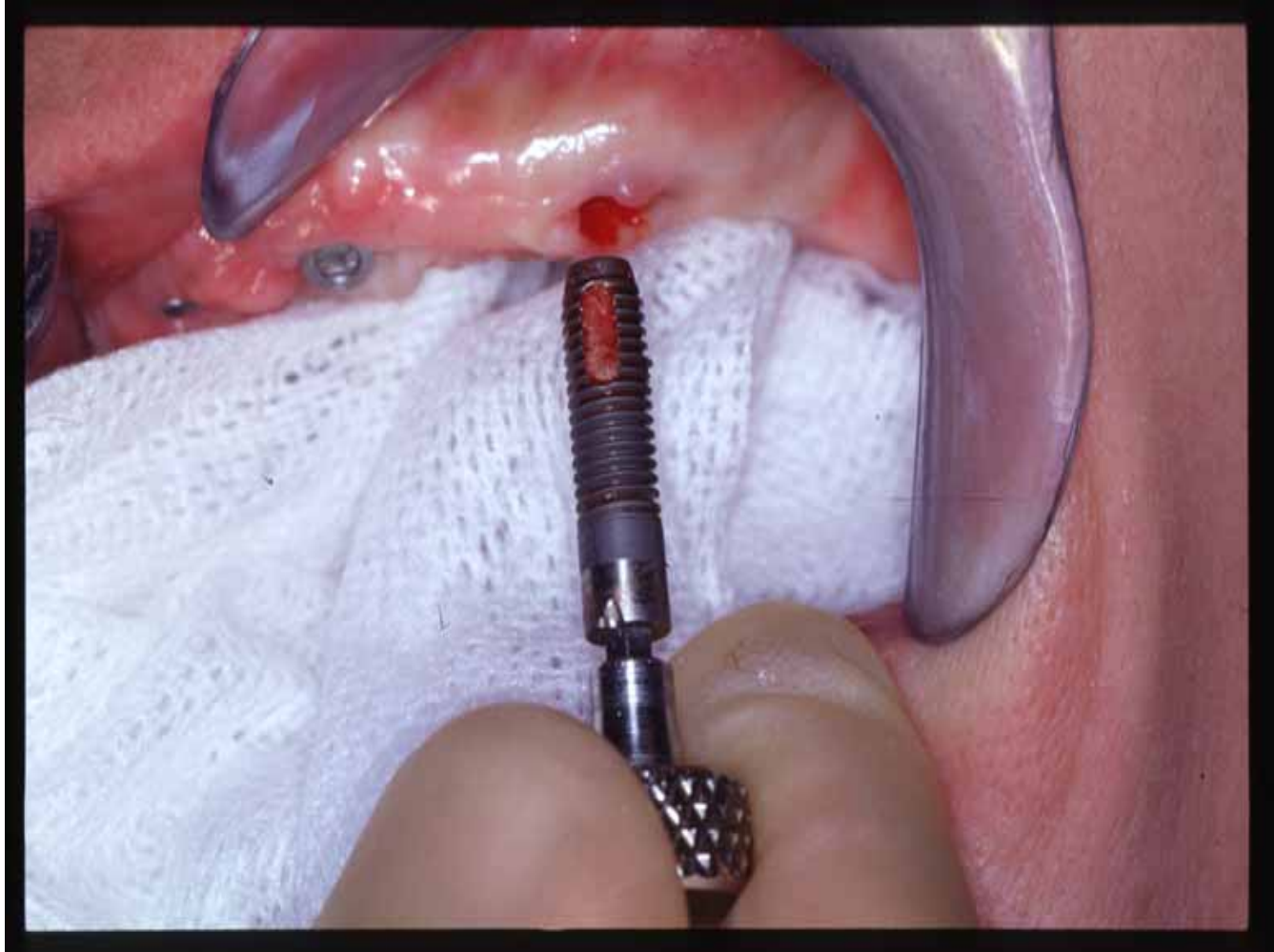




Unscrewing the Implant



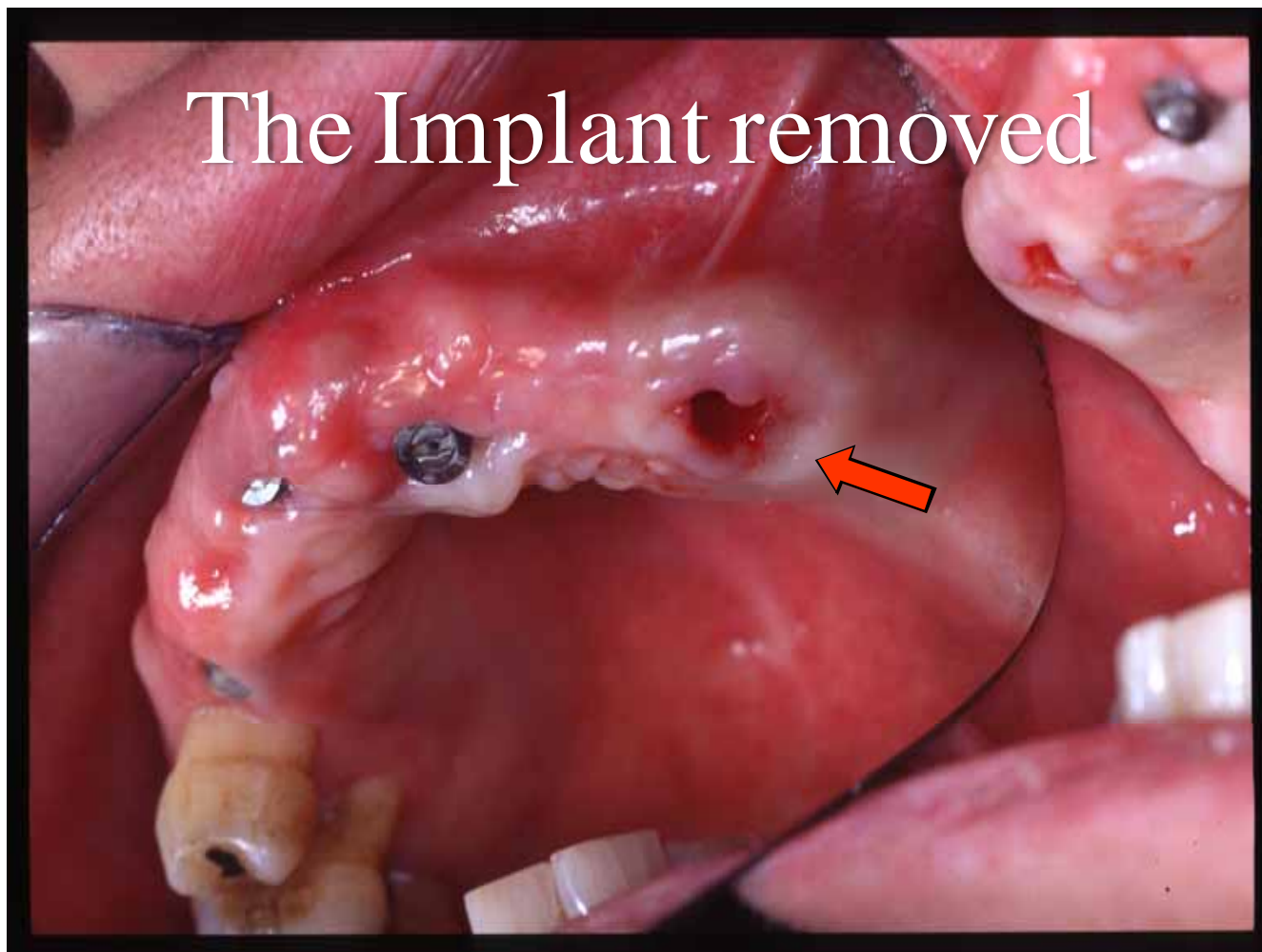




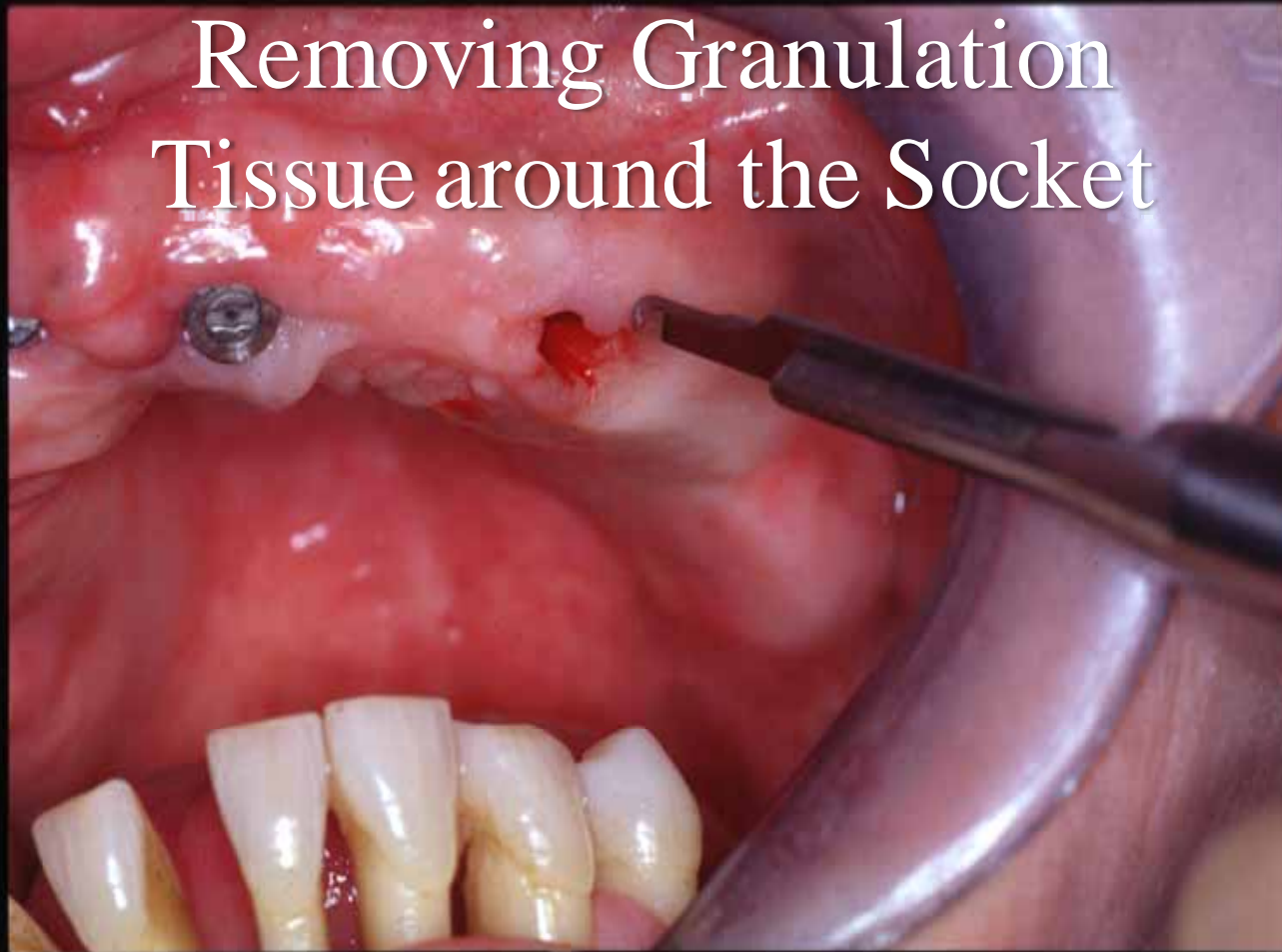The Implant removed

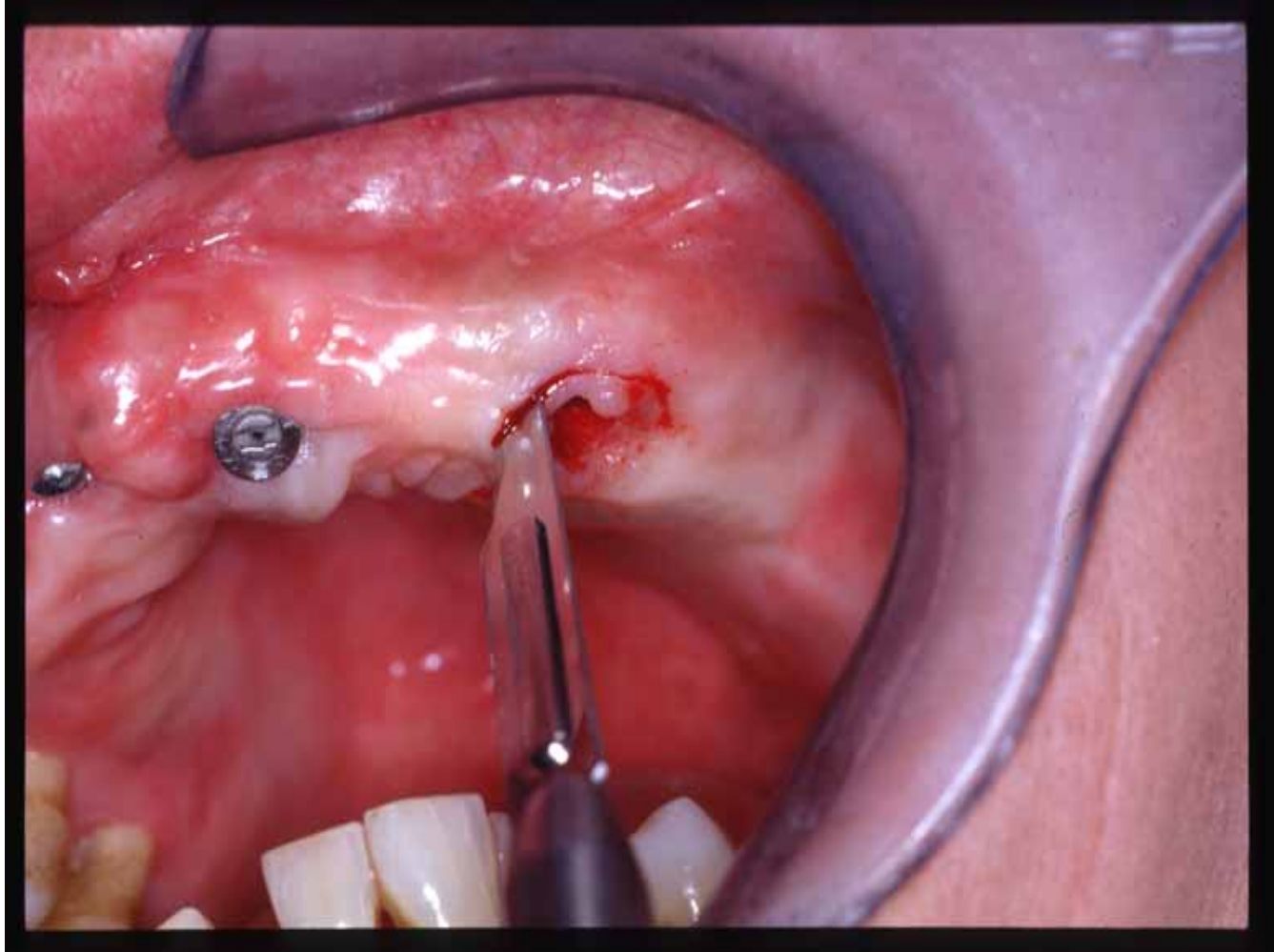


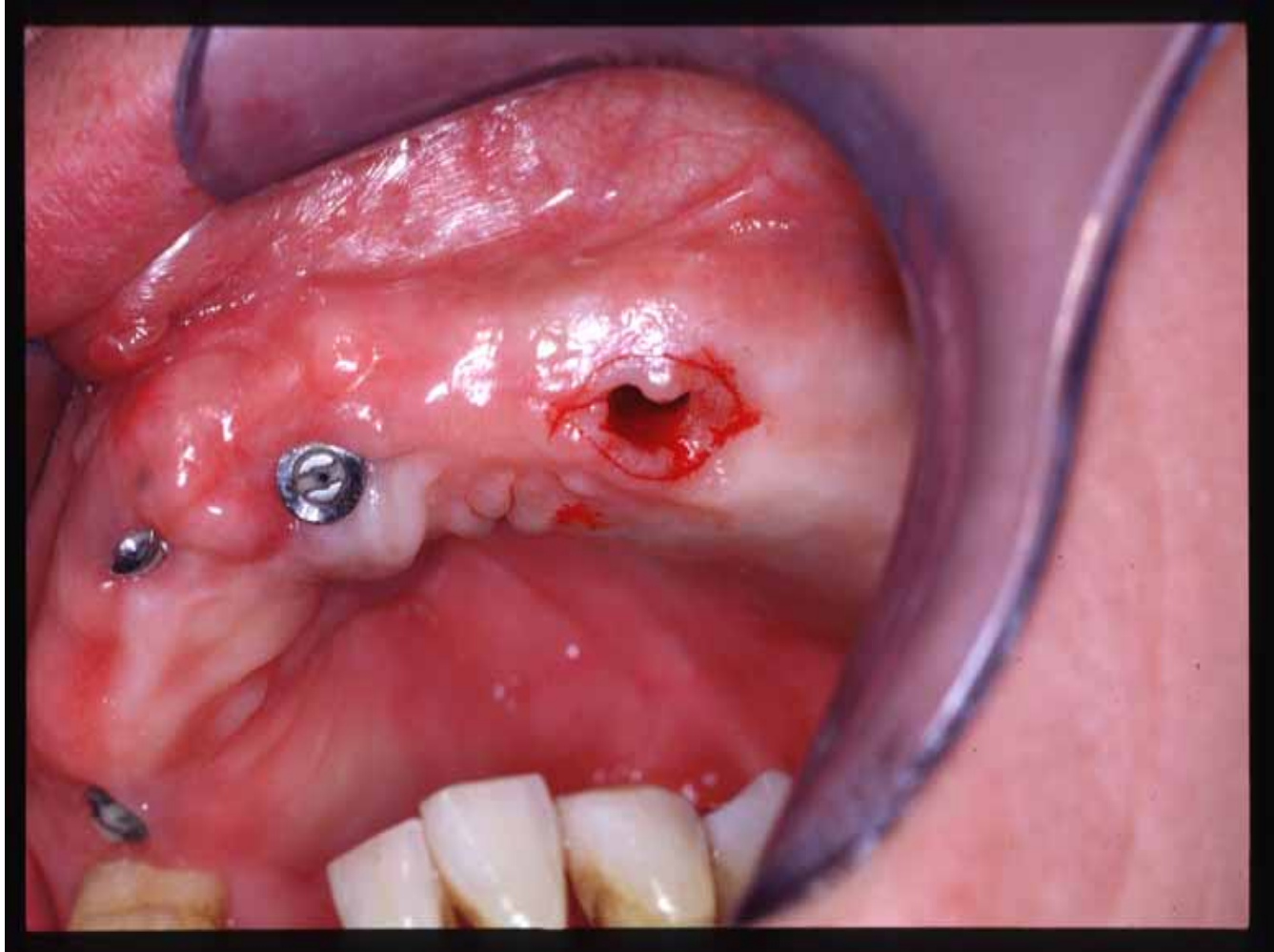
The Implant removed

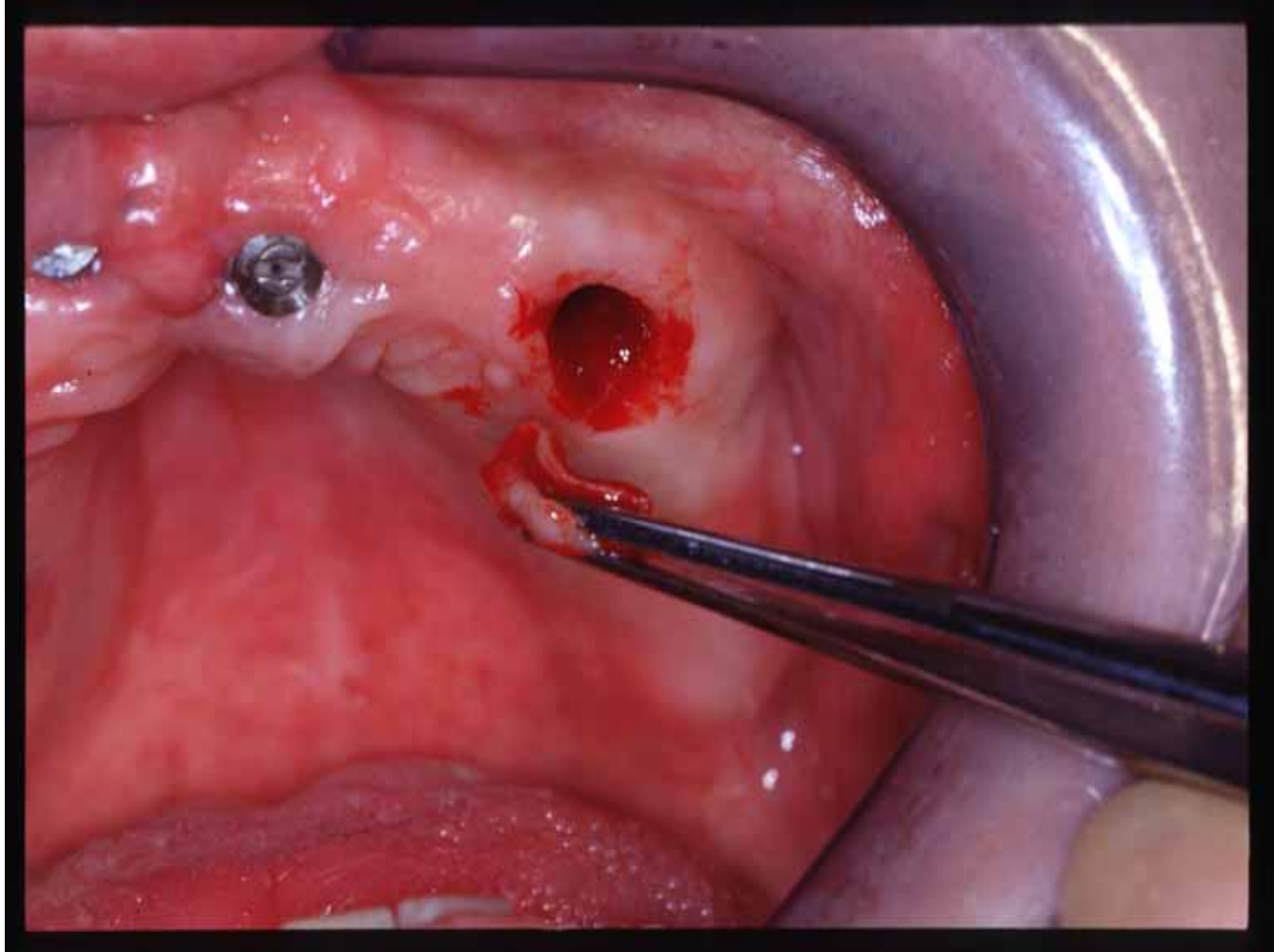


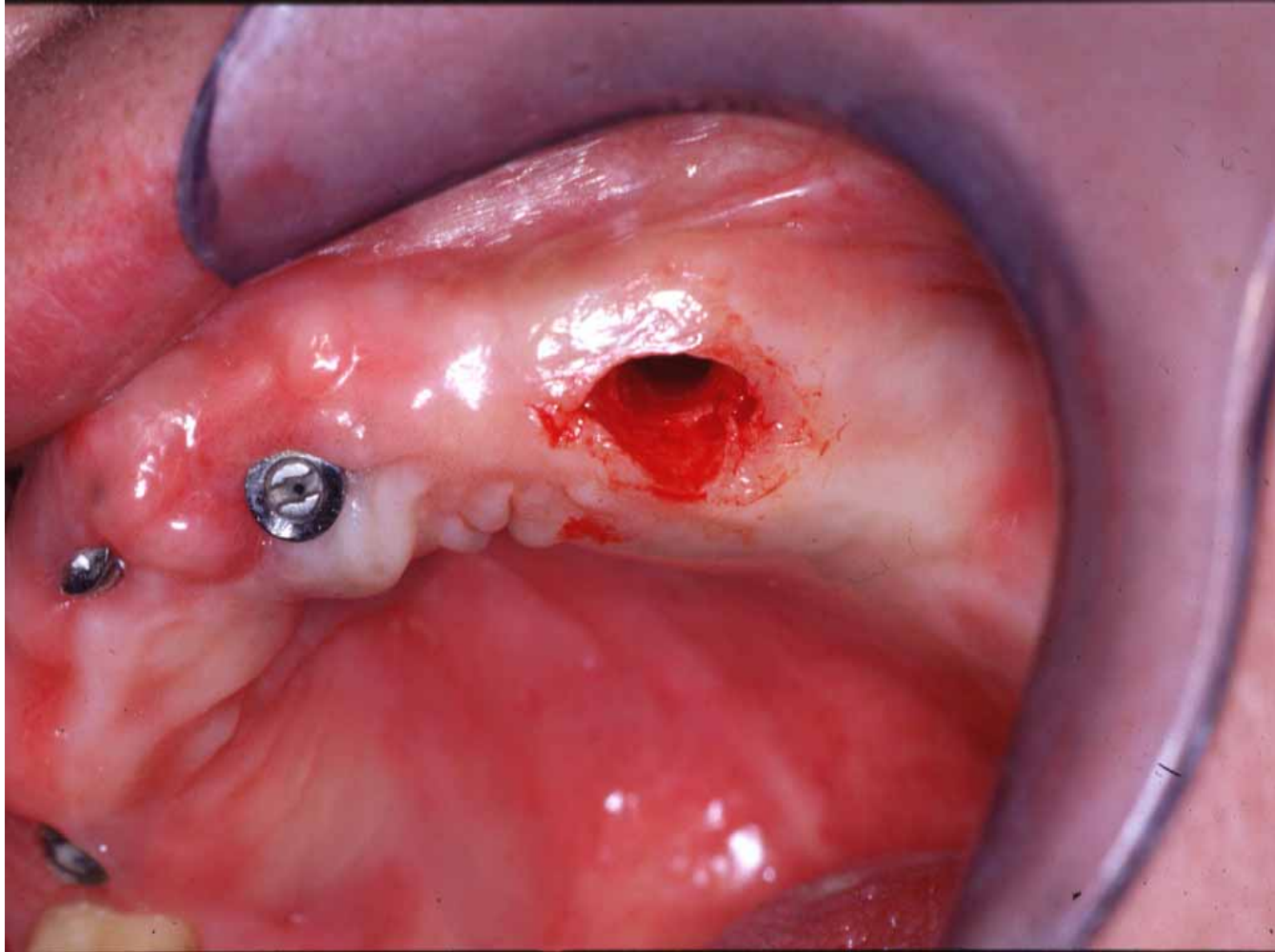
Removing Granulation Tissue around the Socket



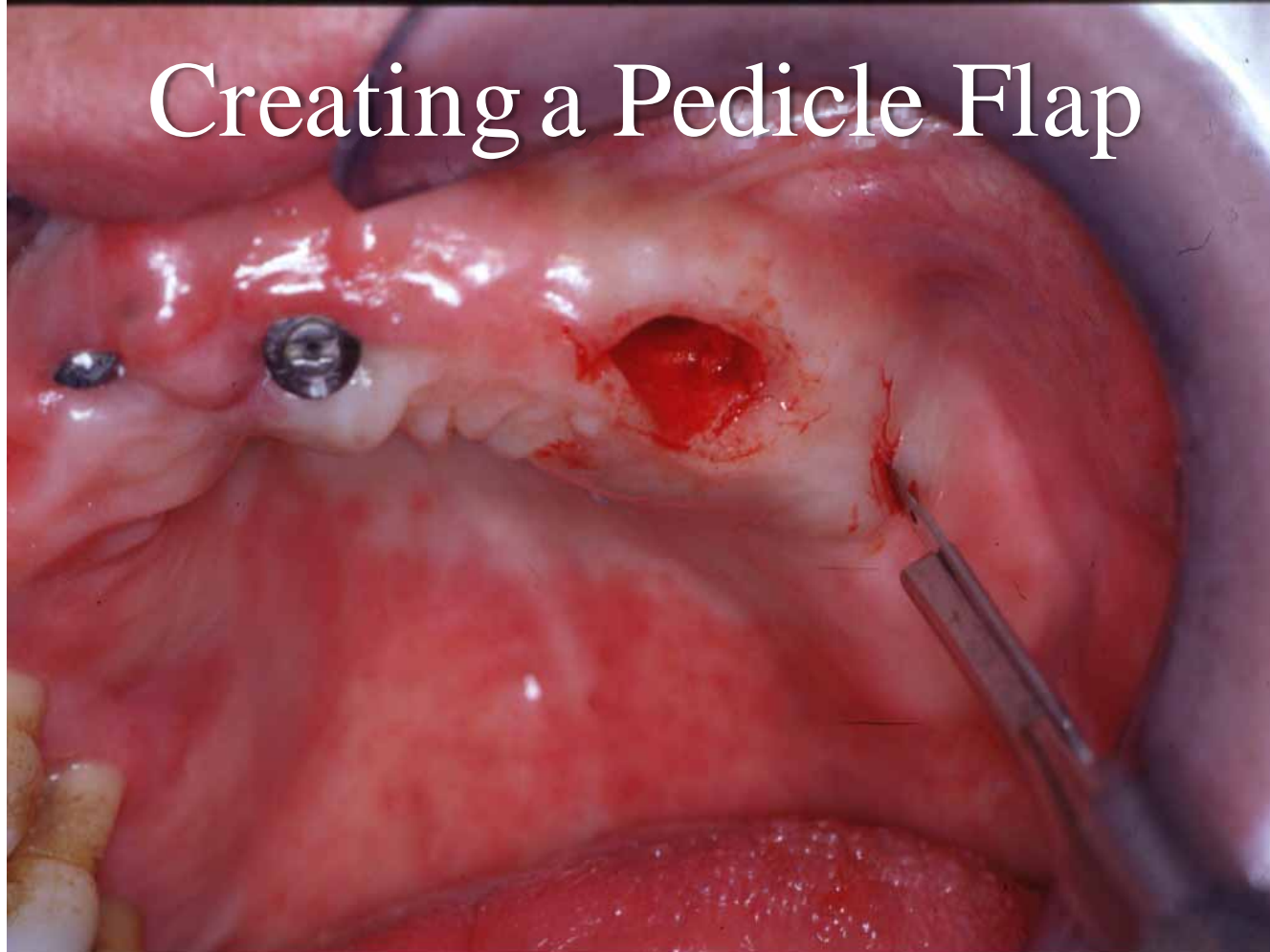




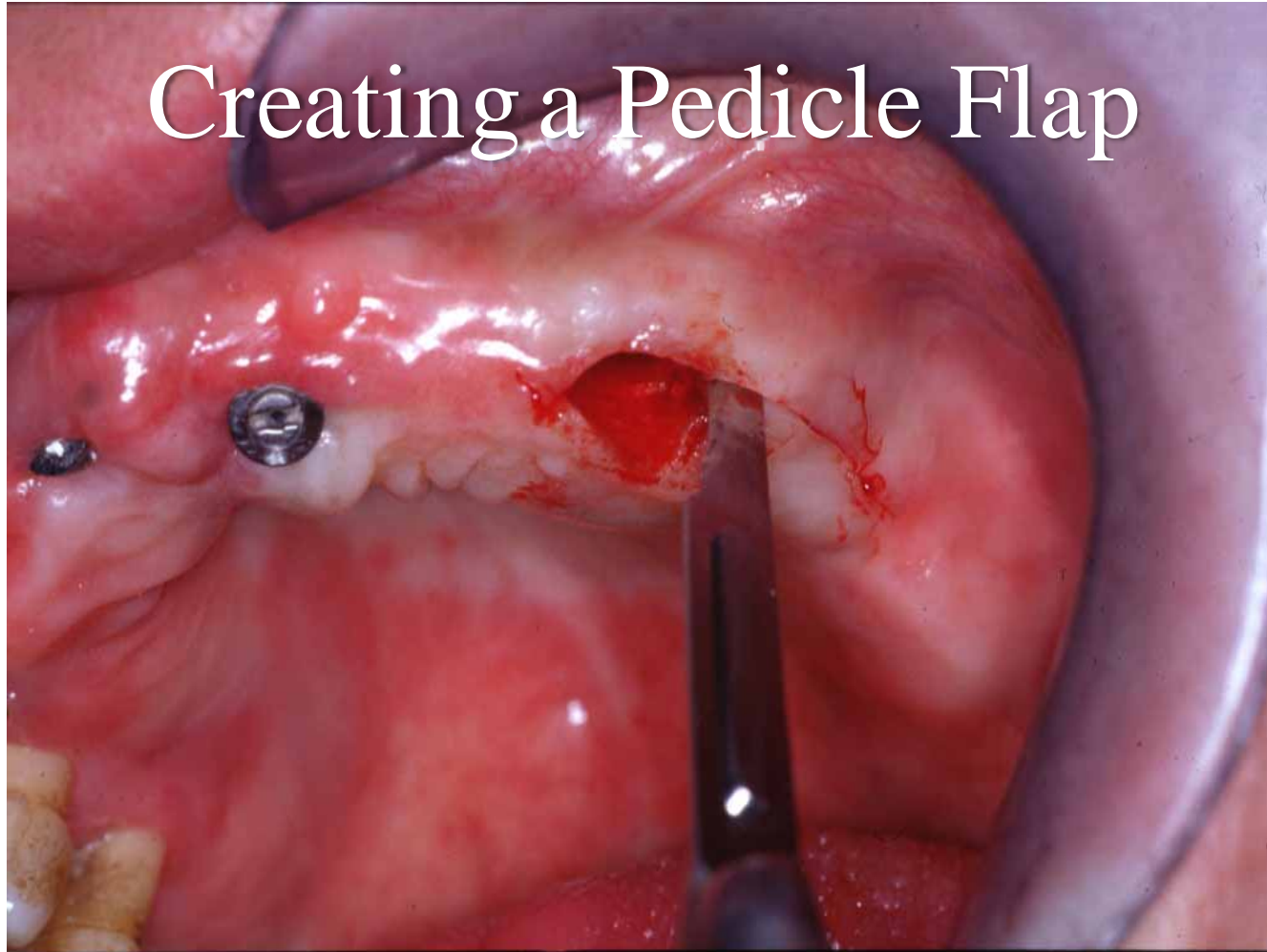




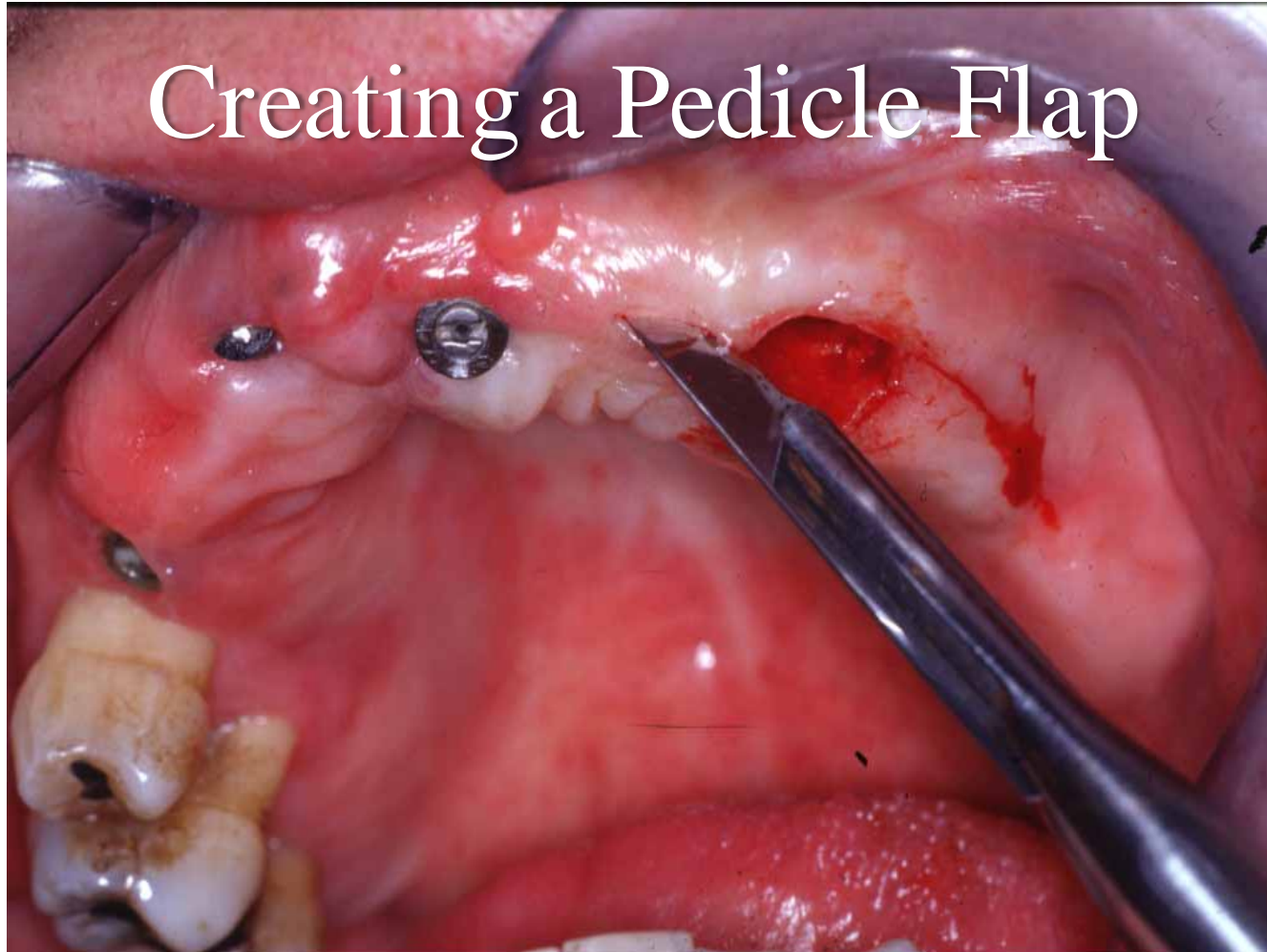
Creating a Pedicle Flap



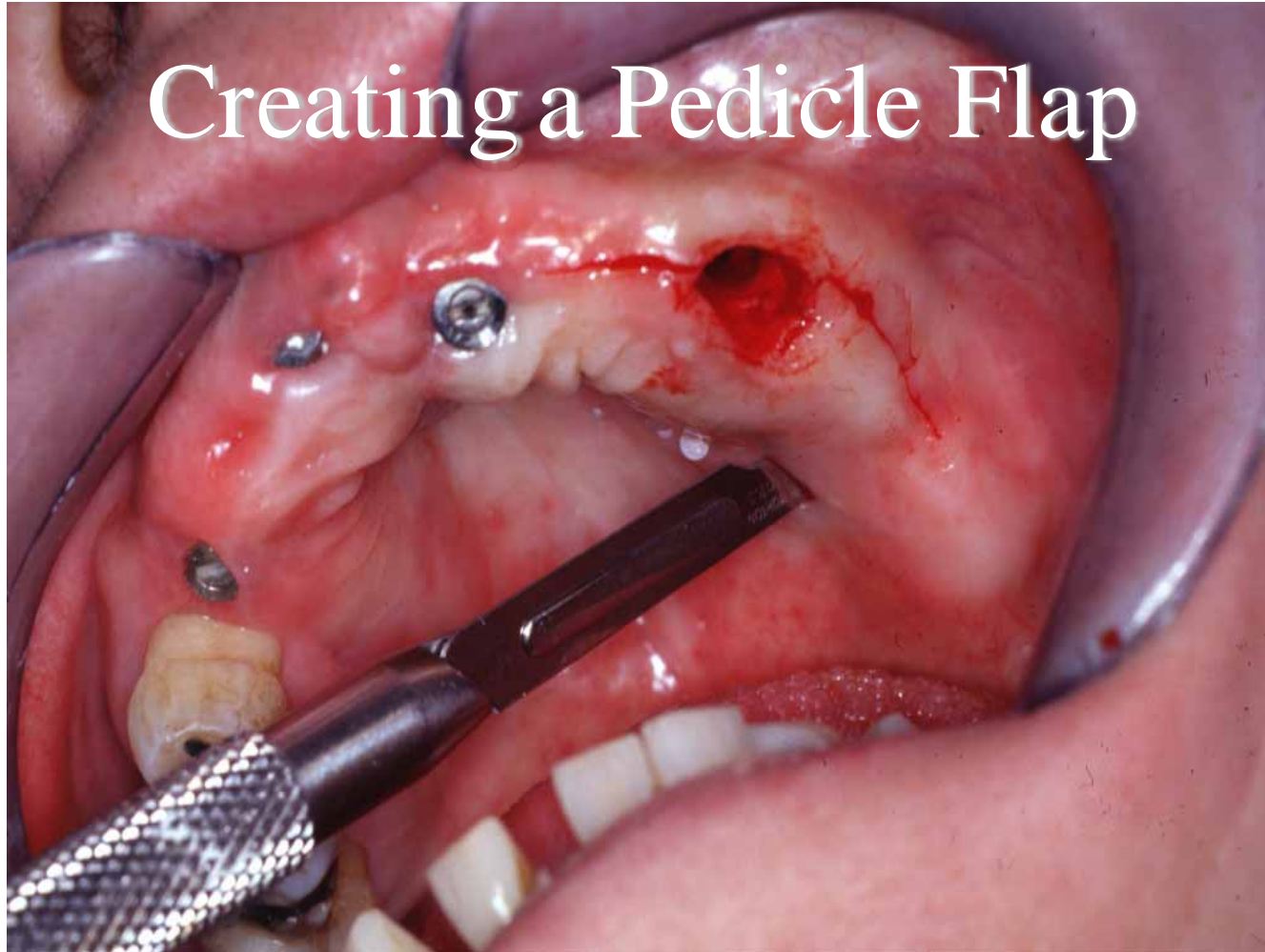
Creating a Pedicle Flap



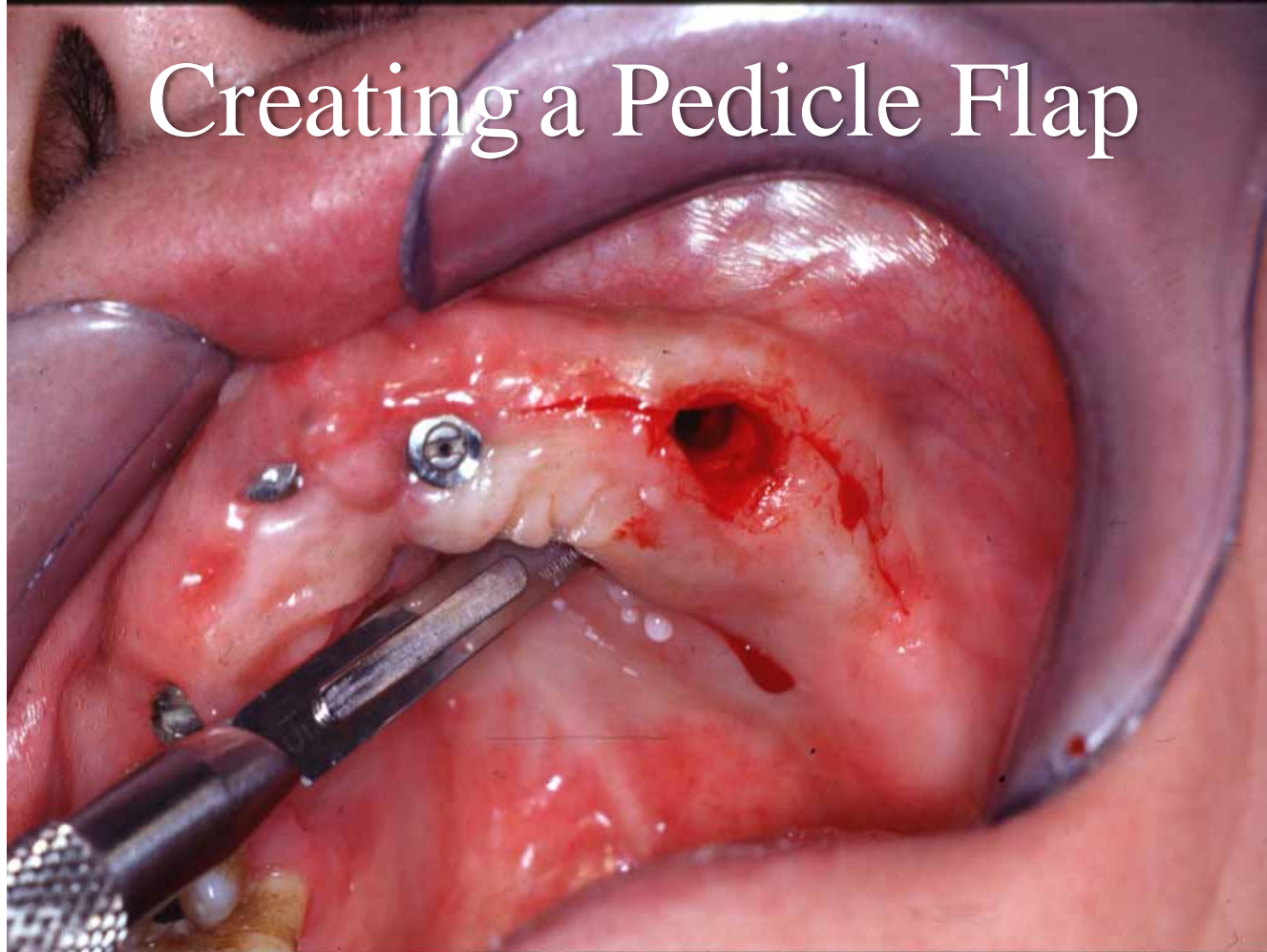
Creating a Pedicle Flap



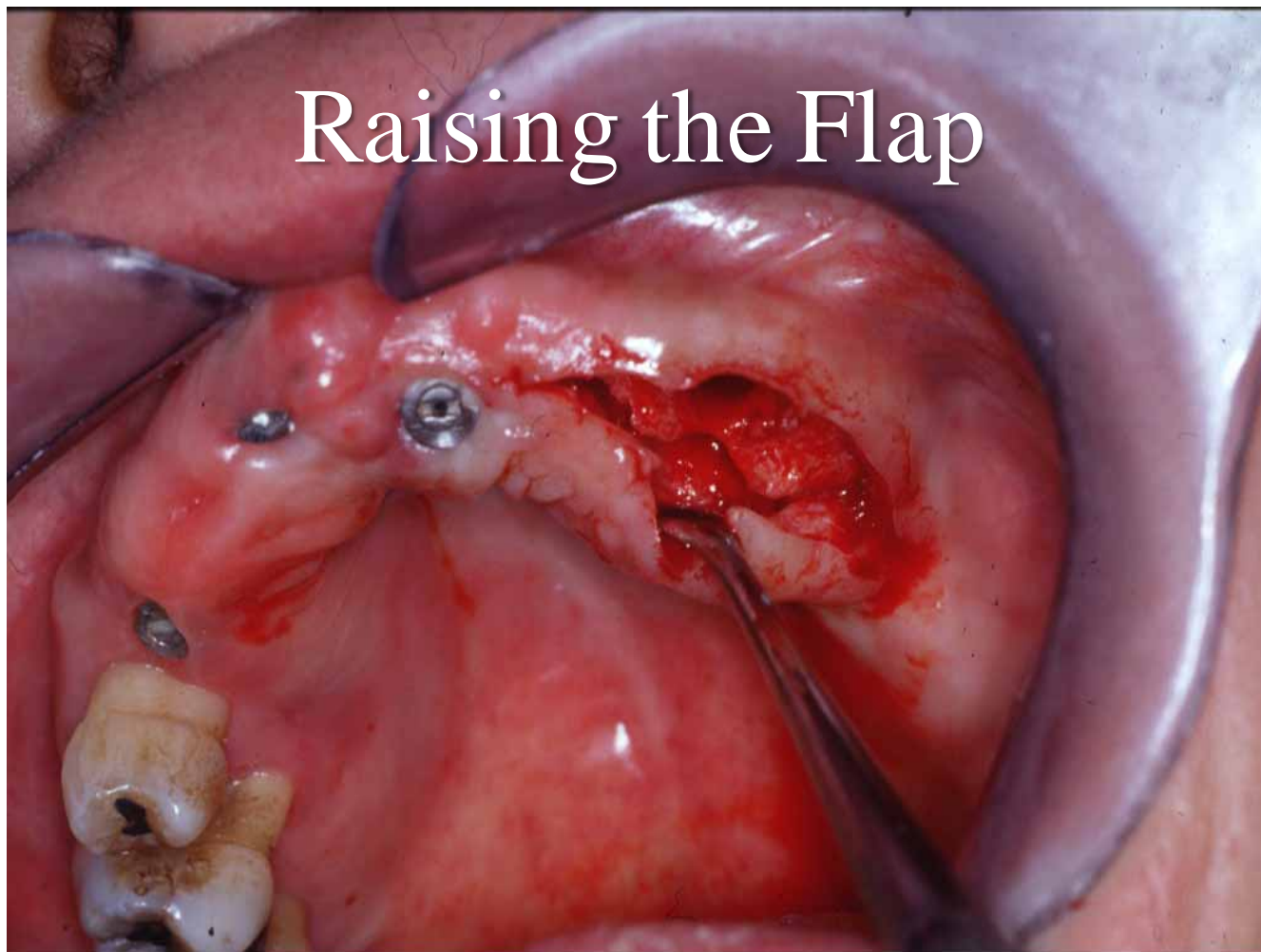
Creating a Pedicle Flap



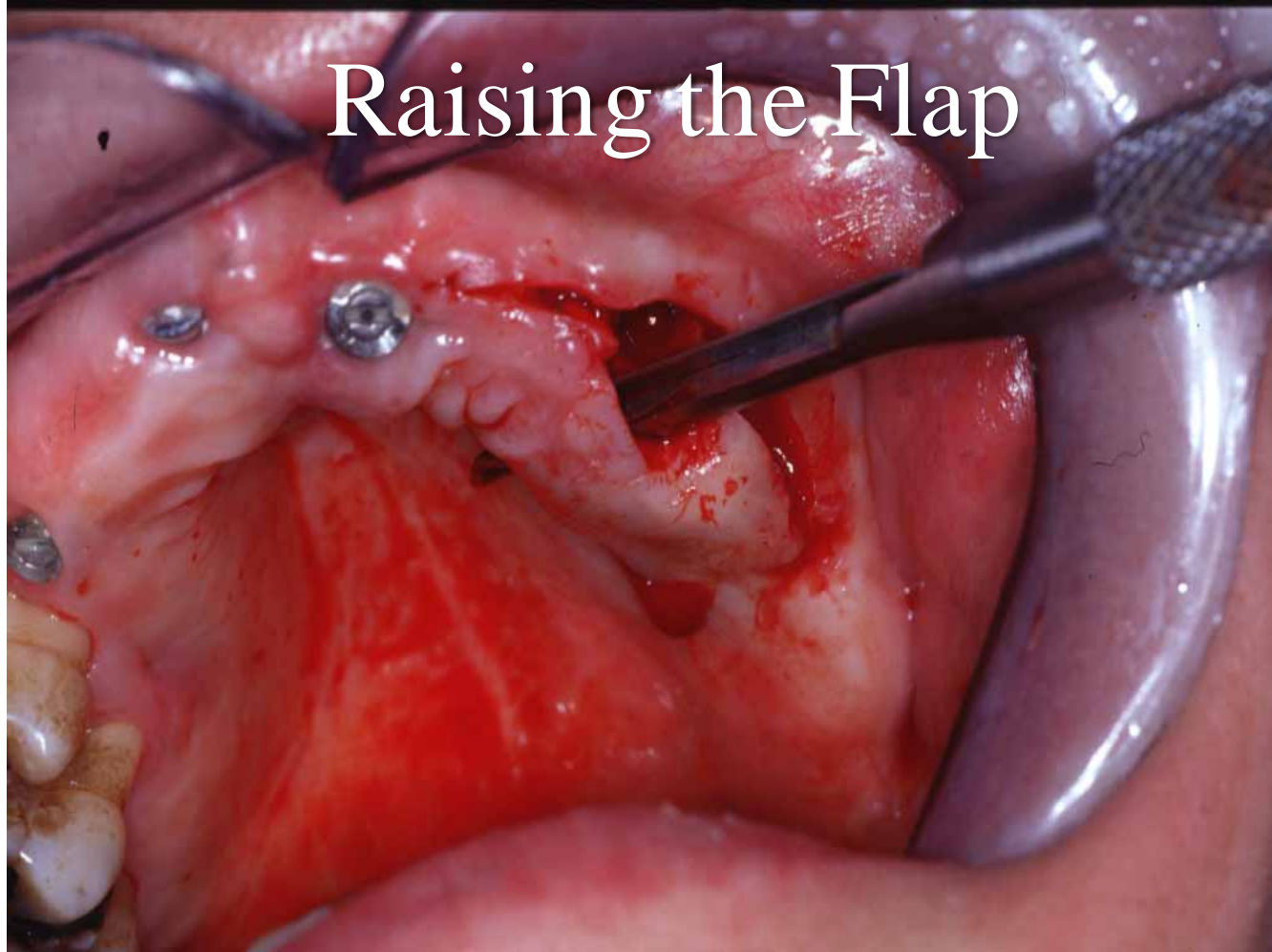
Creating a Pedicle Flap



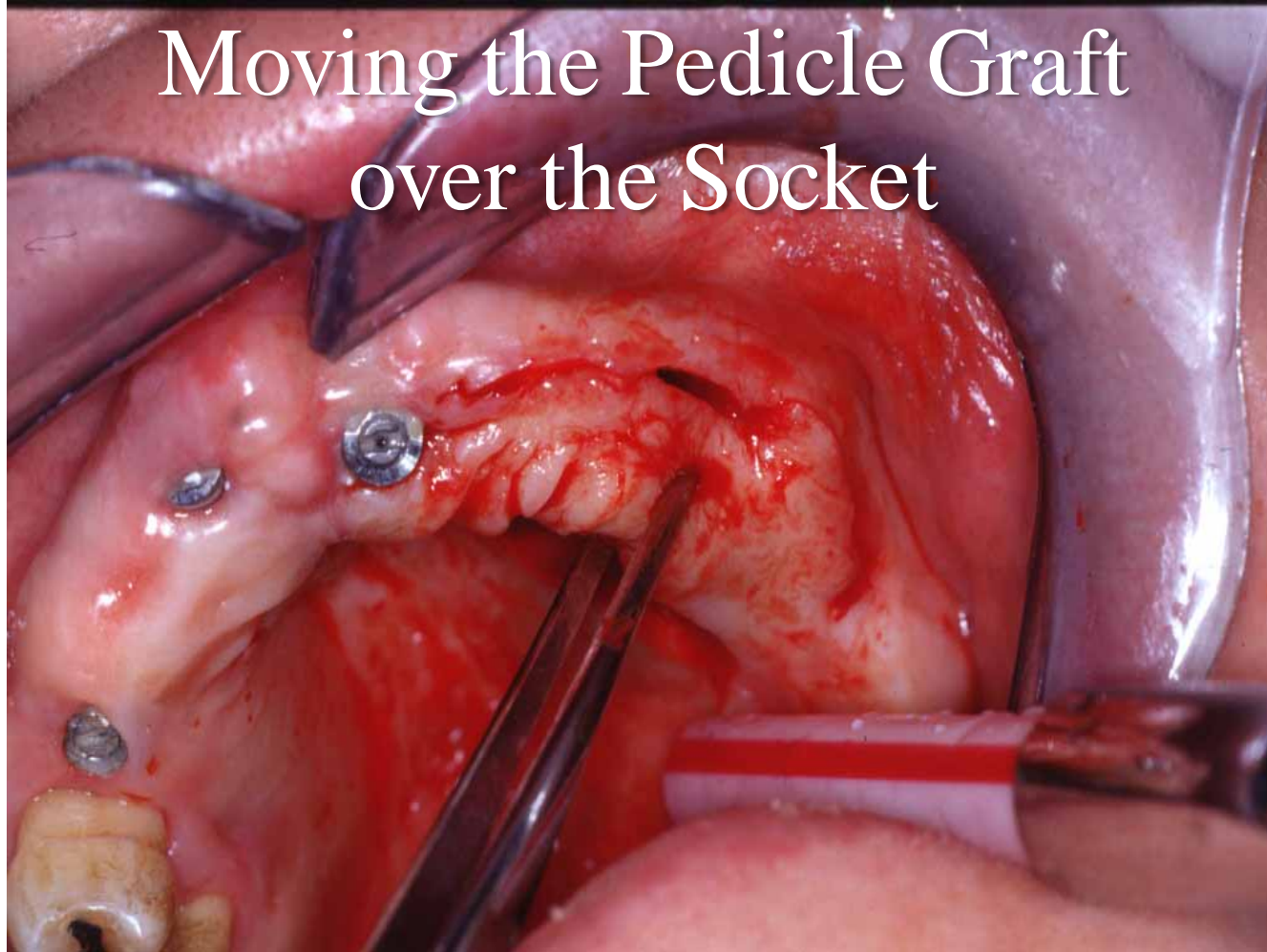
Raising the Flap



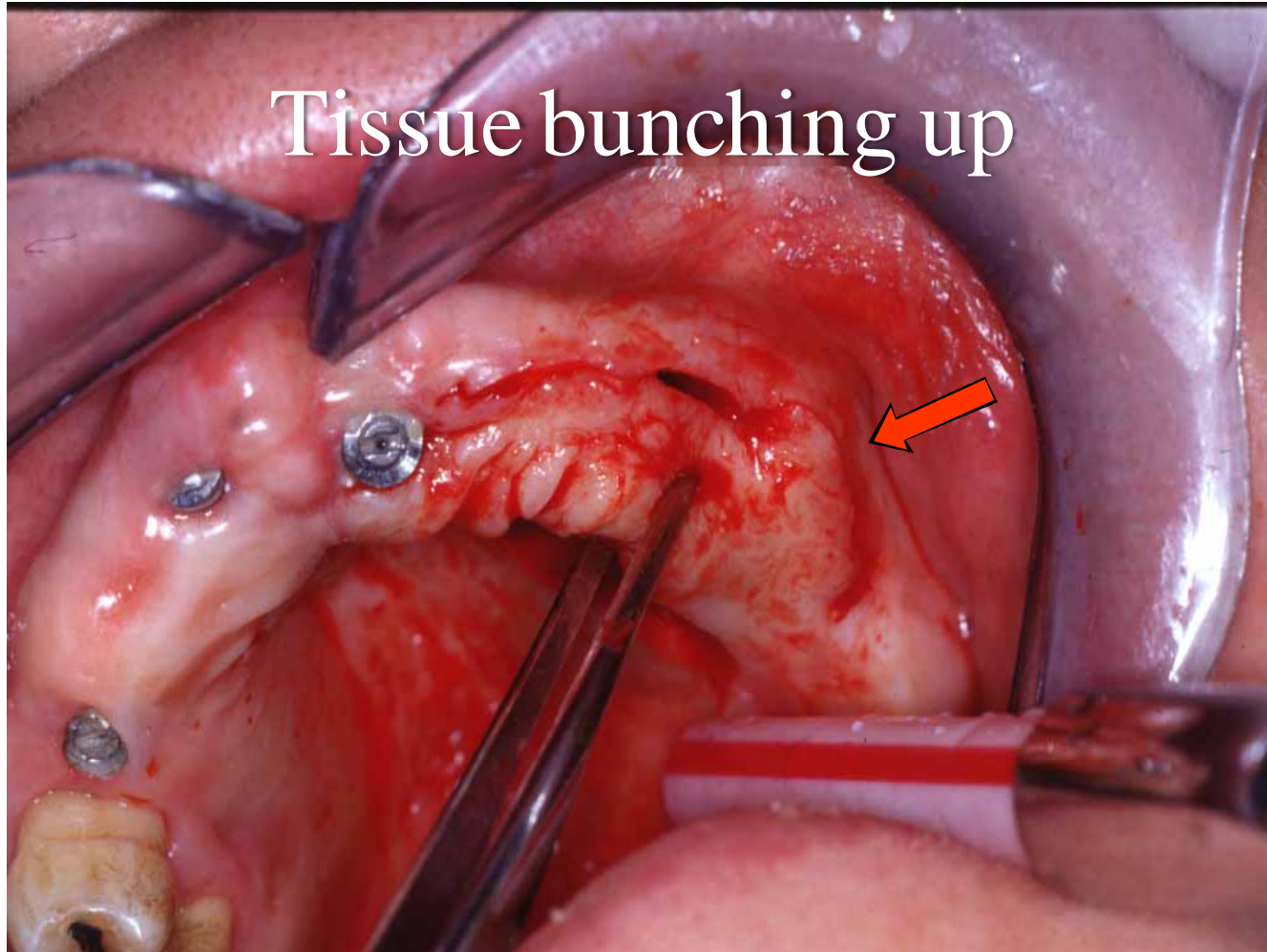
Raising the Flap



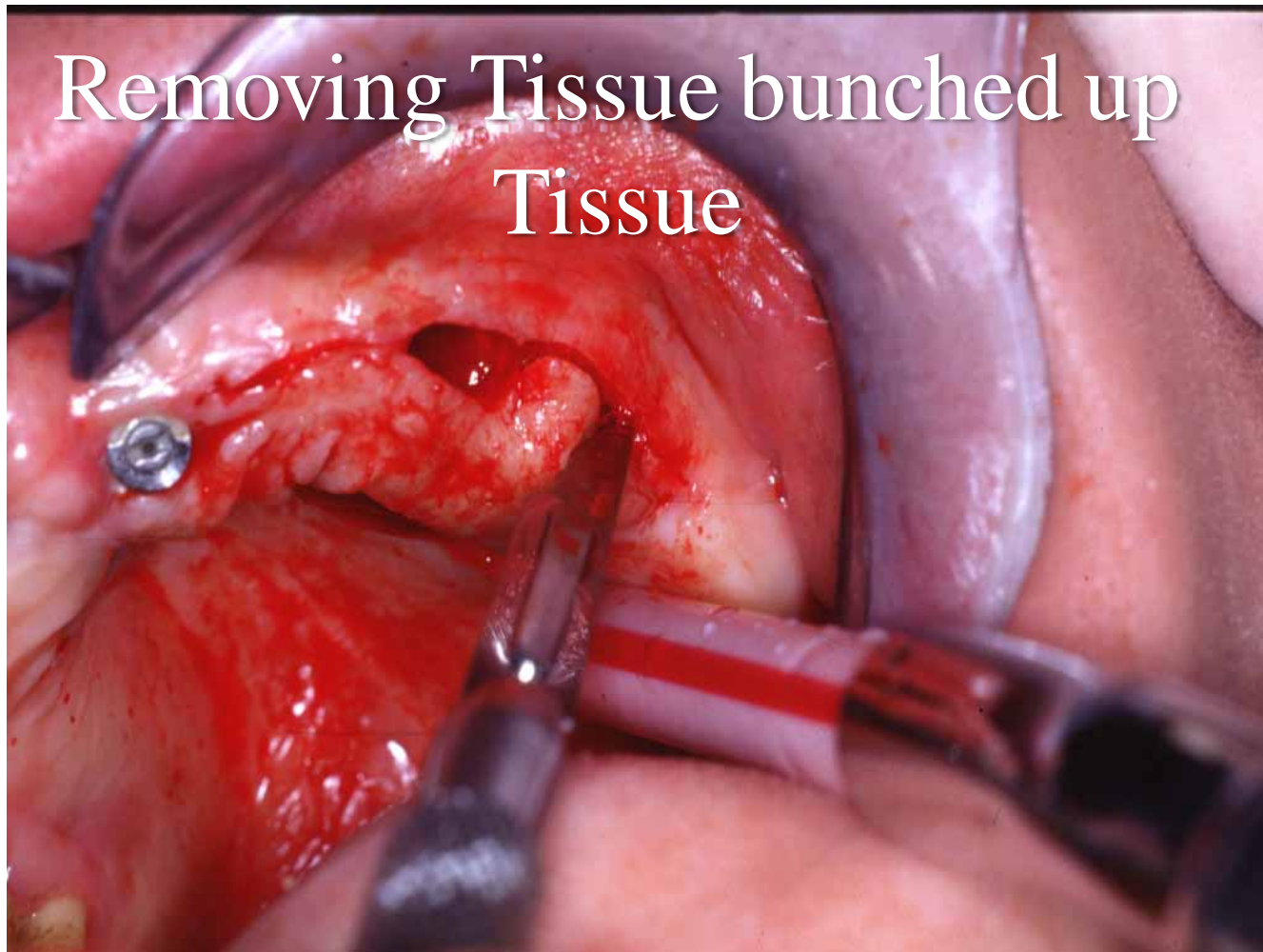
Moving the Pedicle Graft over the Socket



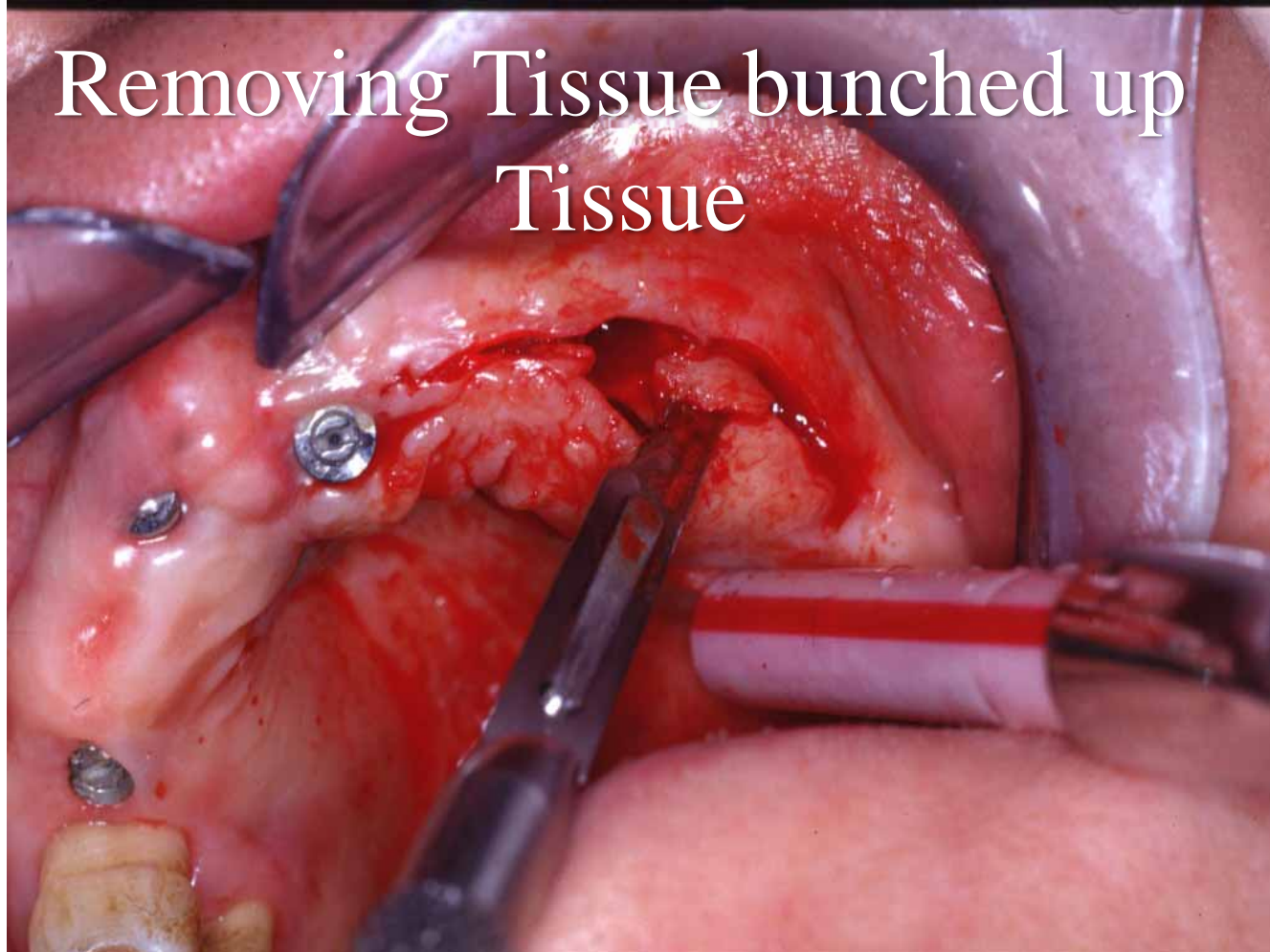
Tissue bunching up

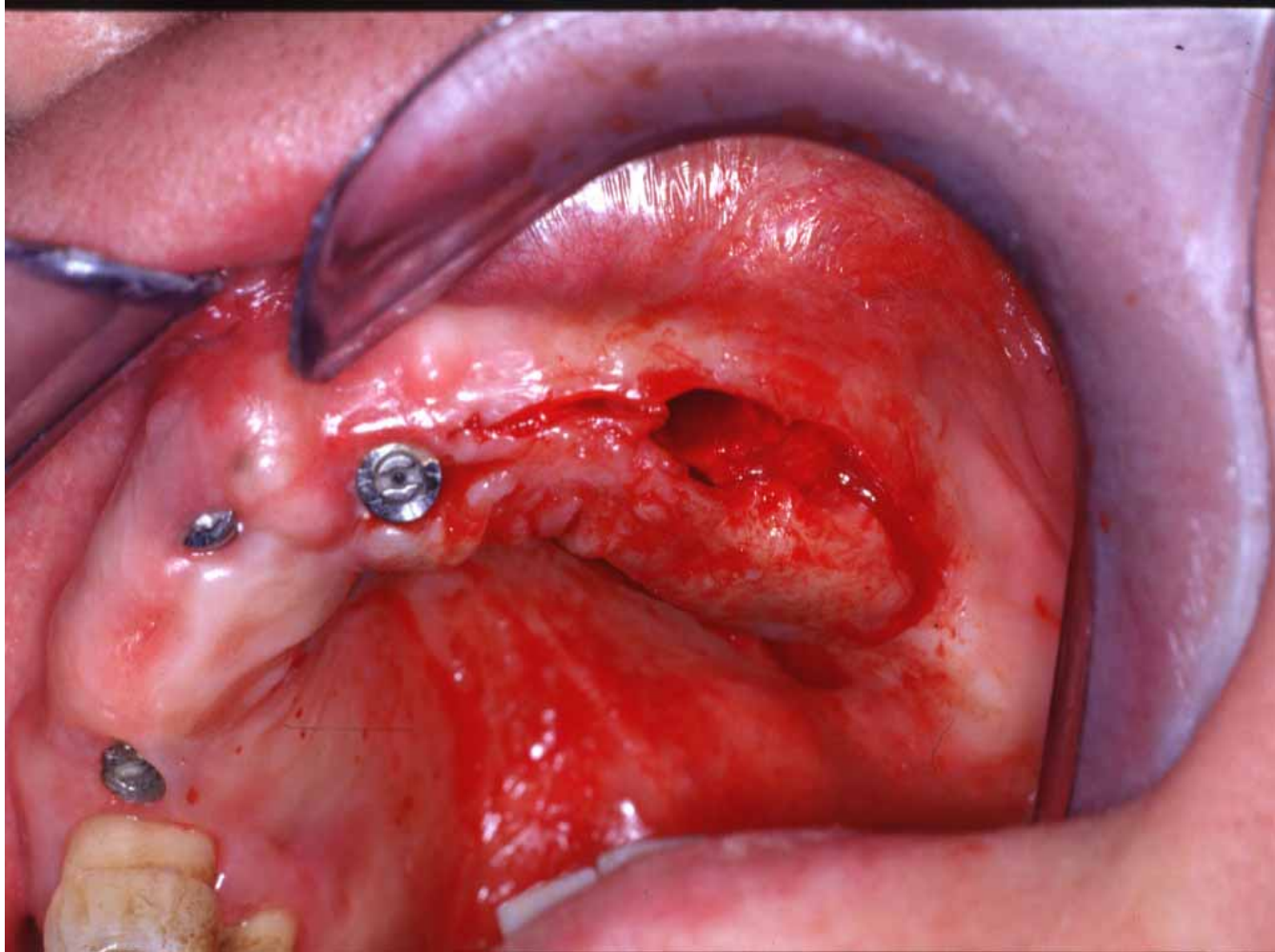


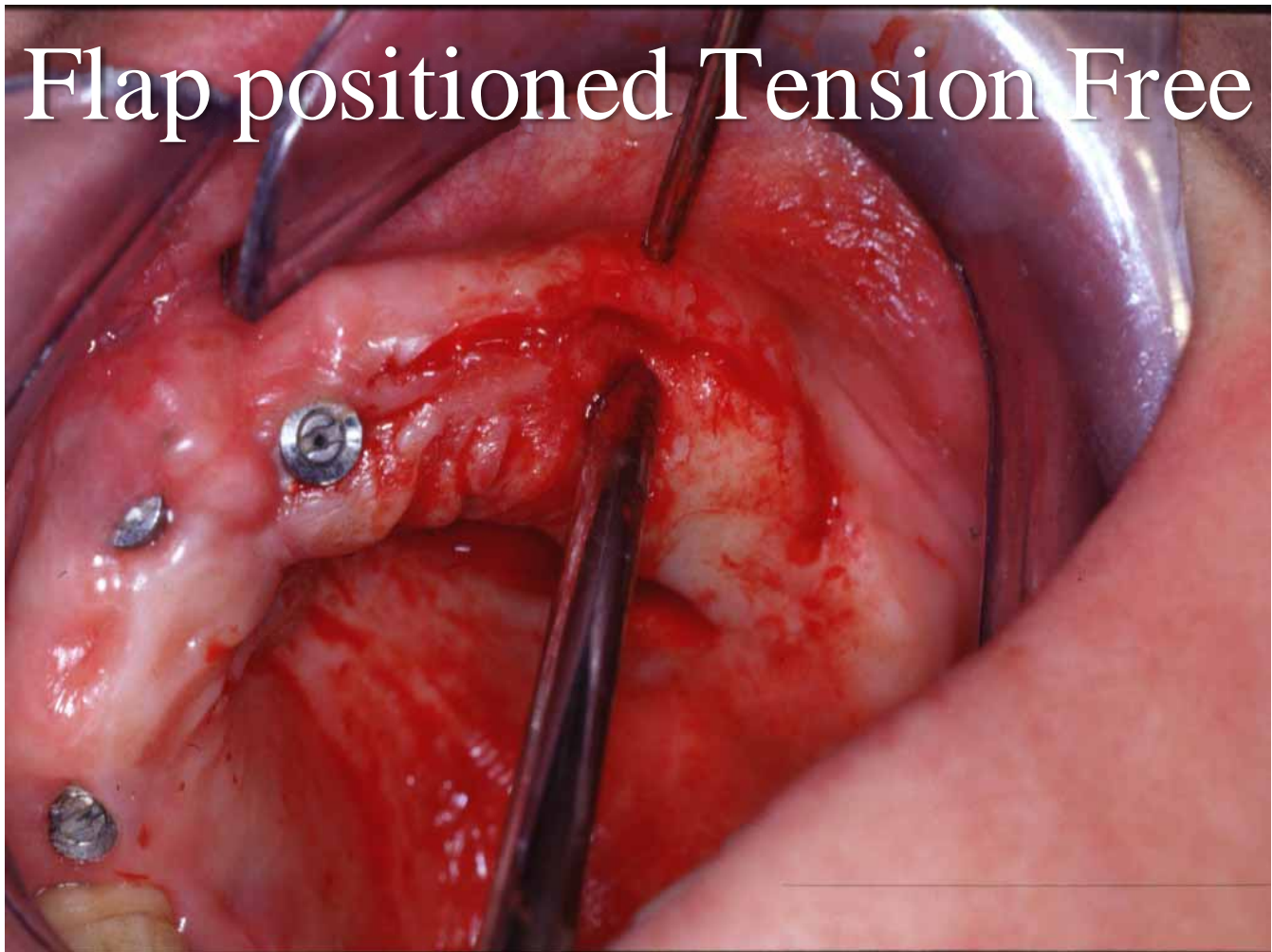
Removing Tissue bunched up
Tissue



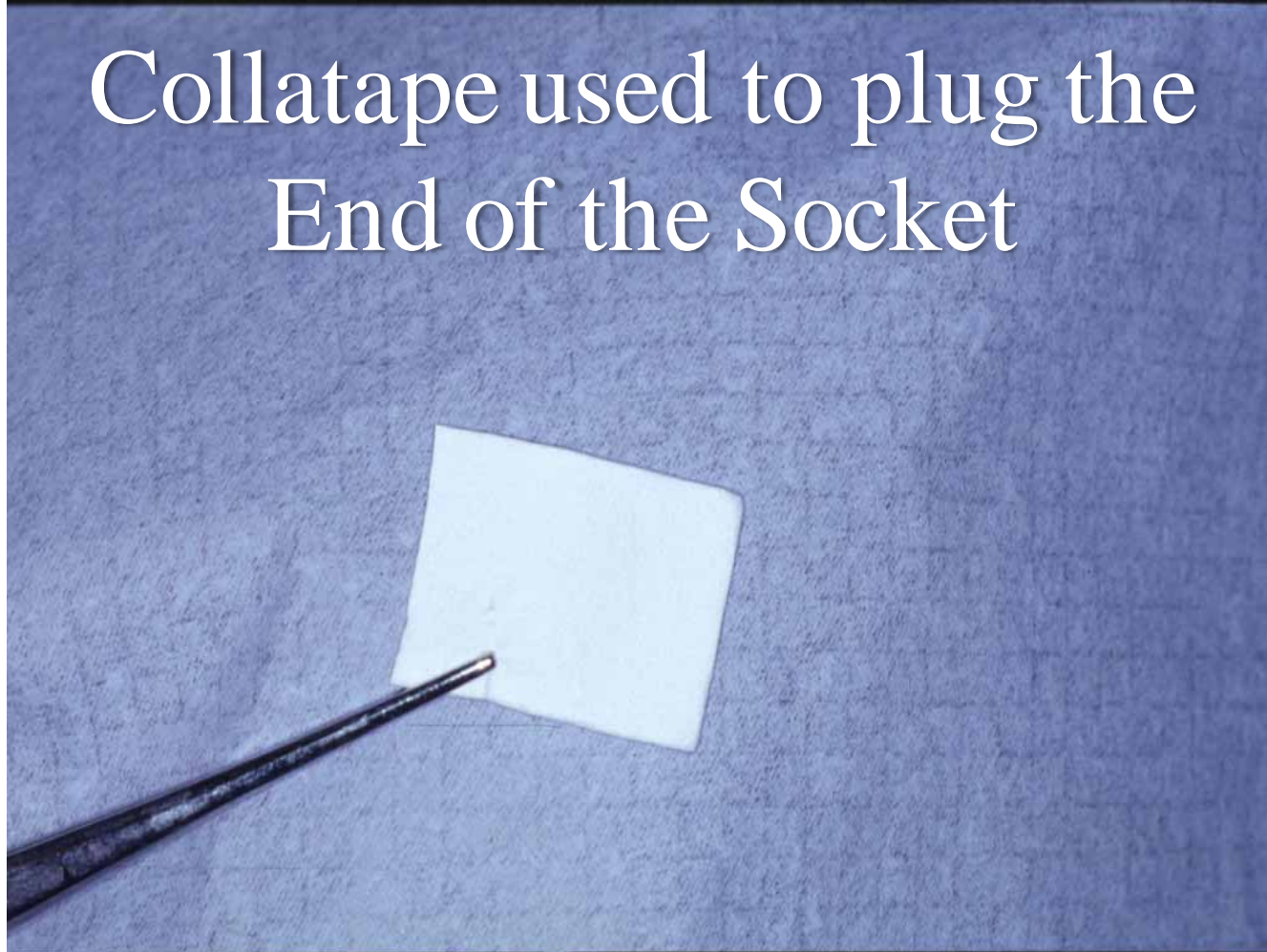
Removing Tissue bunched up
Tissue



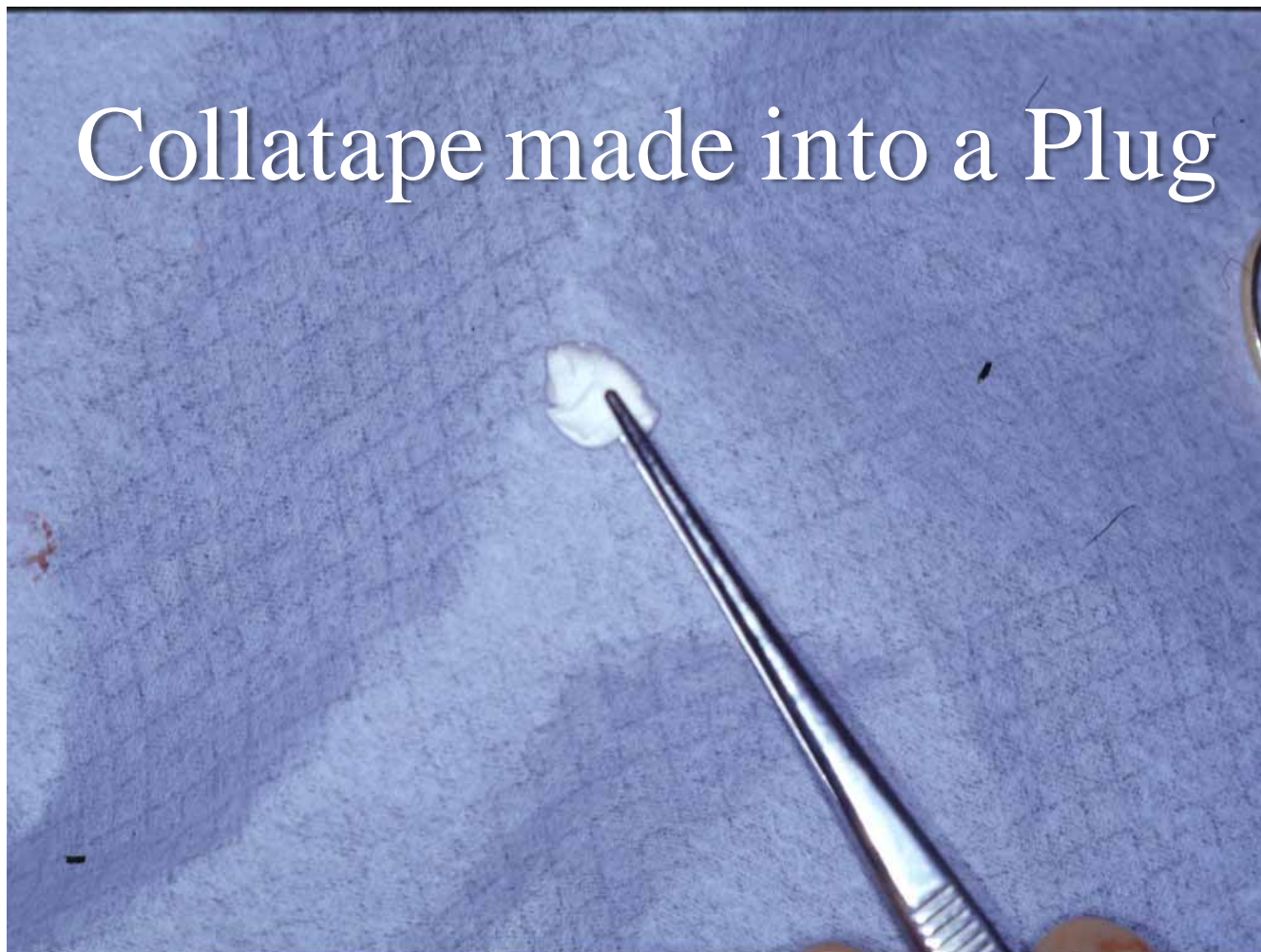




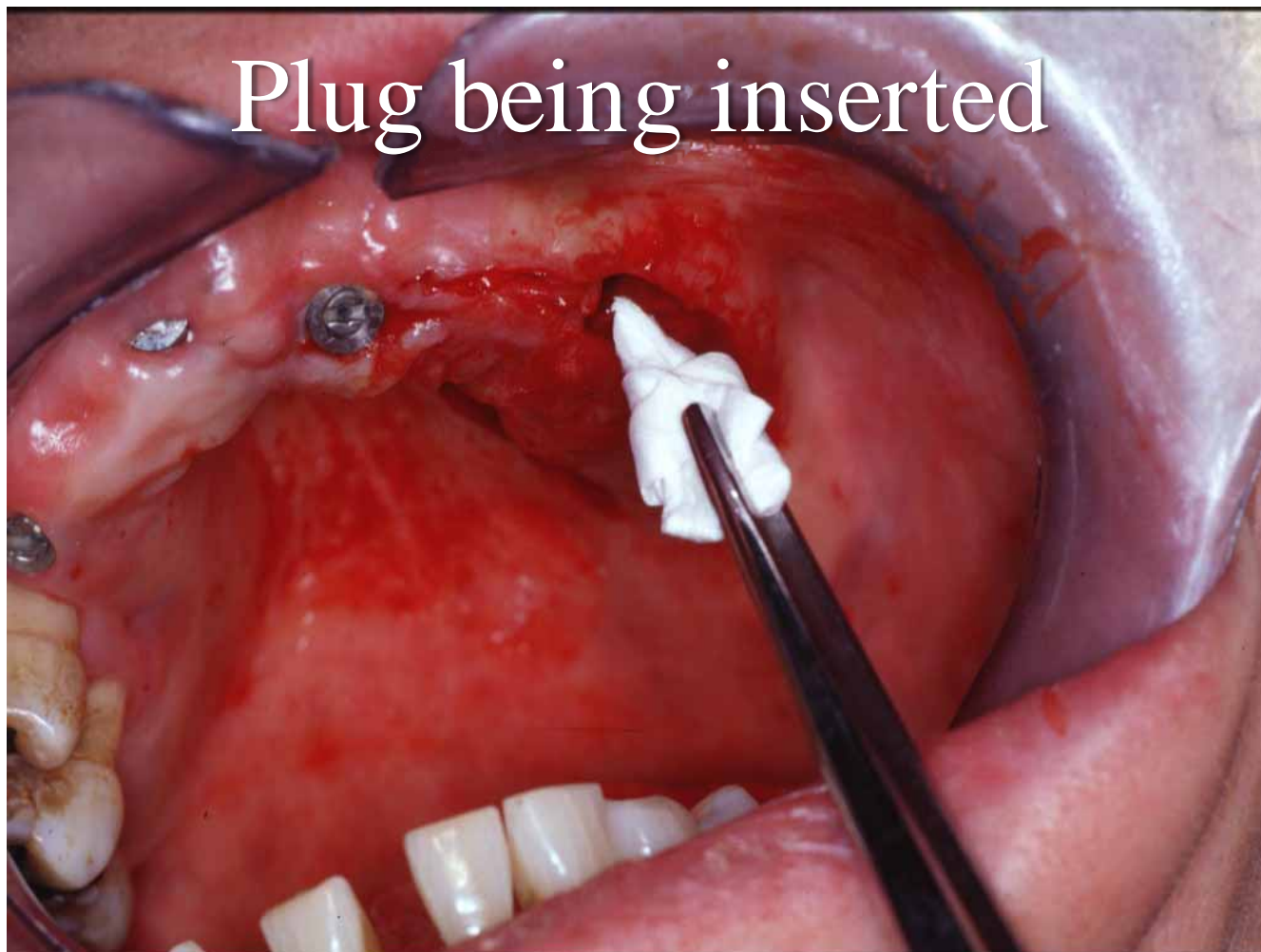
Collatape used to plug the End of the Socket



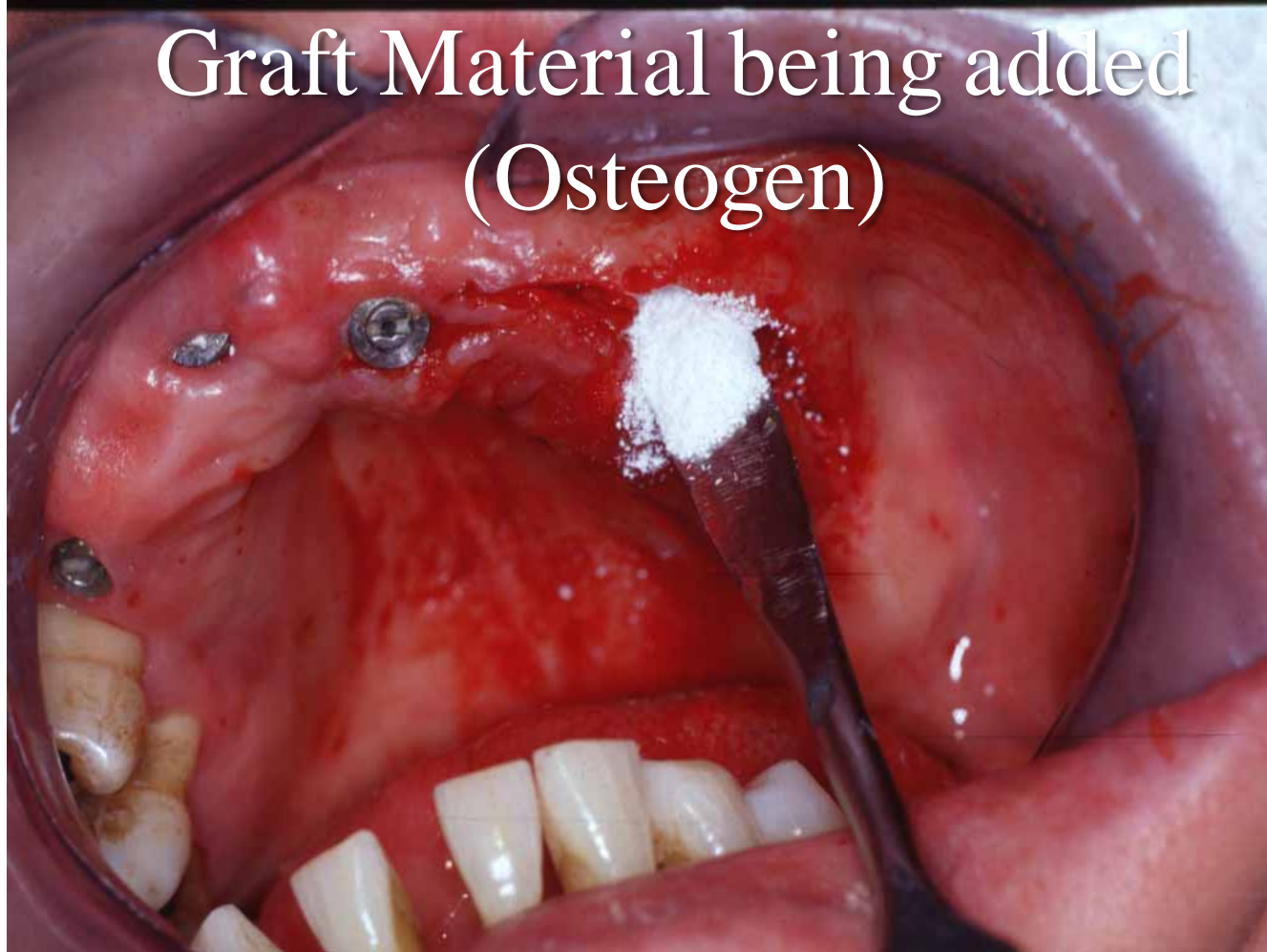Collatape made into a Plug

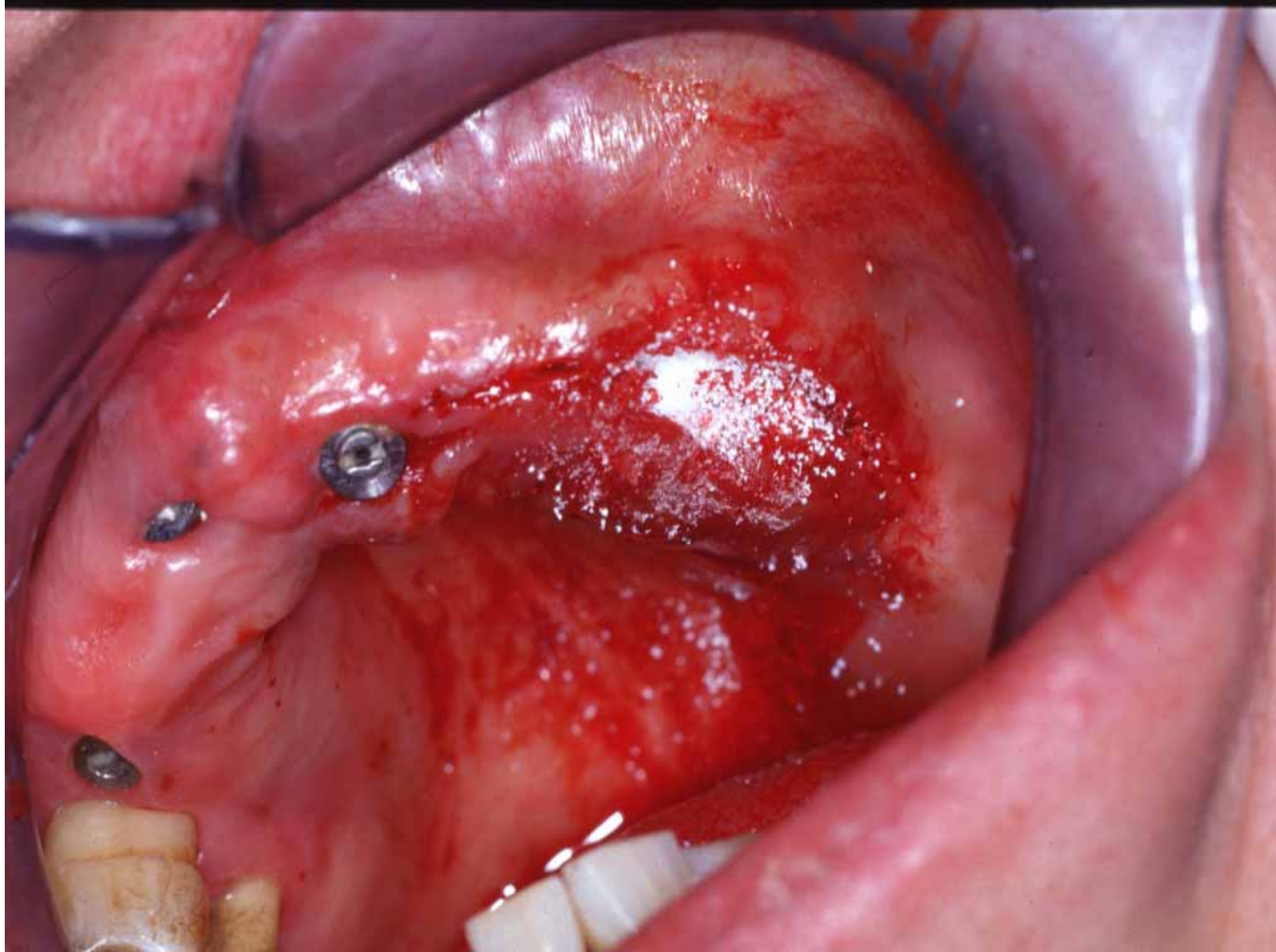


Plug being inserted

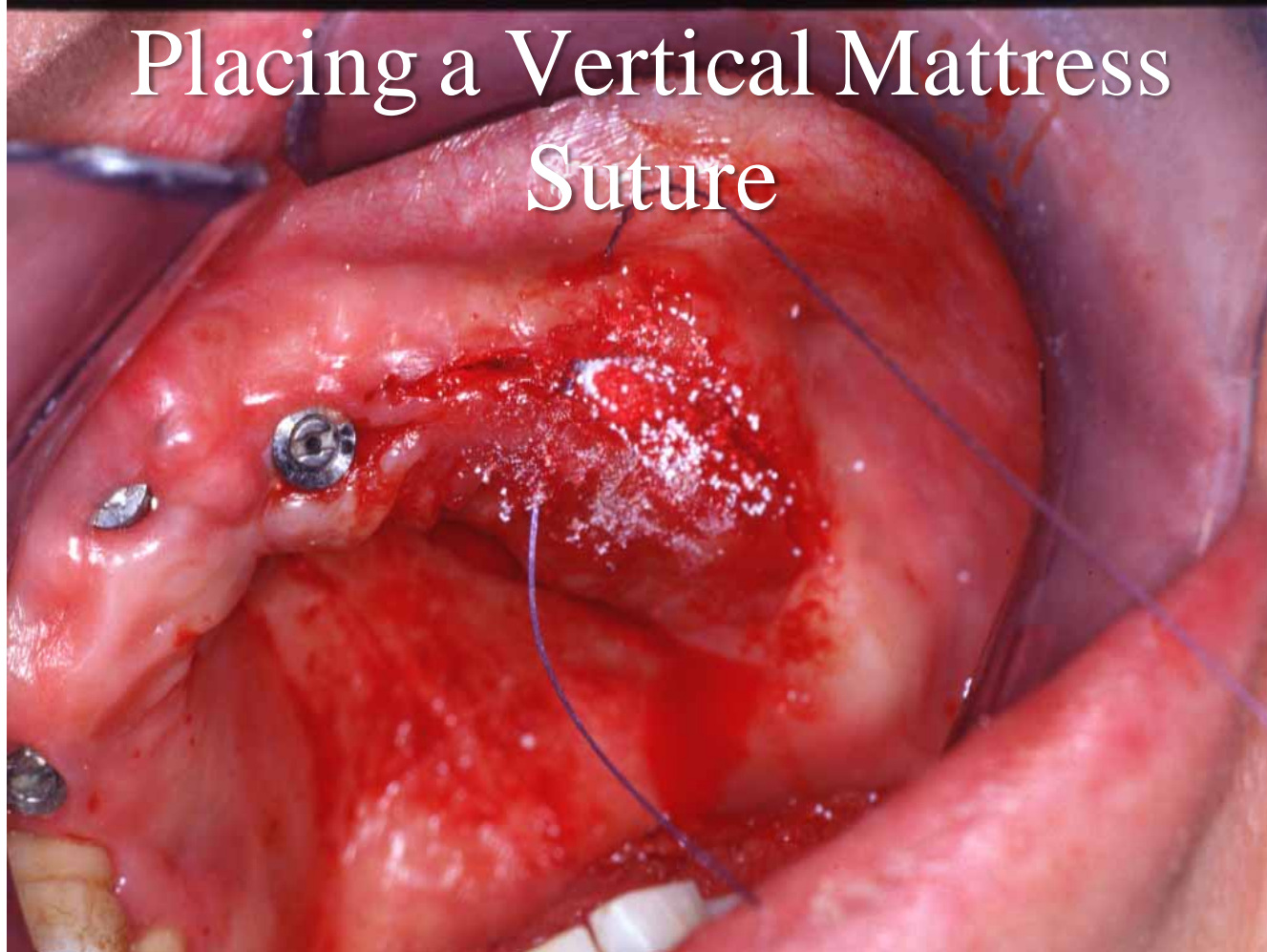


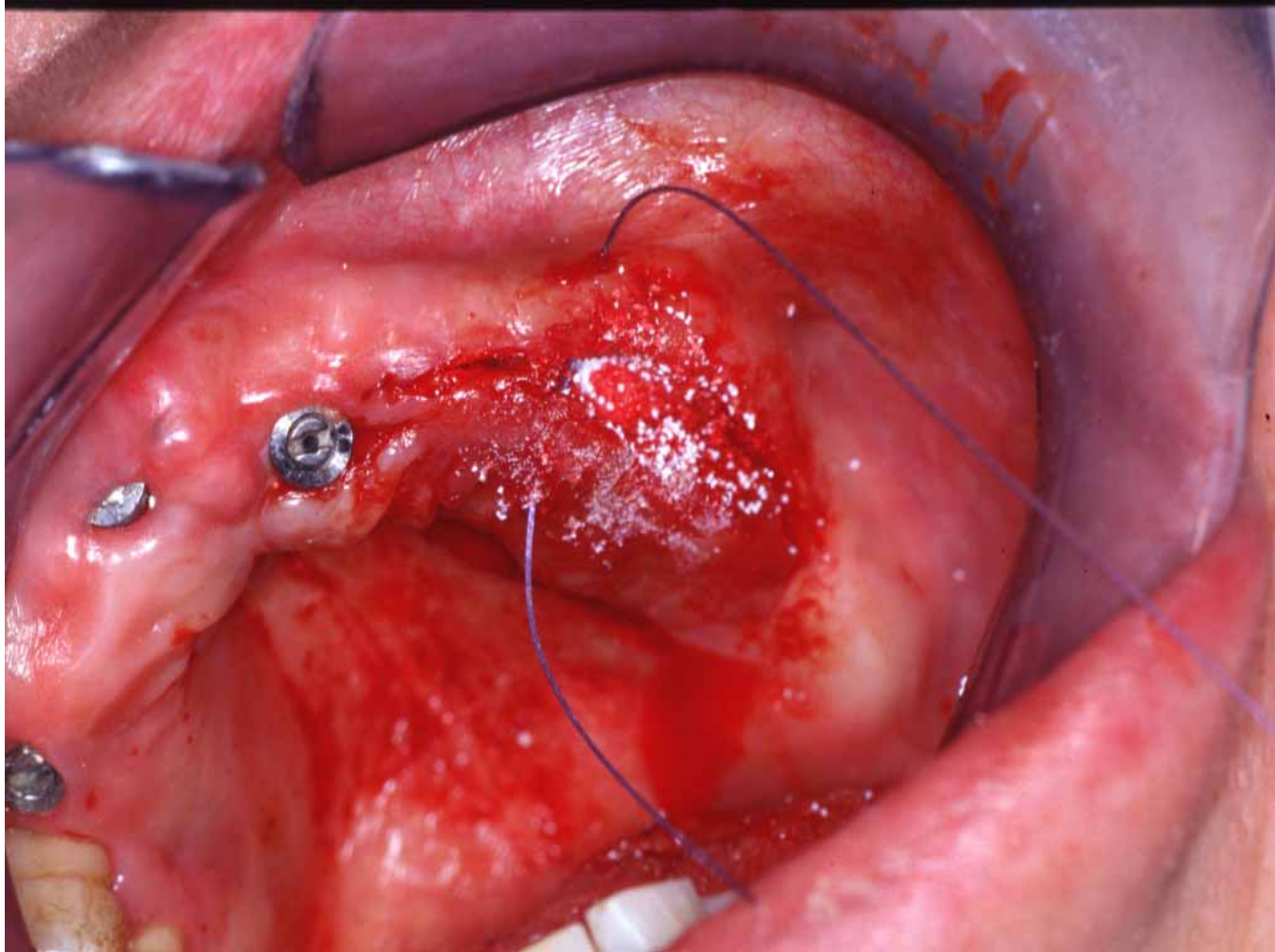
Graft Material being added
(Osteogen)

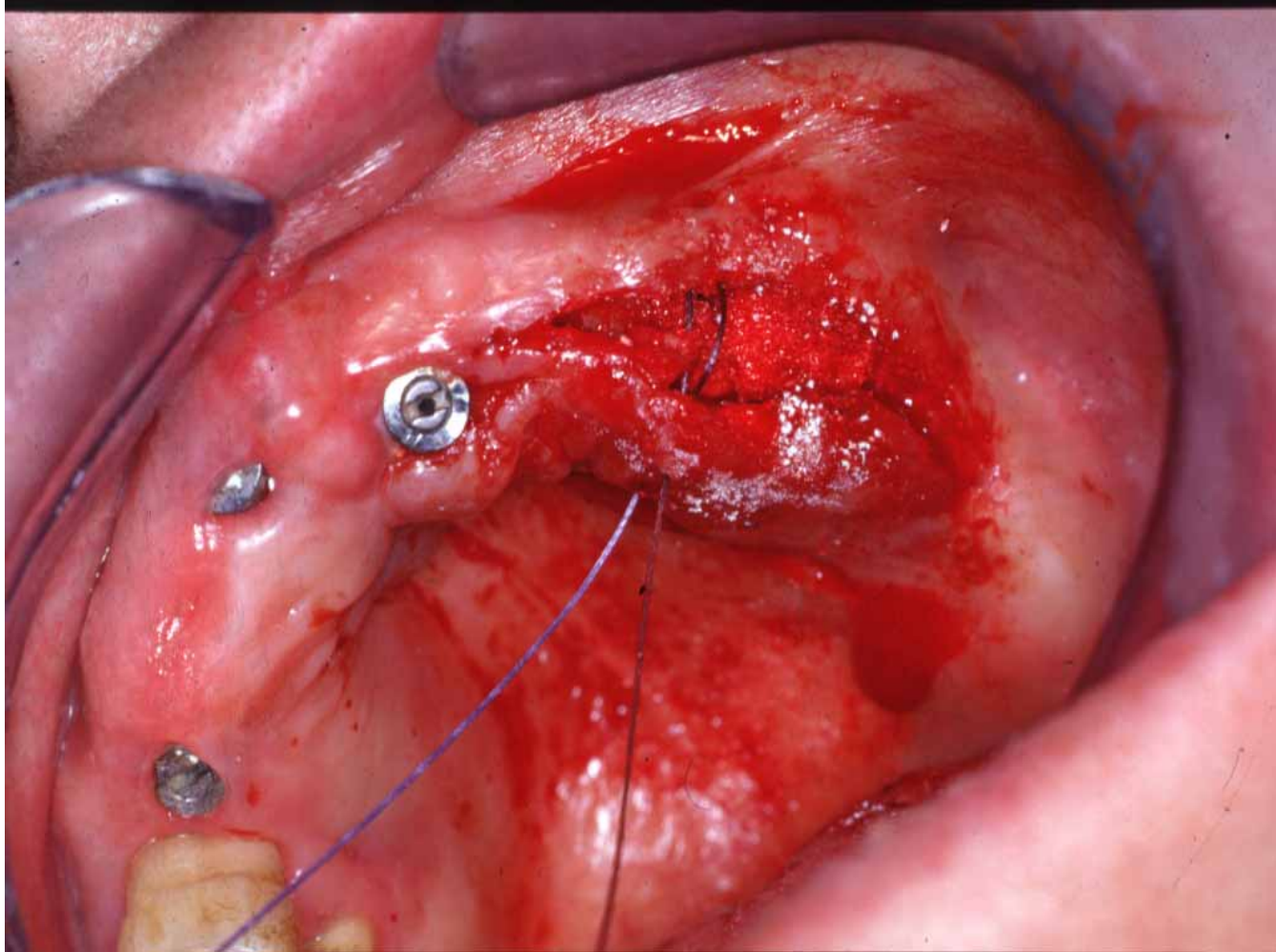


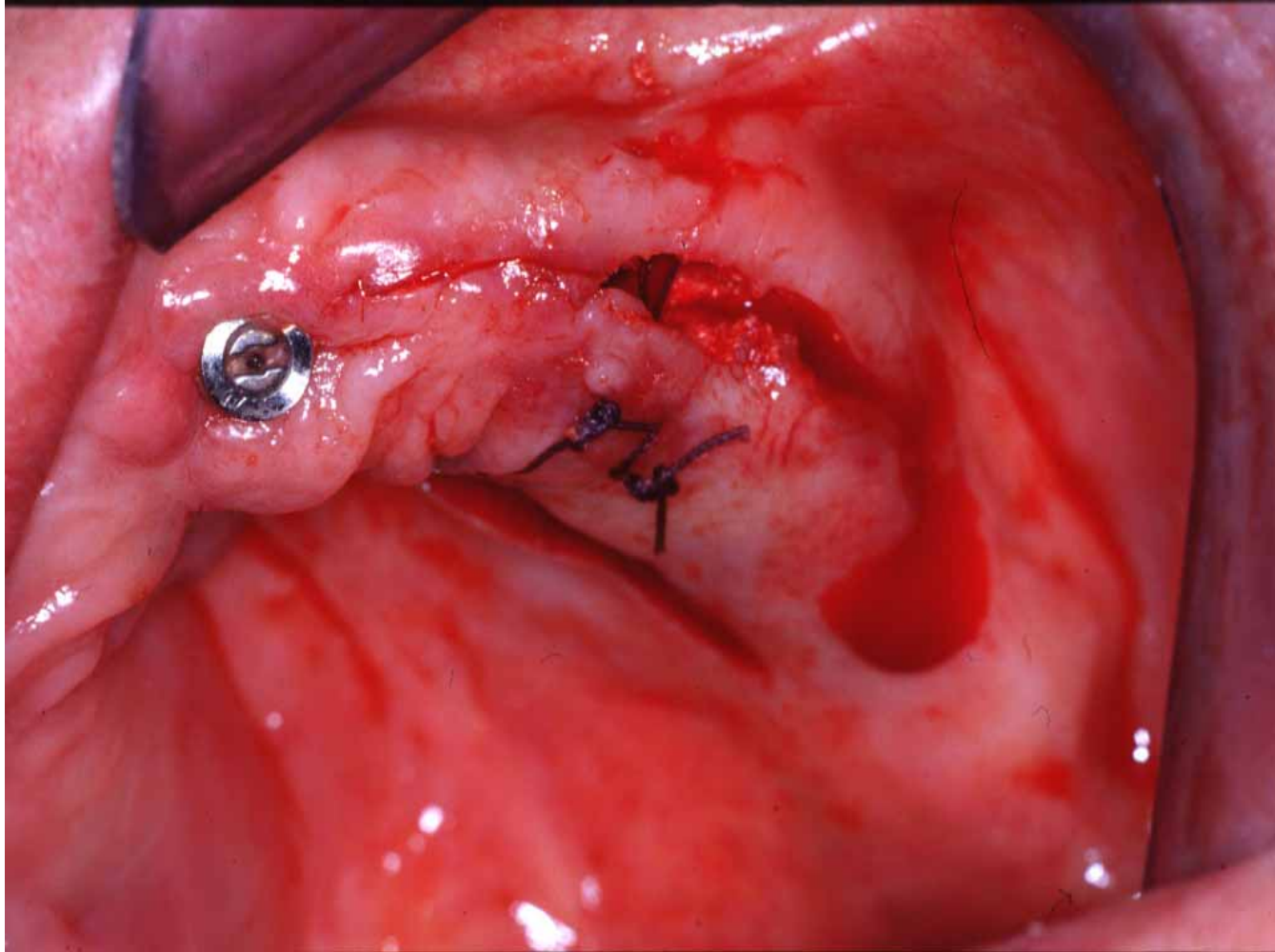


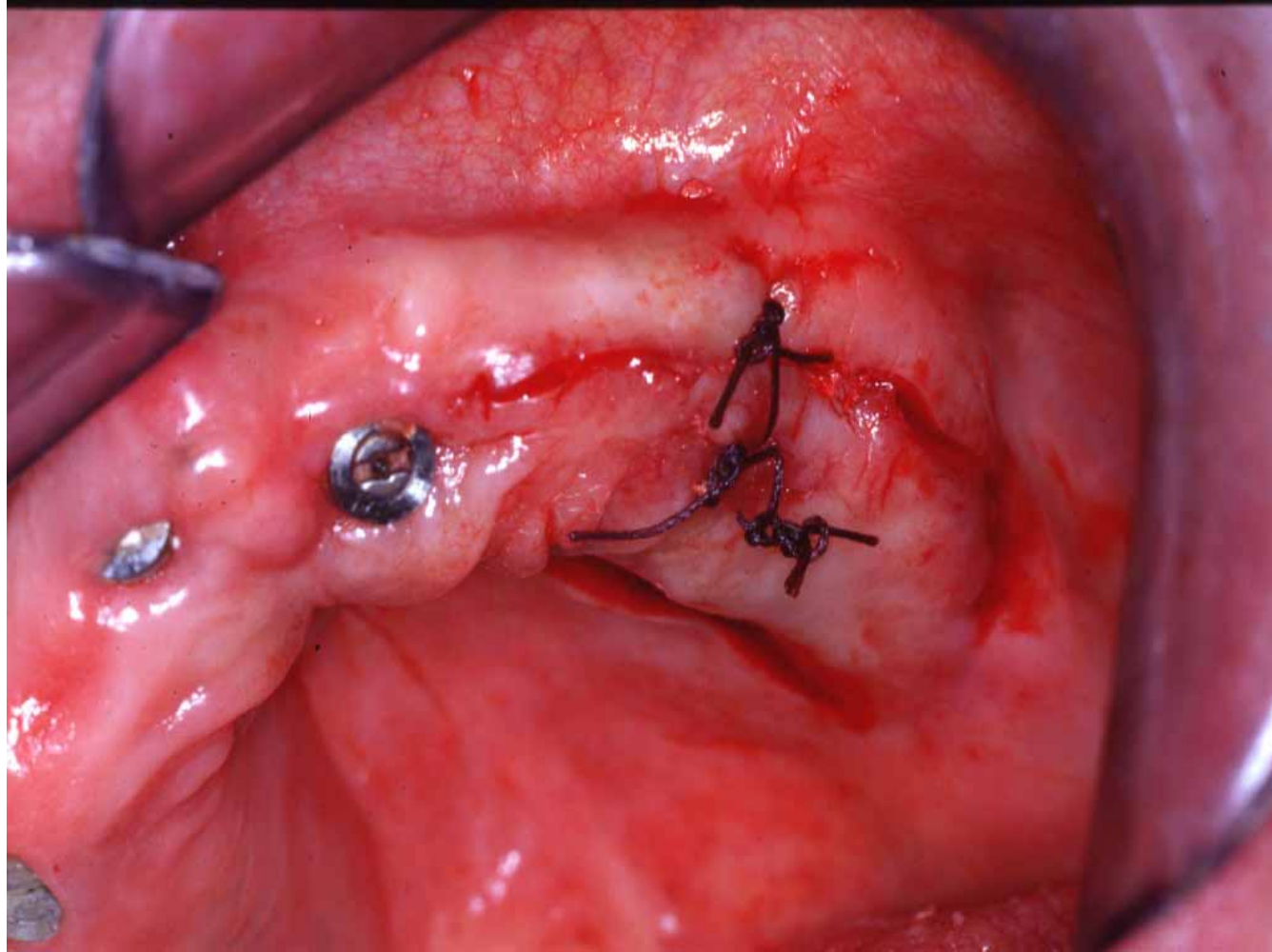
Placing a Vertical Mattress Suture



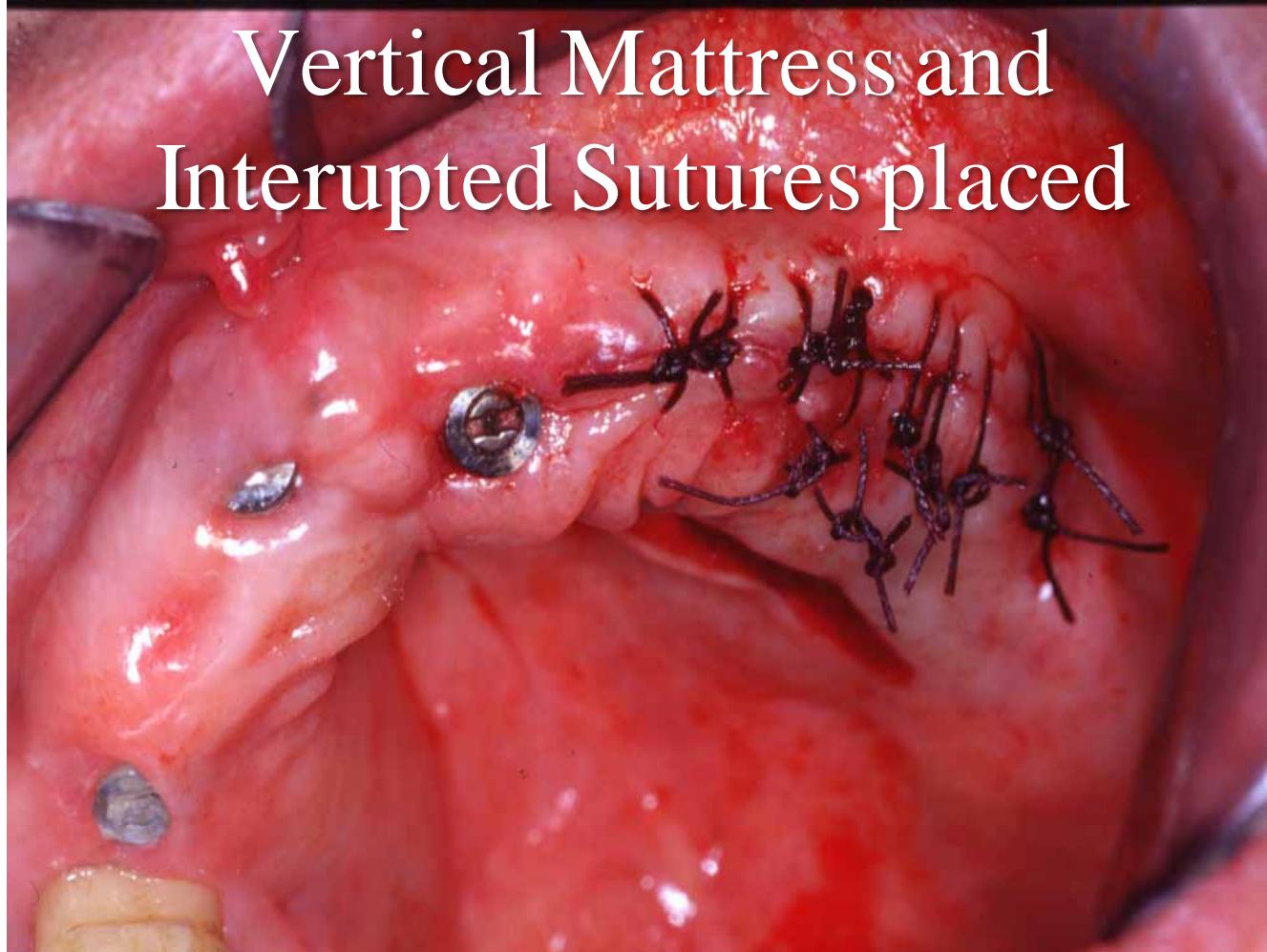


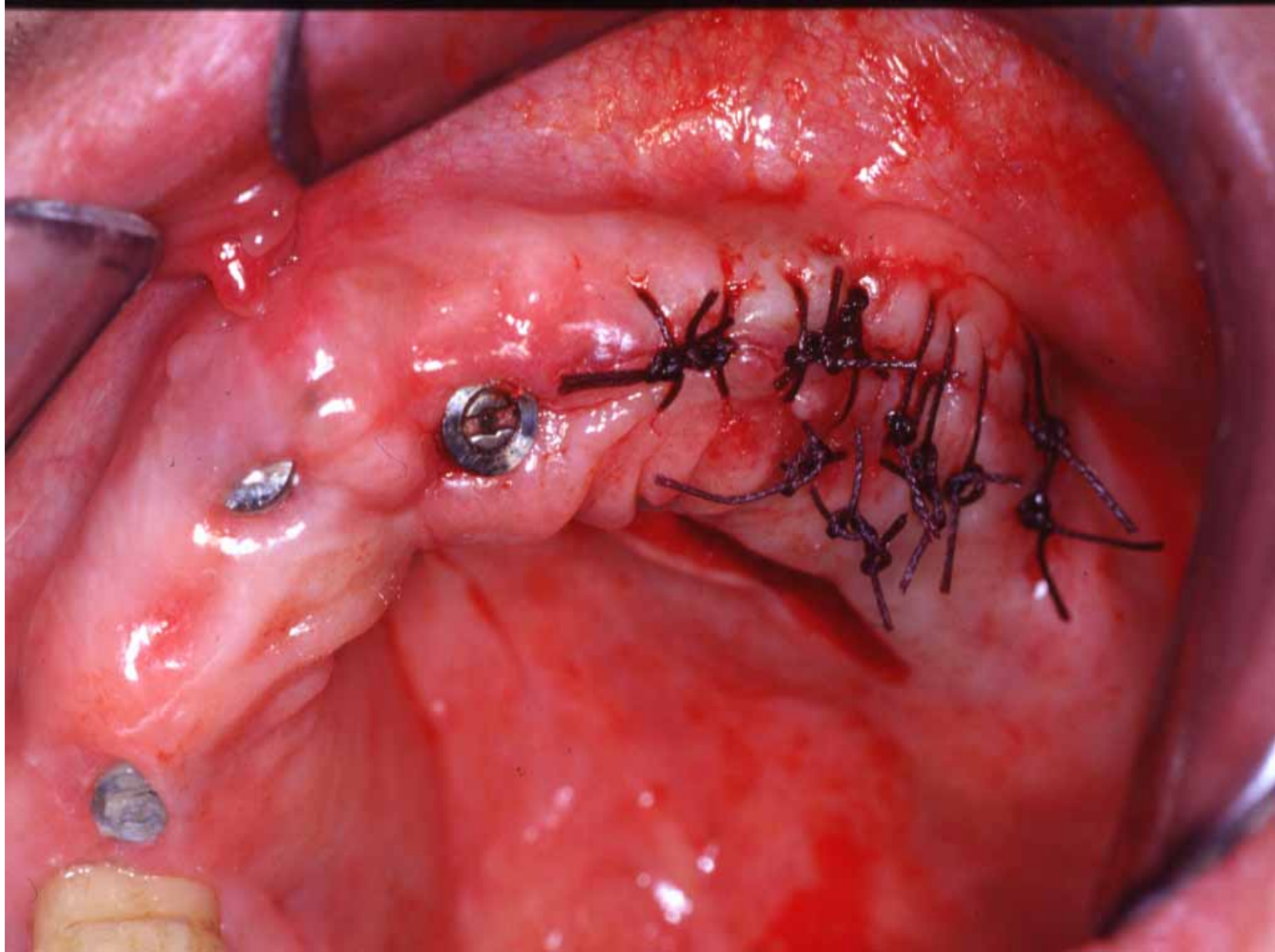




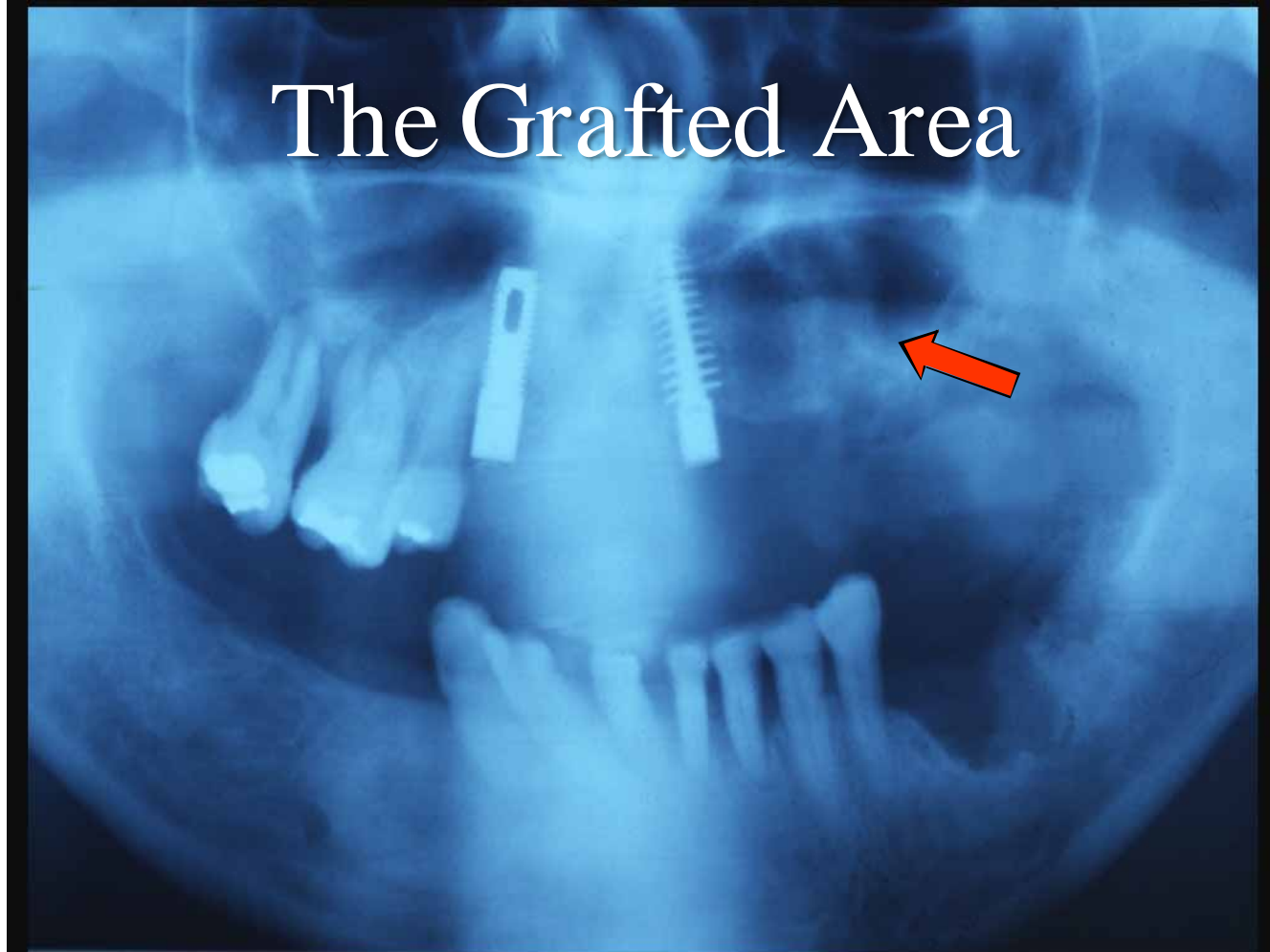

Vertical Mattress and
Interrupted Sutures placed





The Grafted Area



A New Implant placed

