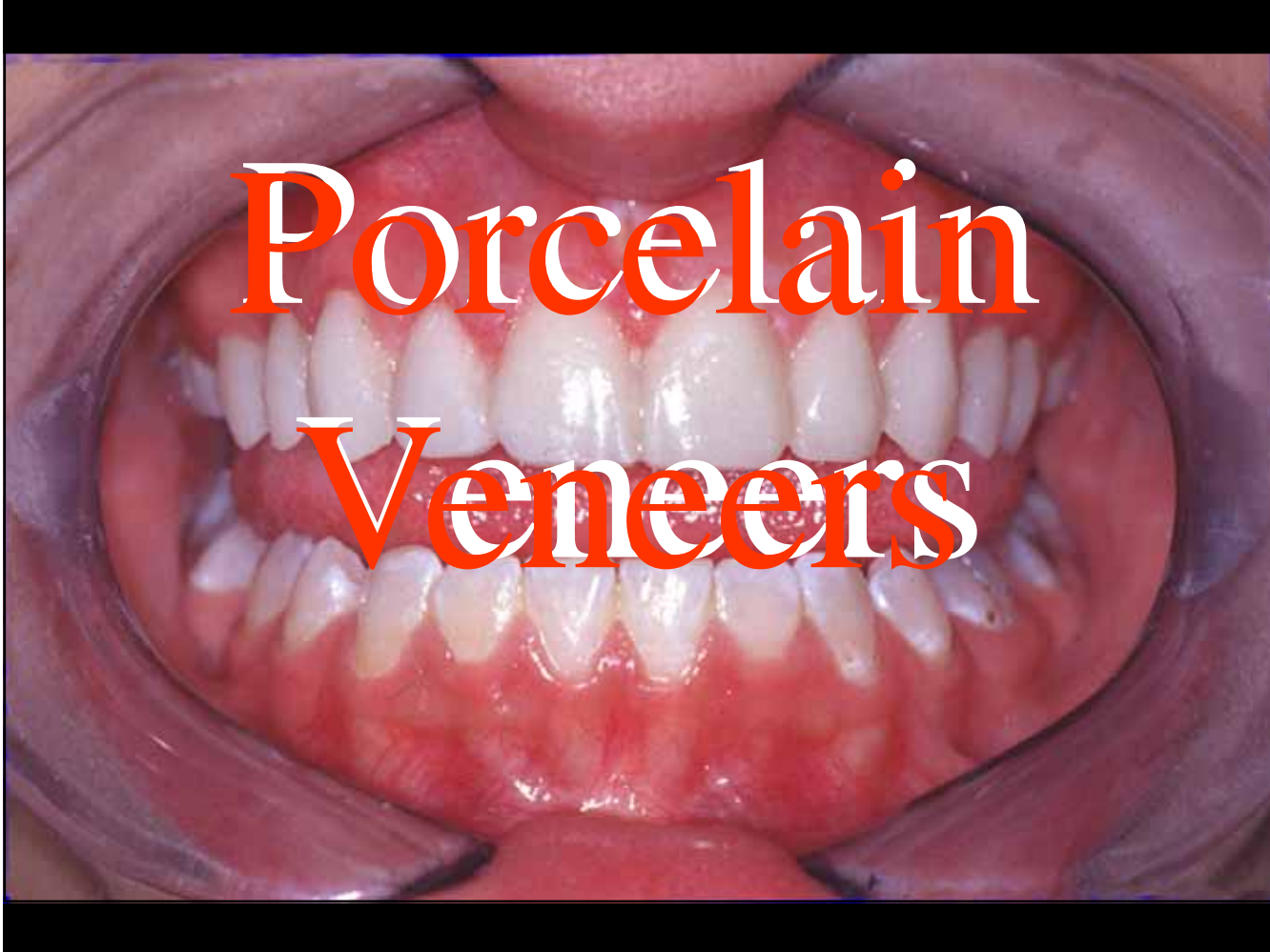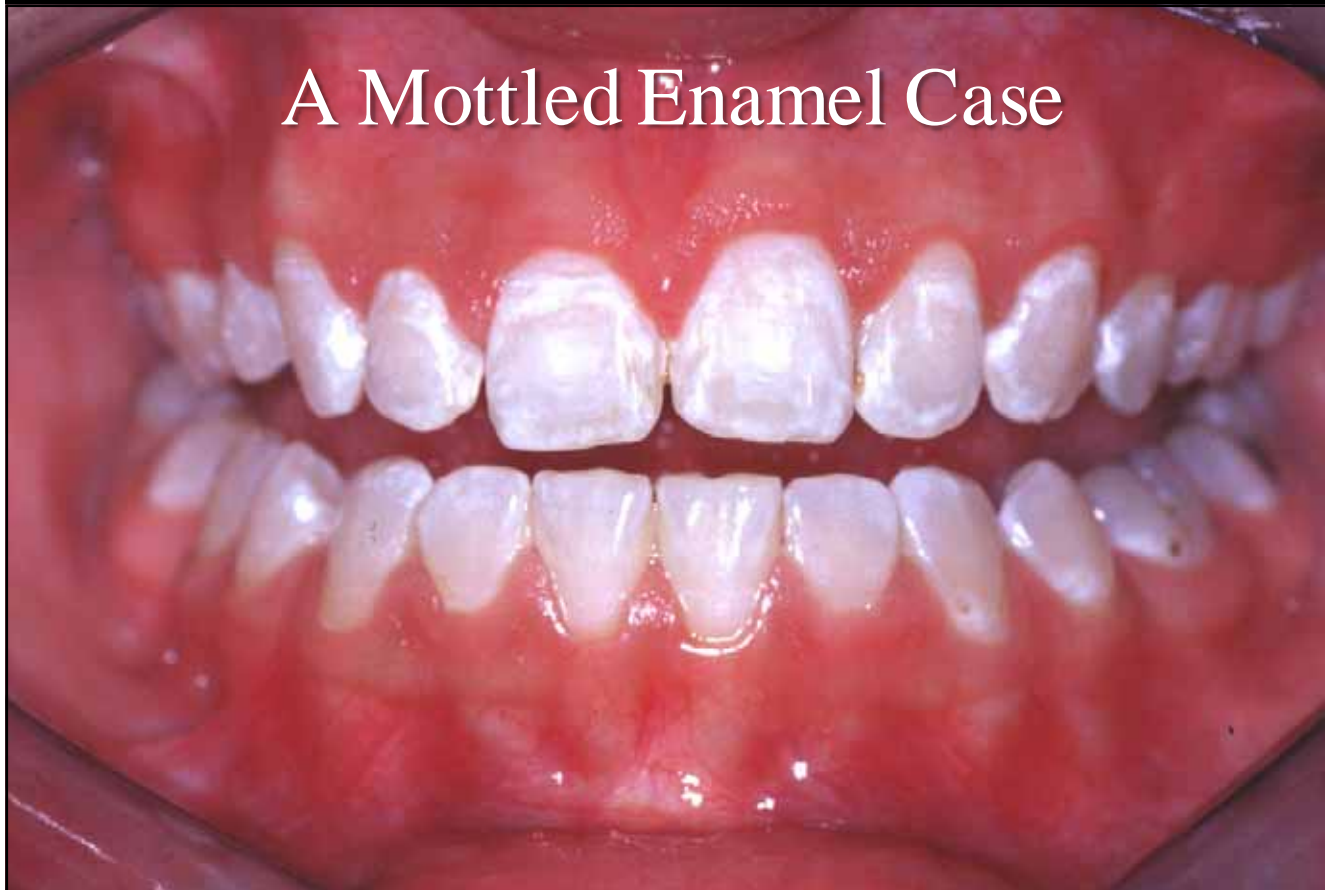

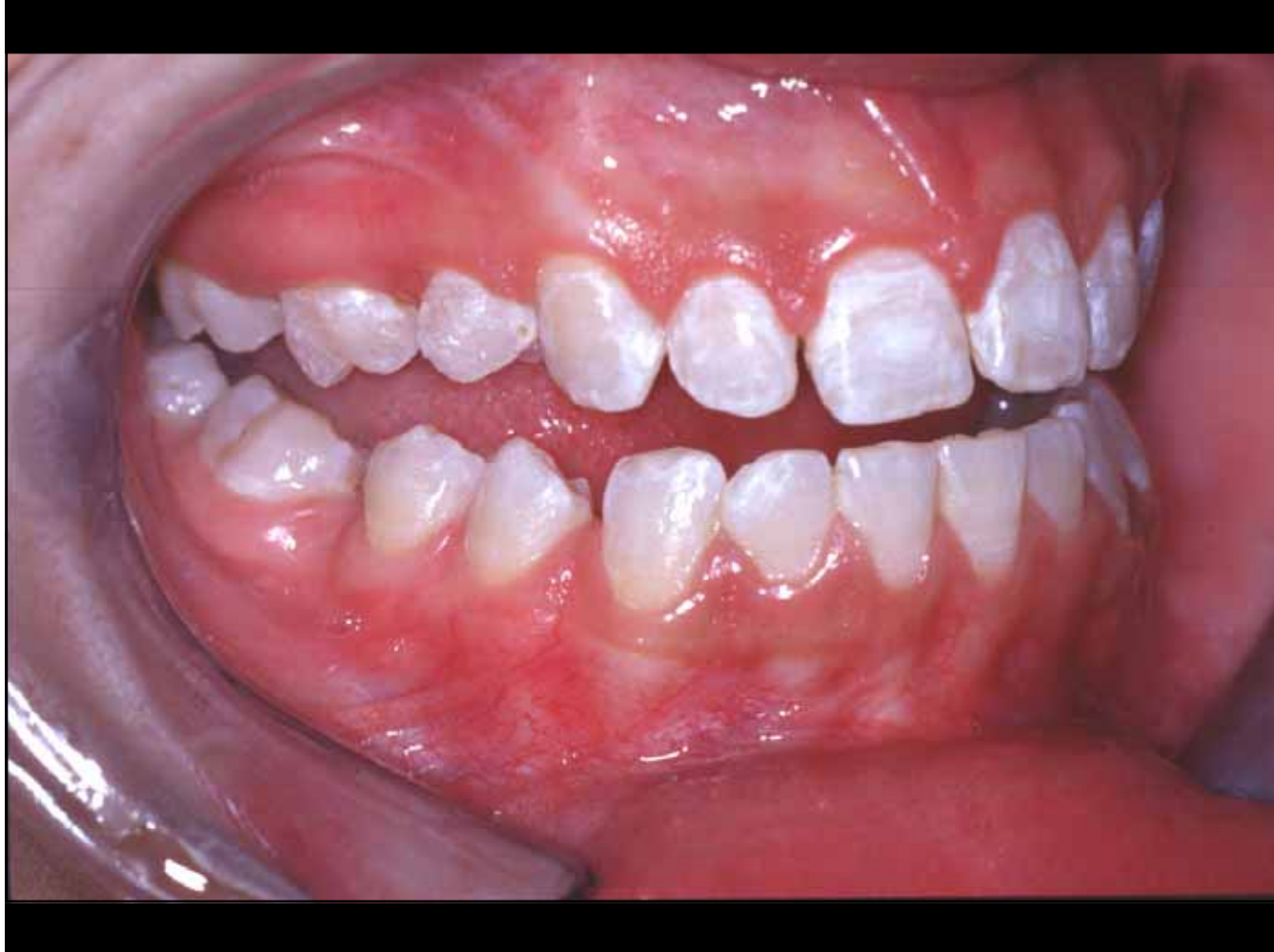


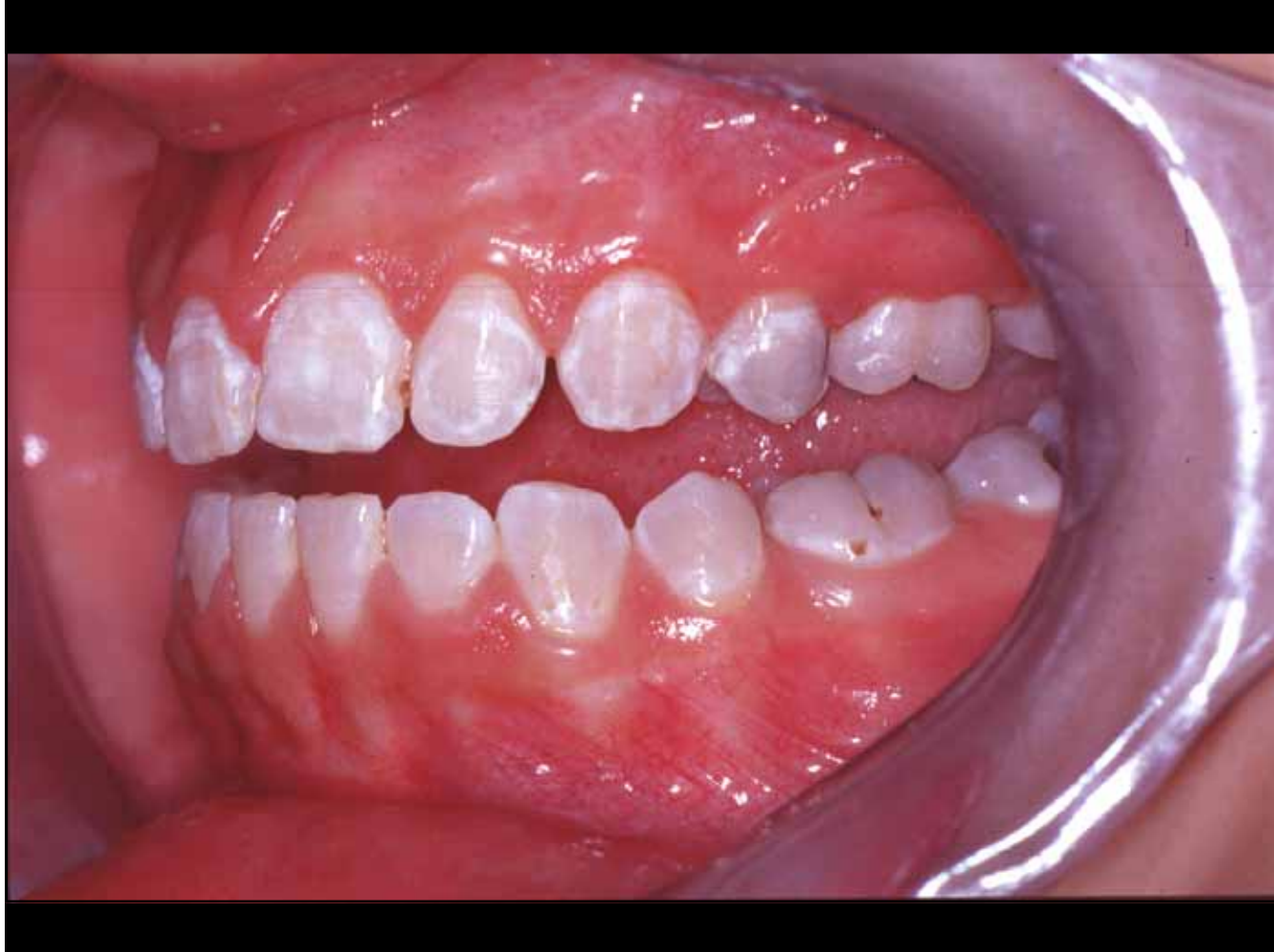Porcelain  
Veneers

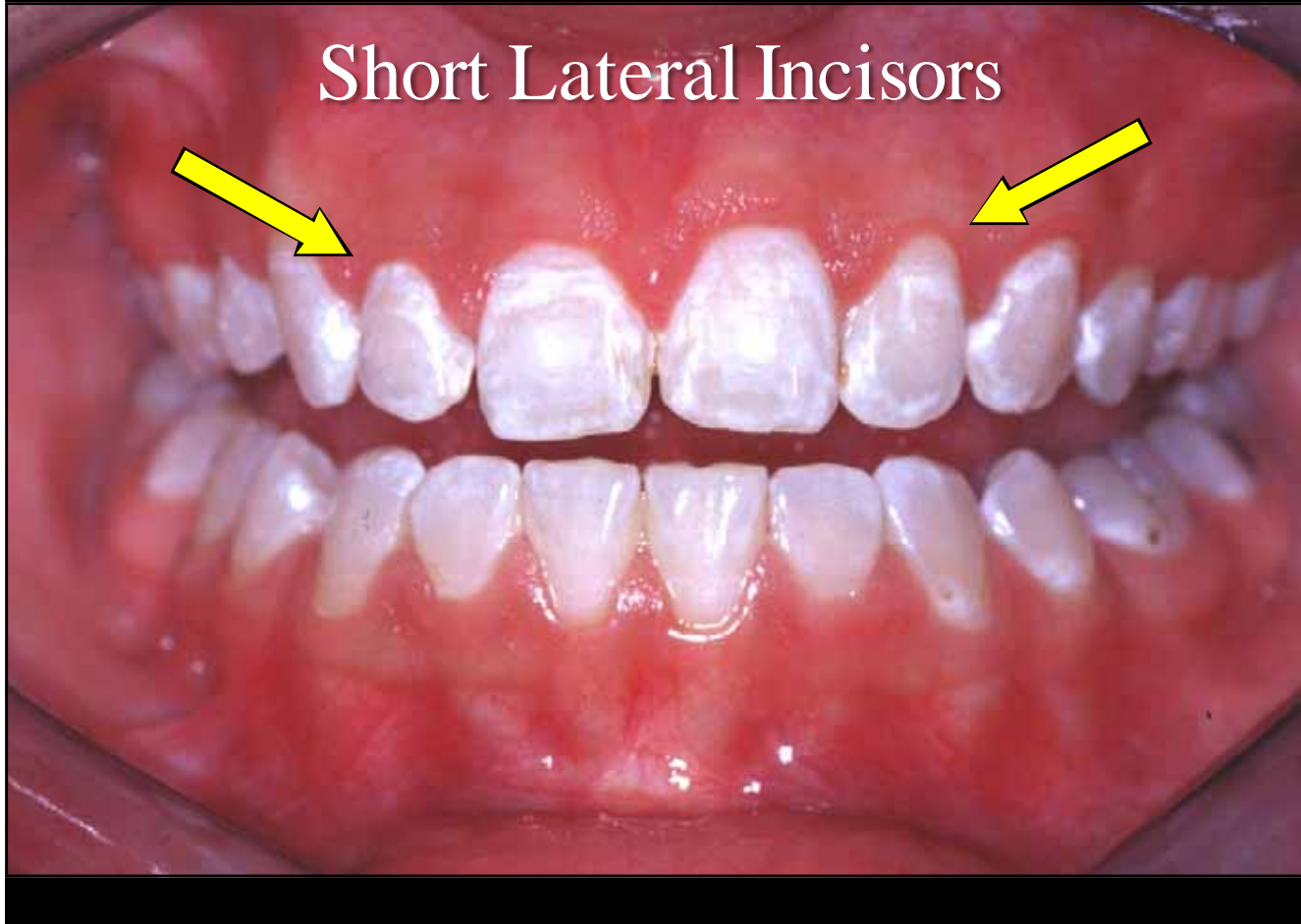
## A Mottled Enamel Case



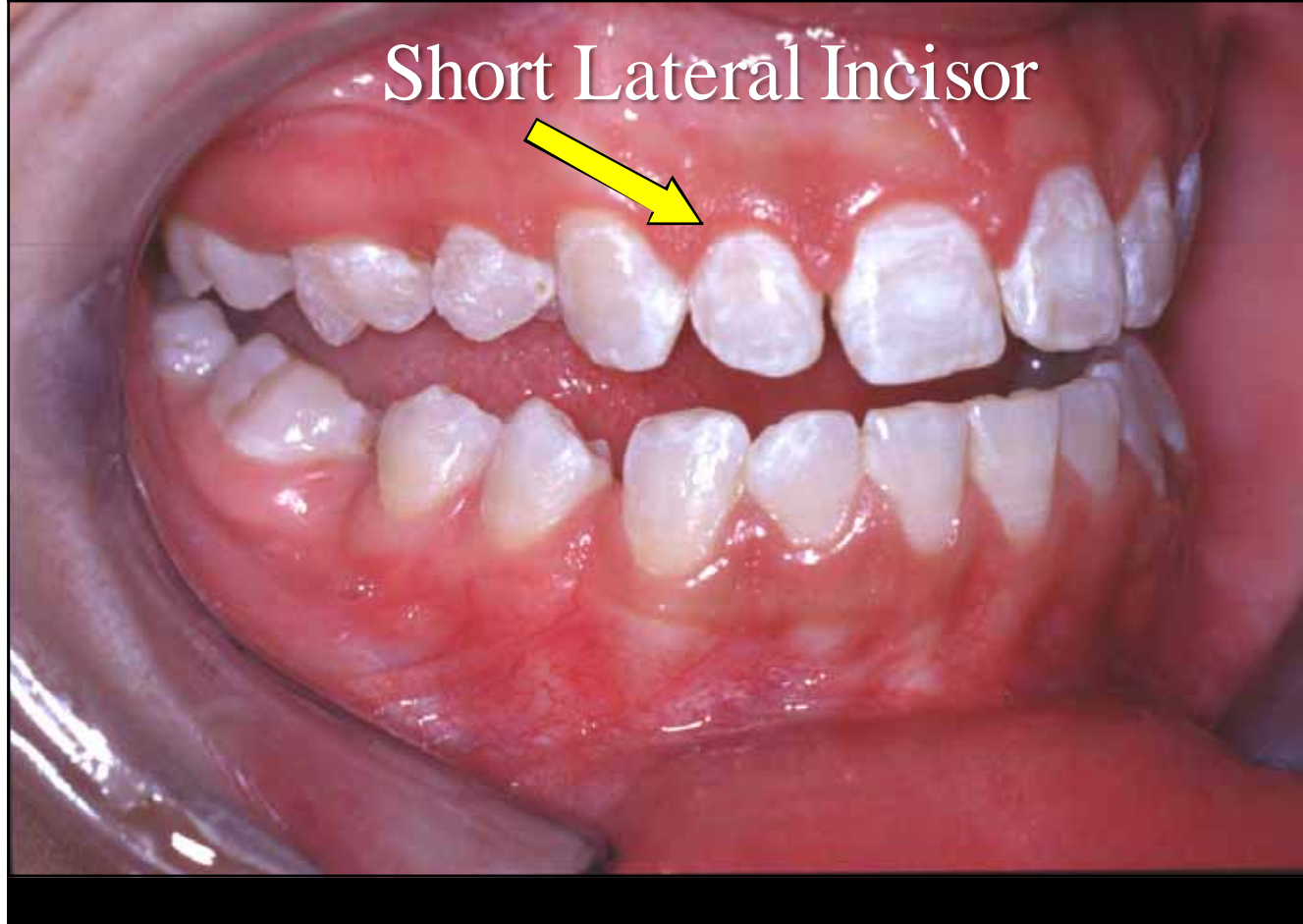




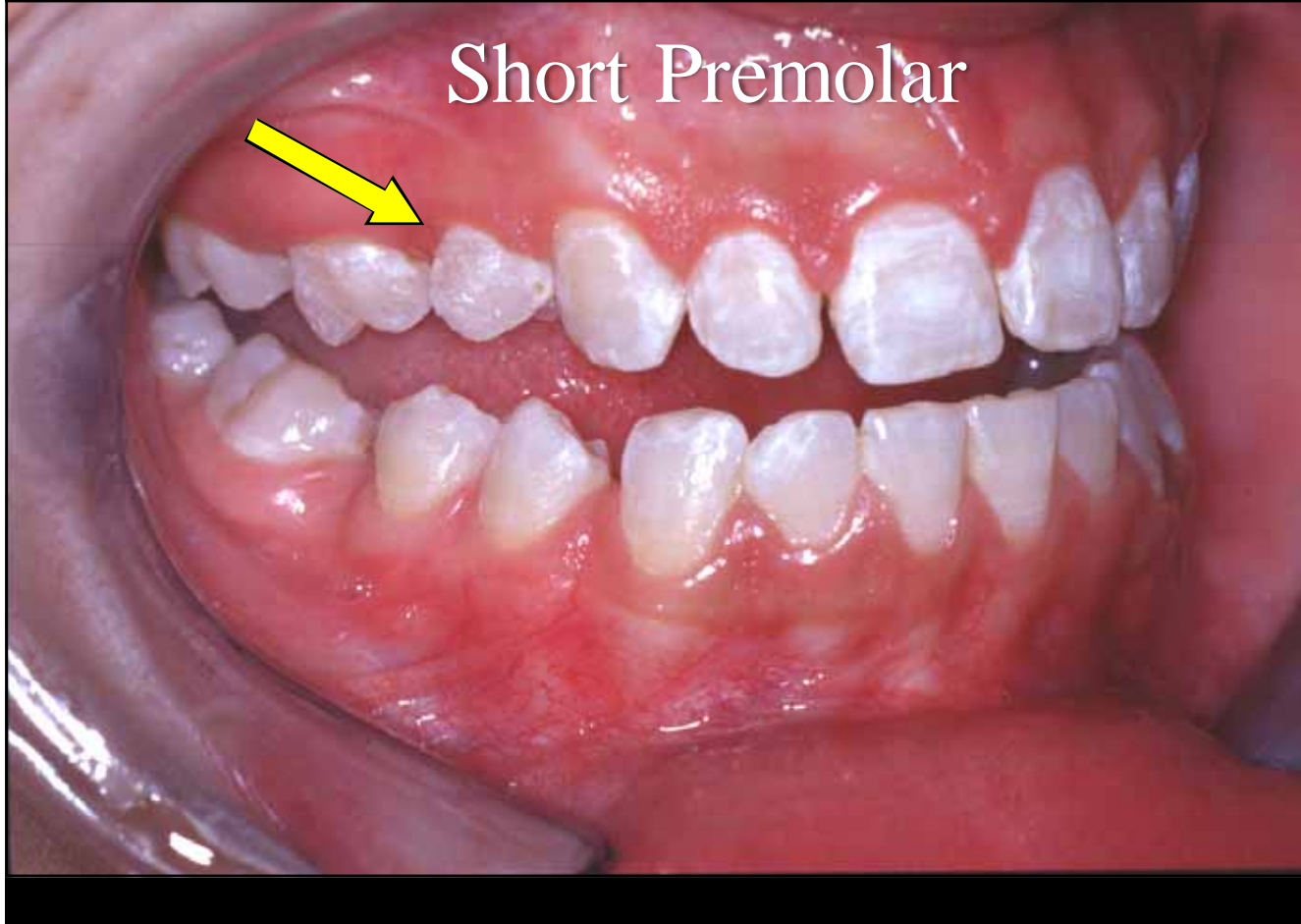
Short Lateral Incisors



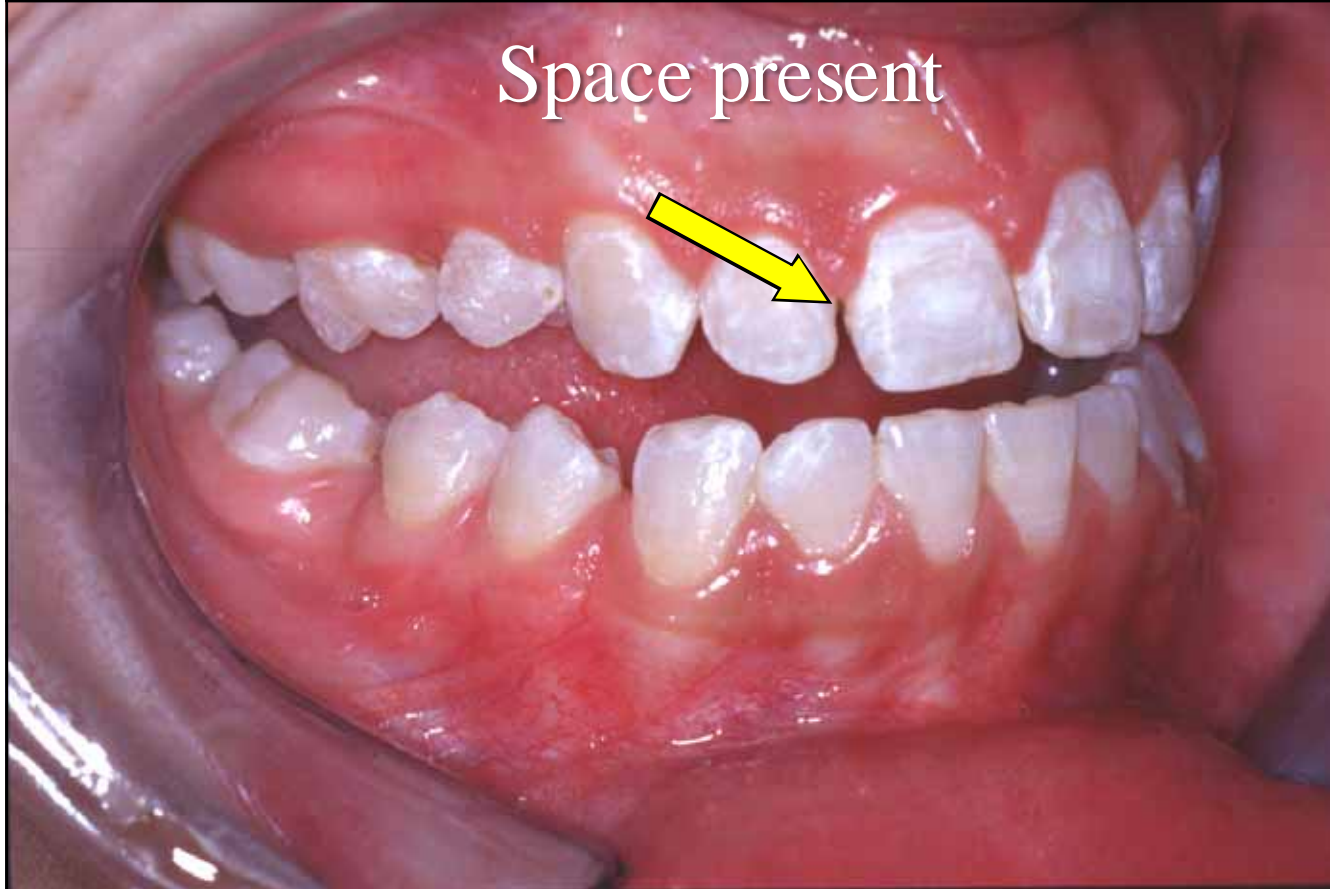
Short Lateral Incisor



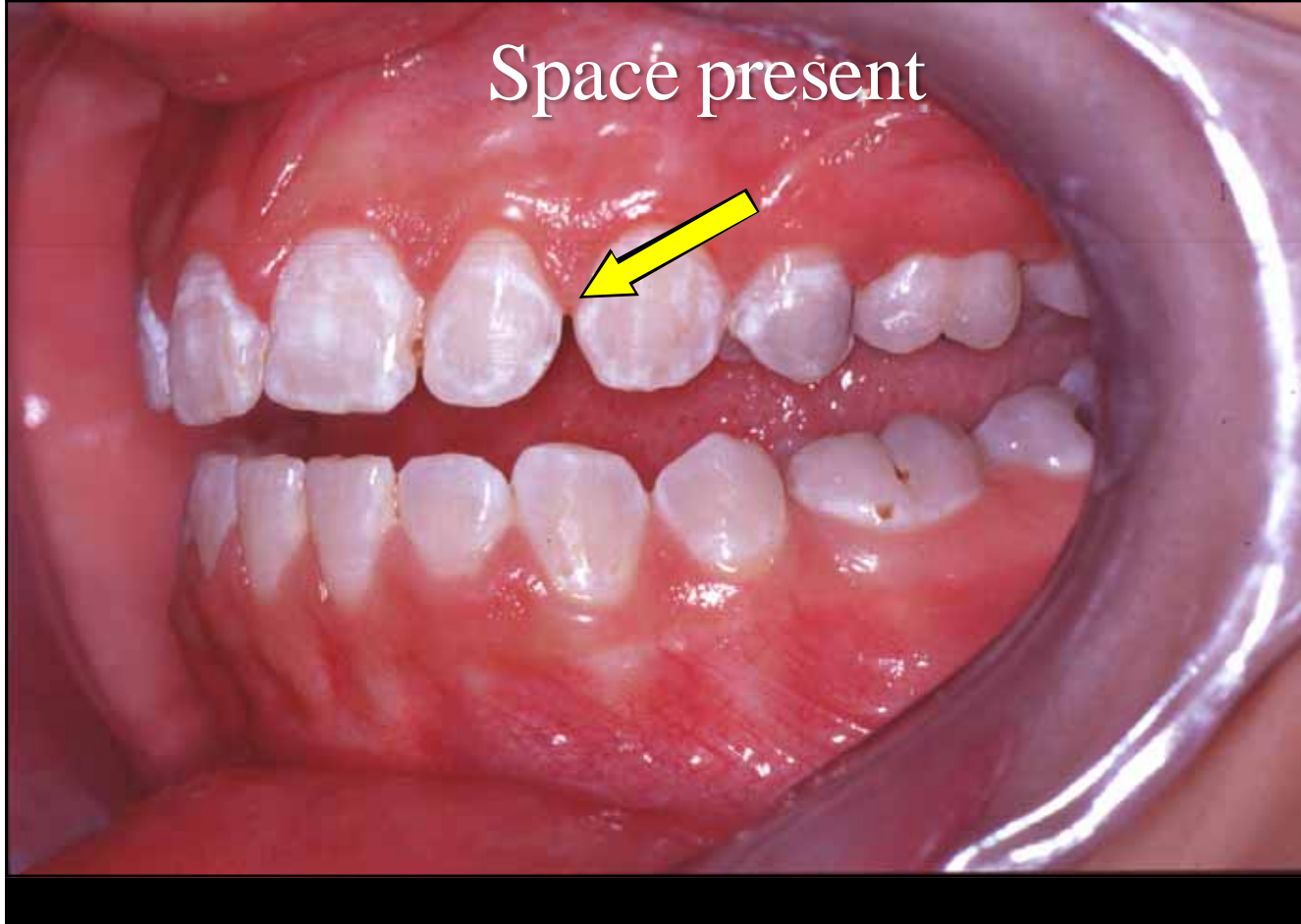
Short Premolar



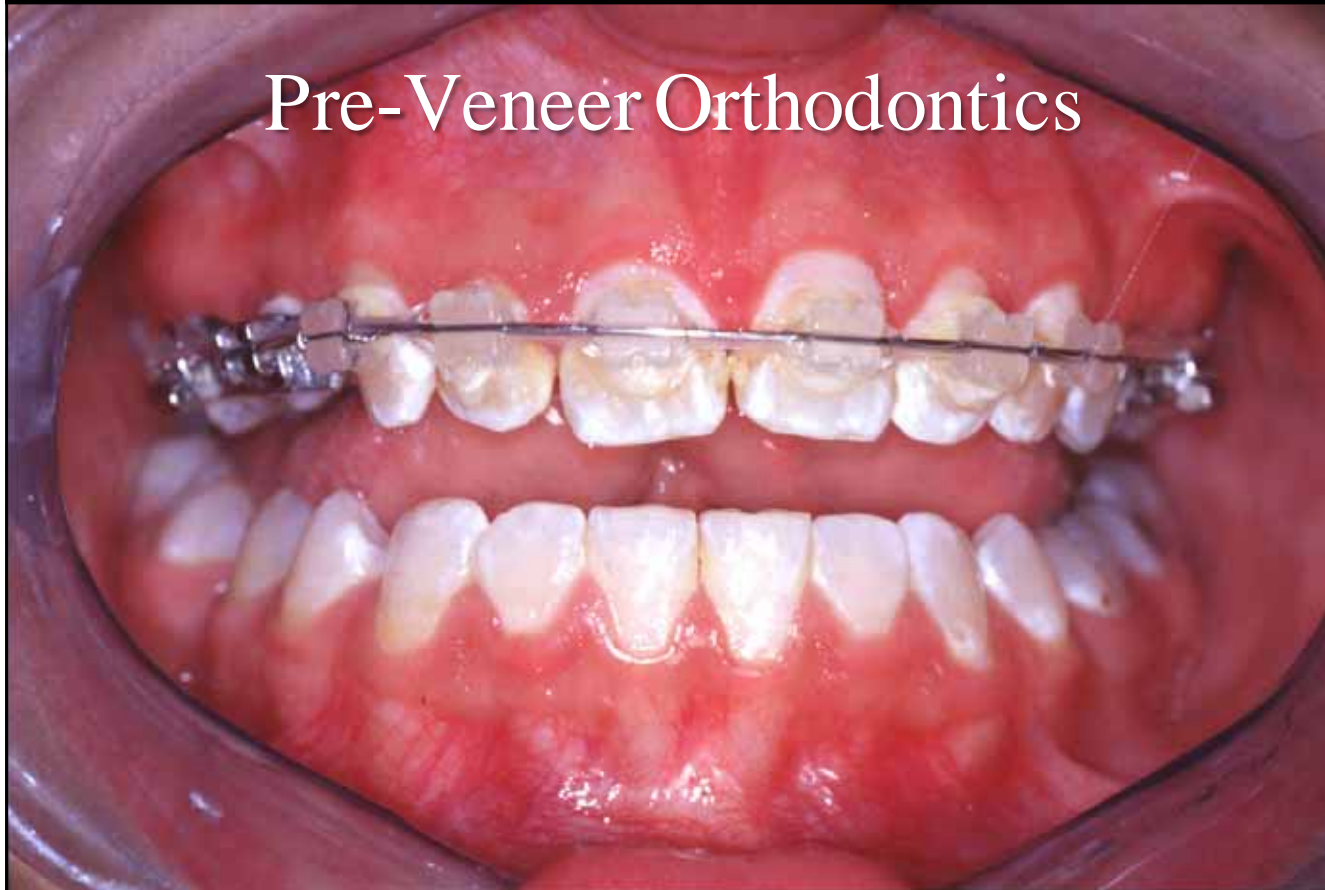
Space present



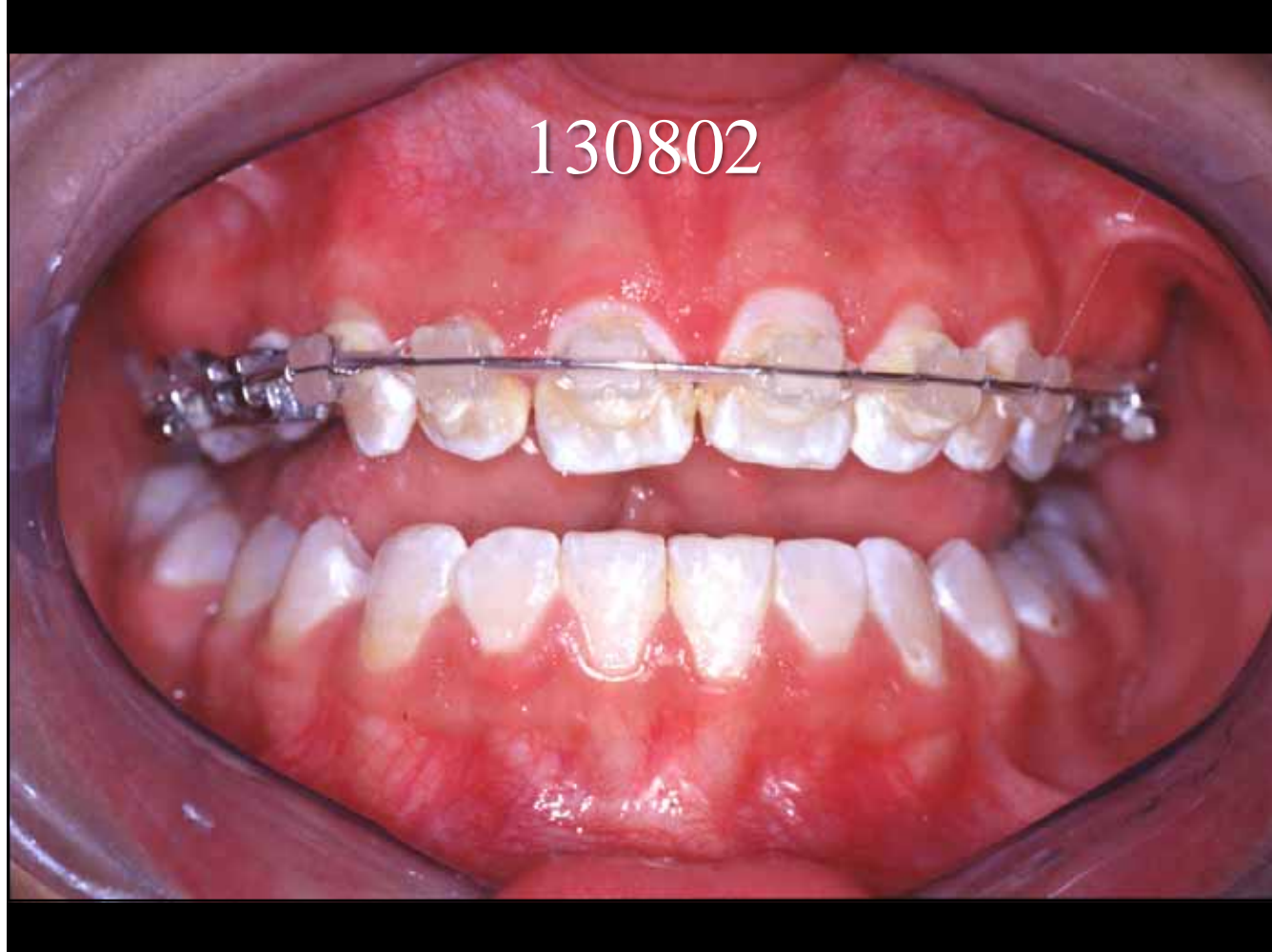Space present

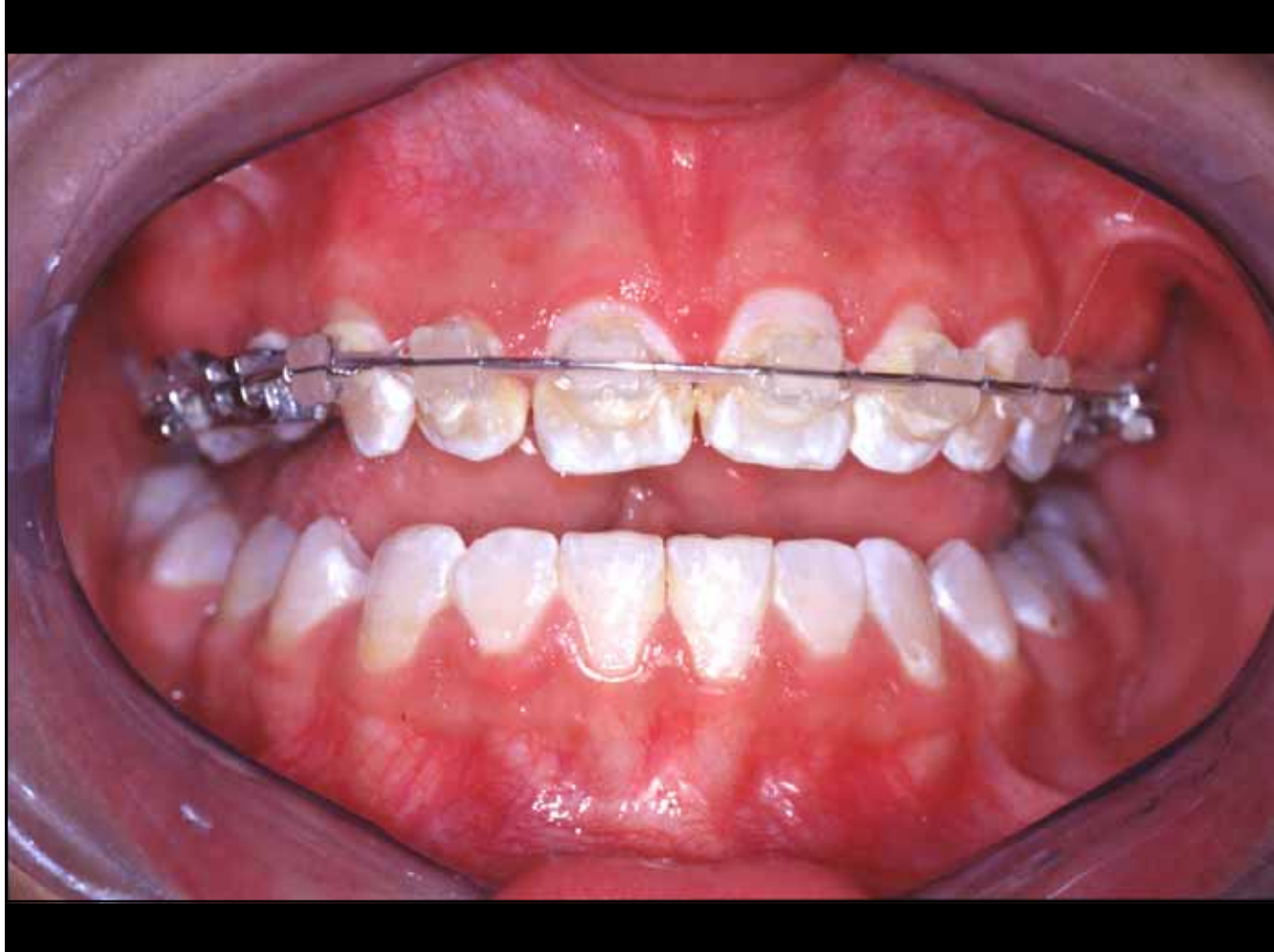

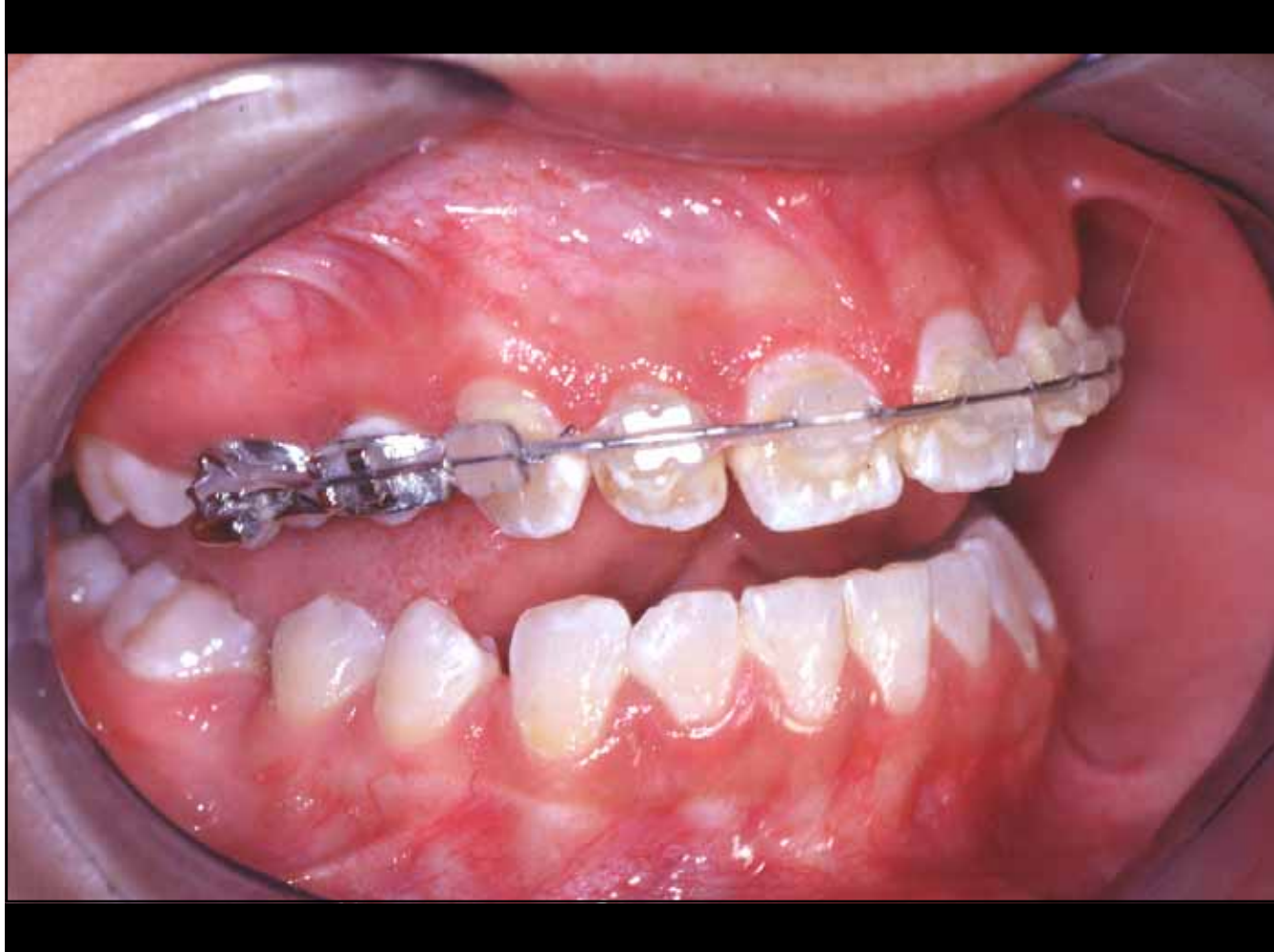Pre-Veneer Orthodontics

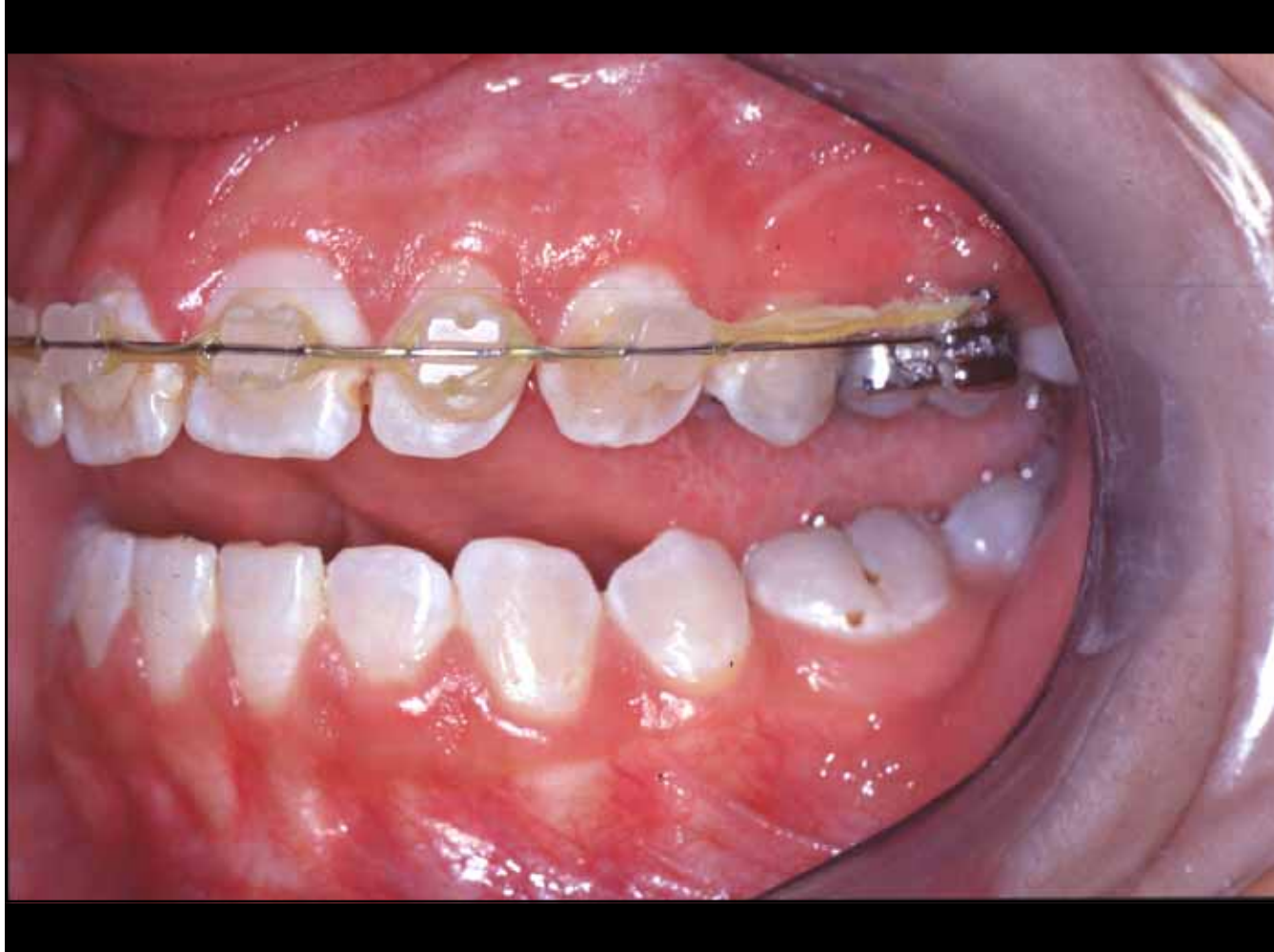

130802

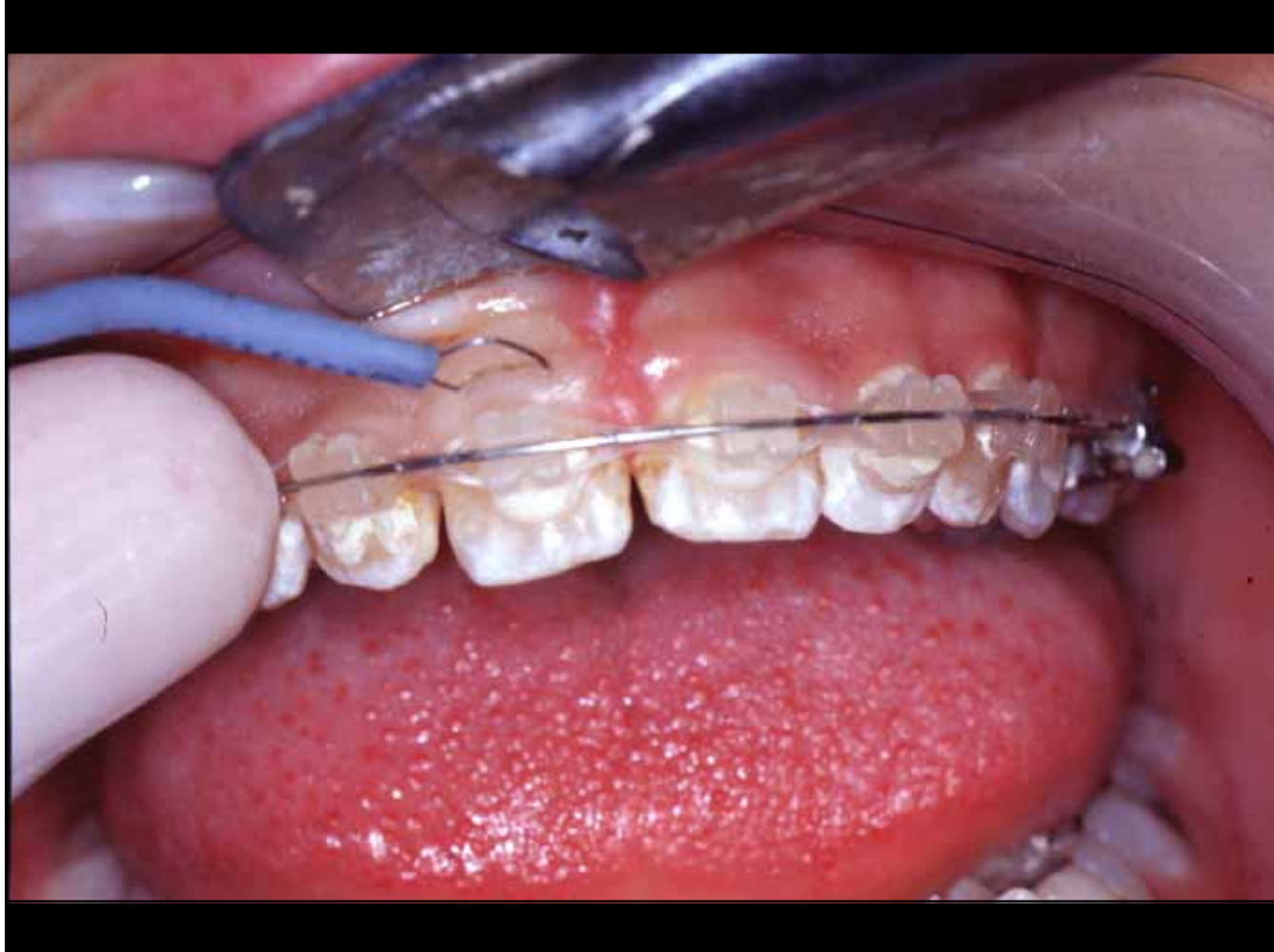


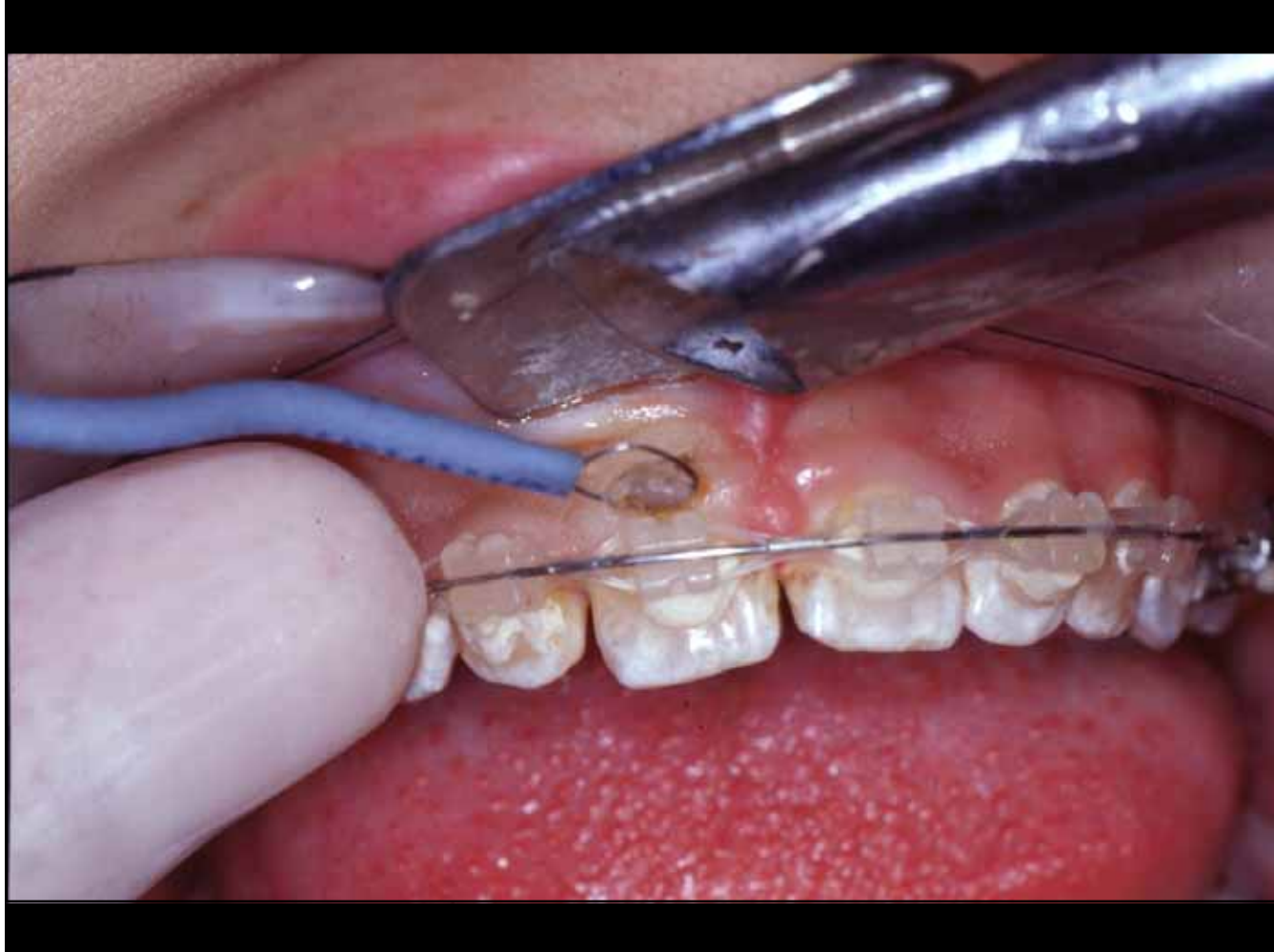


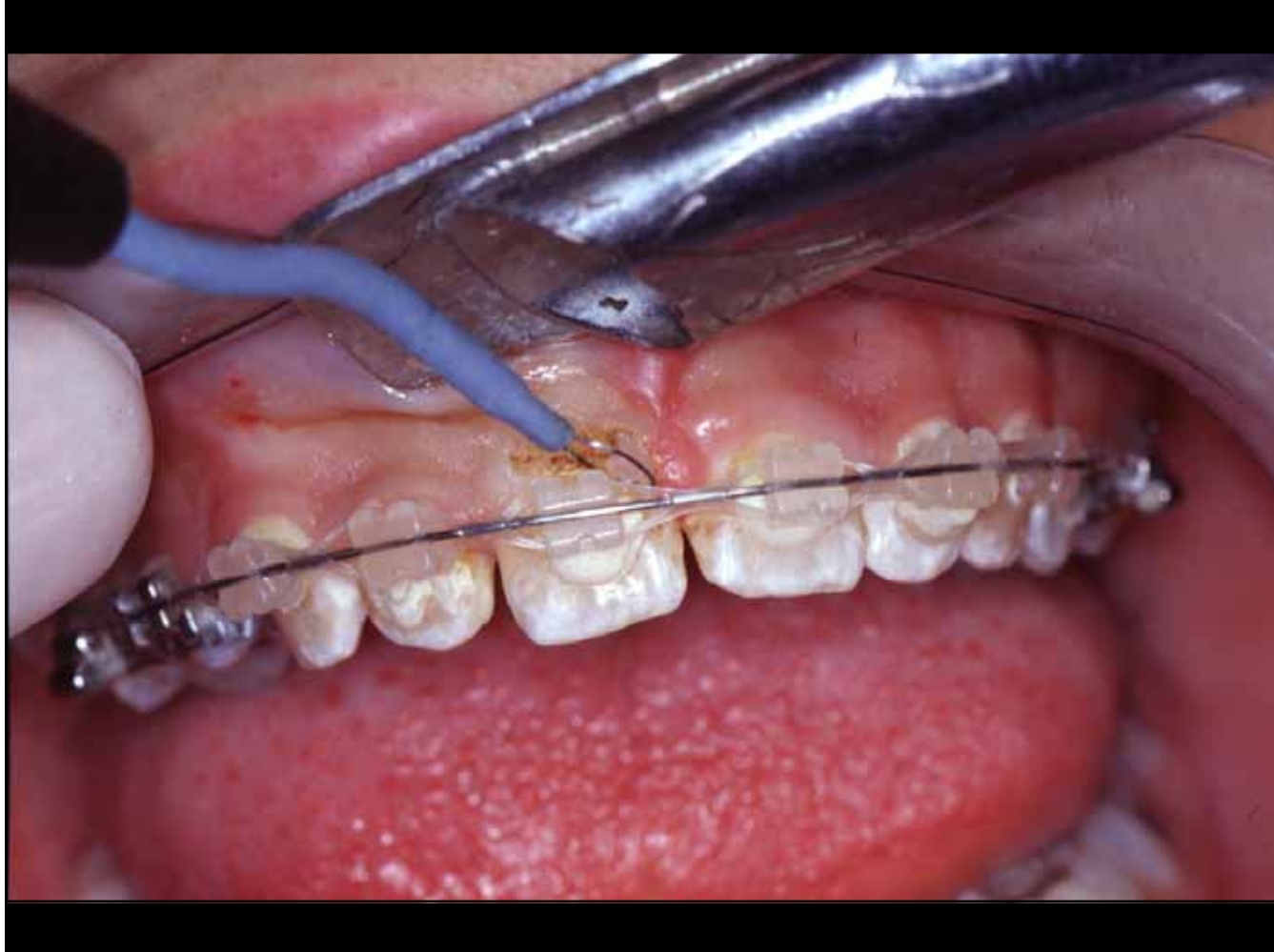


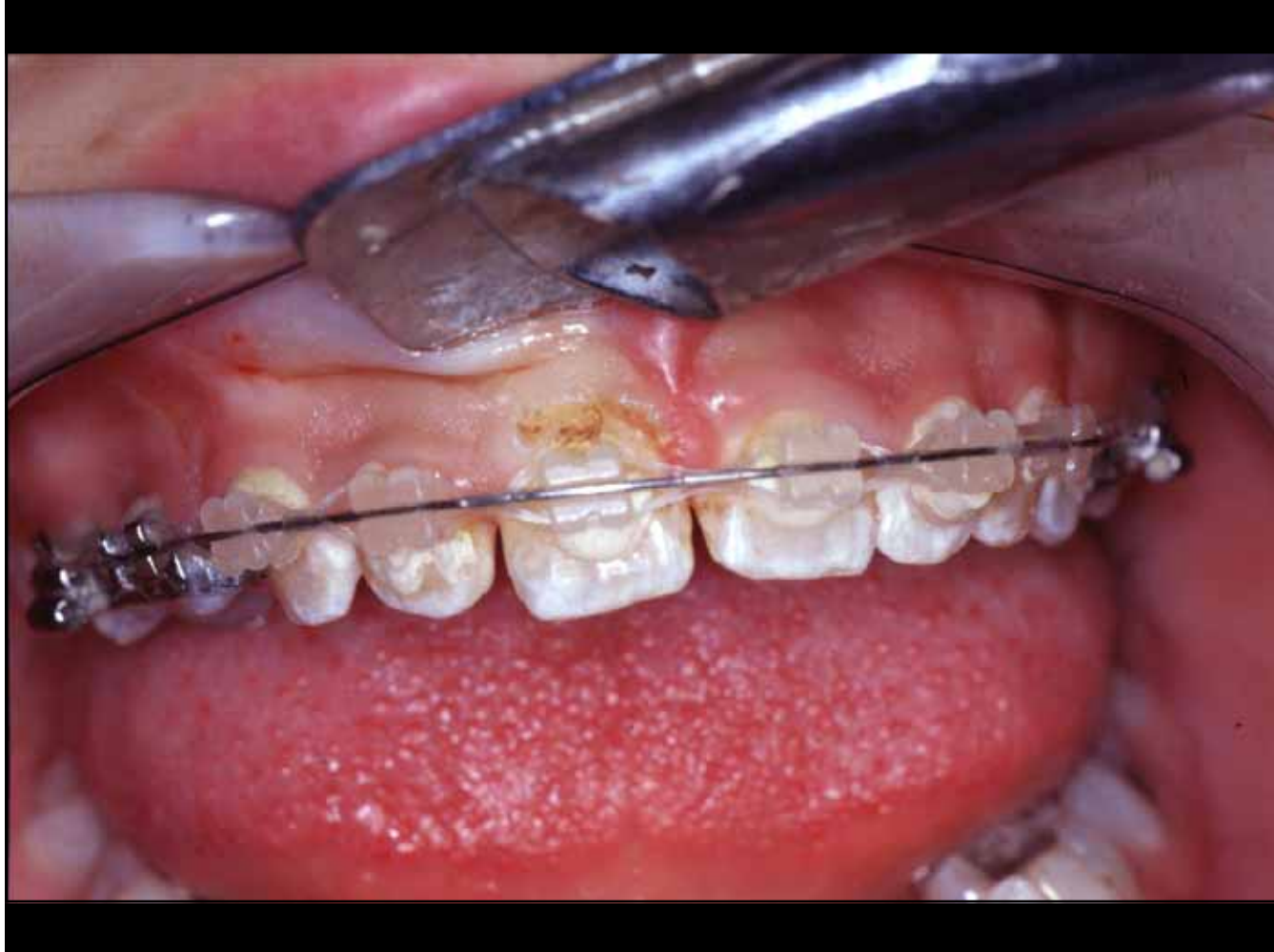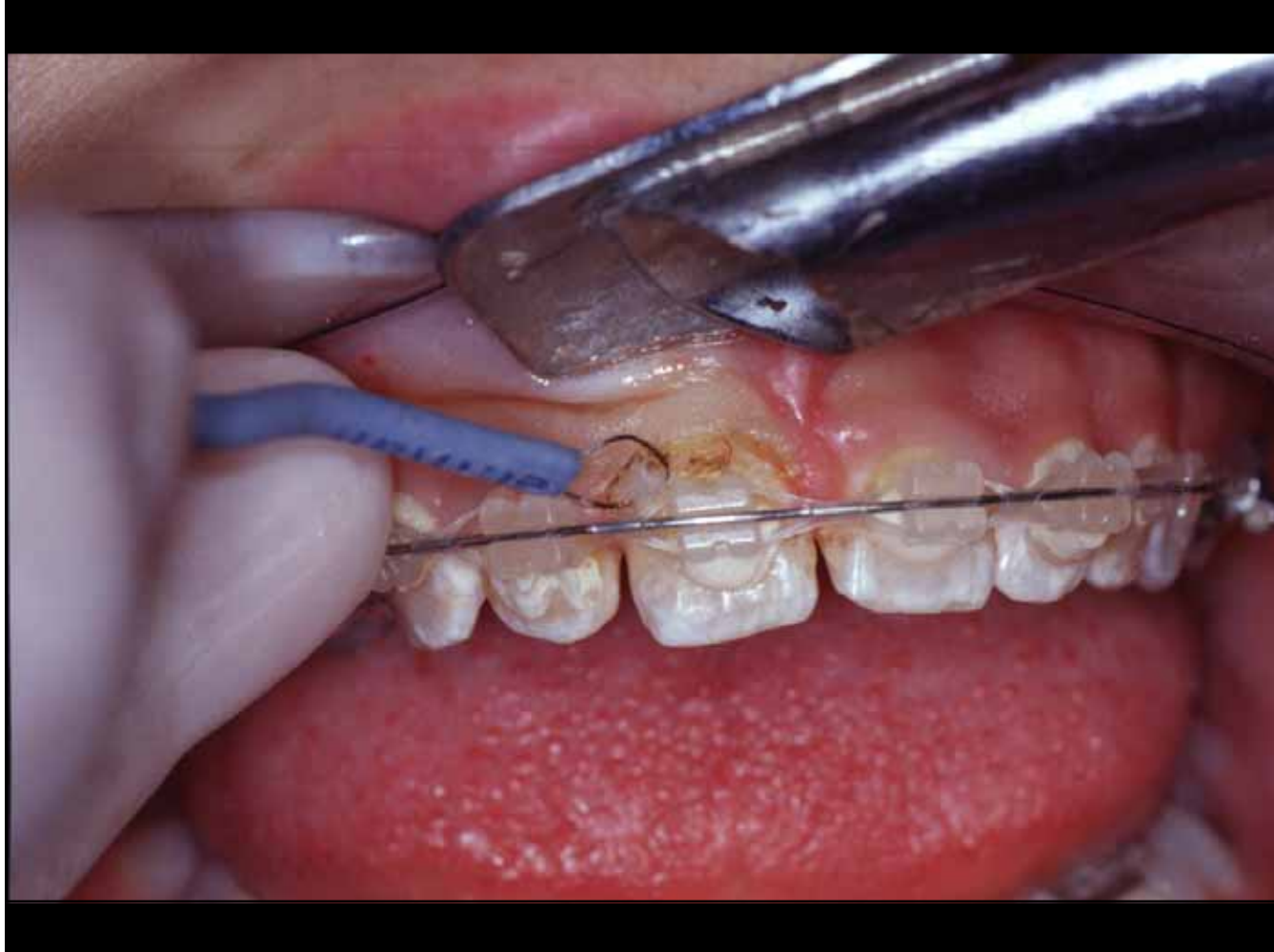11 Months Later 220703  
Crown Lengthening Procedure  
using Electrosurgery

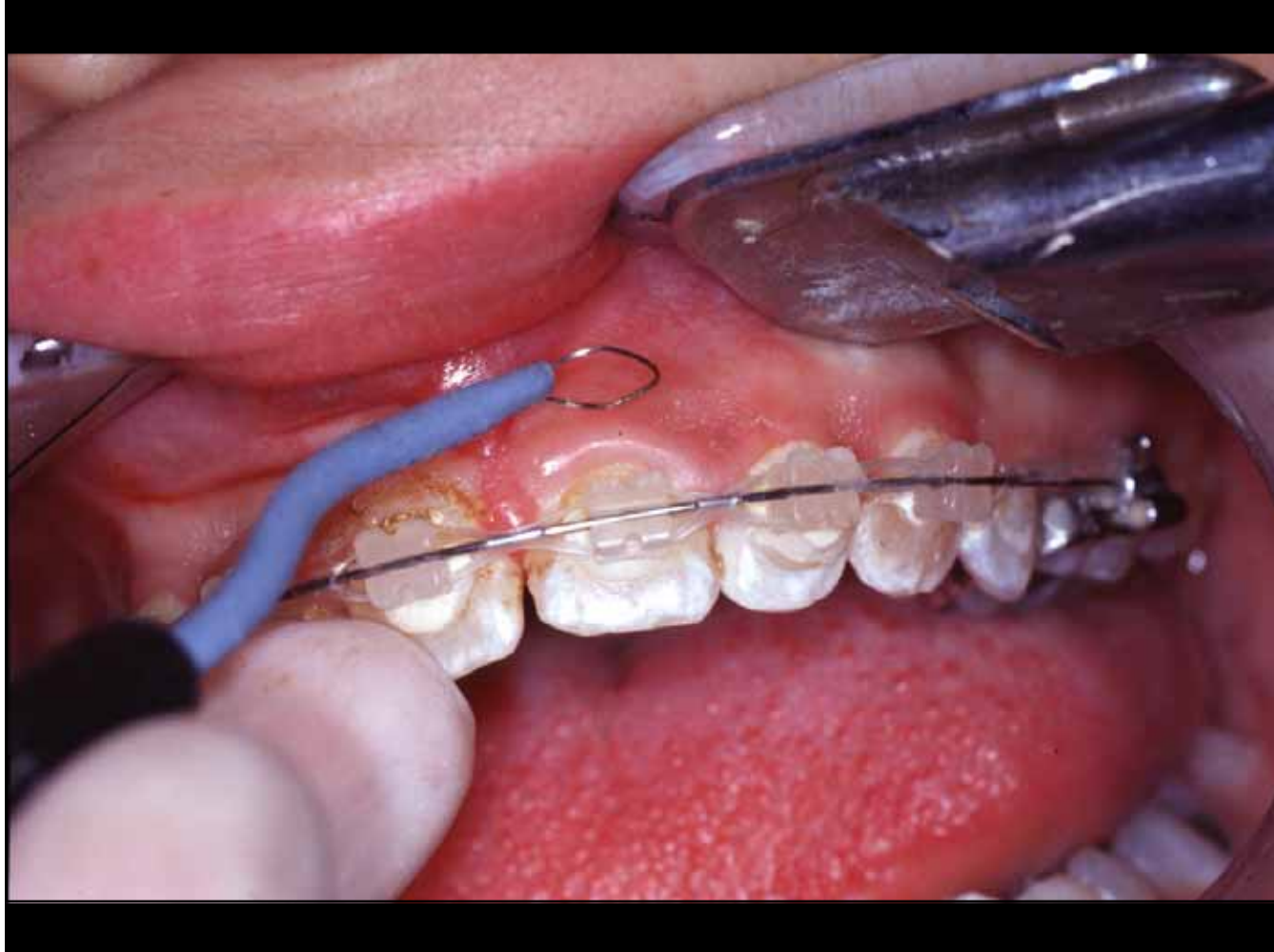

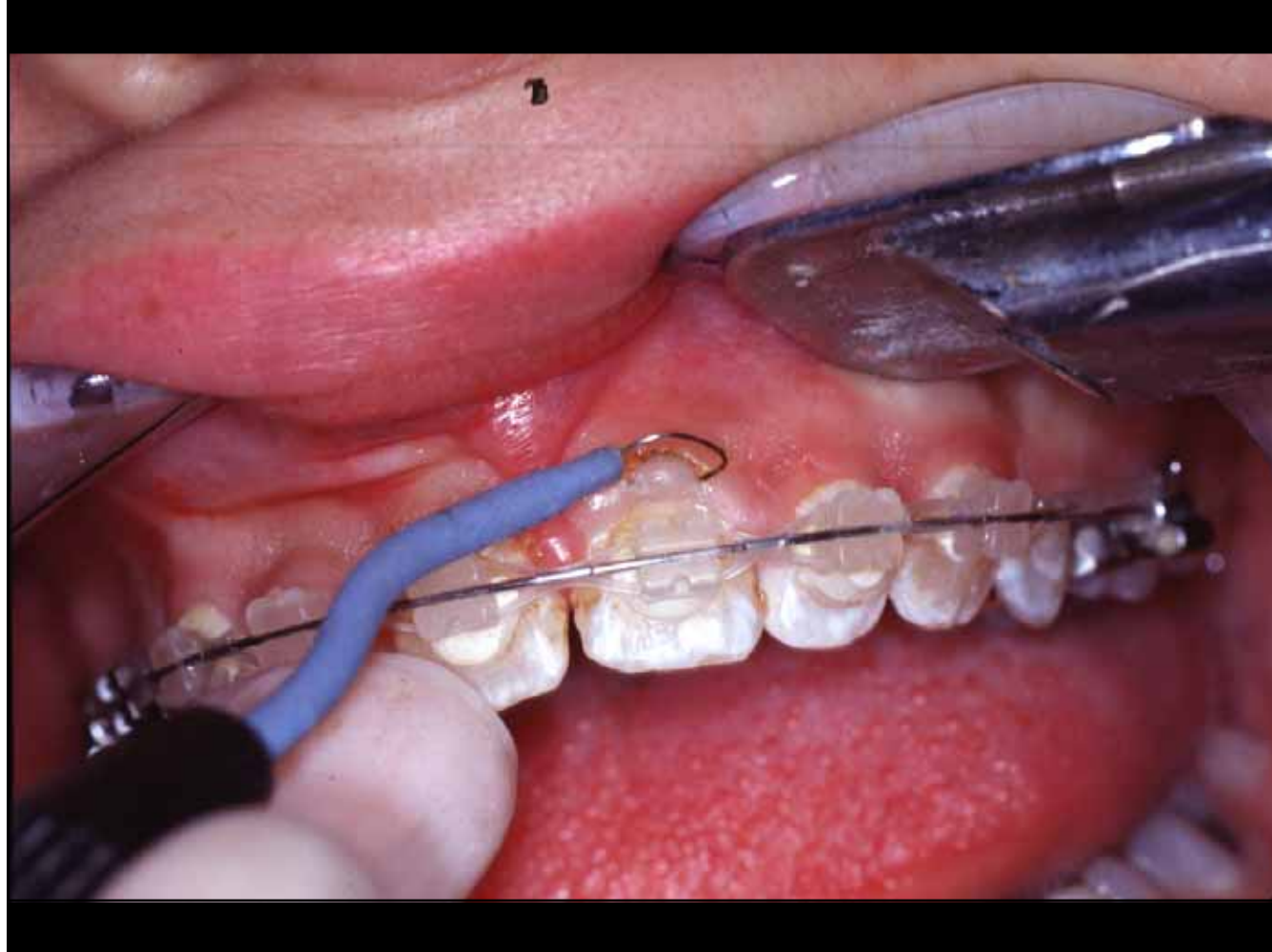



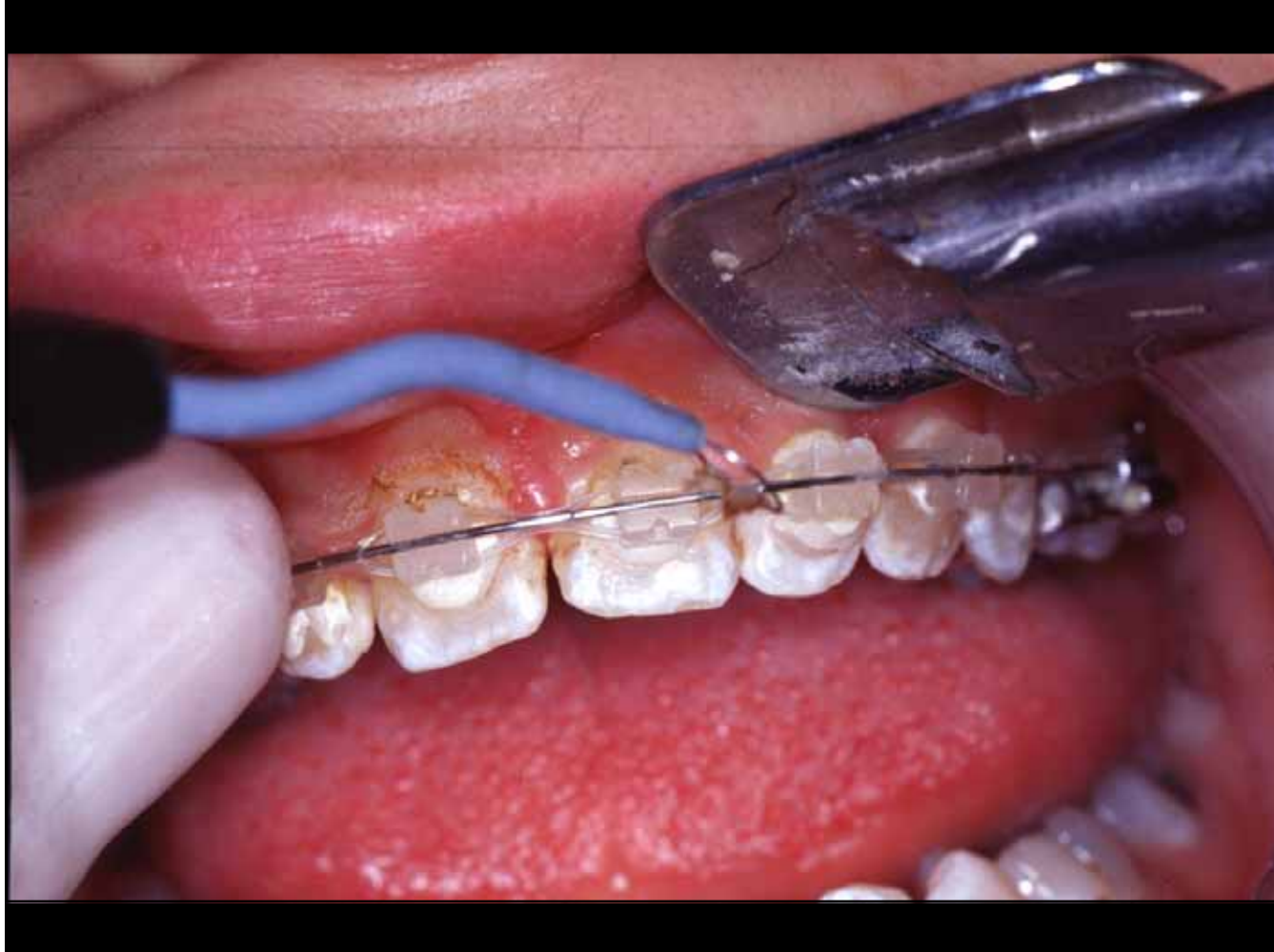


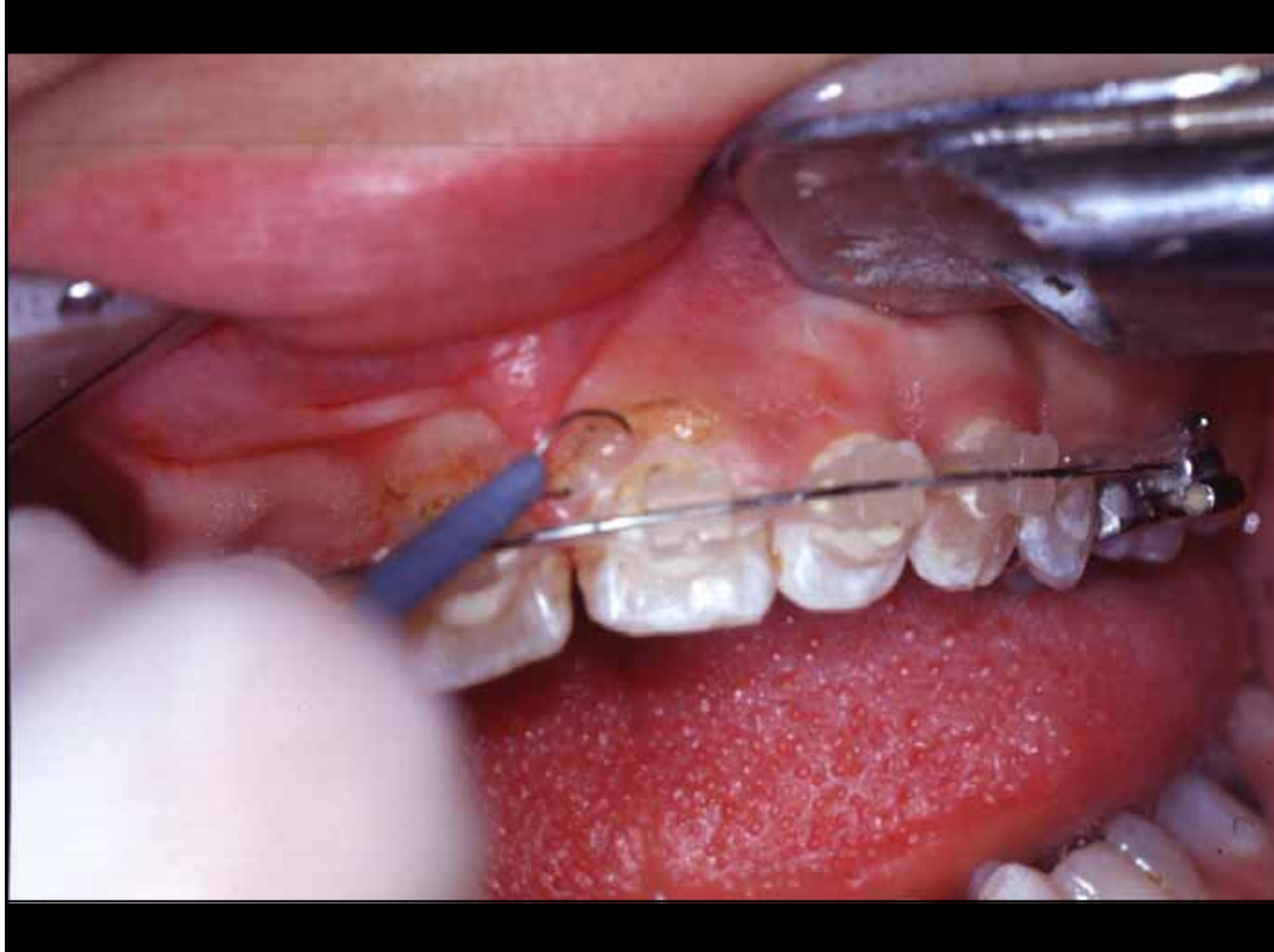


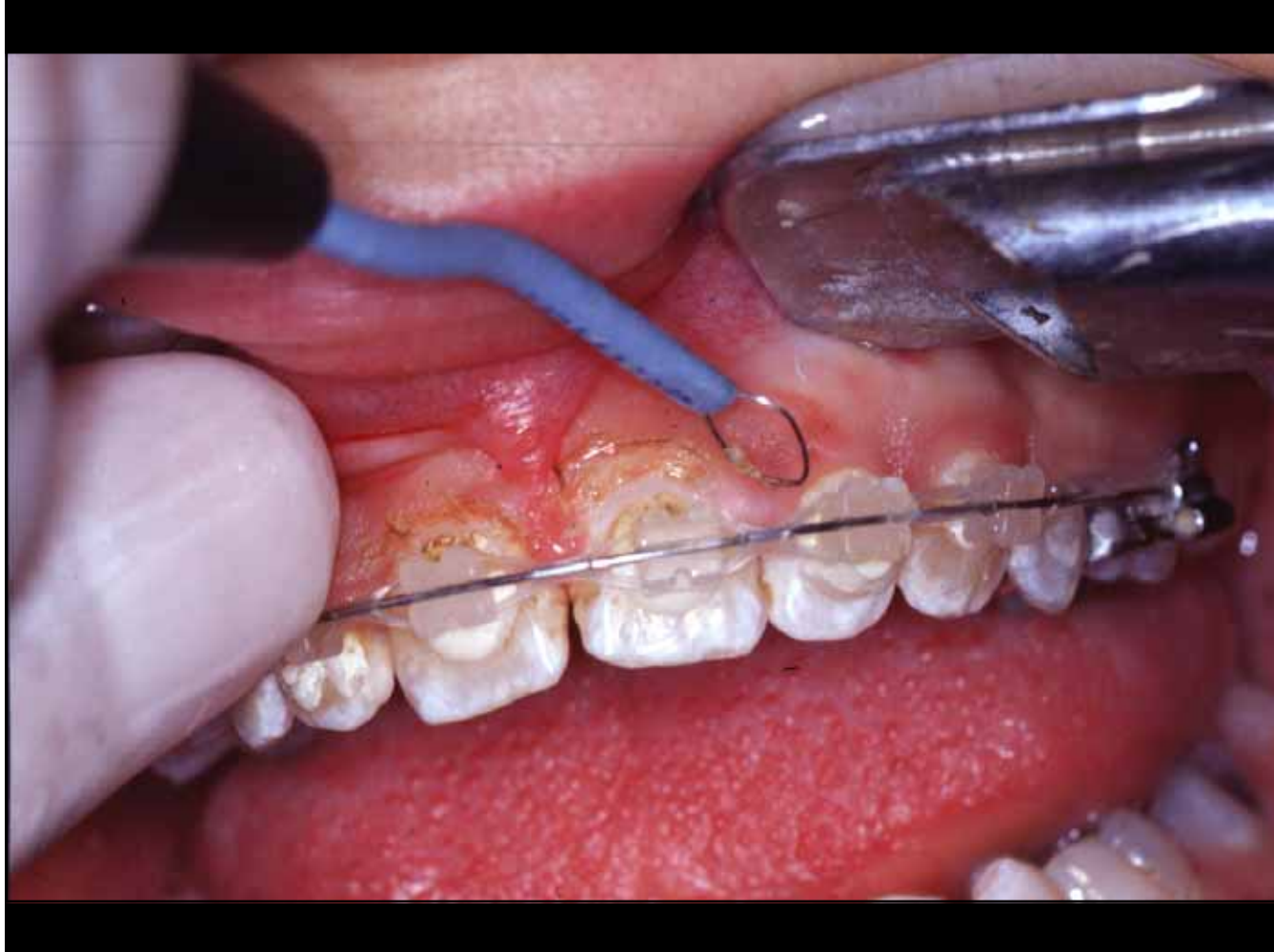


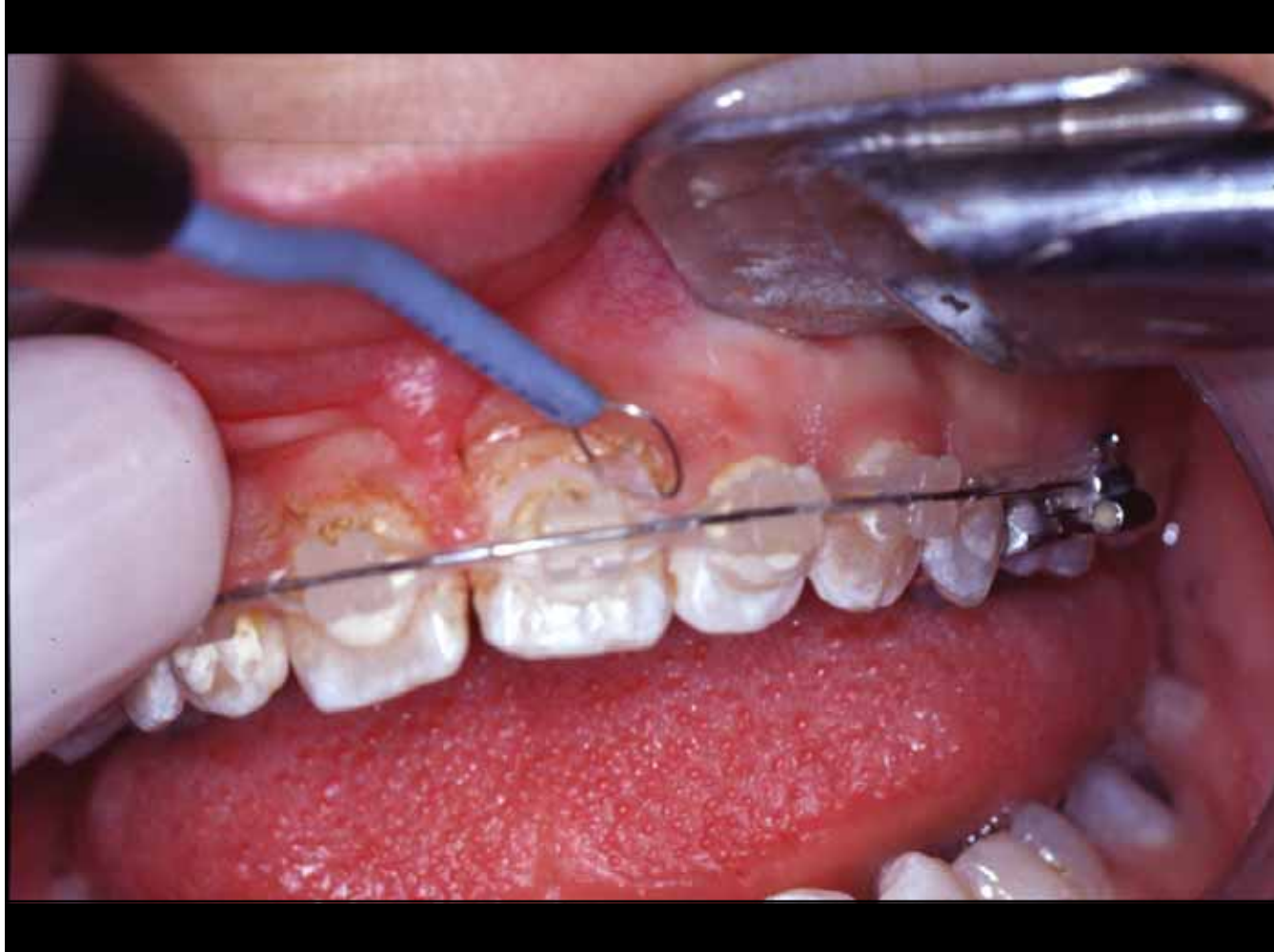


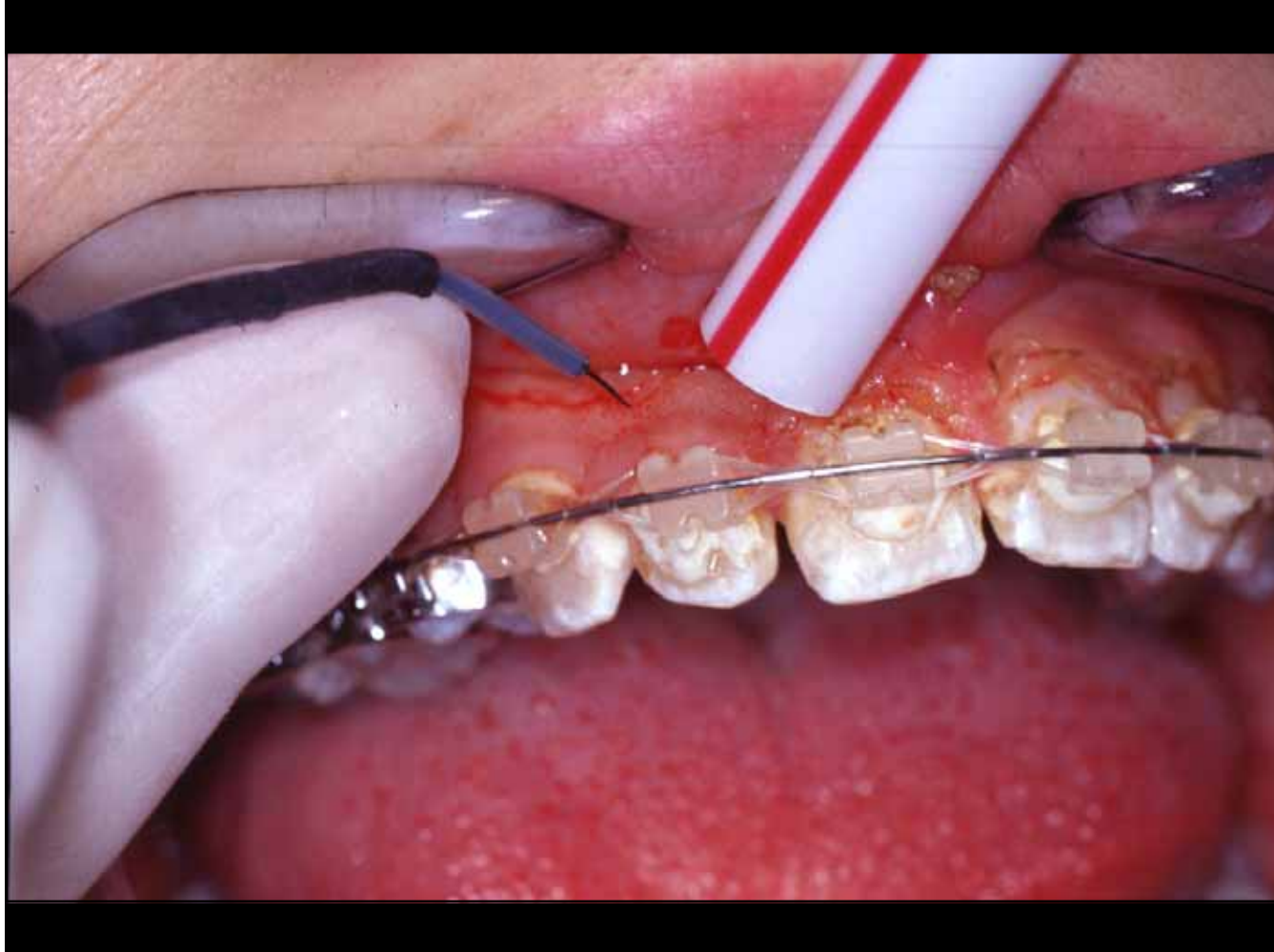
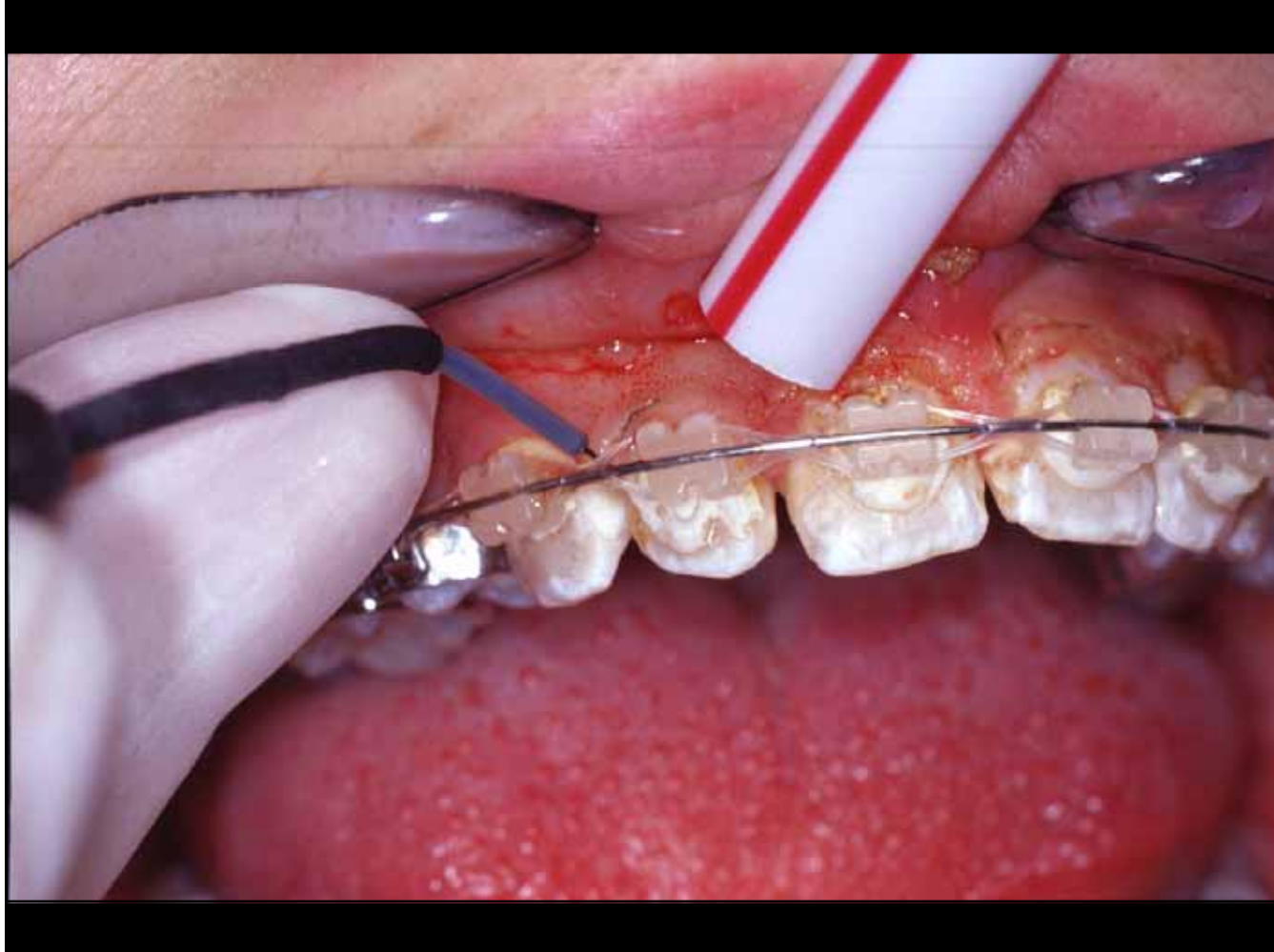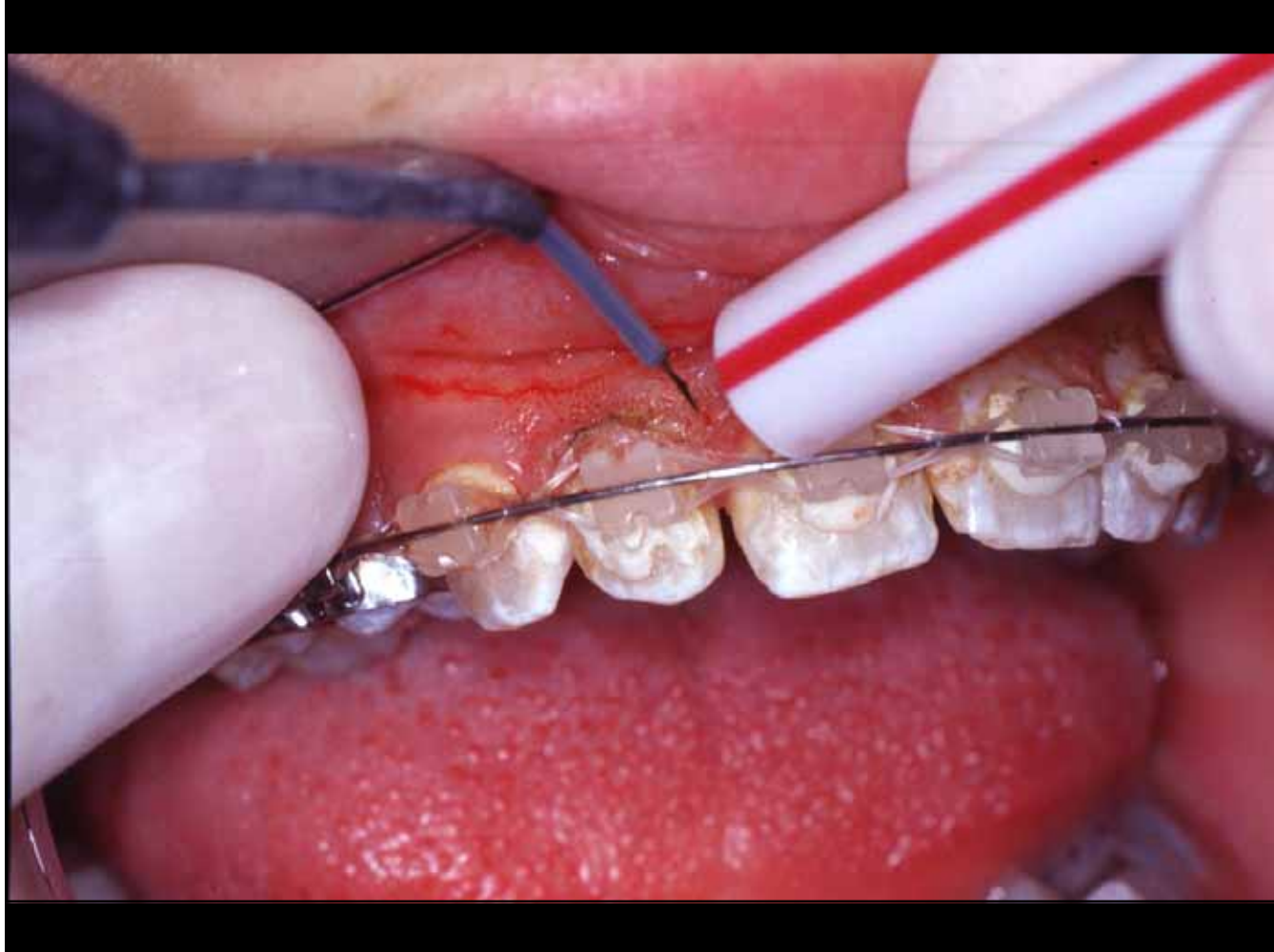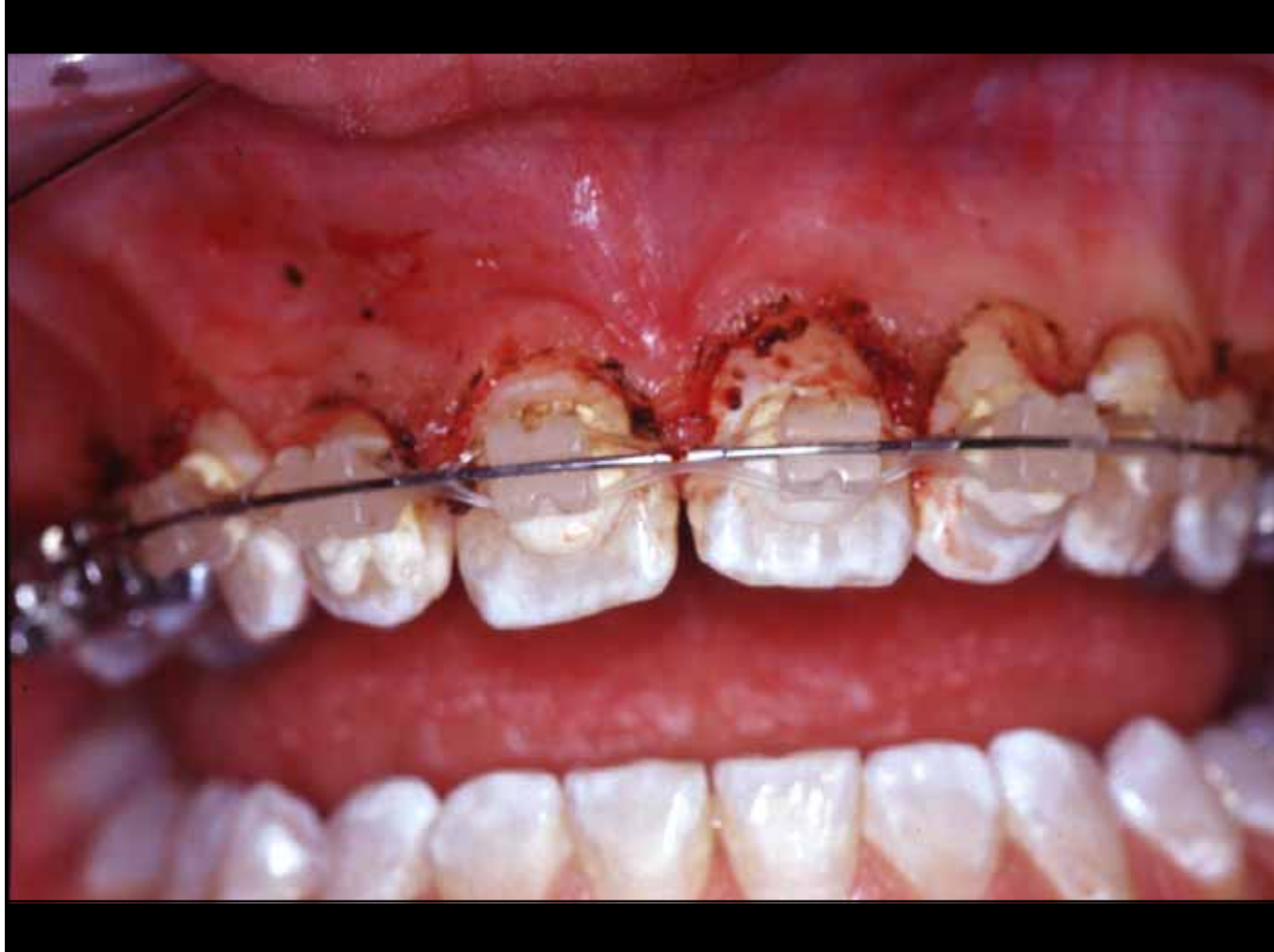










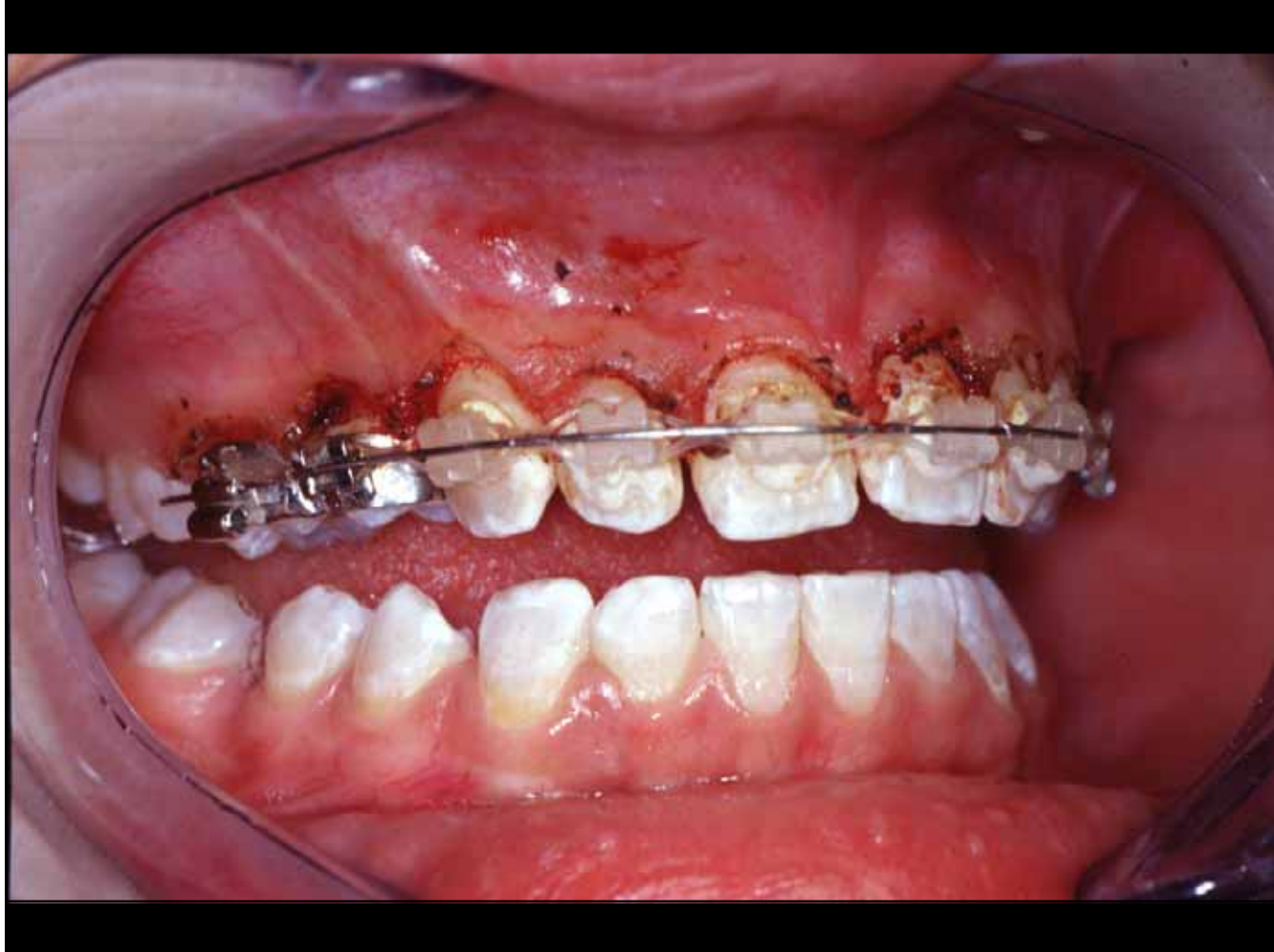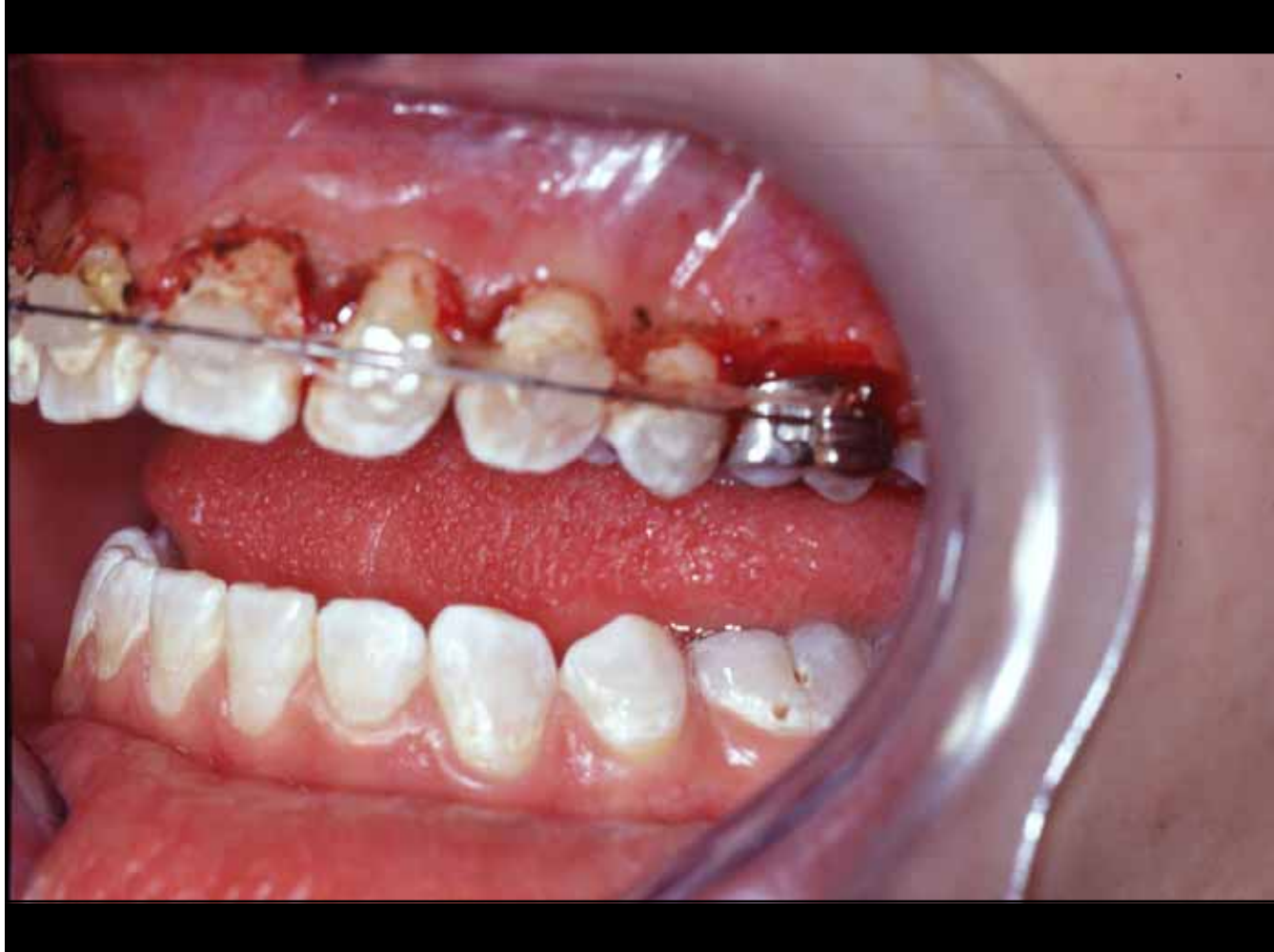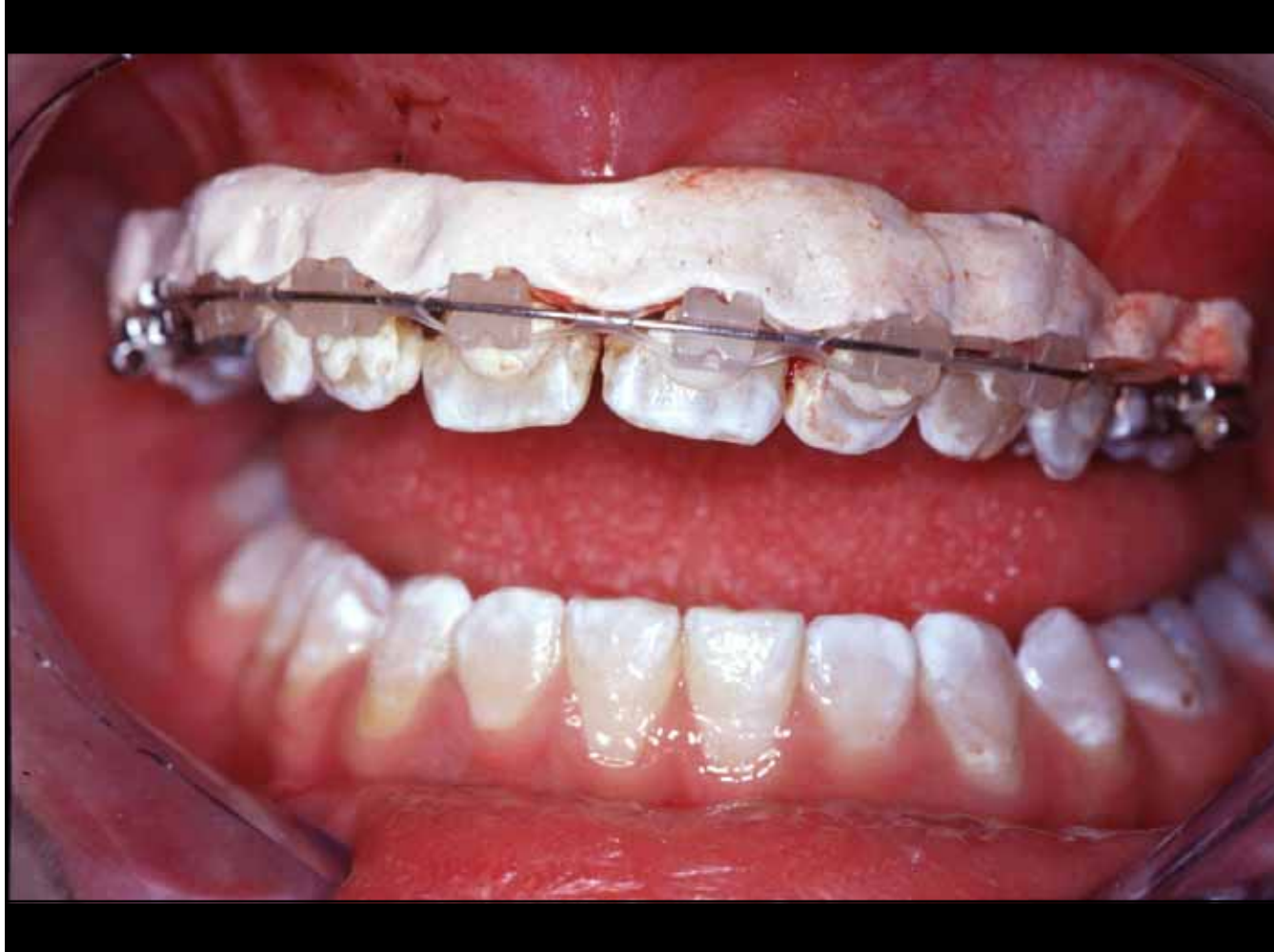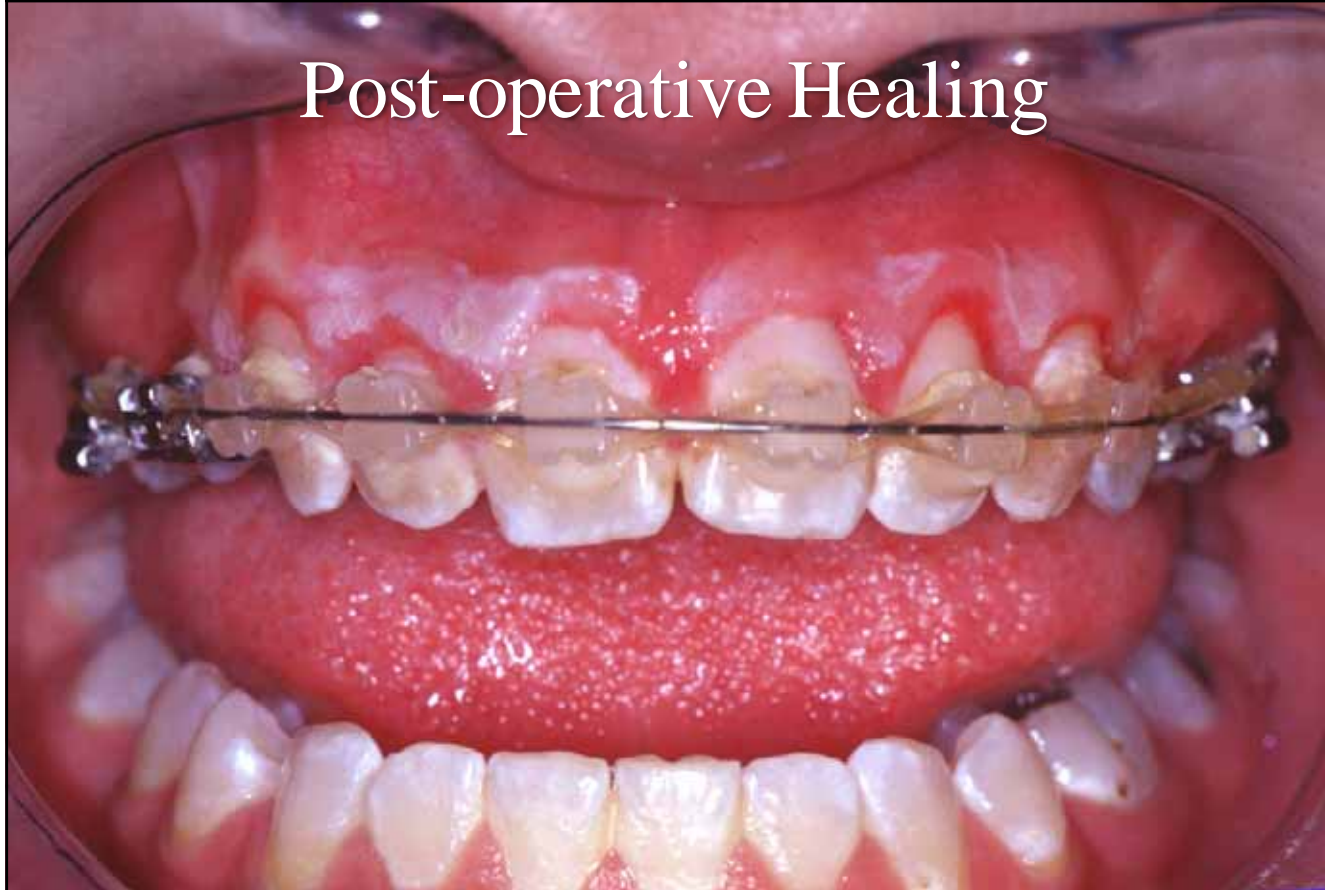








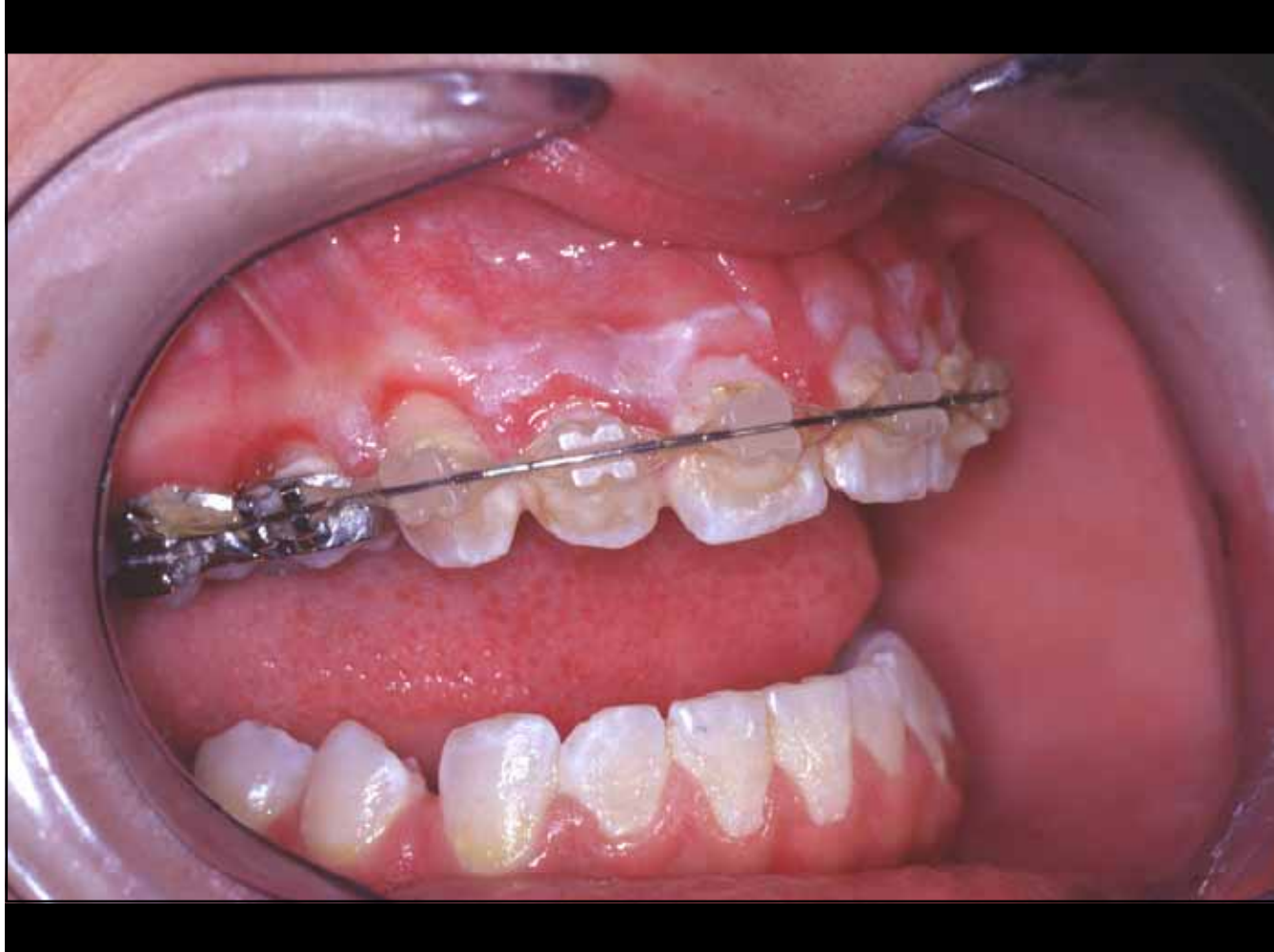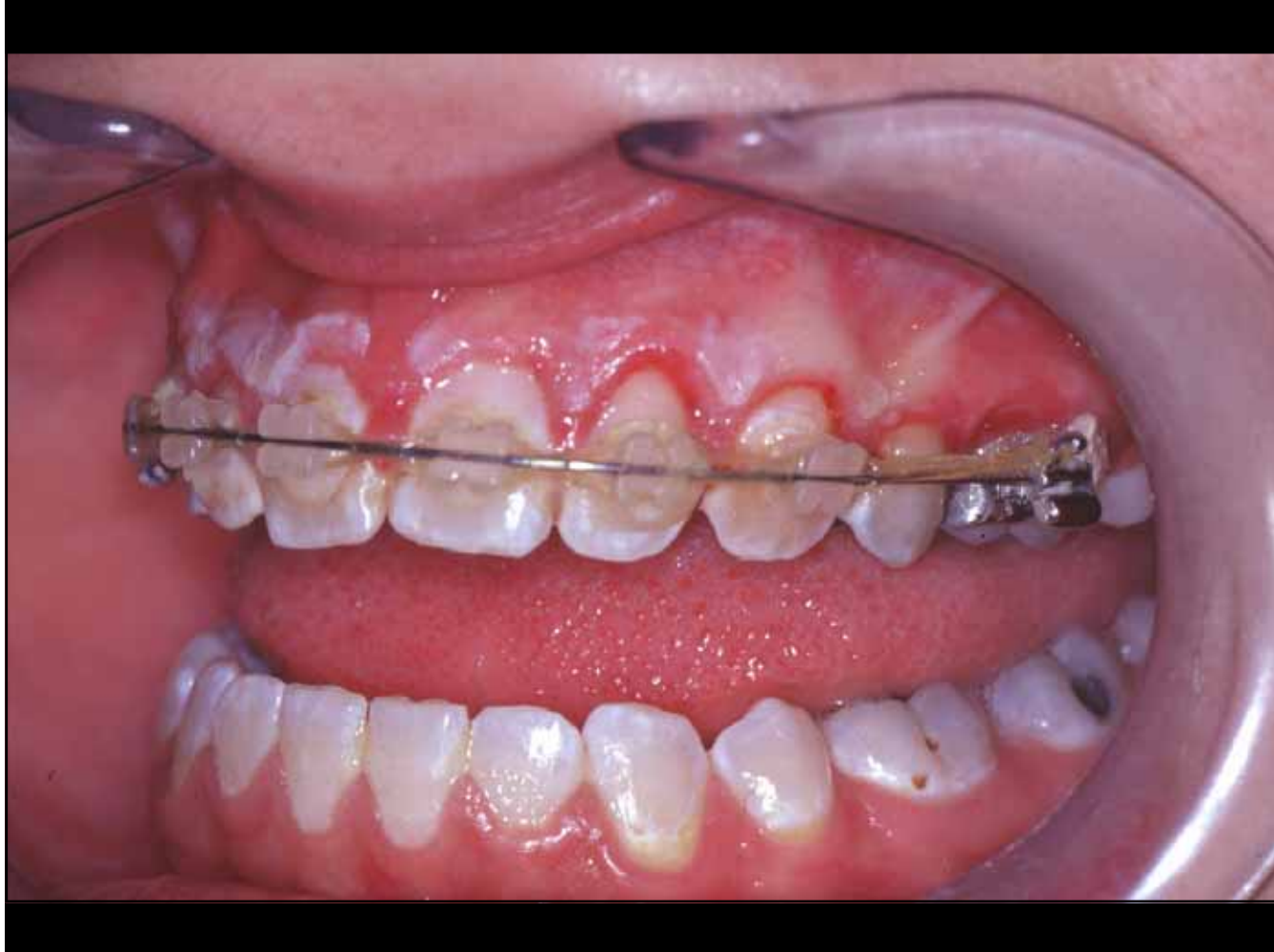# Post-operative Healing

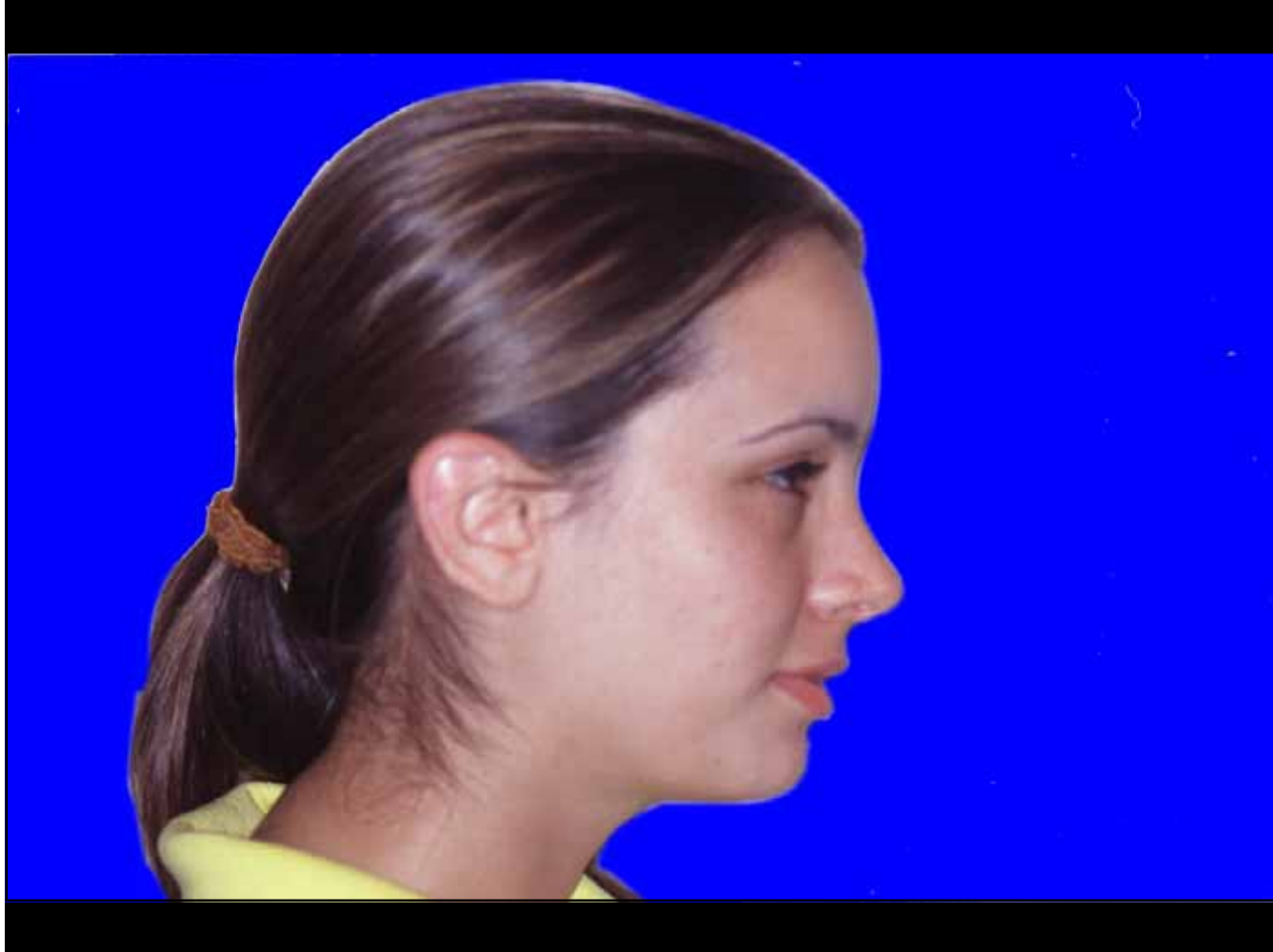


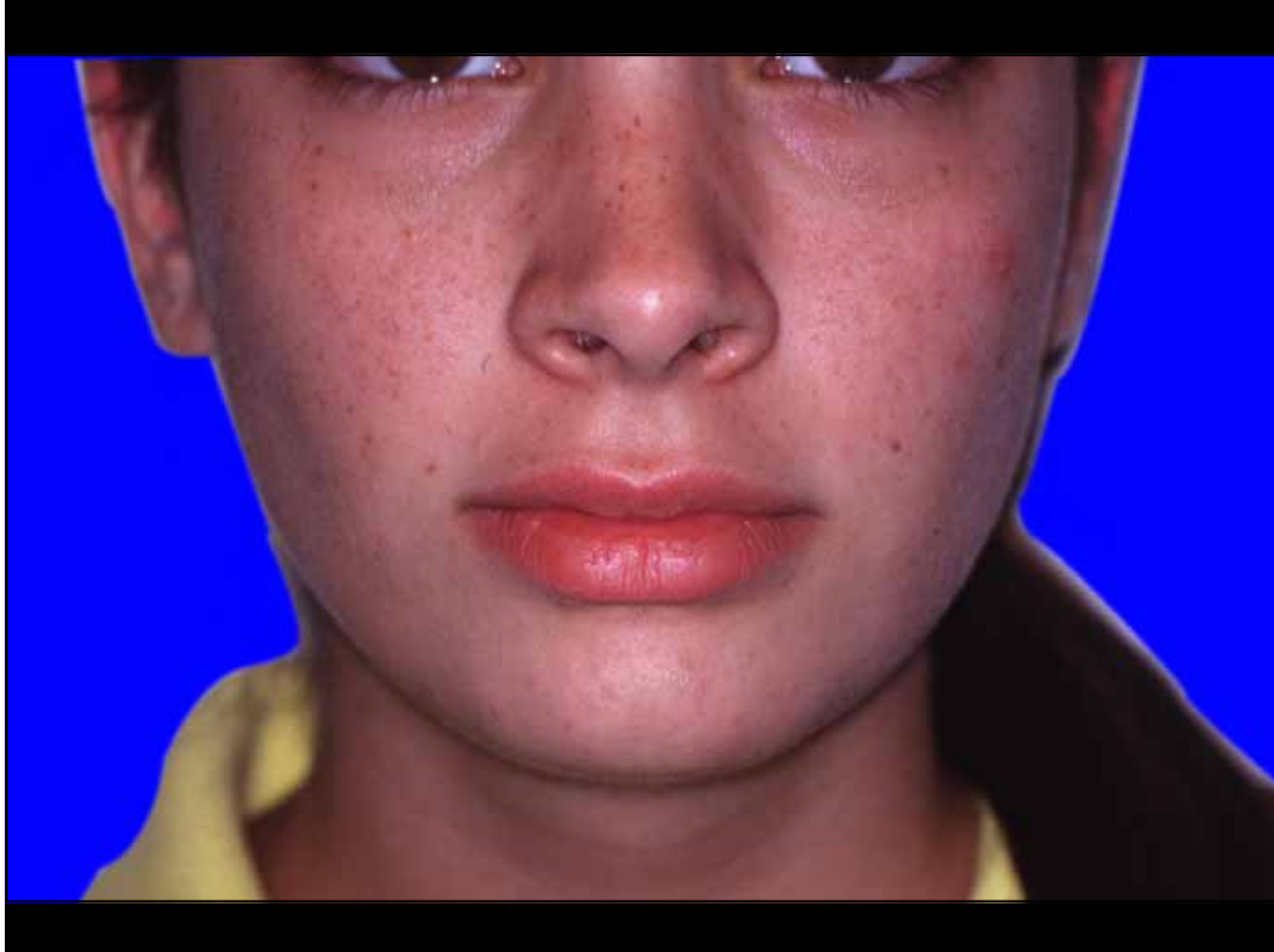


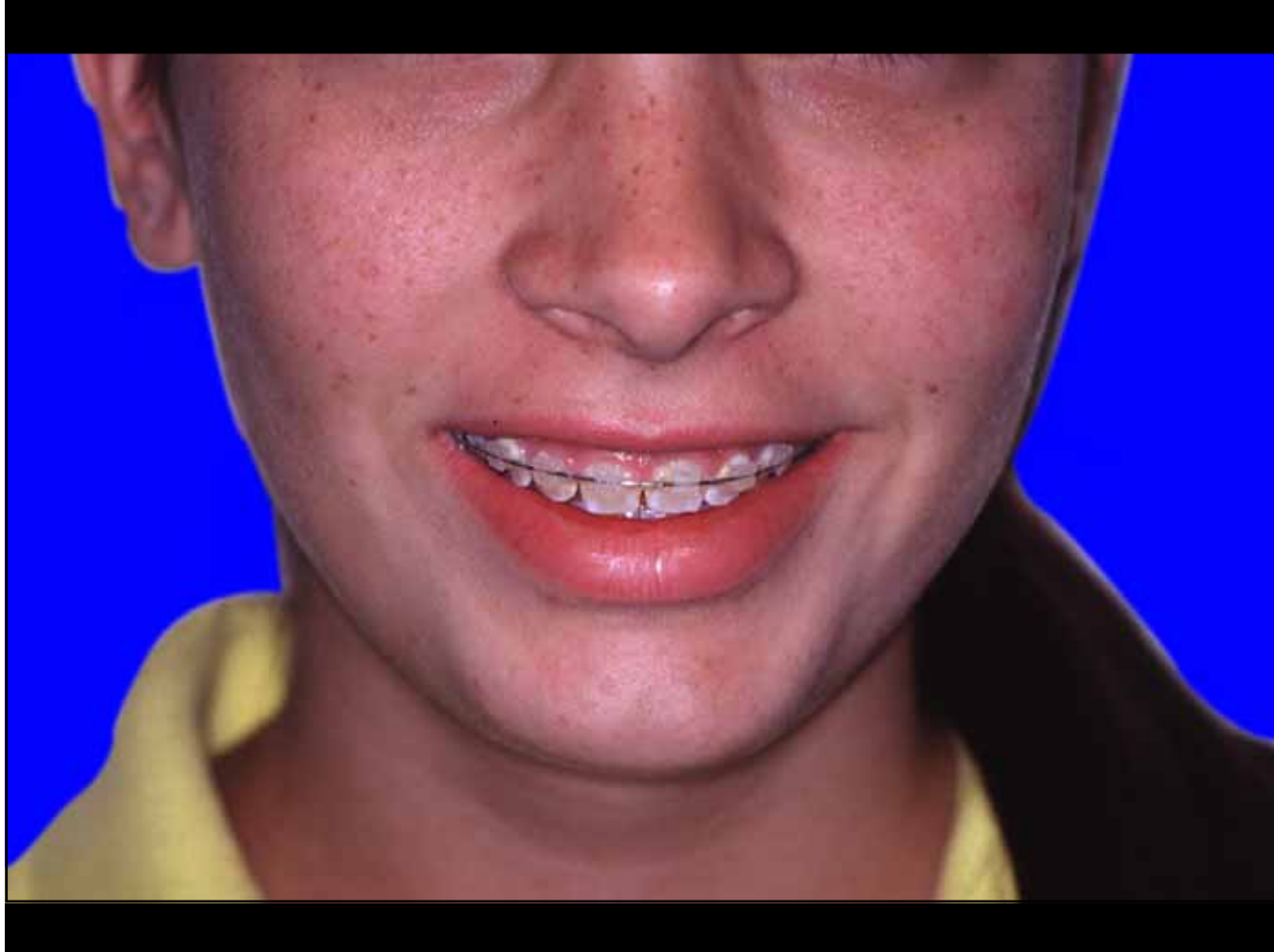
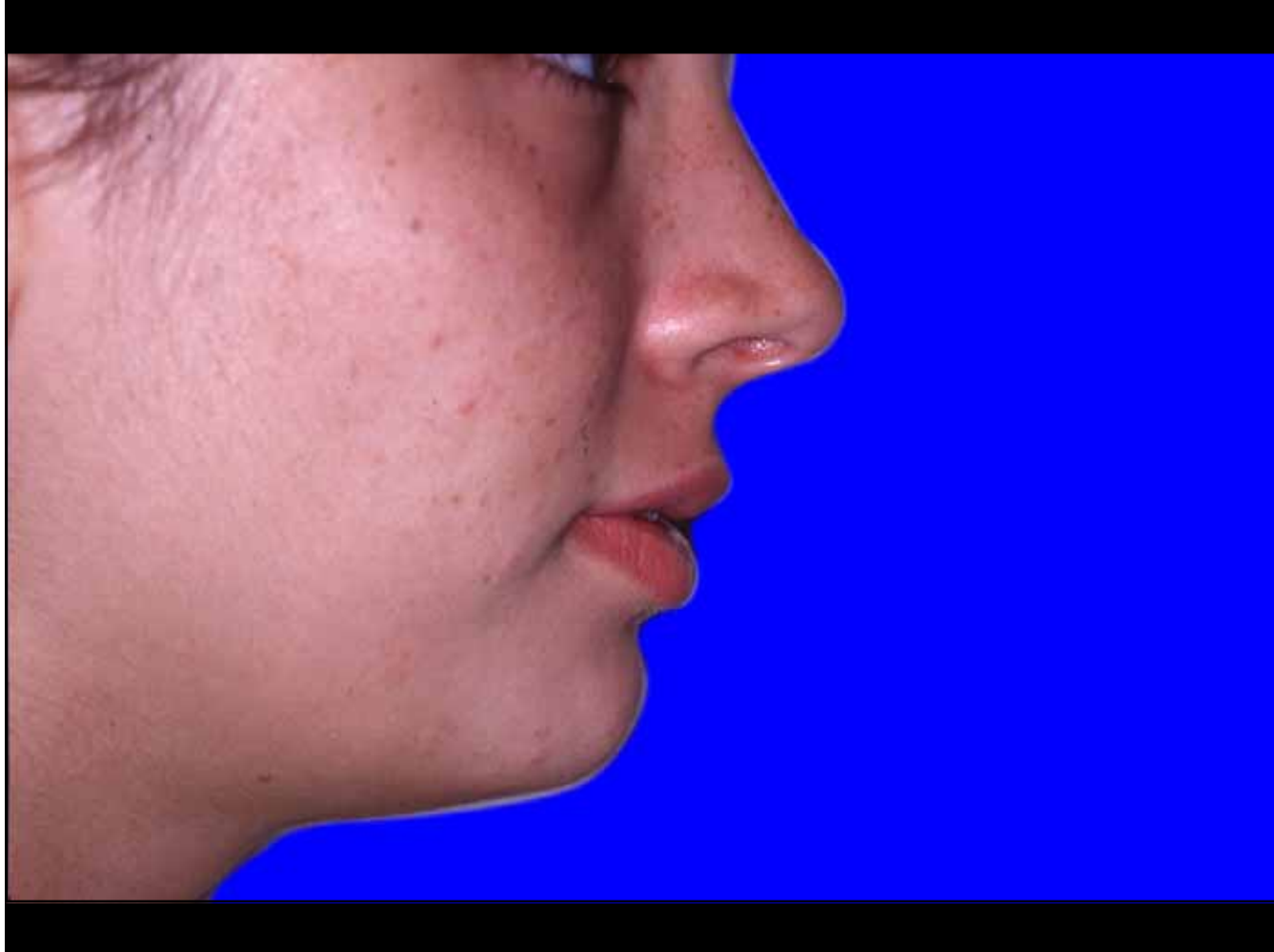# Pre-Veneer Photos

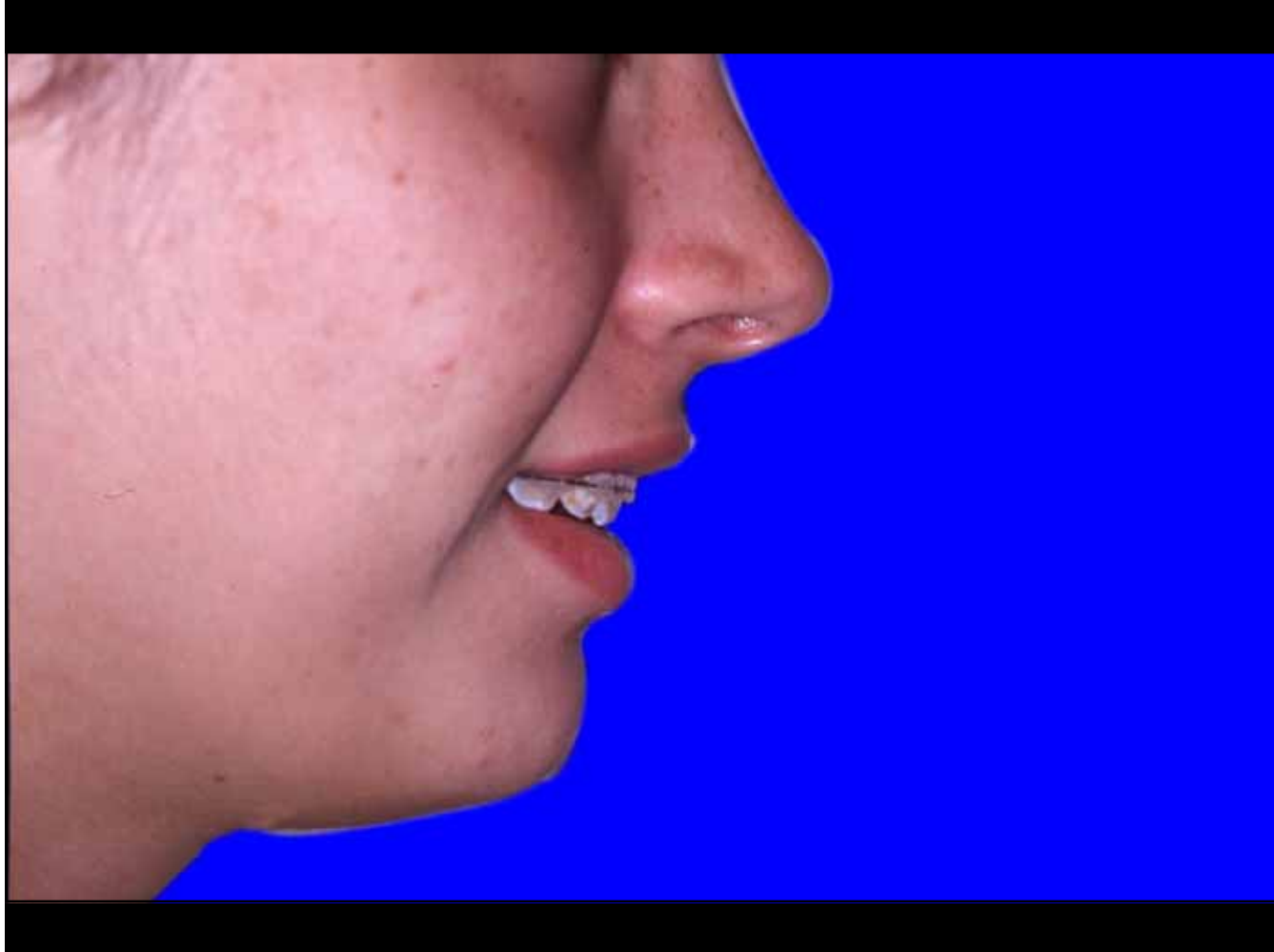




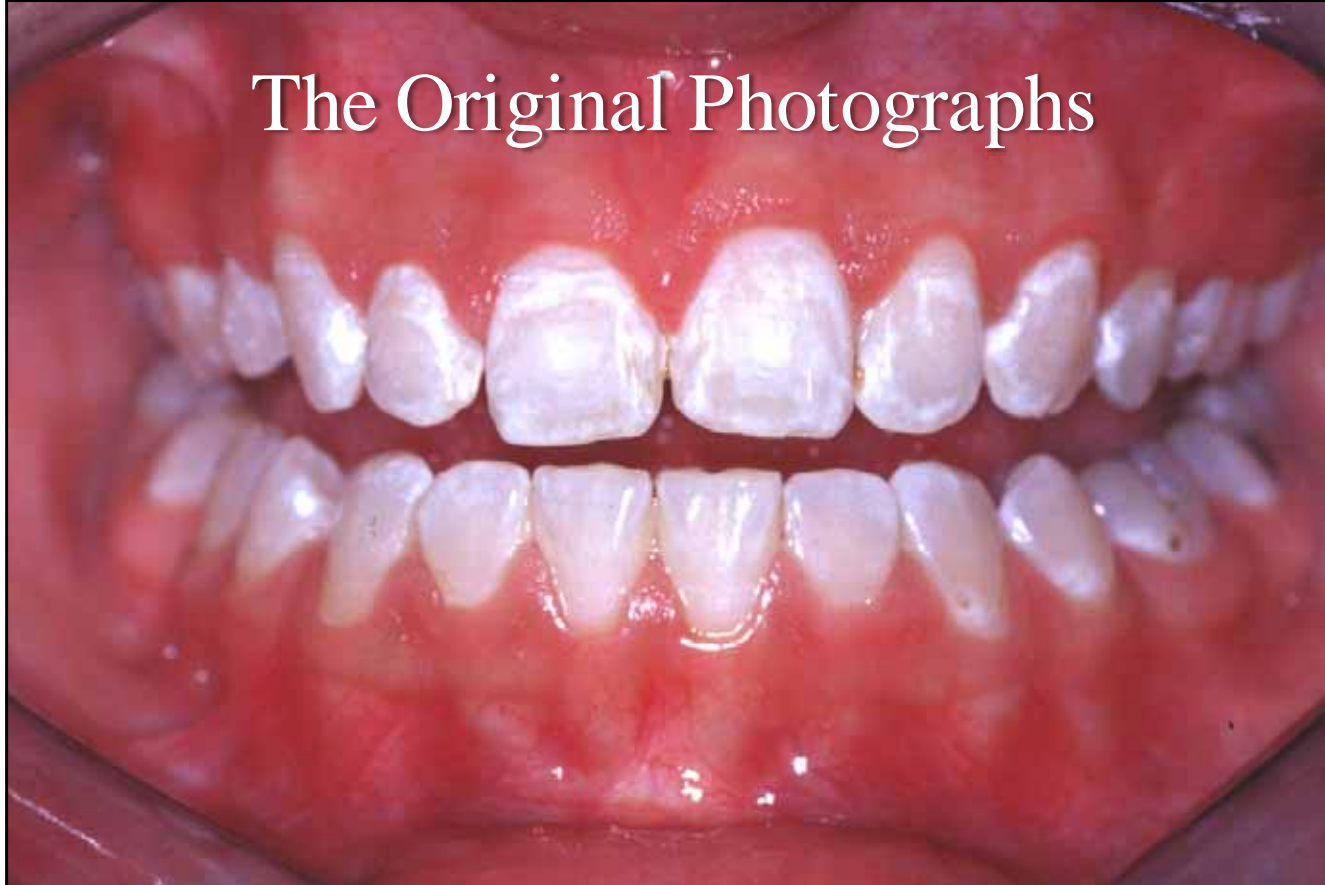


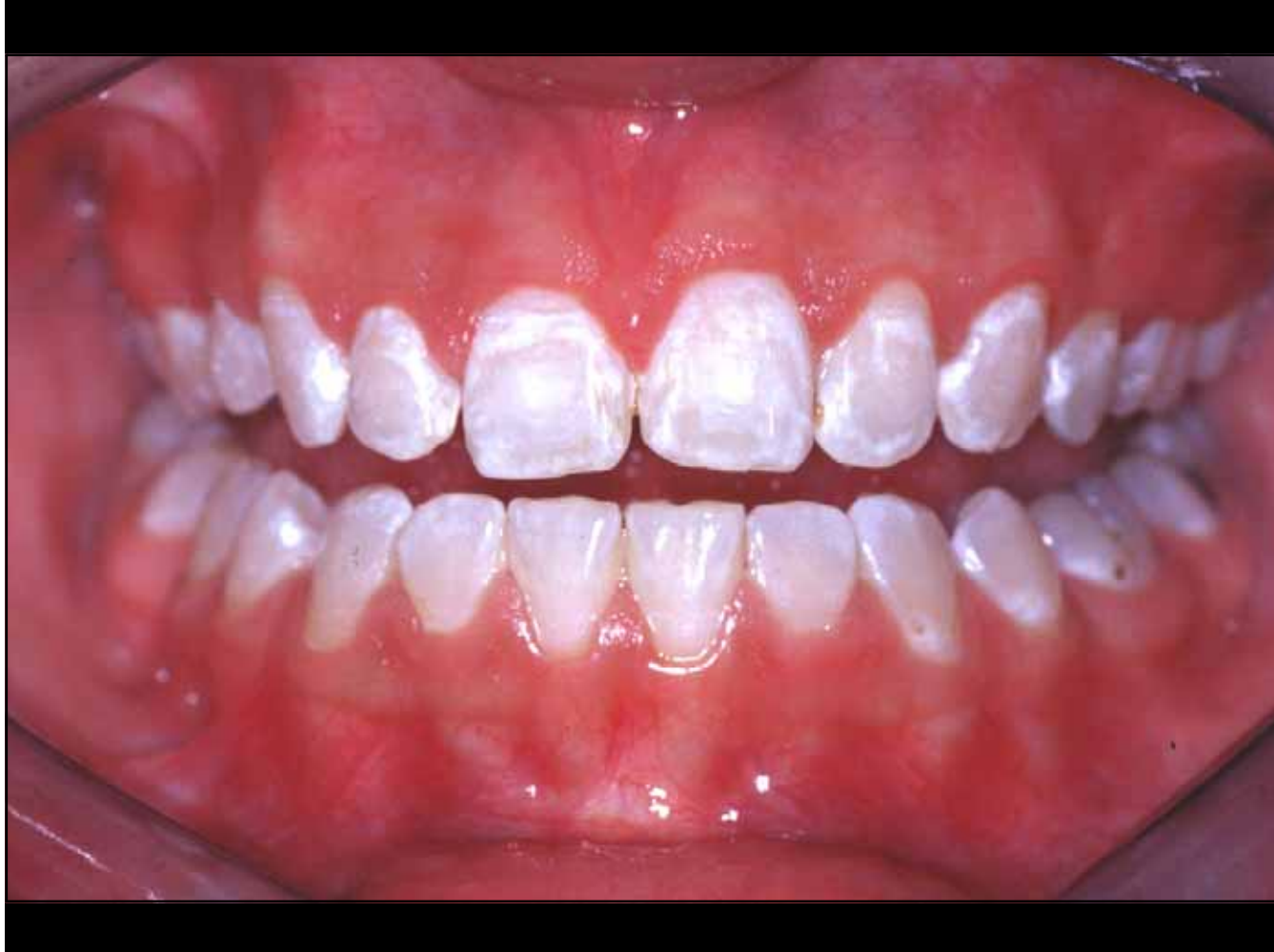





The Original Photographs

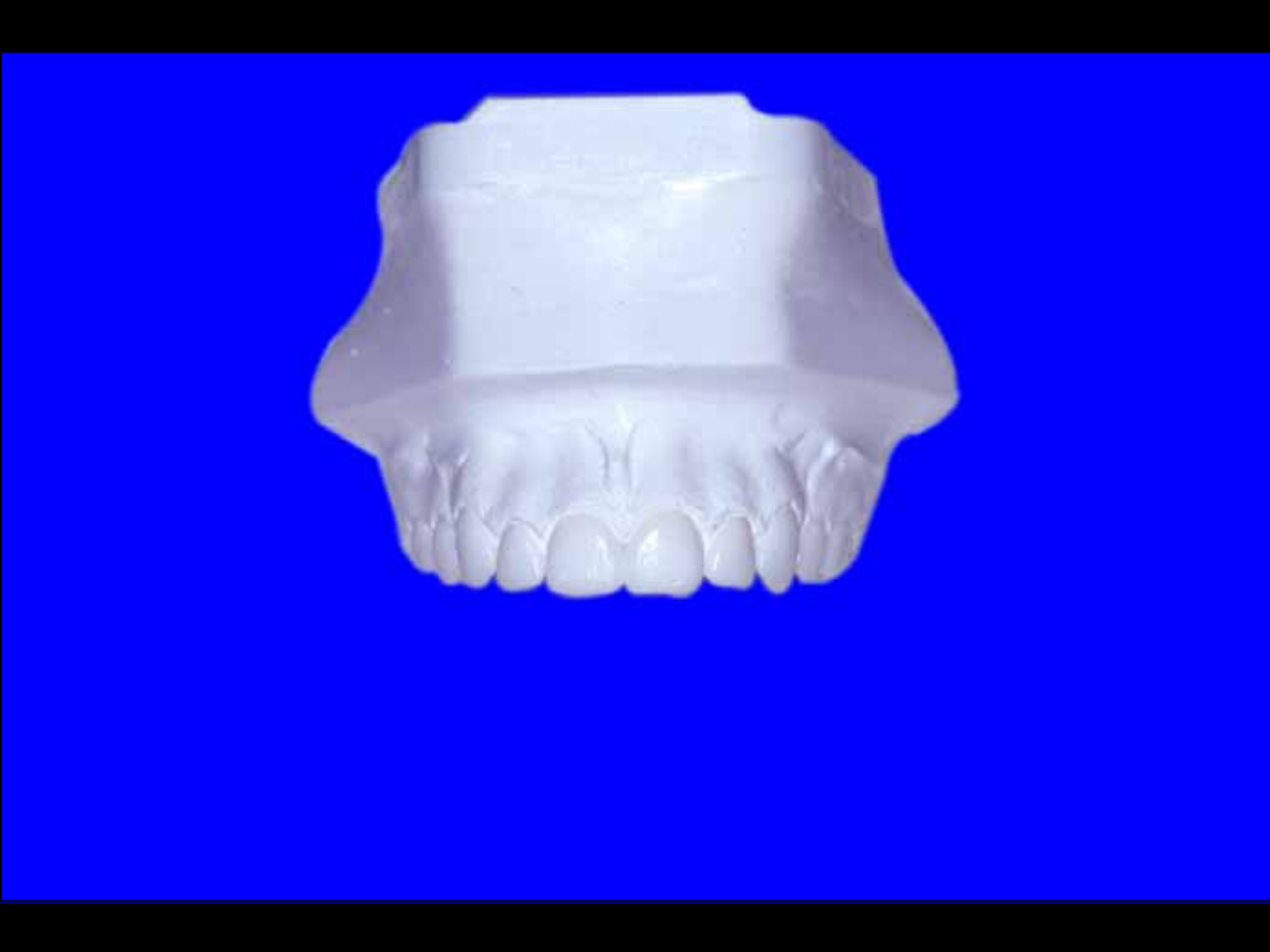


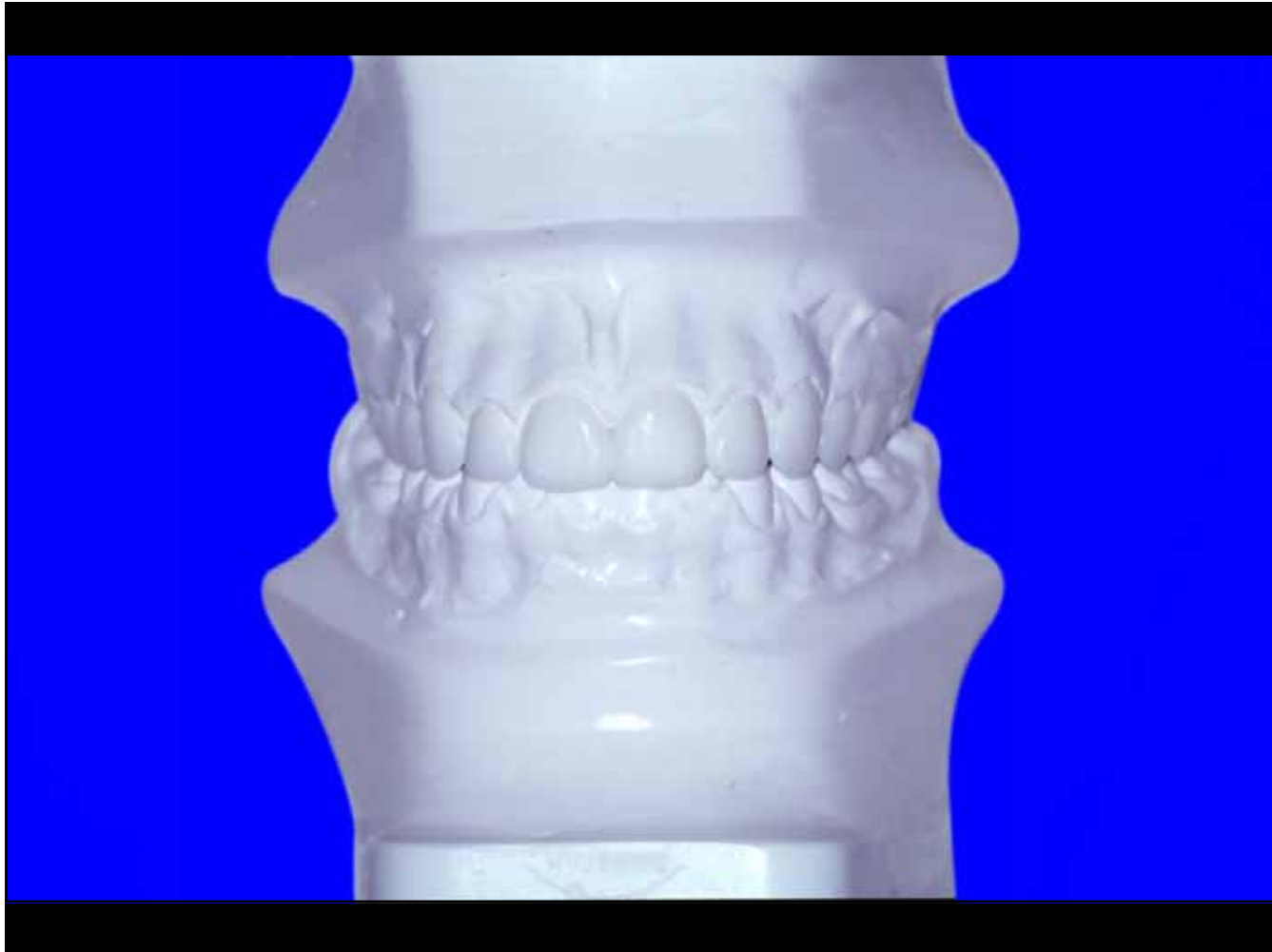


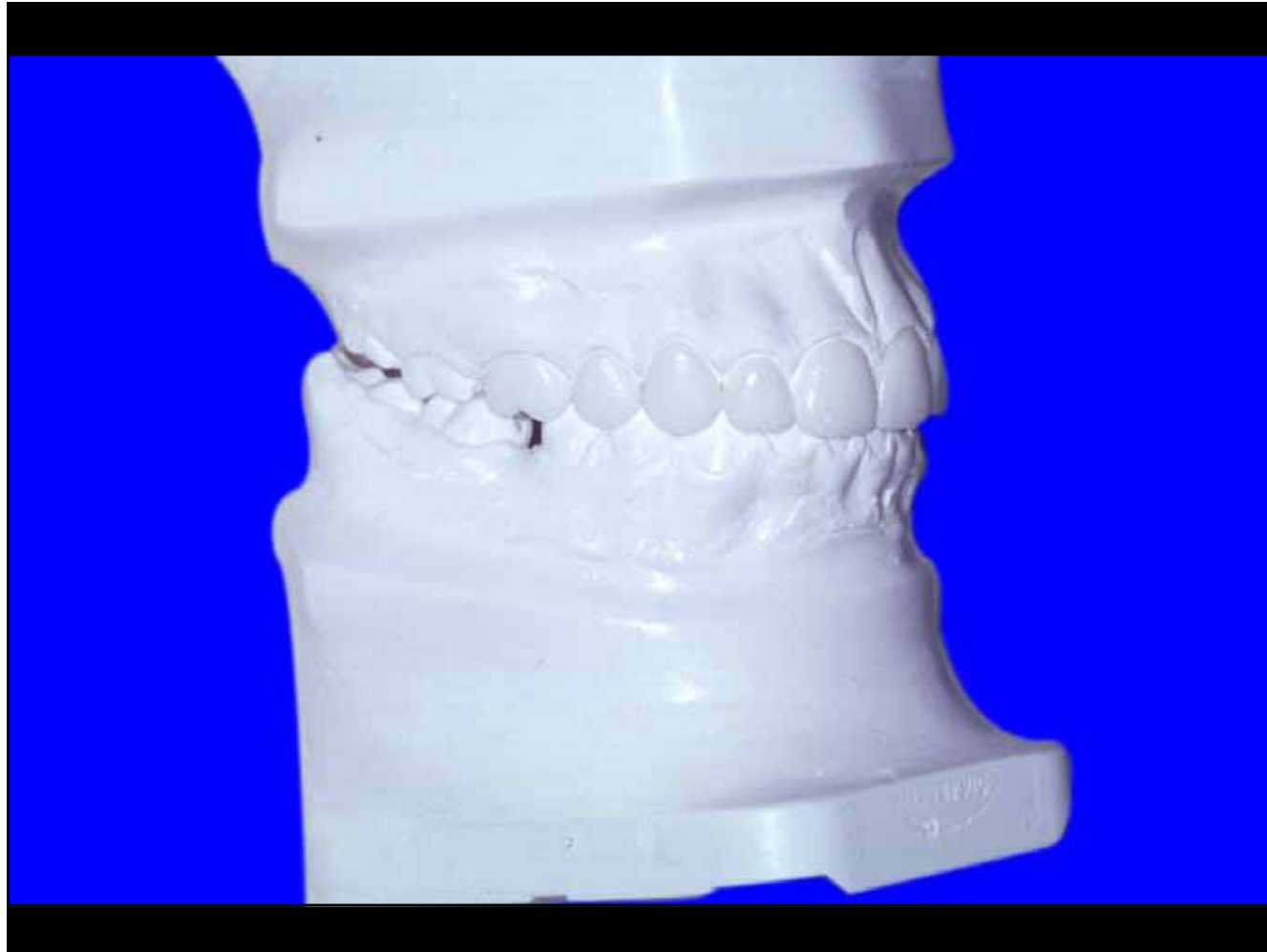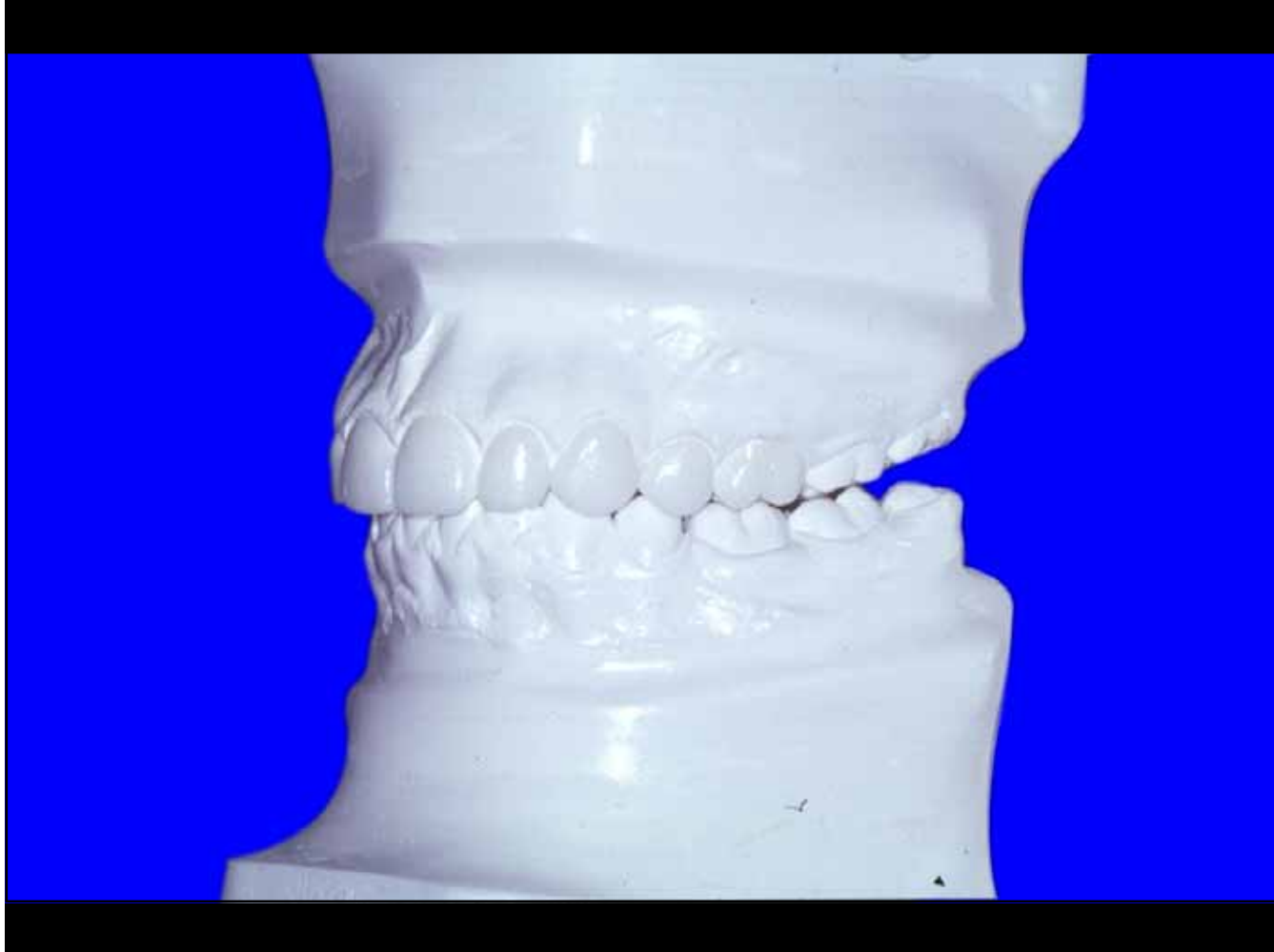


# Diagnostic Wax-ups







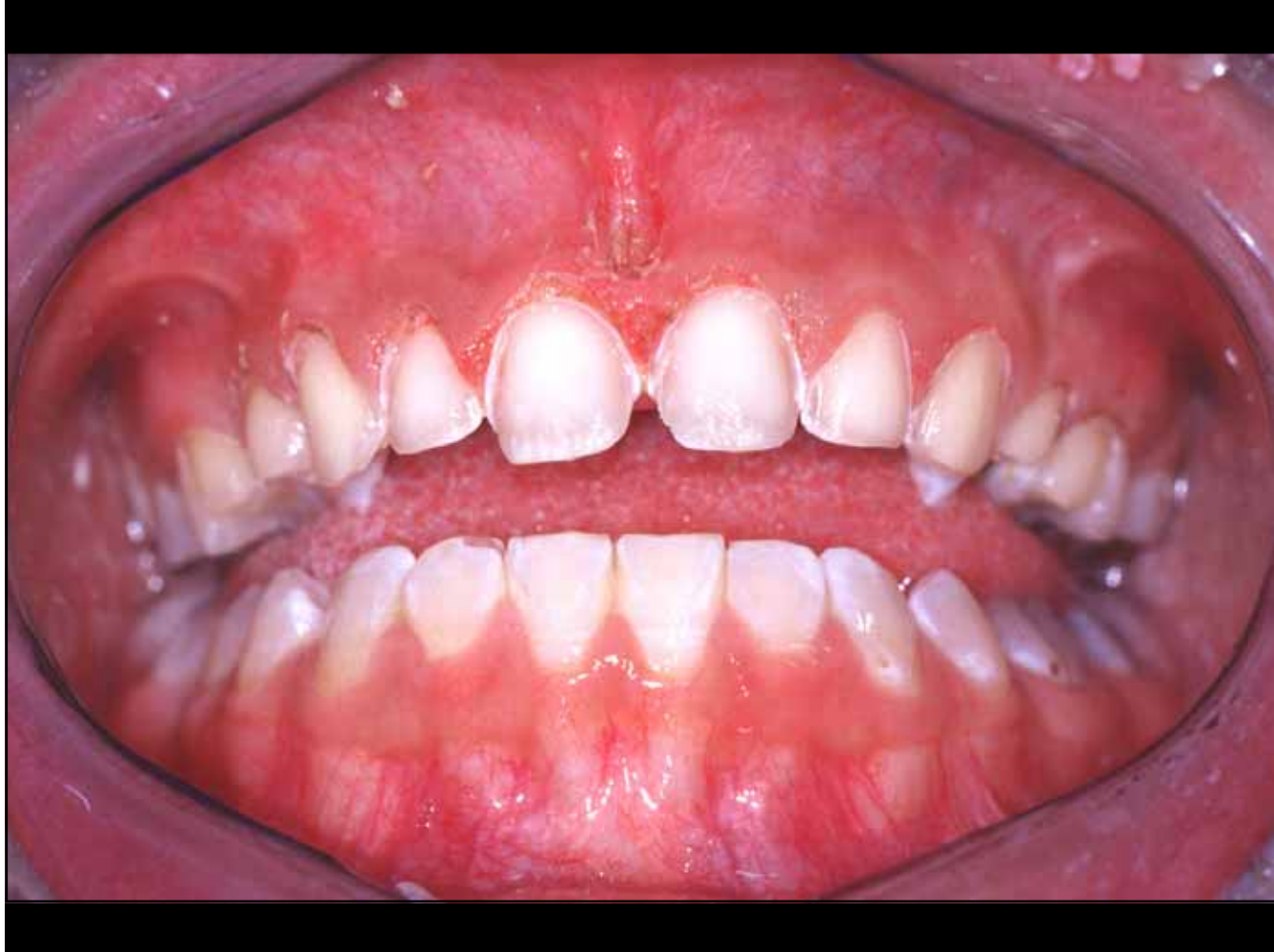

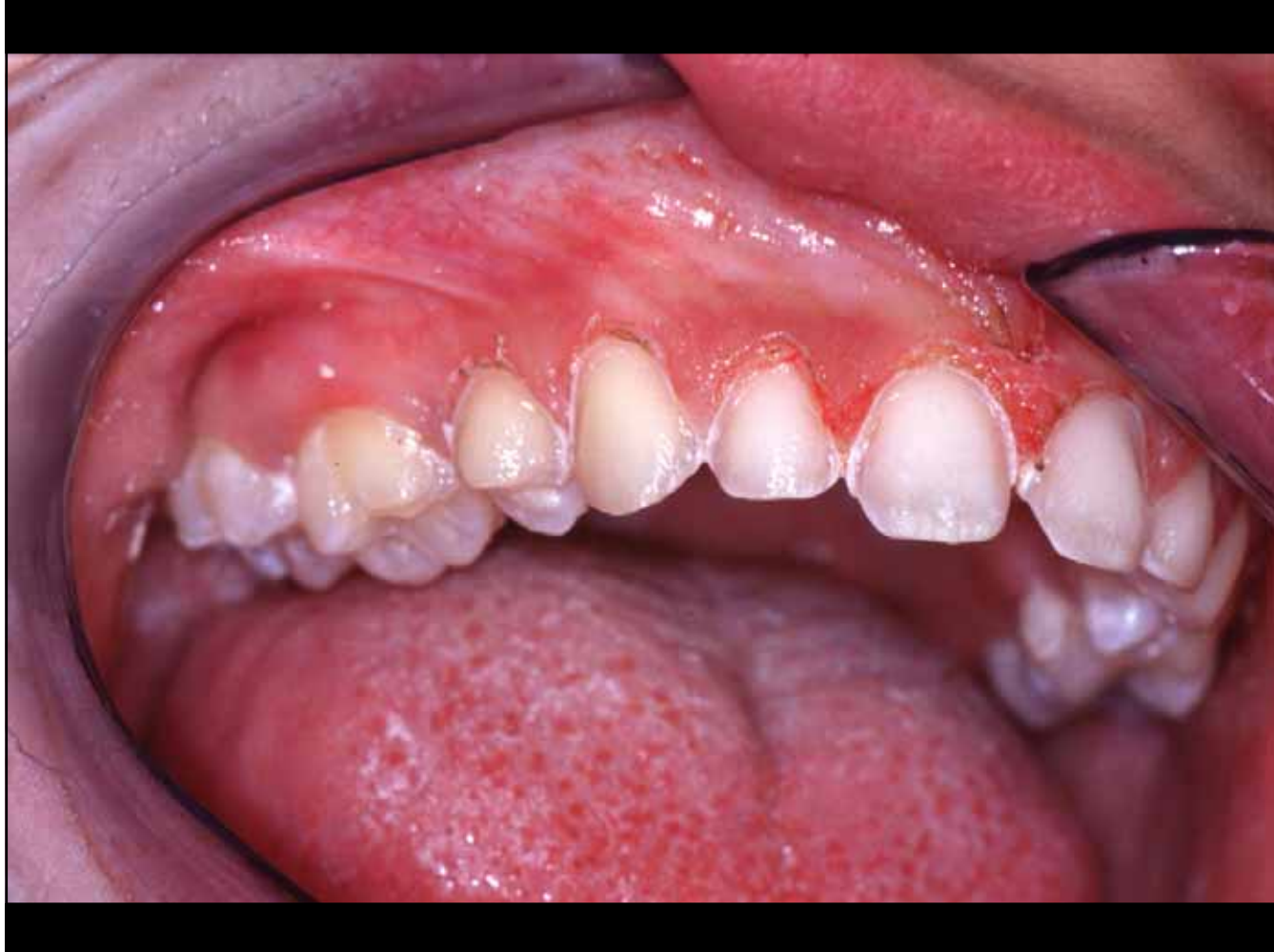# Shade Decision

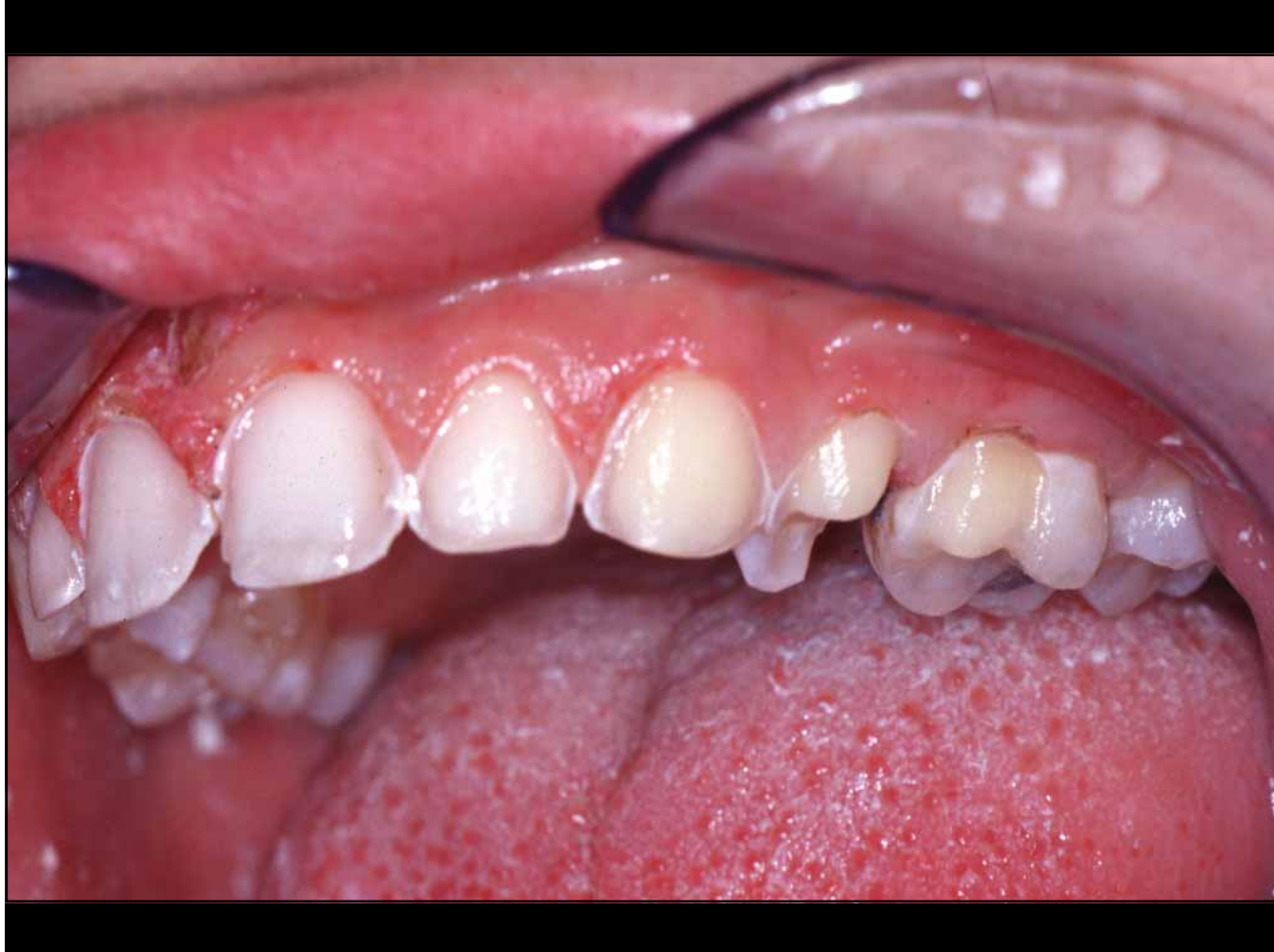After Considerable Discussion  
the Patient decided on A1 for the  
Incisal Region  
and A2 for the Body of the Veneers

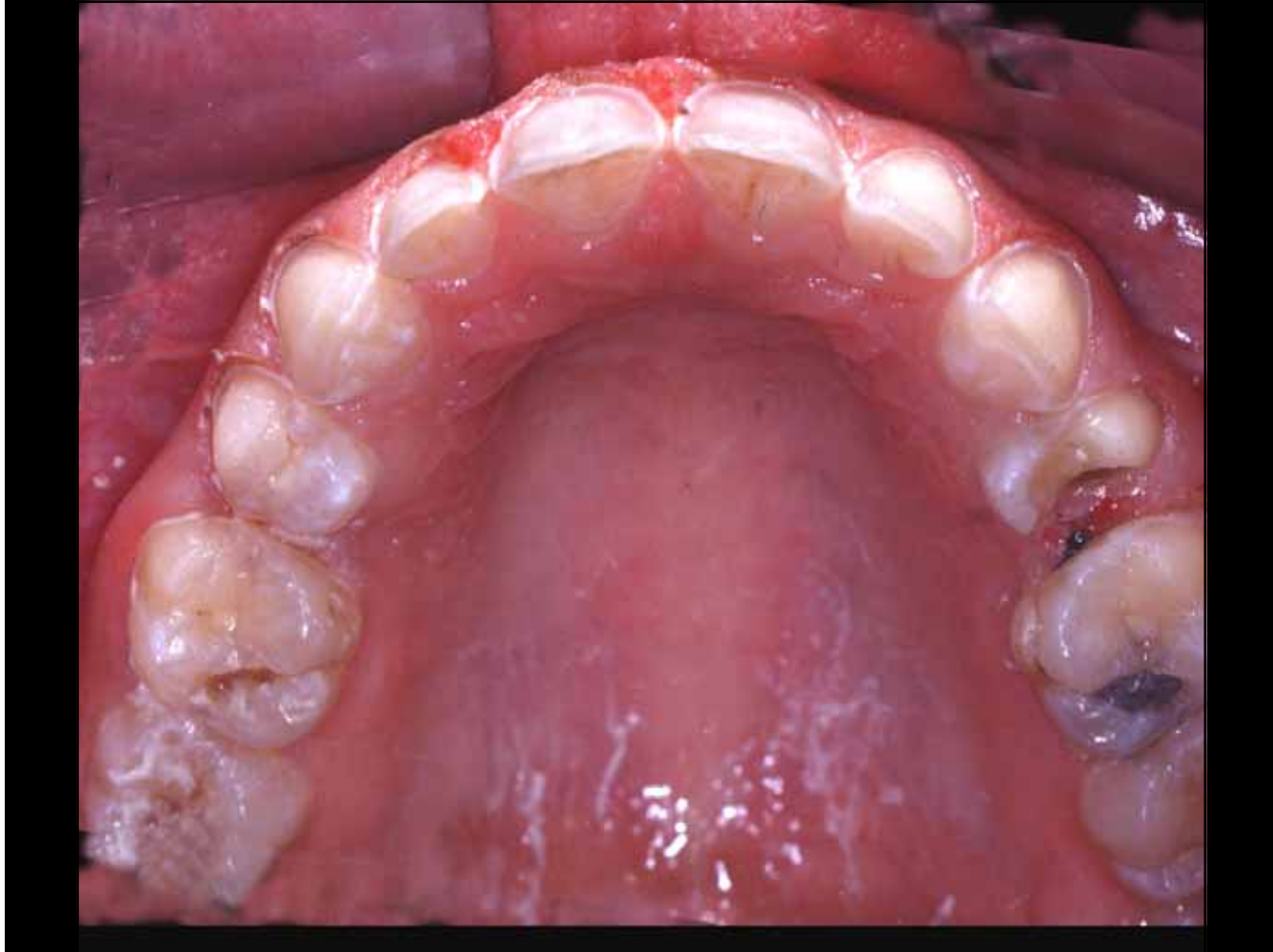
200903

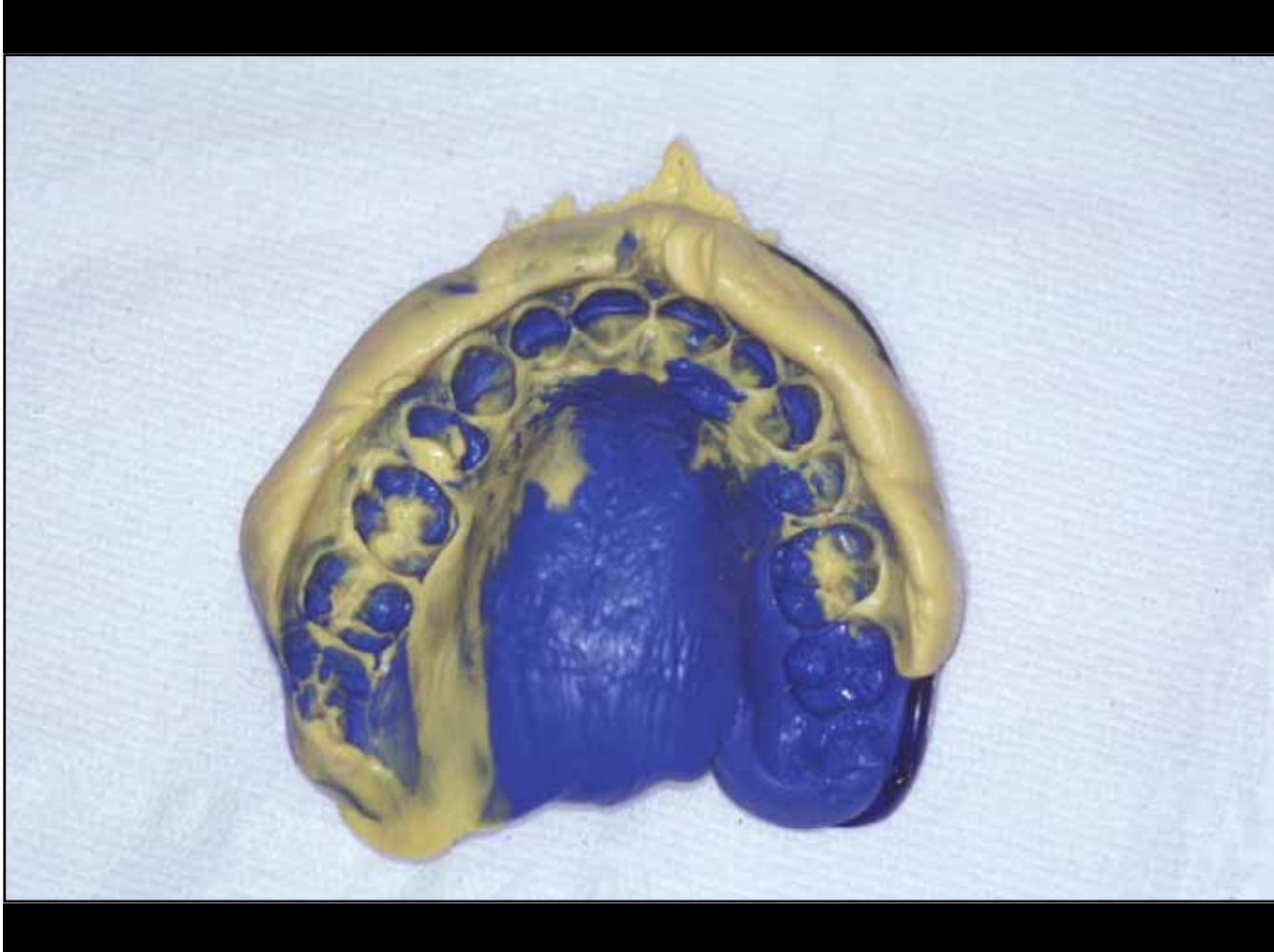# Veneer Preparation Procedure

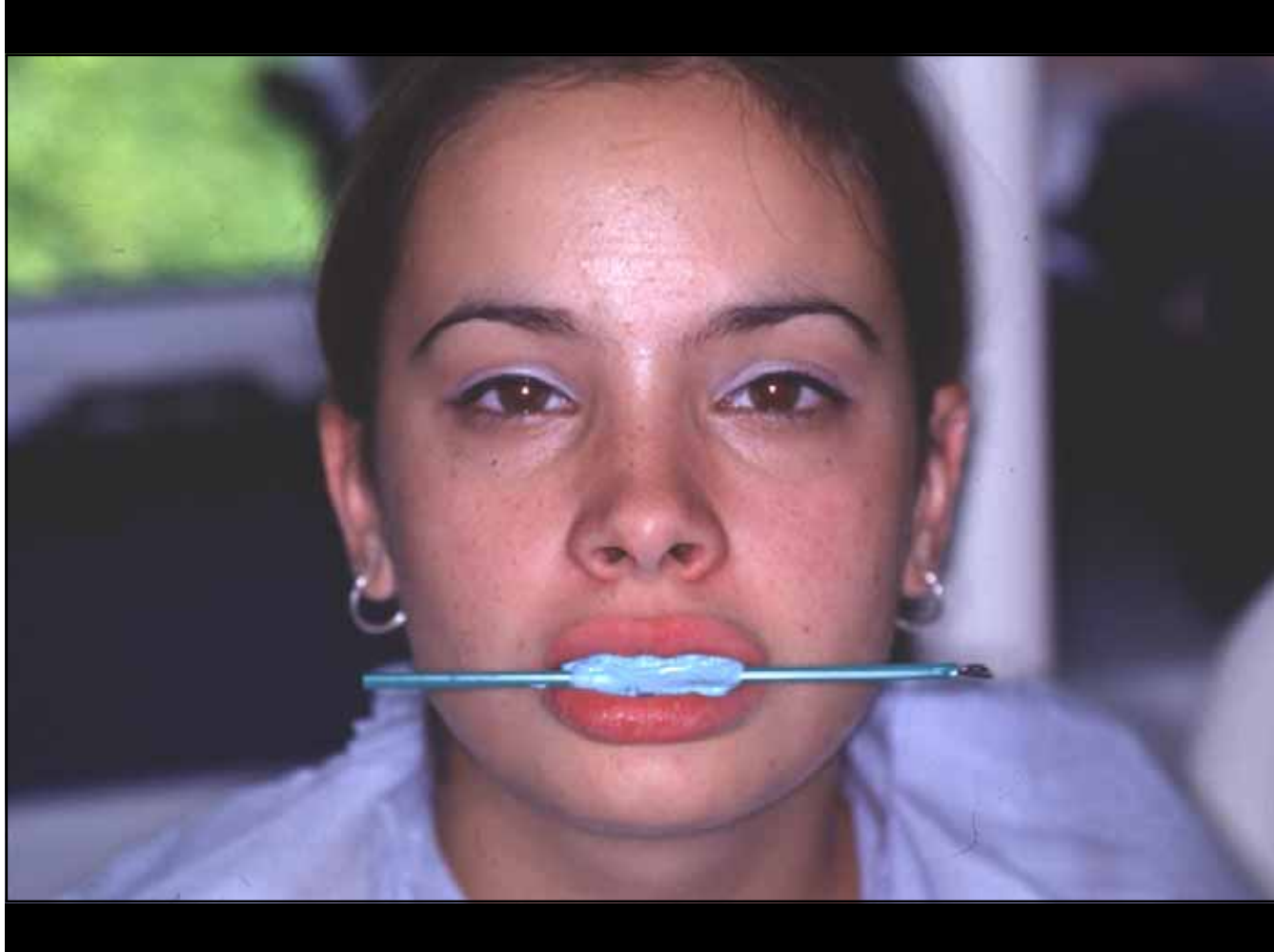












# Shade Decision

During the Veneer Preparation on the  
Veneer Course

Considerable Pressure was put on the  
Patient

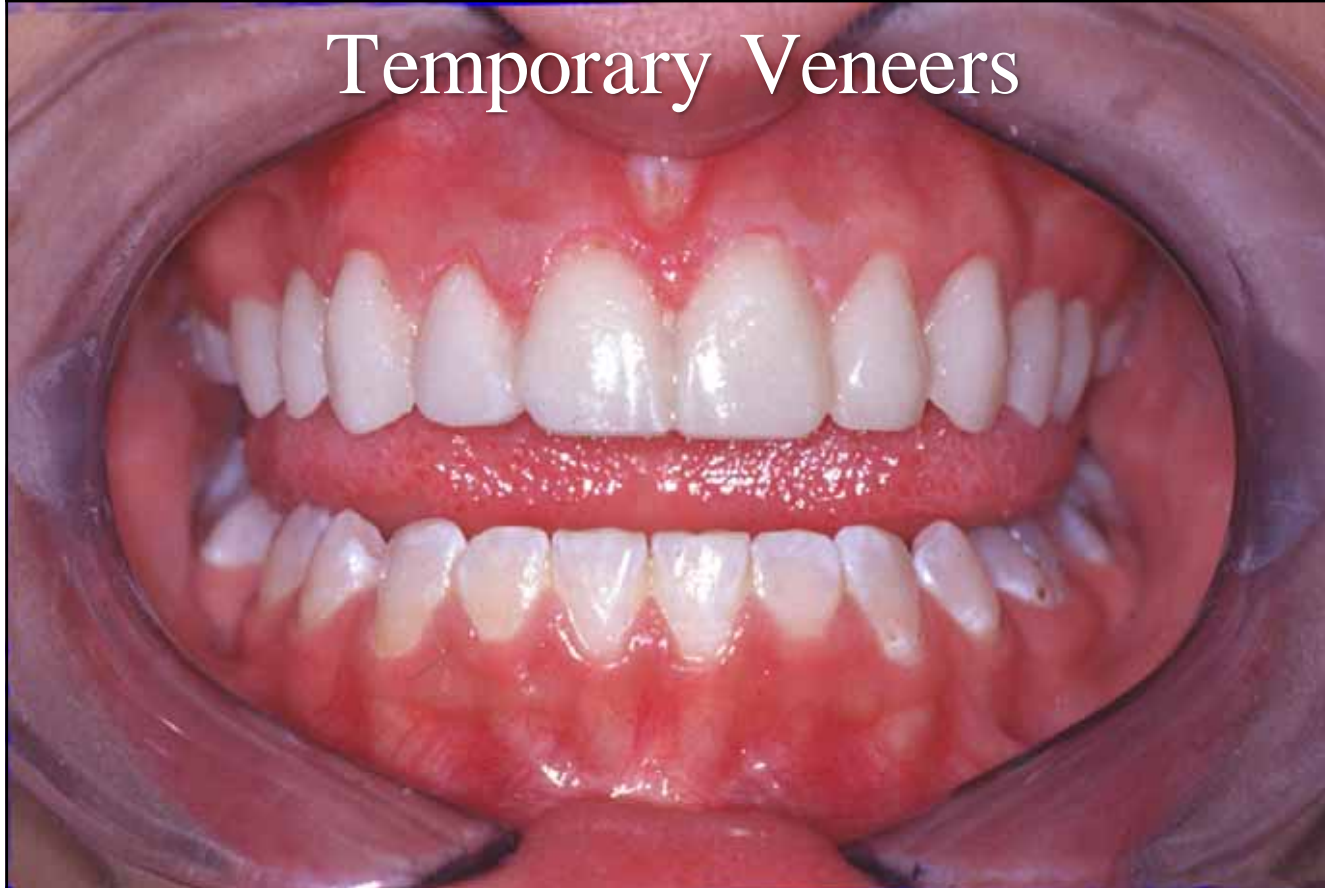
to have the Brilliant White Shade

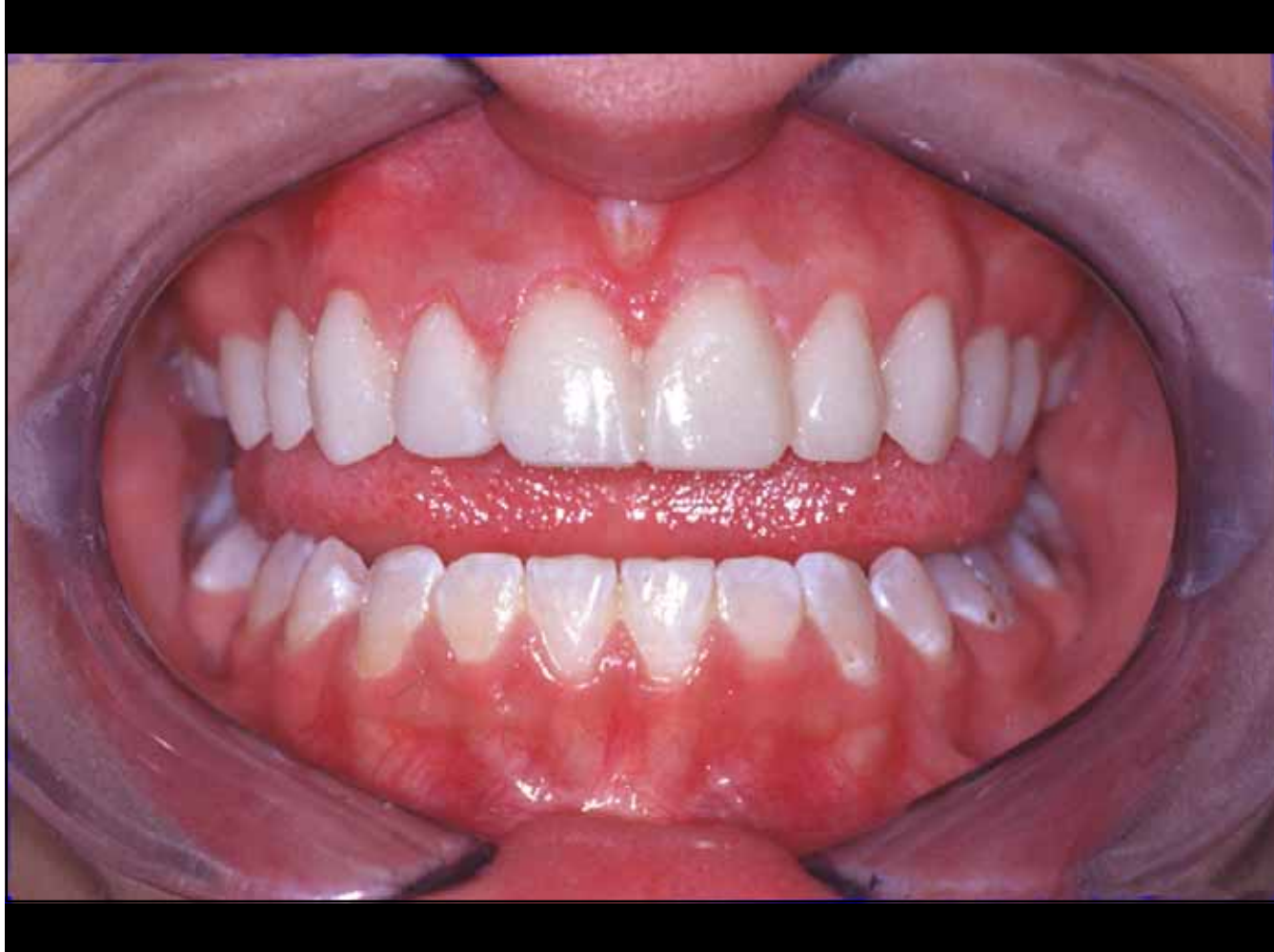# Shade Decision

The Patient resisted the Pressure  
Staying with A1 for the Incisal  
Region

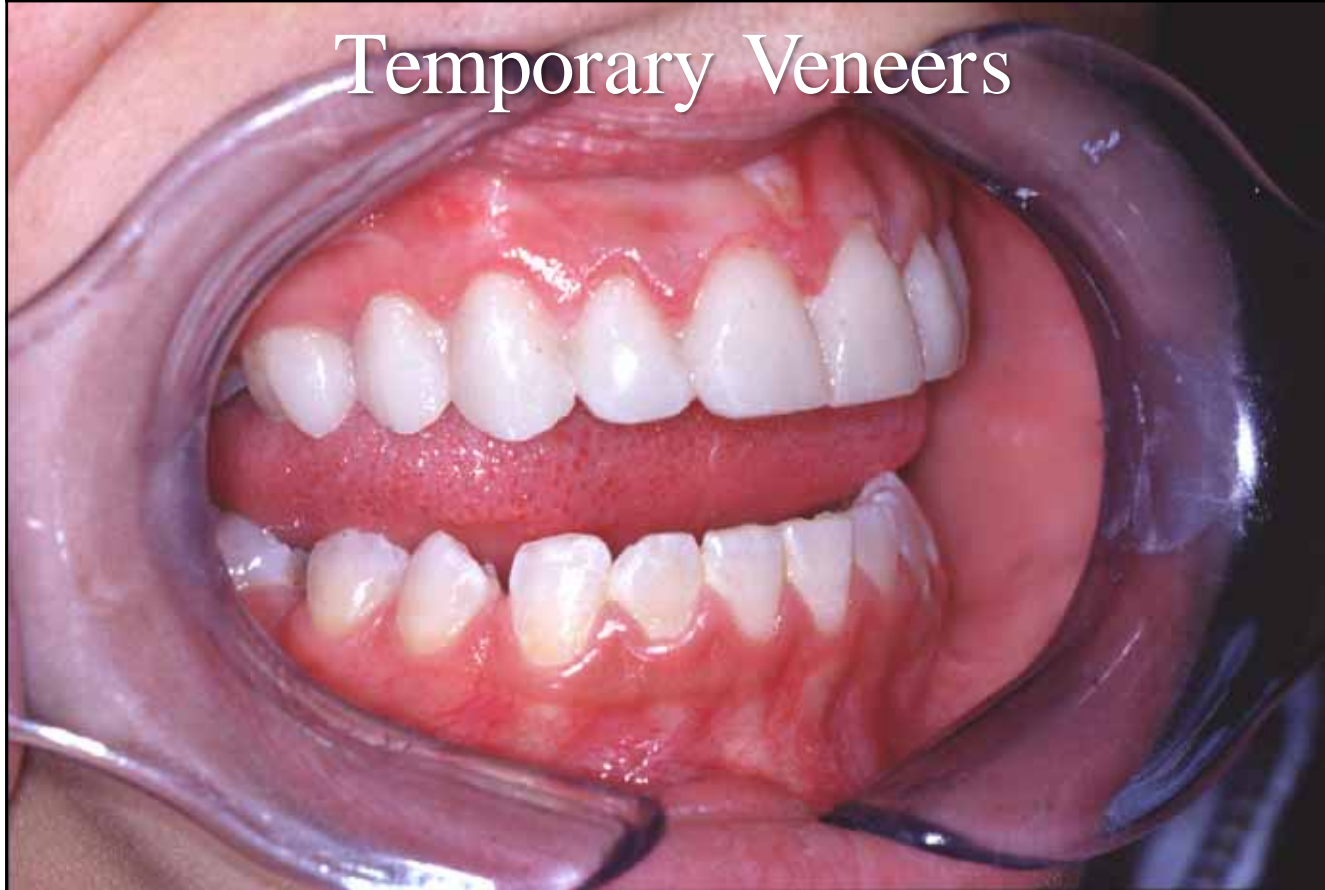
and A2 for the Body of the Veneers

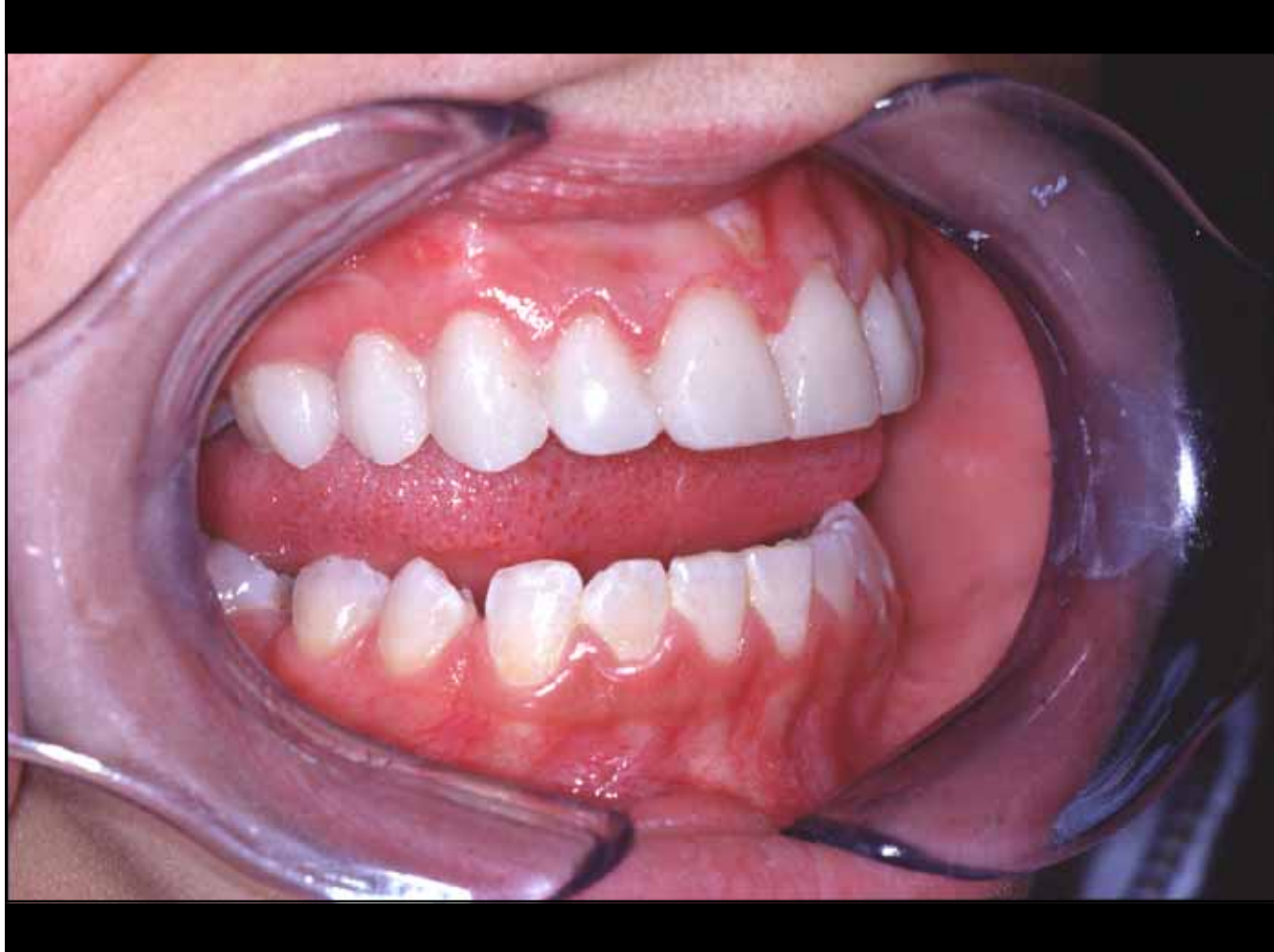# Temporary Veneers



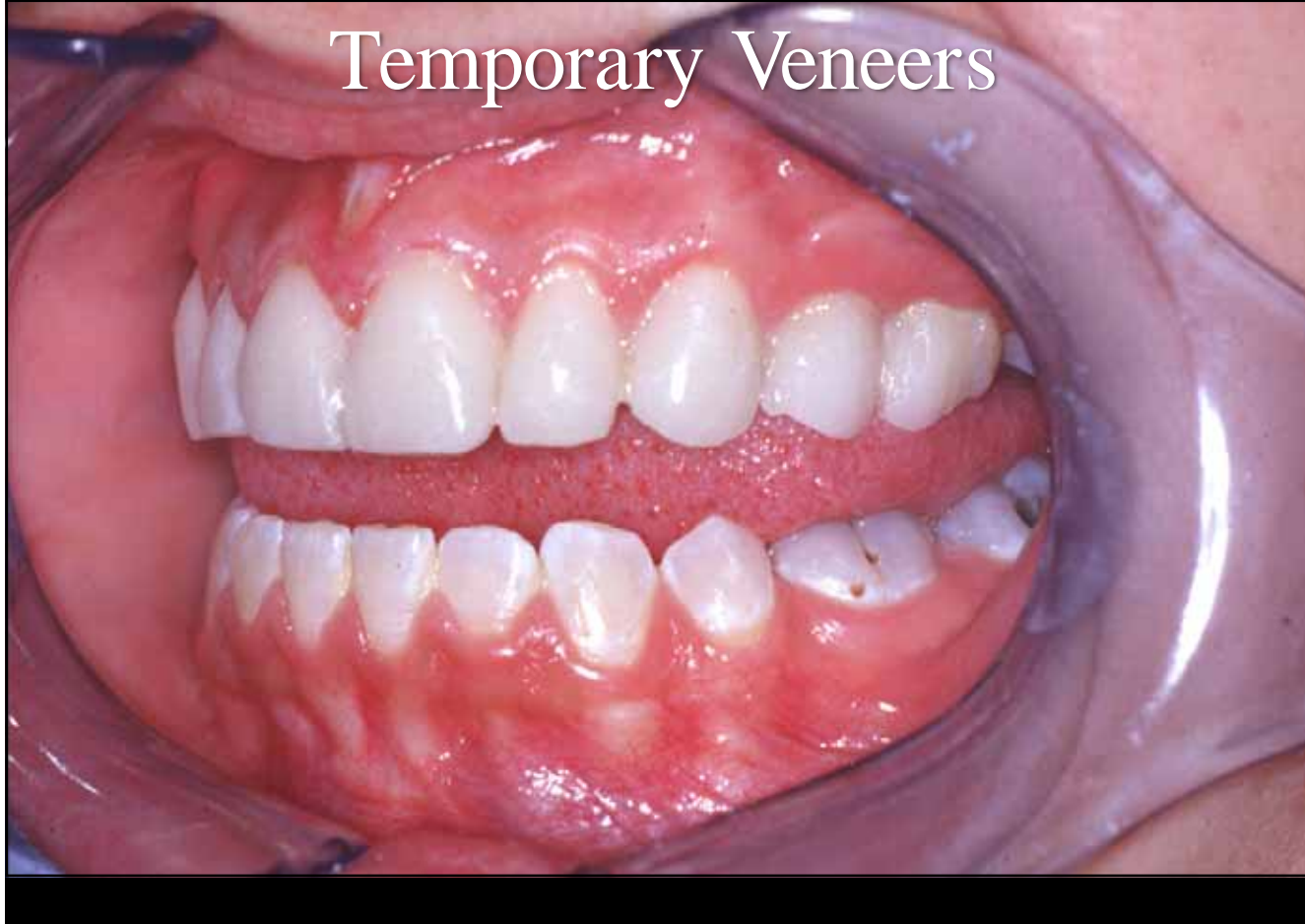


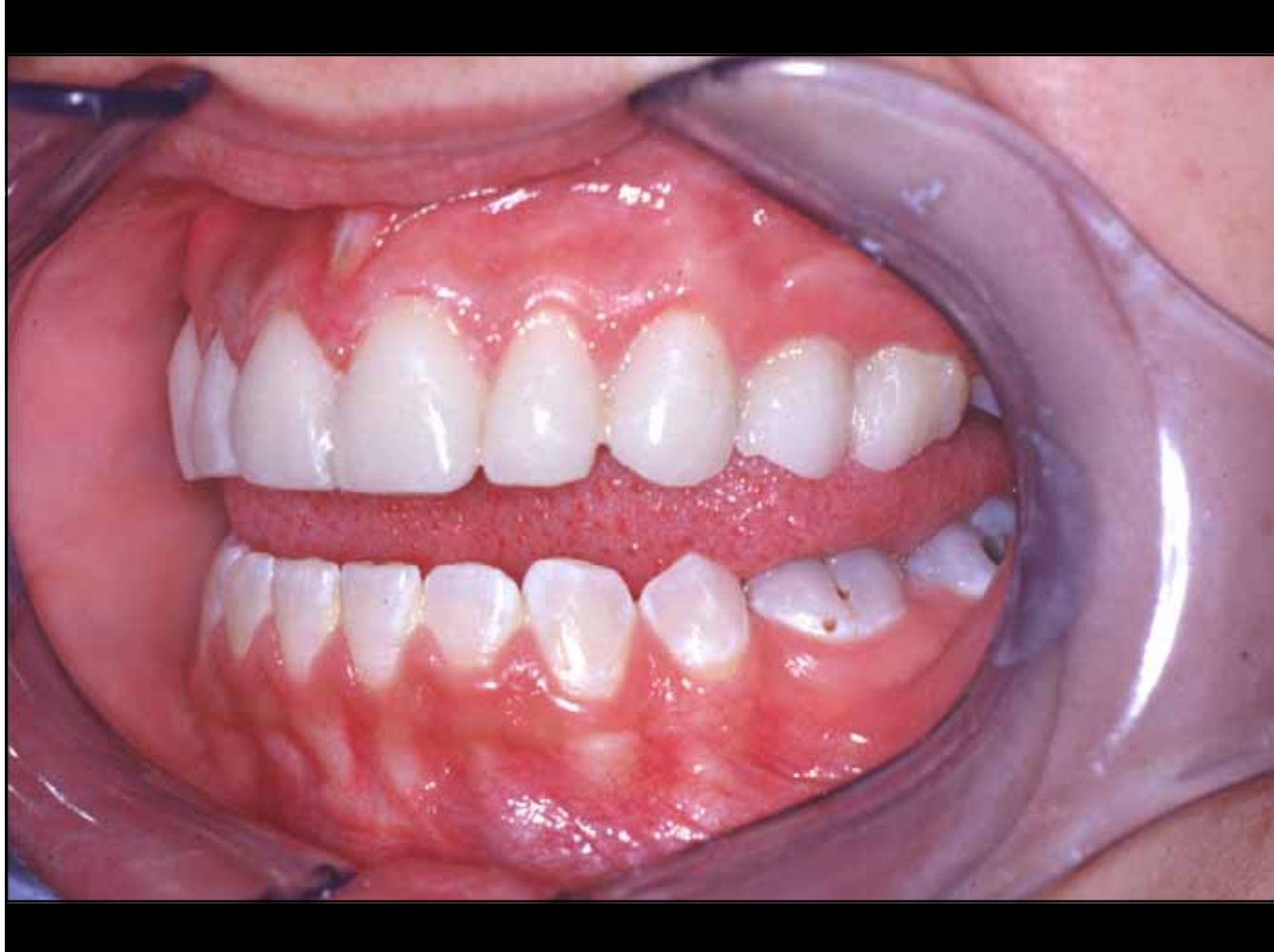# Temporary Veneers

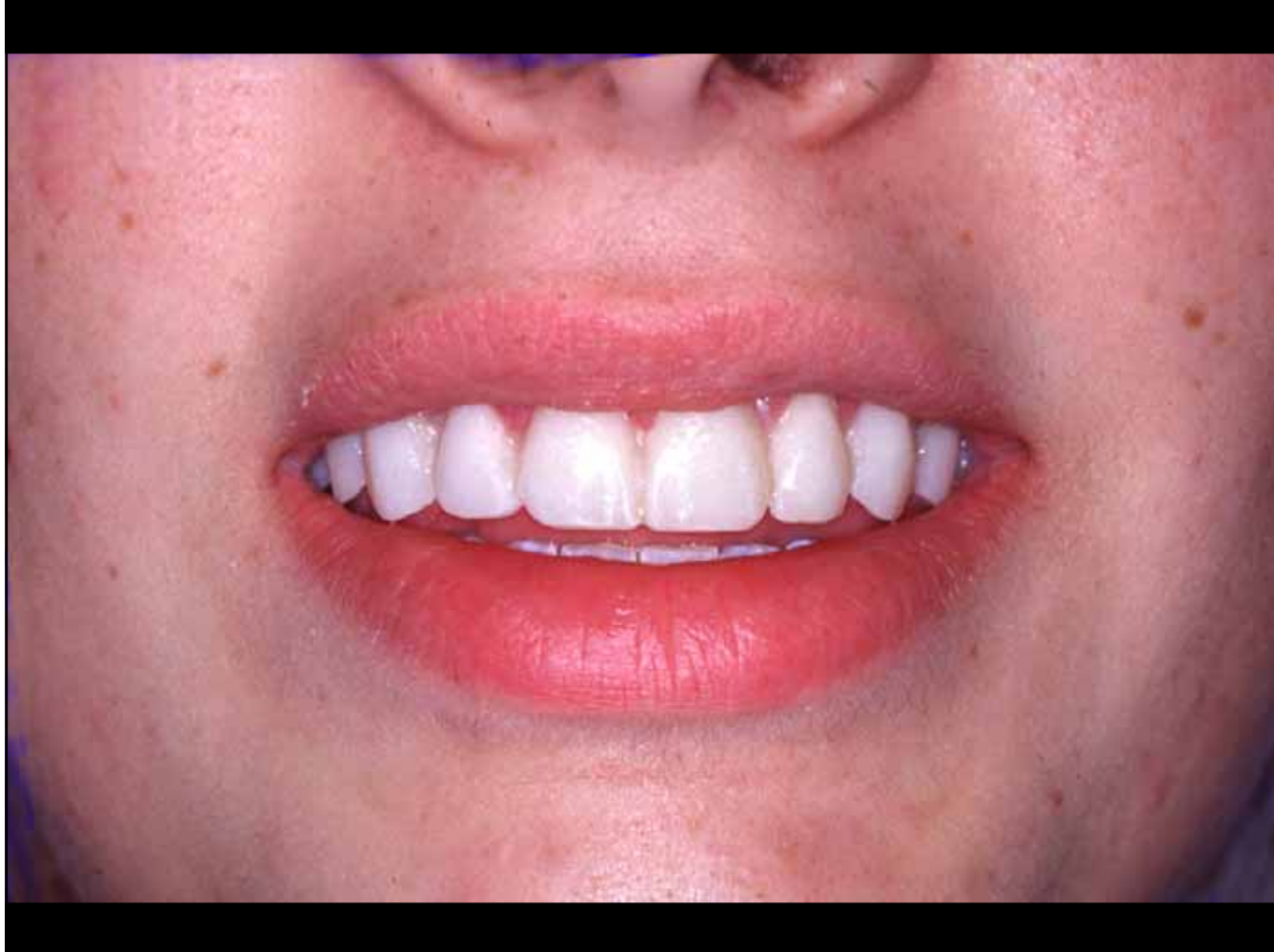



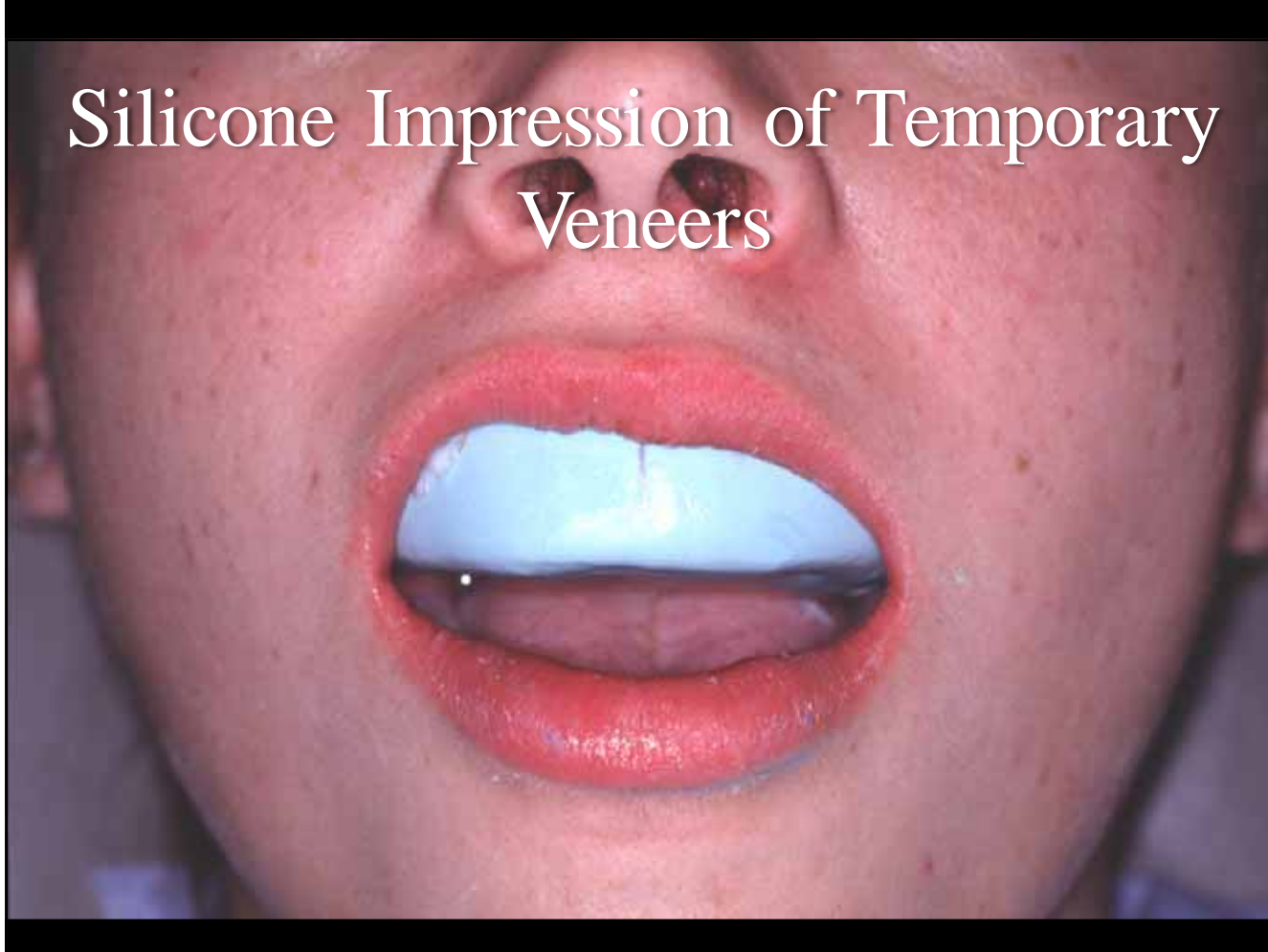# Temporary Veneers

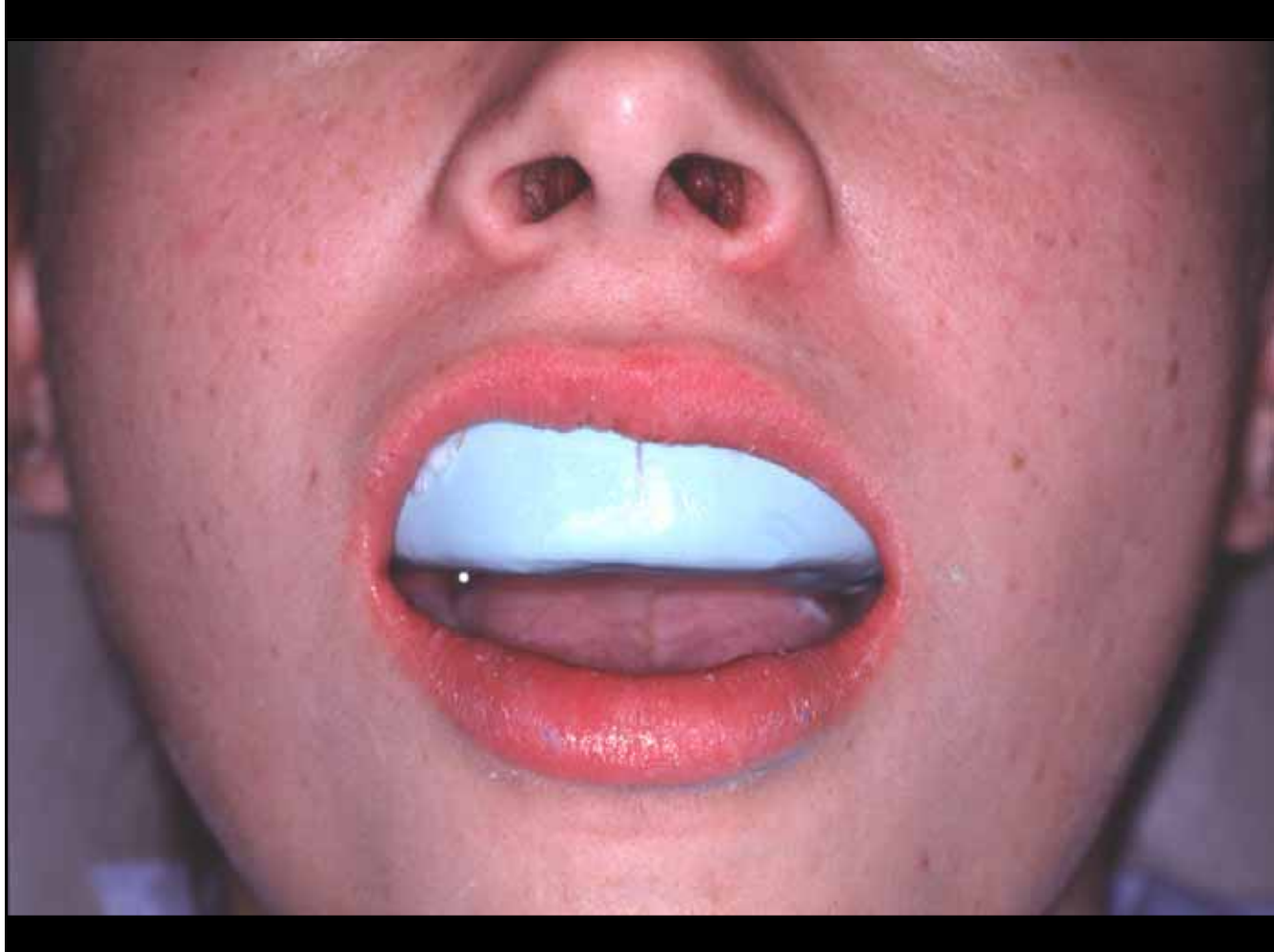






Silicone Impression of Temporary  
Veneers





# Shade Decision

Having worn the Temporary Veneers  
for a Few Days

The Patient decided on

A1 for the Incisal  
and the Body as well

281003

# Veneer Fitting











