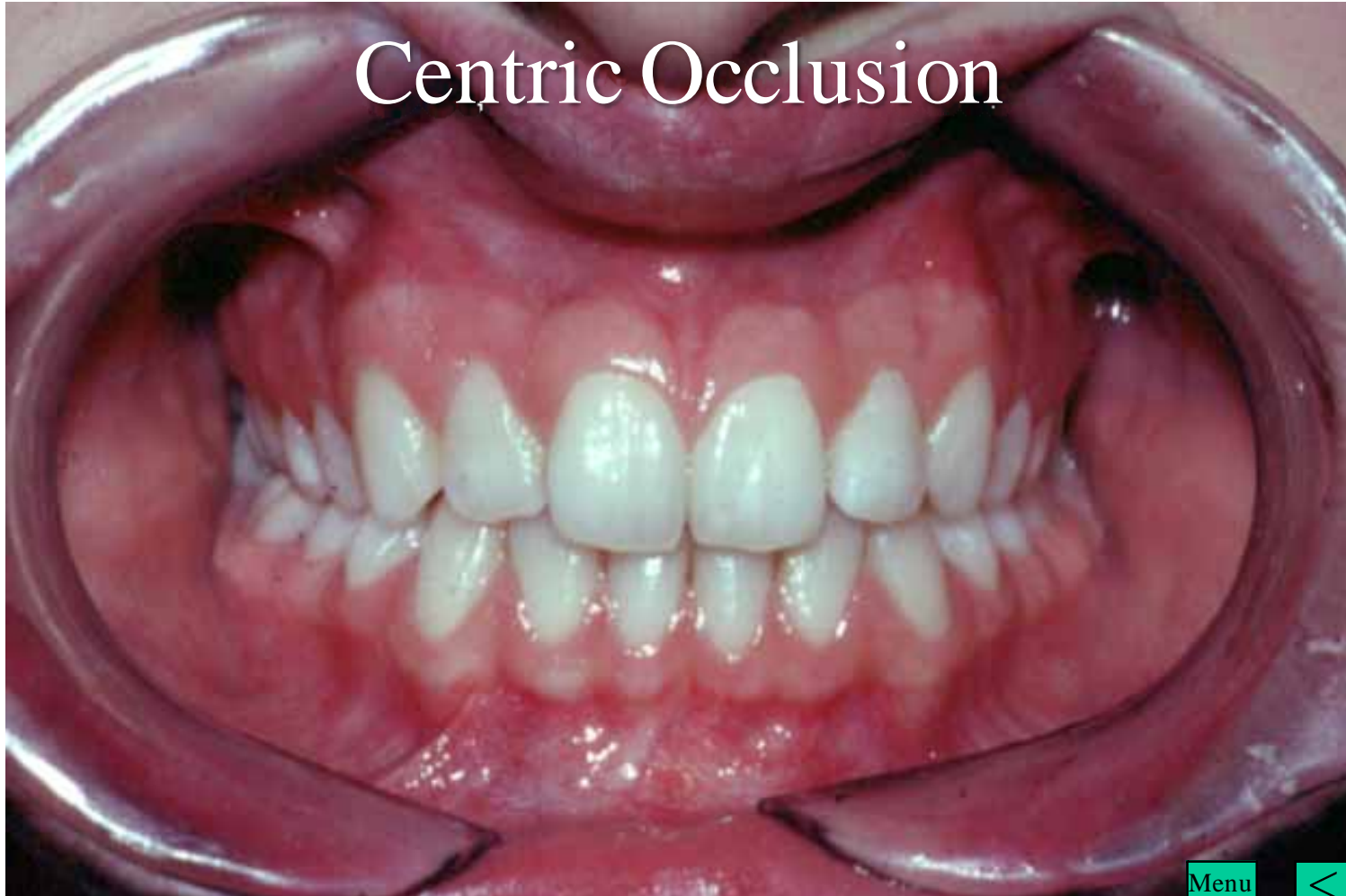


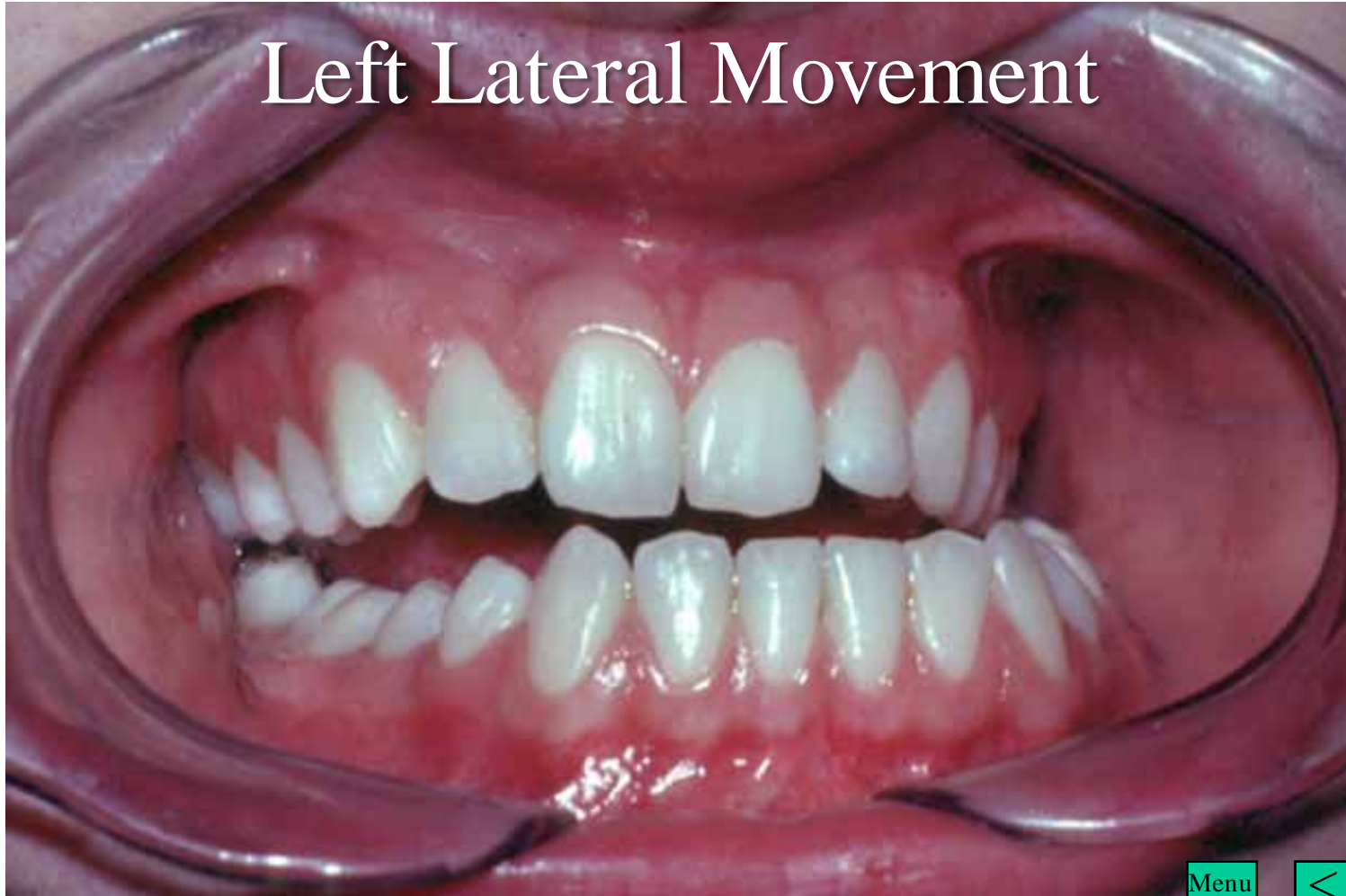# Occlusal Adjustment on Study Models

Menu

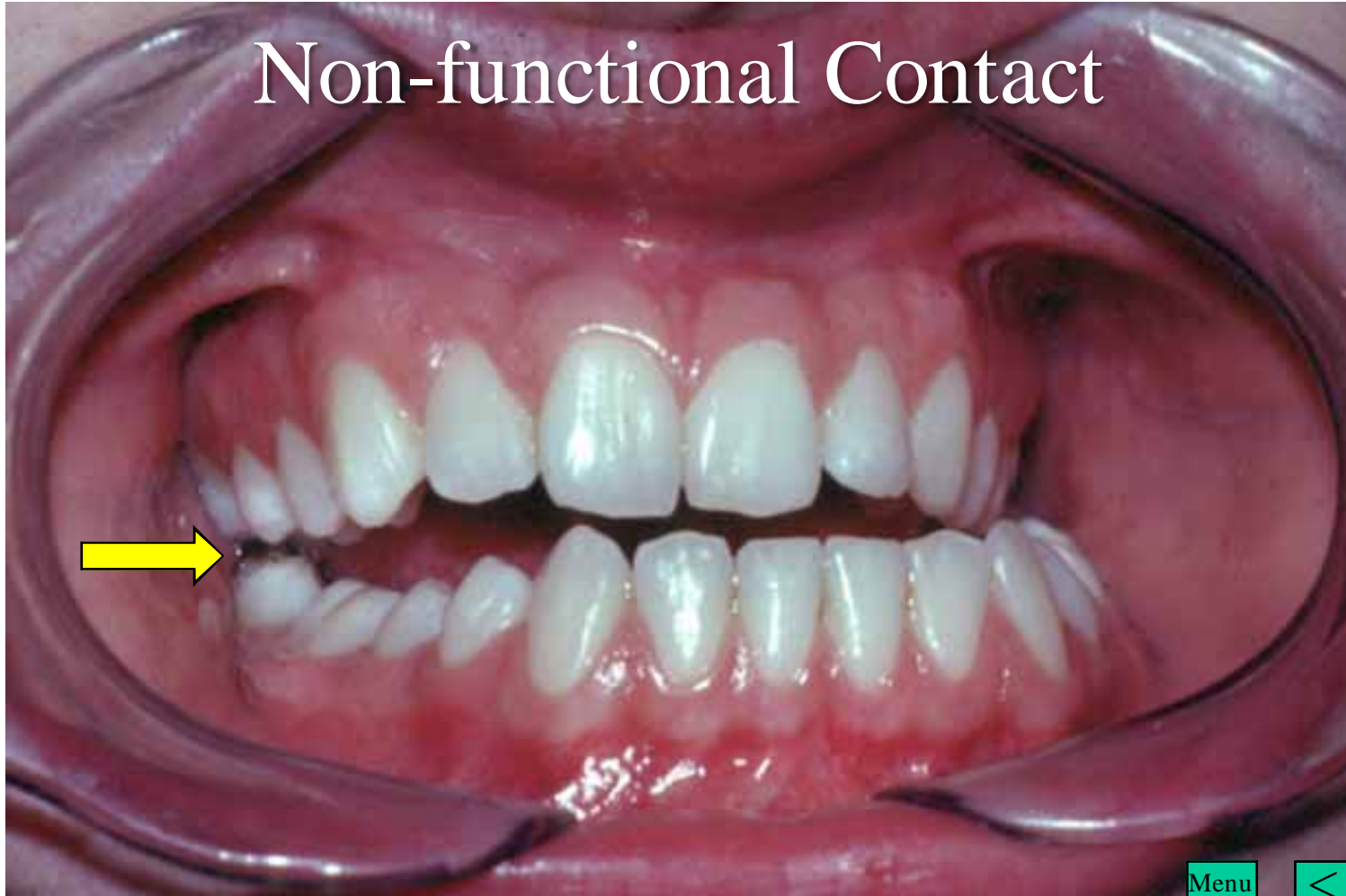# Centric Occlusion



# Left Lateral Movement



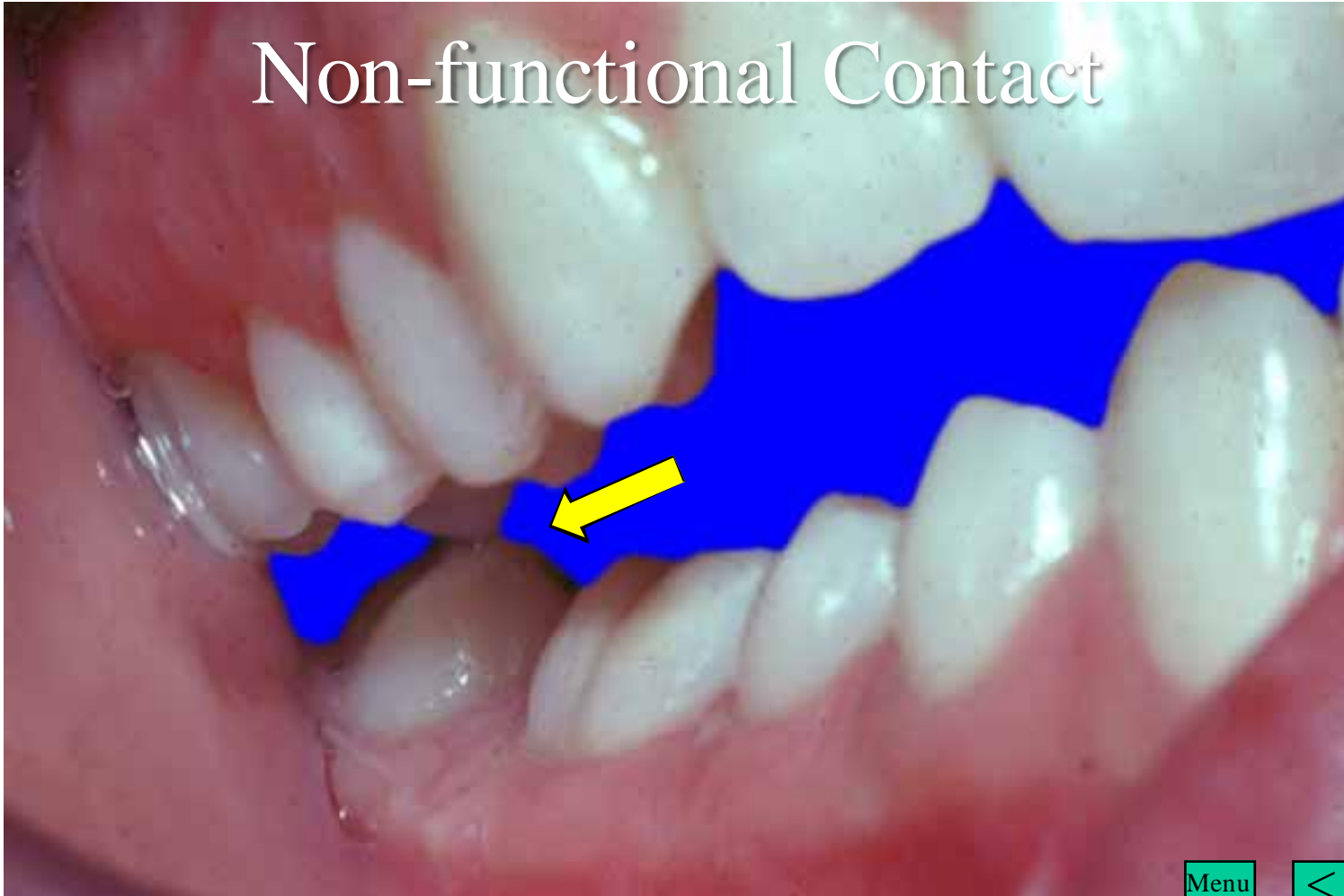
# Non-functional Contact



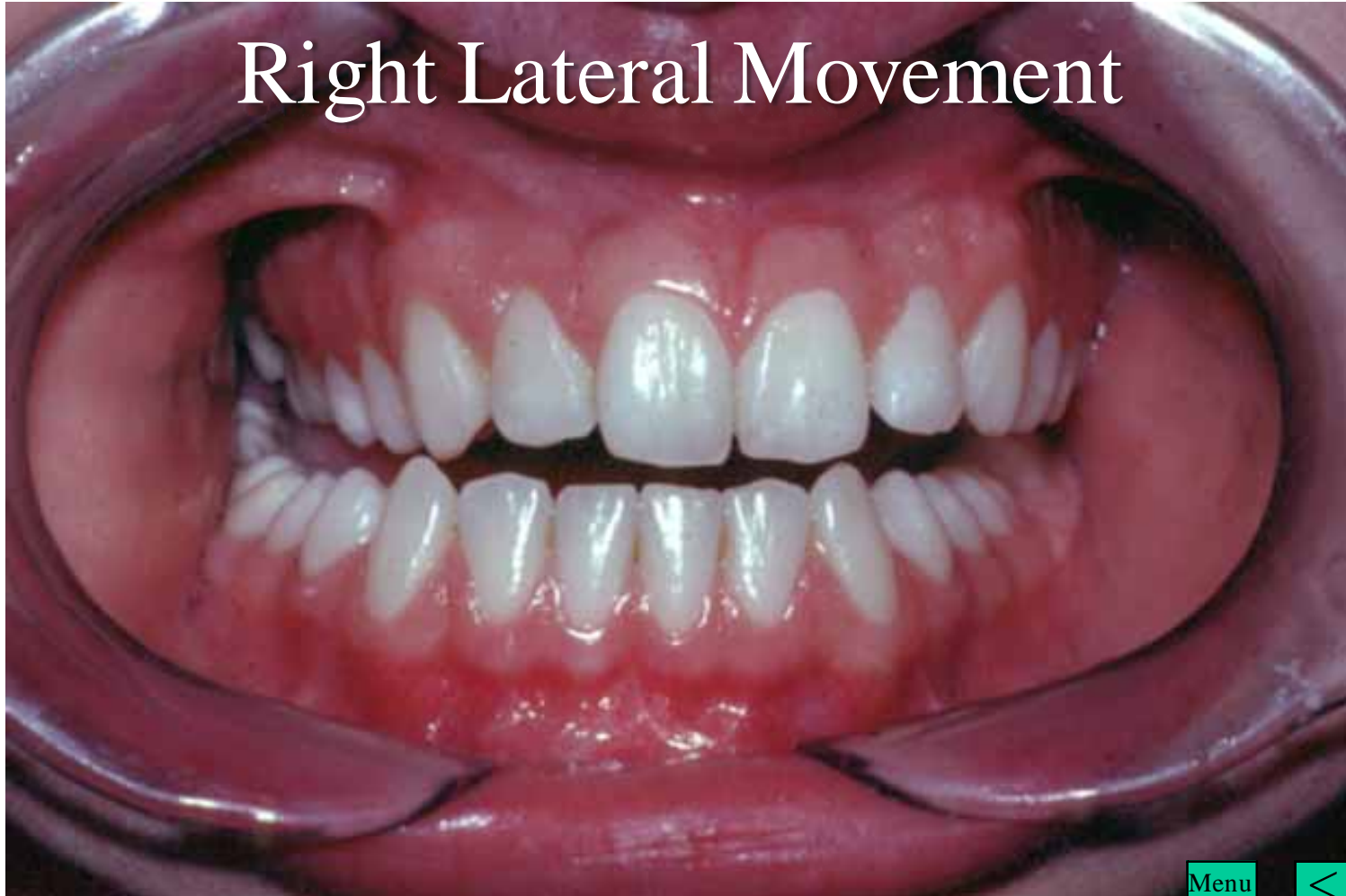Menu



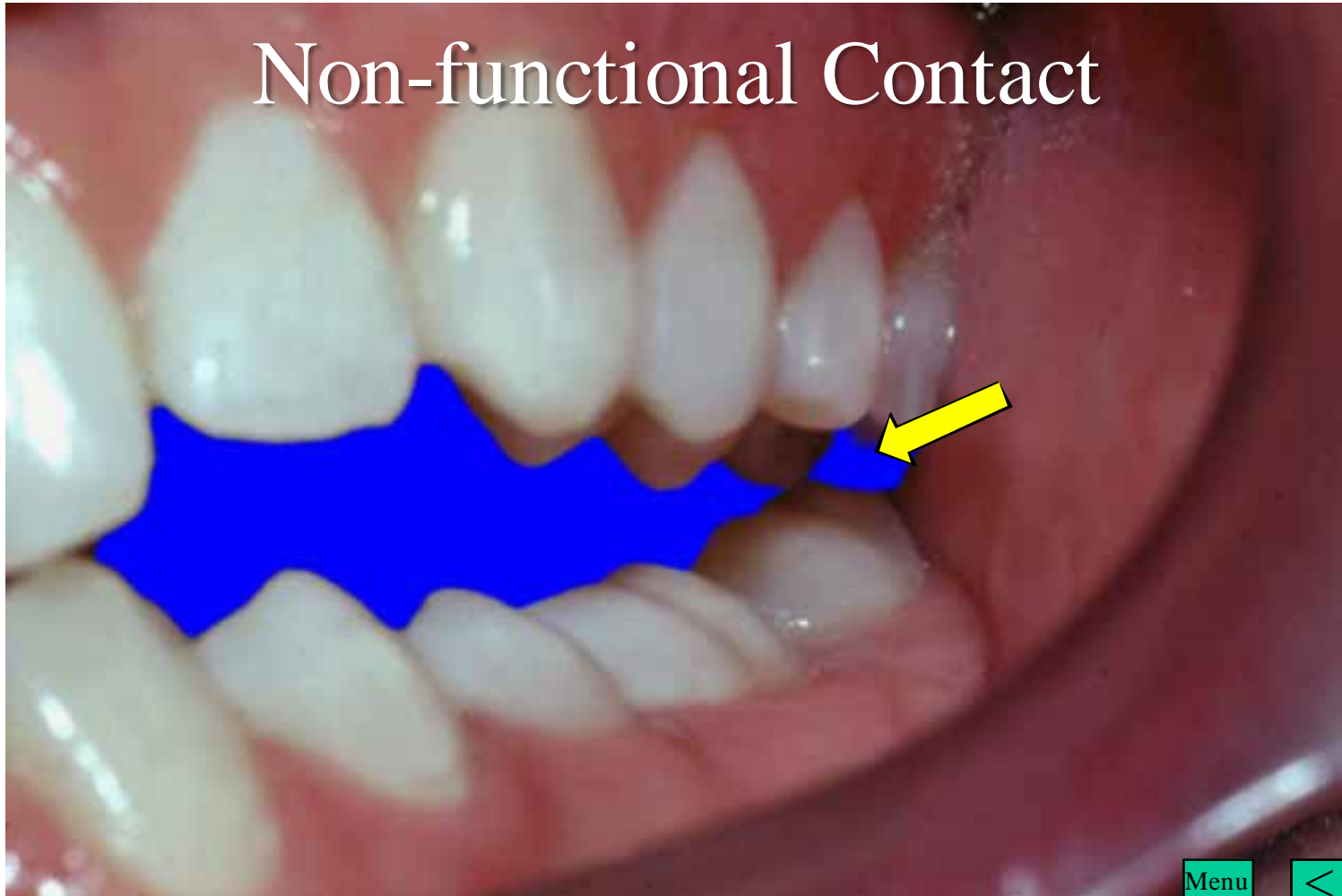
# Non-functional Contact



# Right Lateral Movement



# Non-functional Contact



Menu



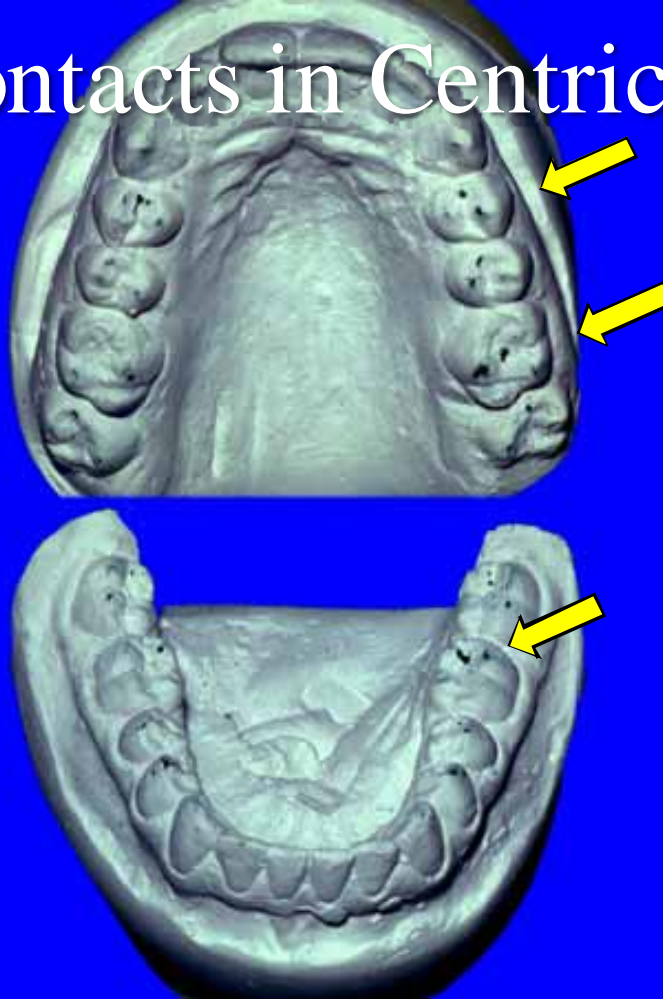
# Two Sets of Mounted Study Models



Menu



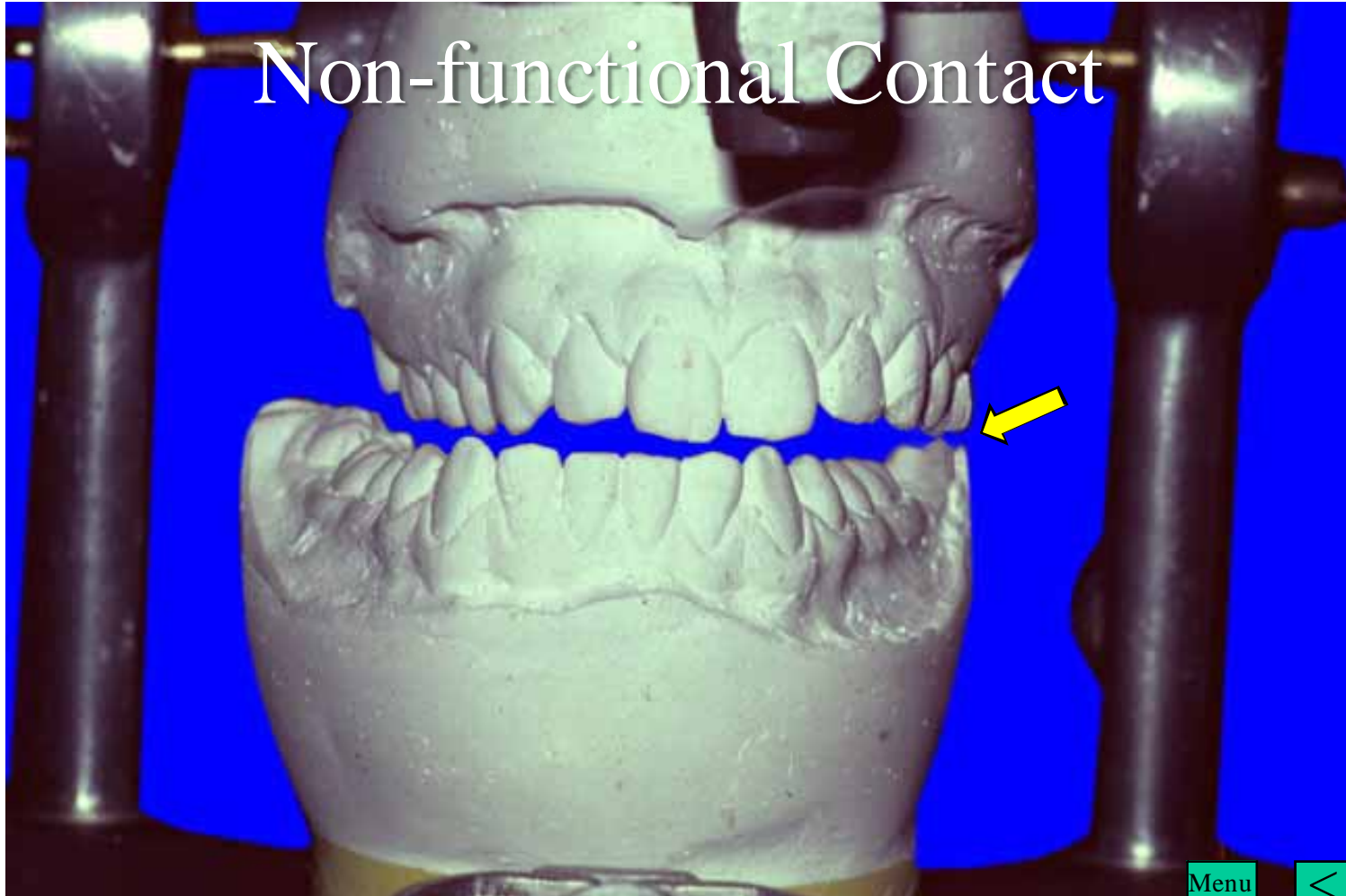# Early Contacts in Centric Relation



Menu



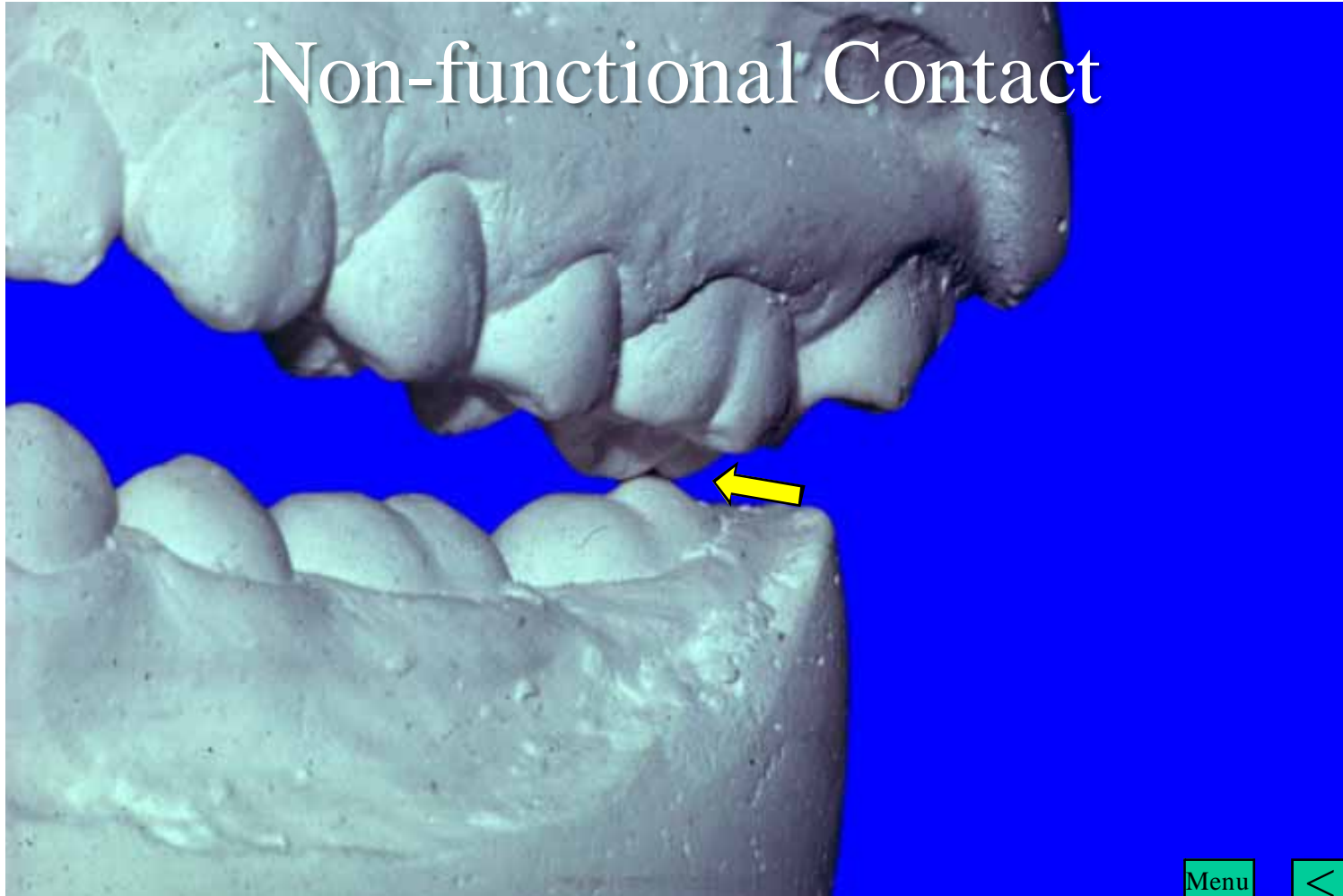
# Non-functional Contact



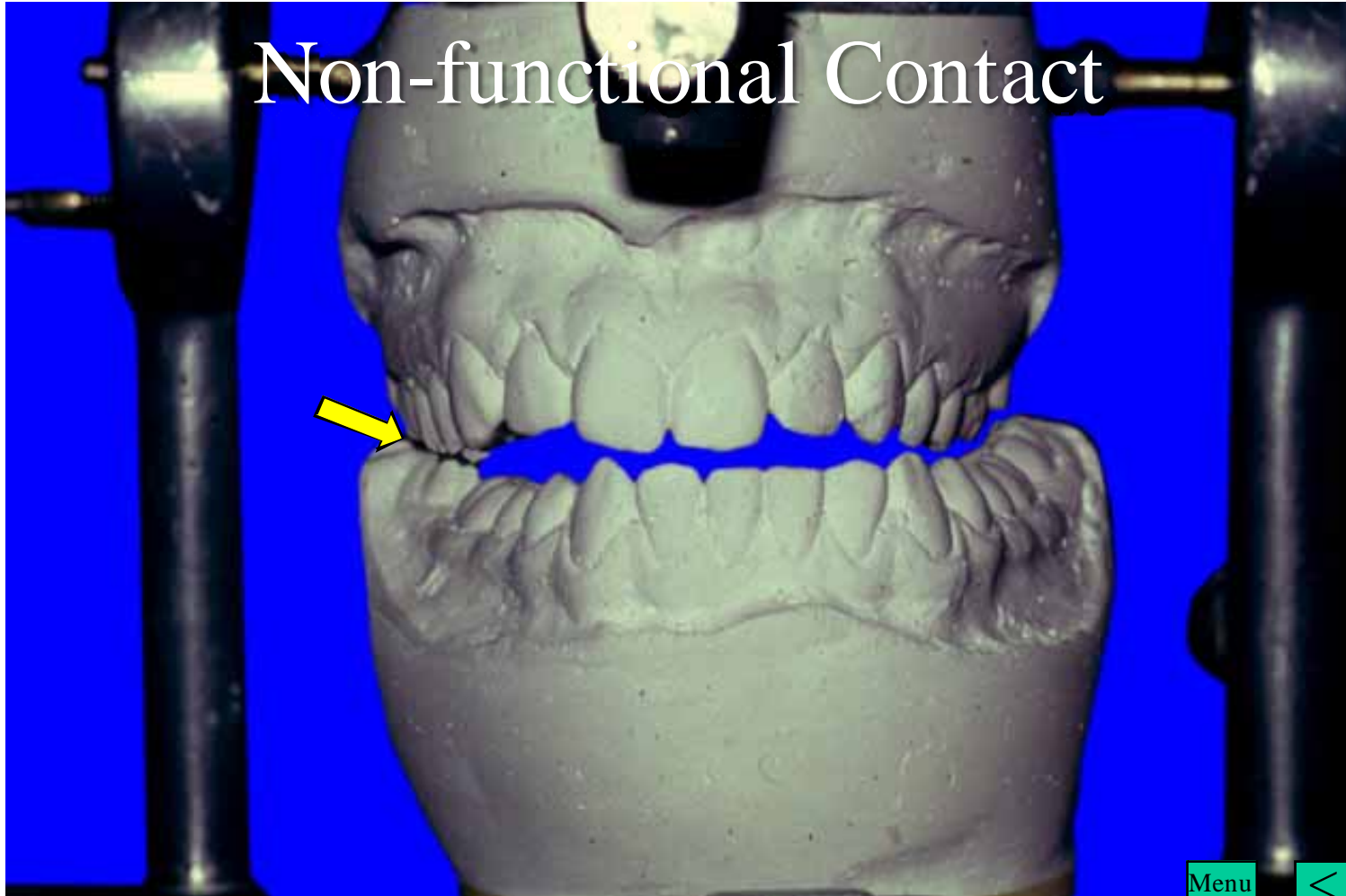
Menu



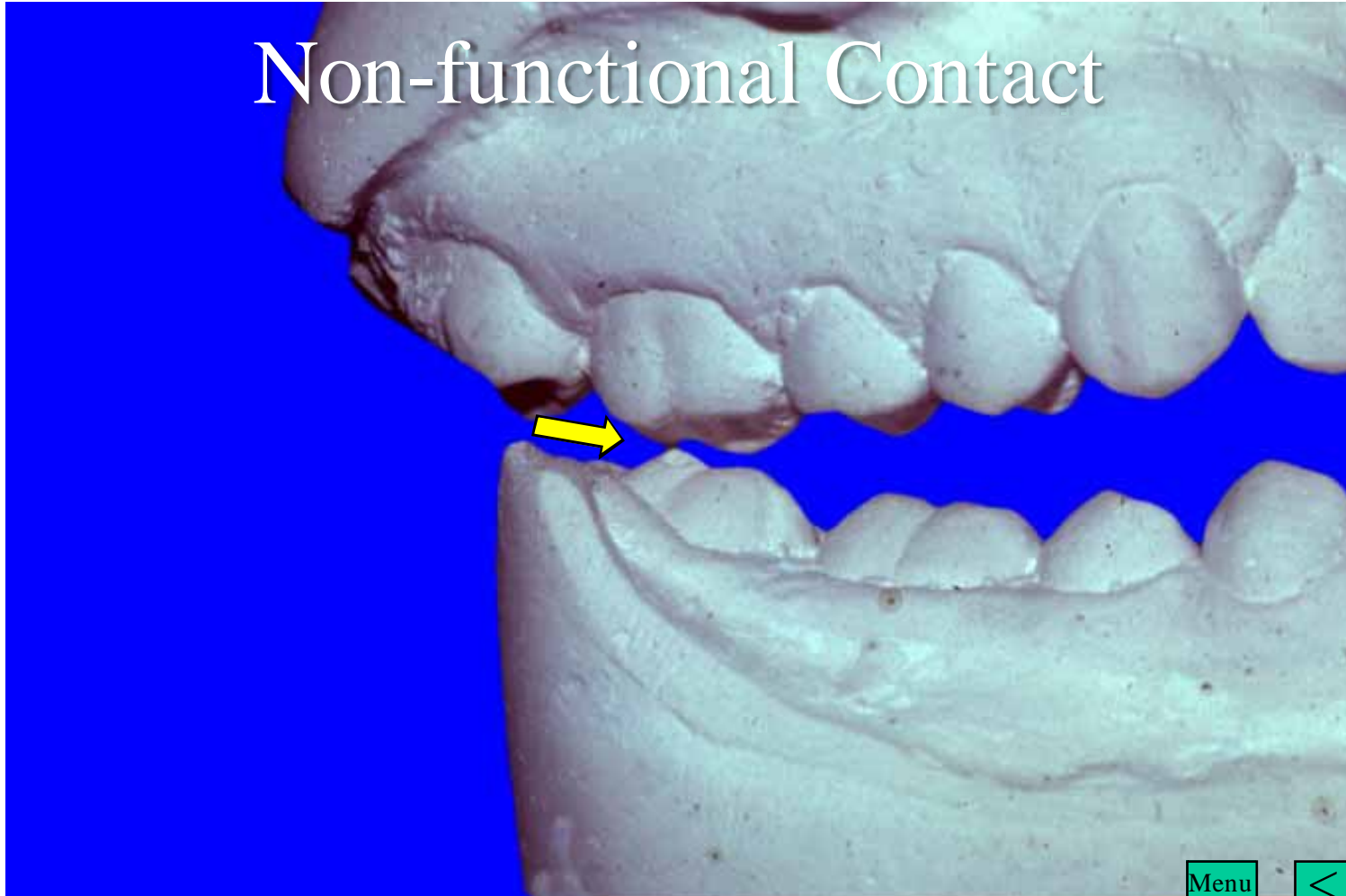
# Non-functional Contact




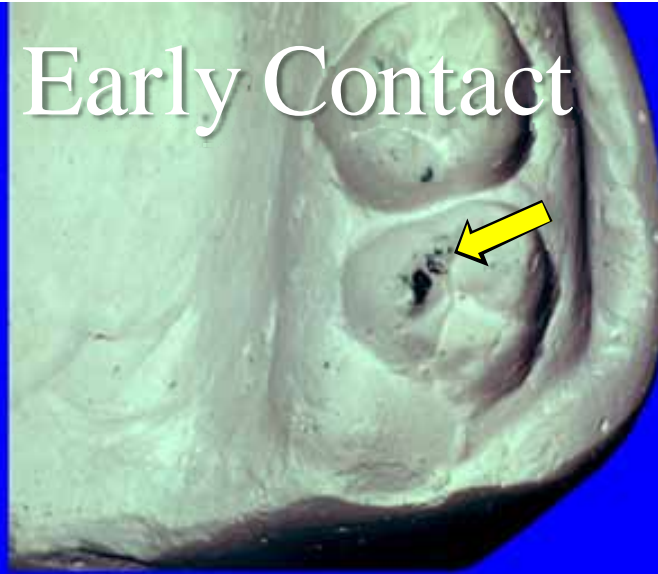
# Non-functional Contact



# Non-functional Contact



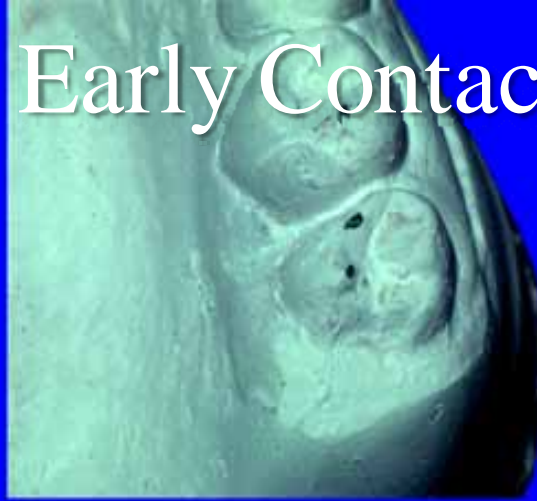
# Early Contact



Menu

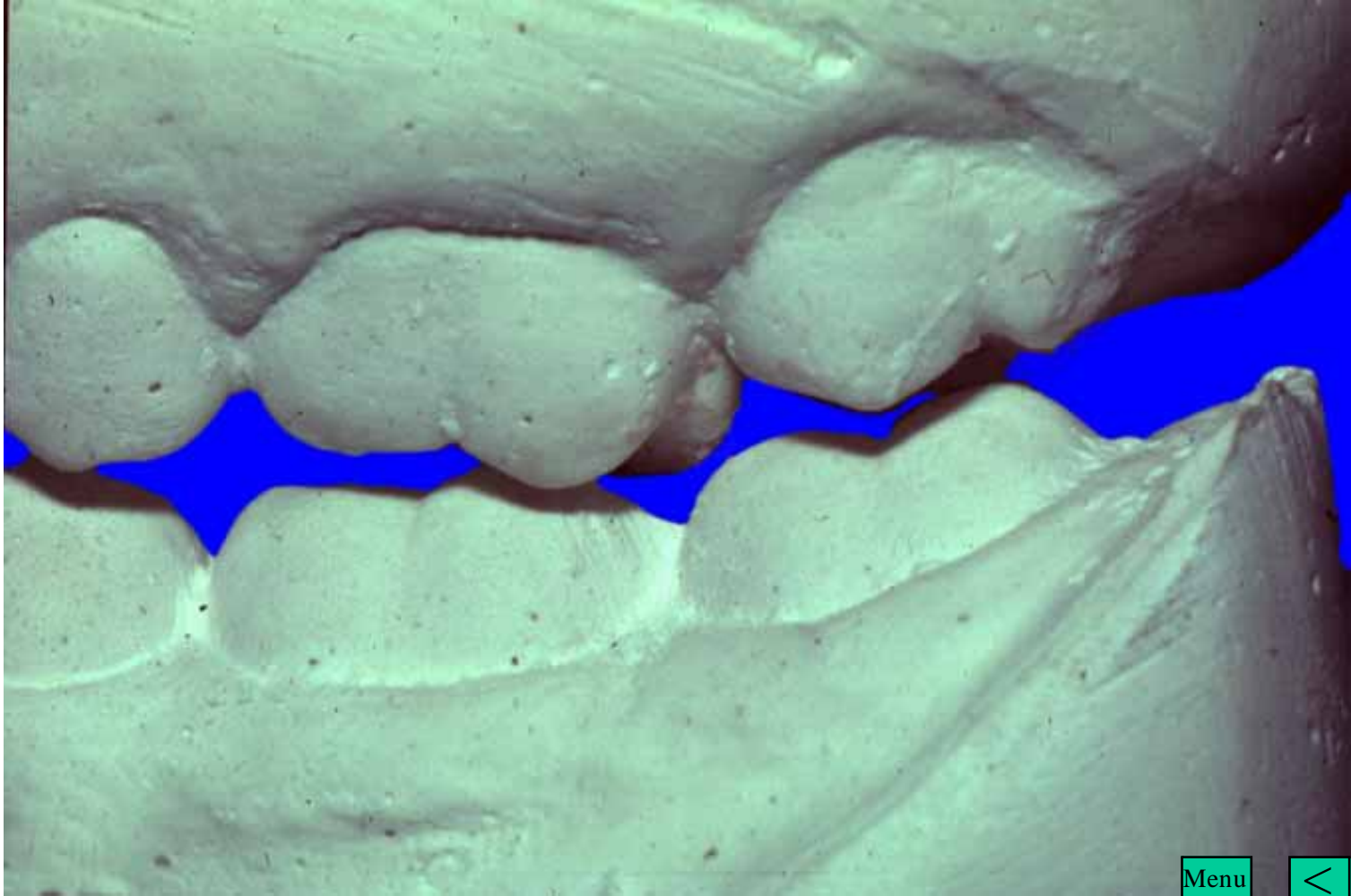


# Early Contact



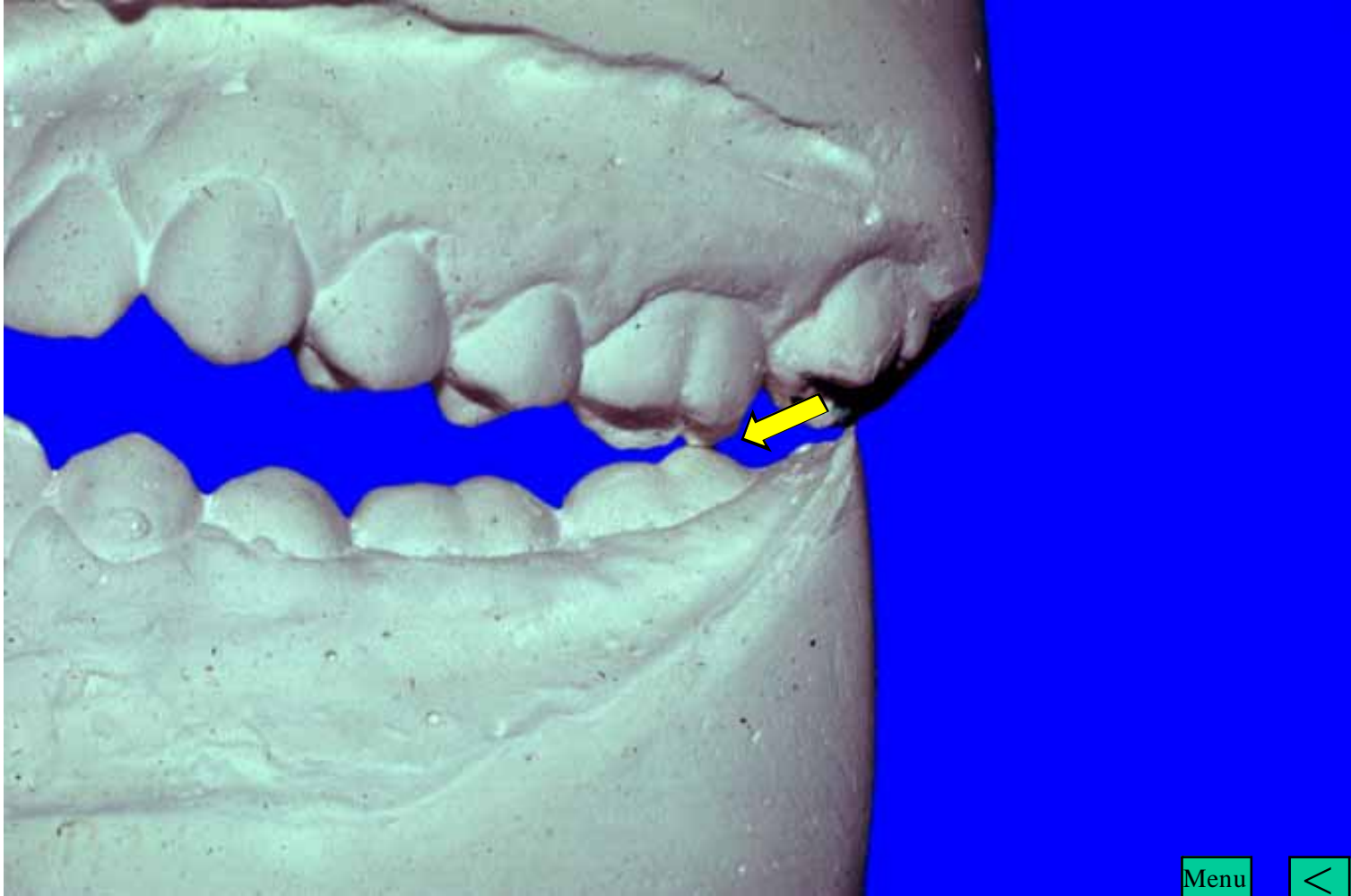
Menu

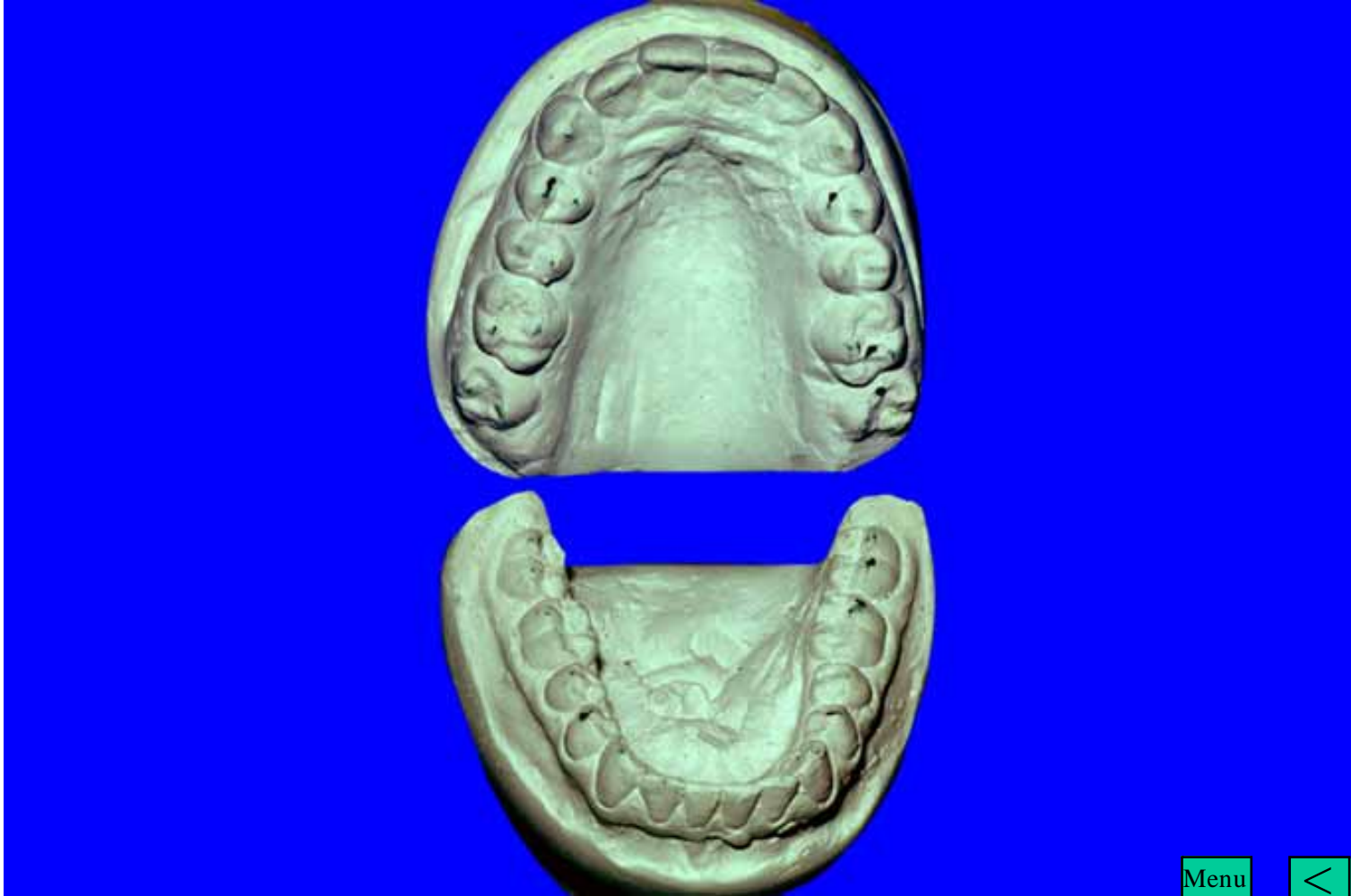



Menu

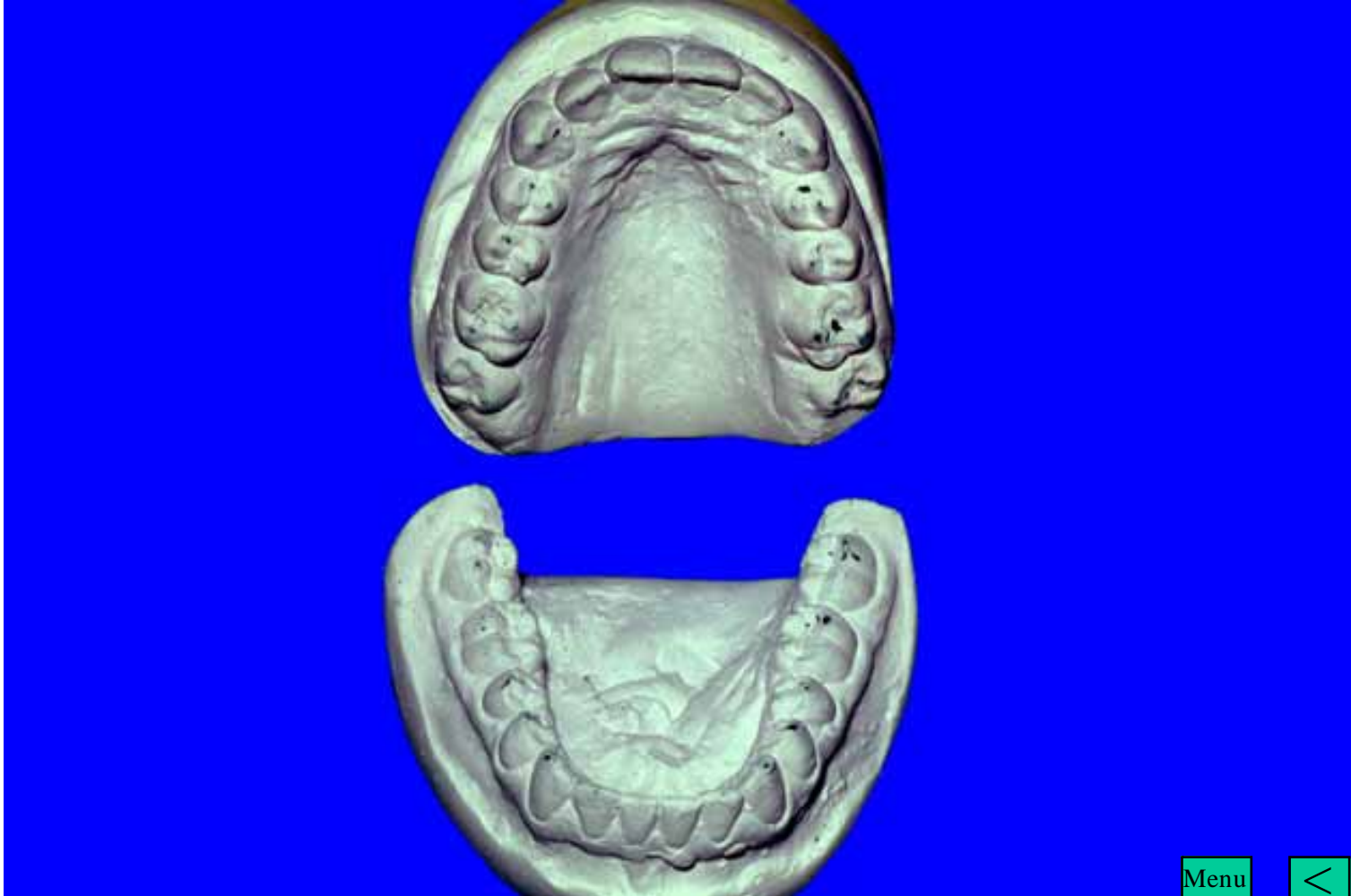





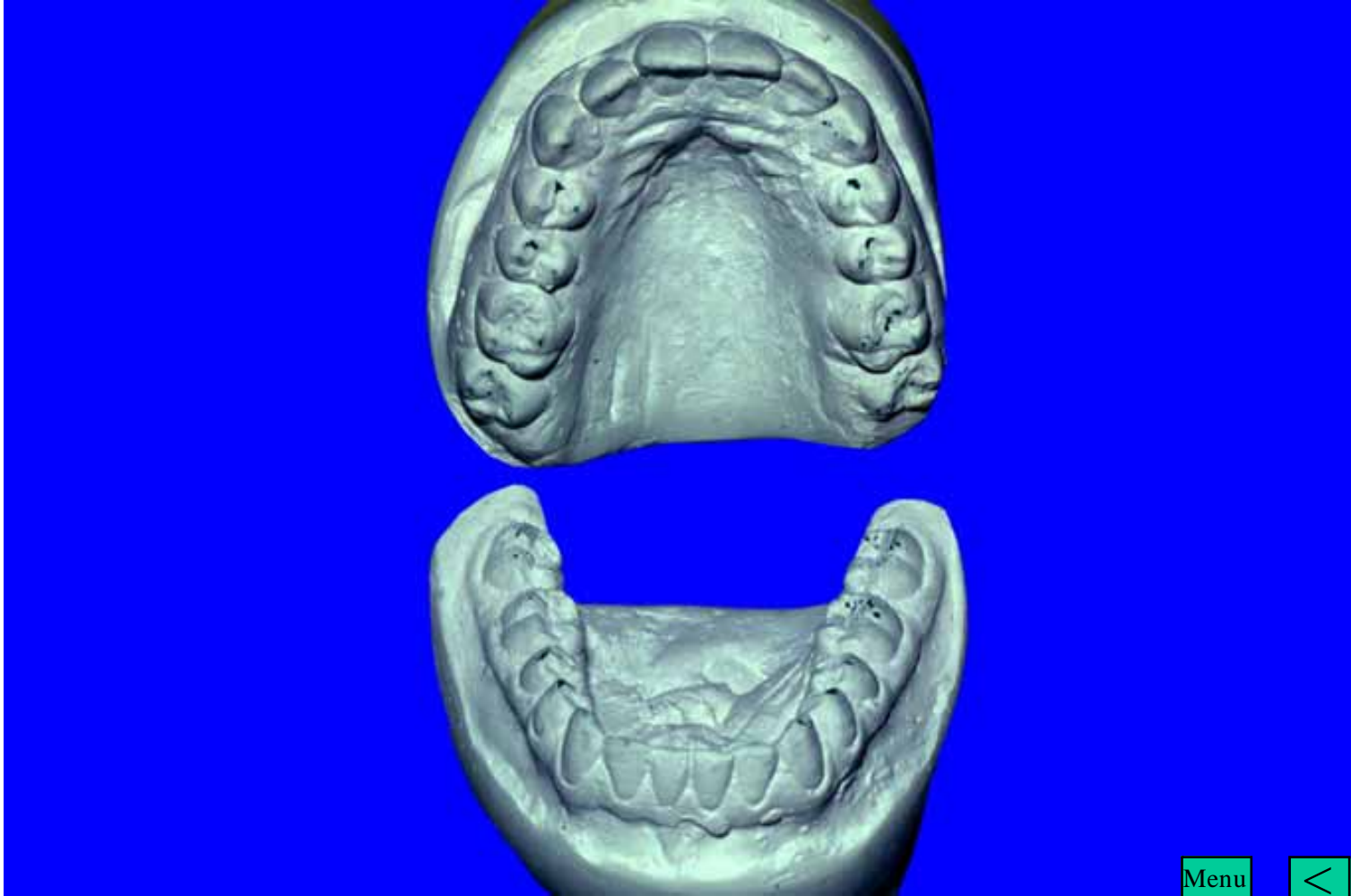
Menu





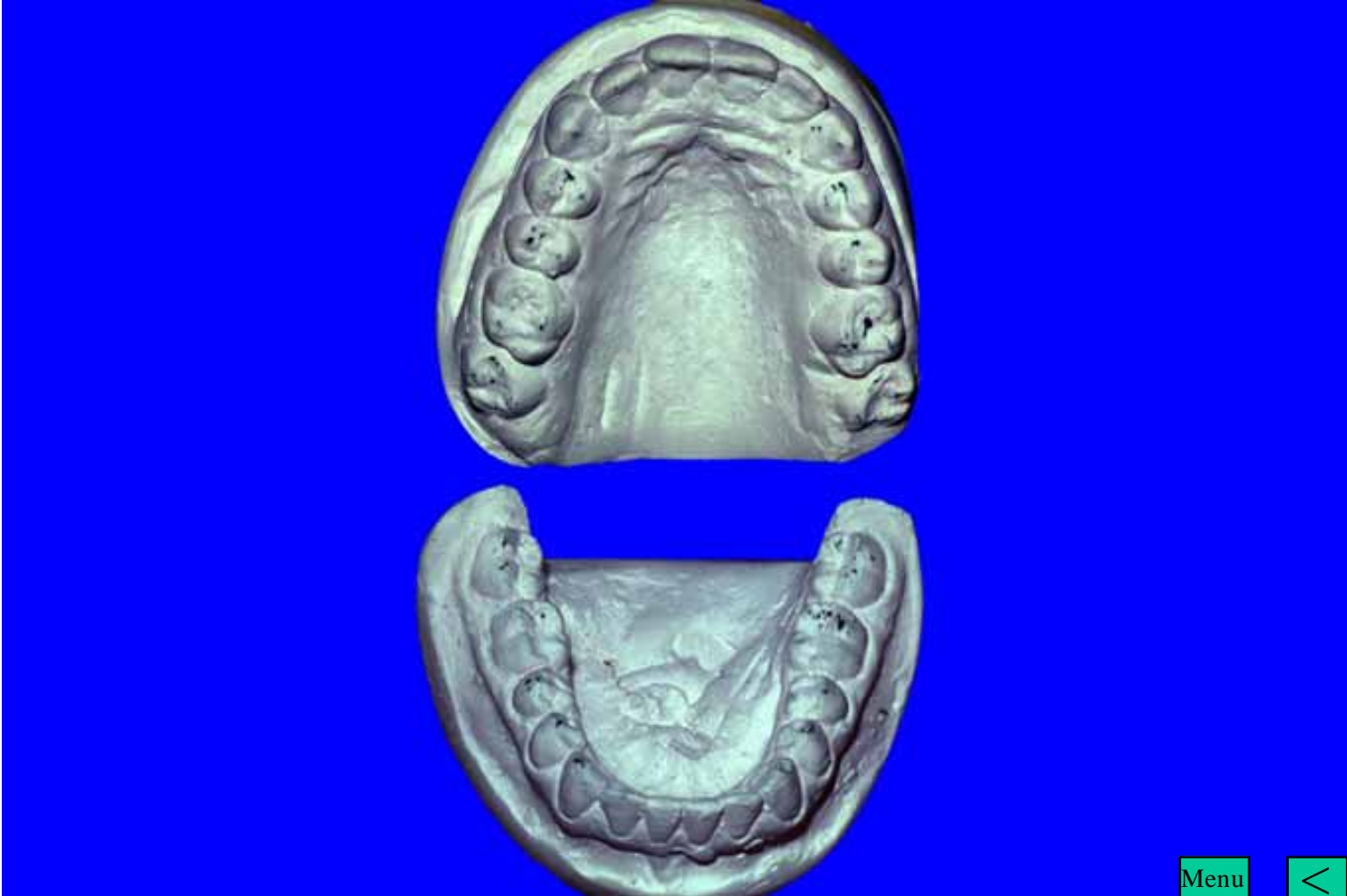
Menu





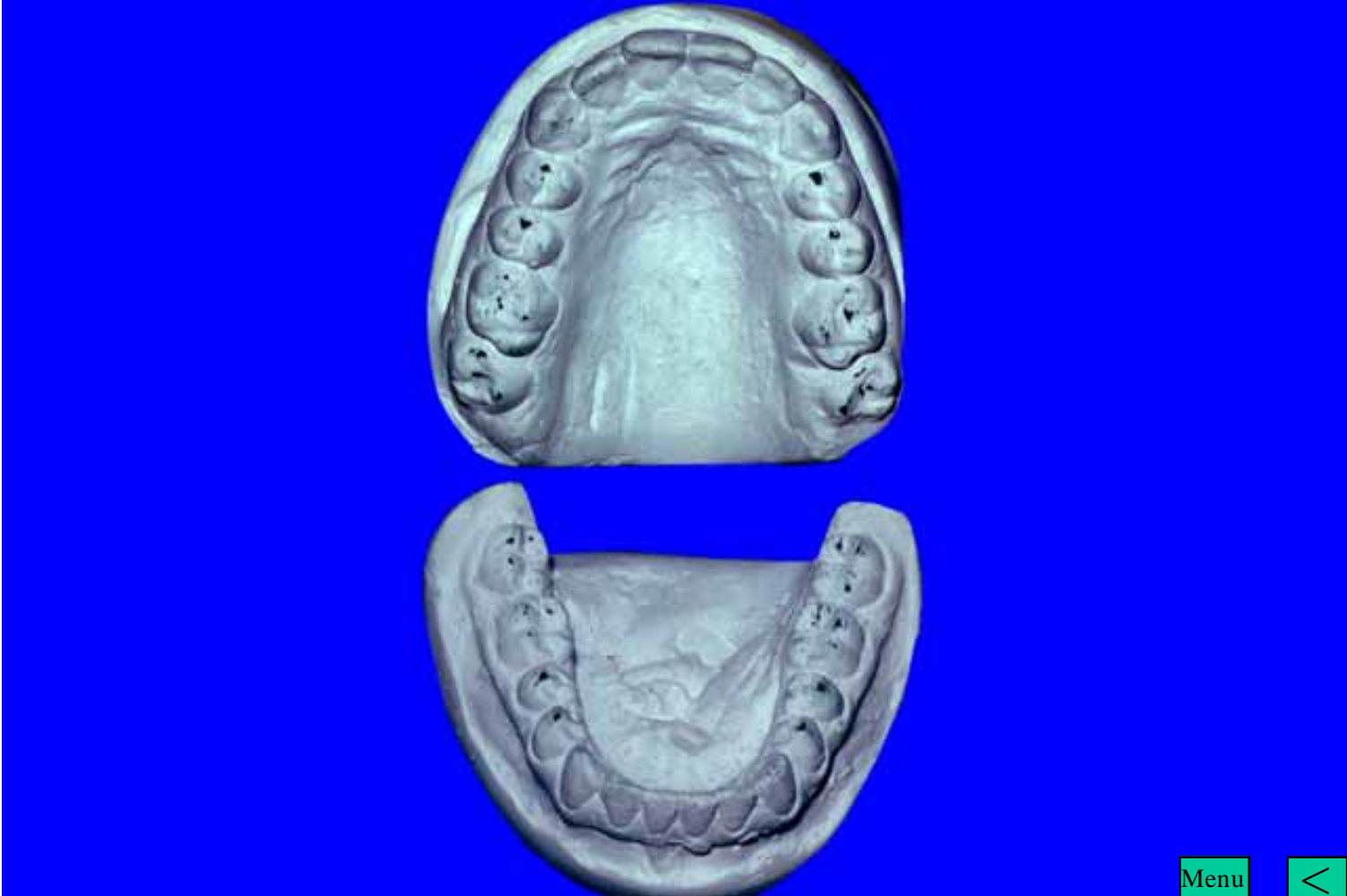Menu





Menu

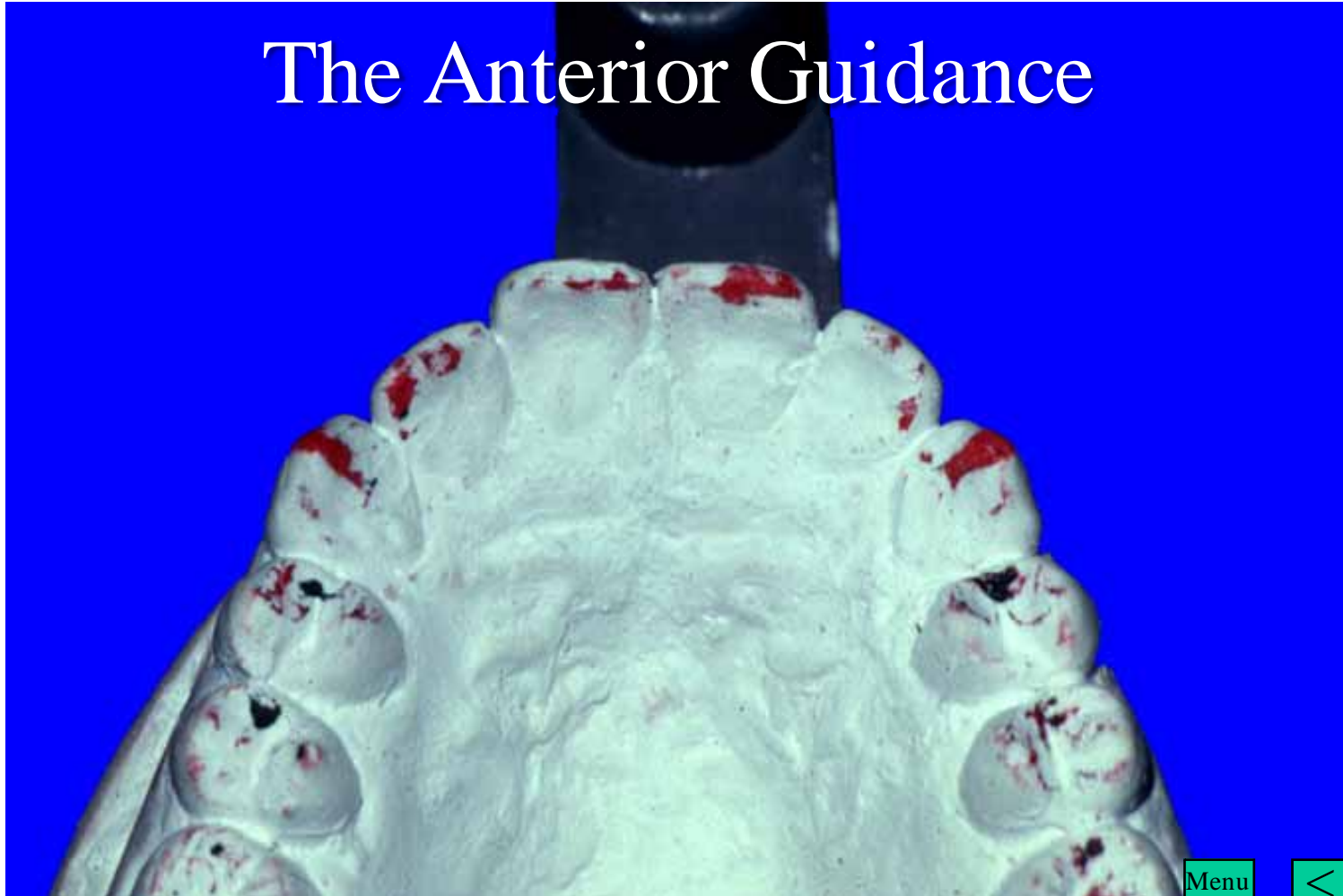




Menu

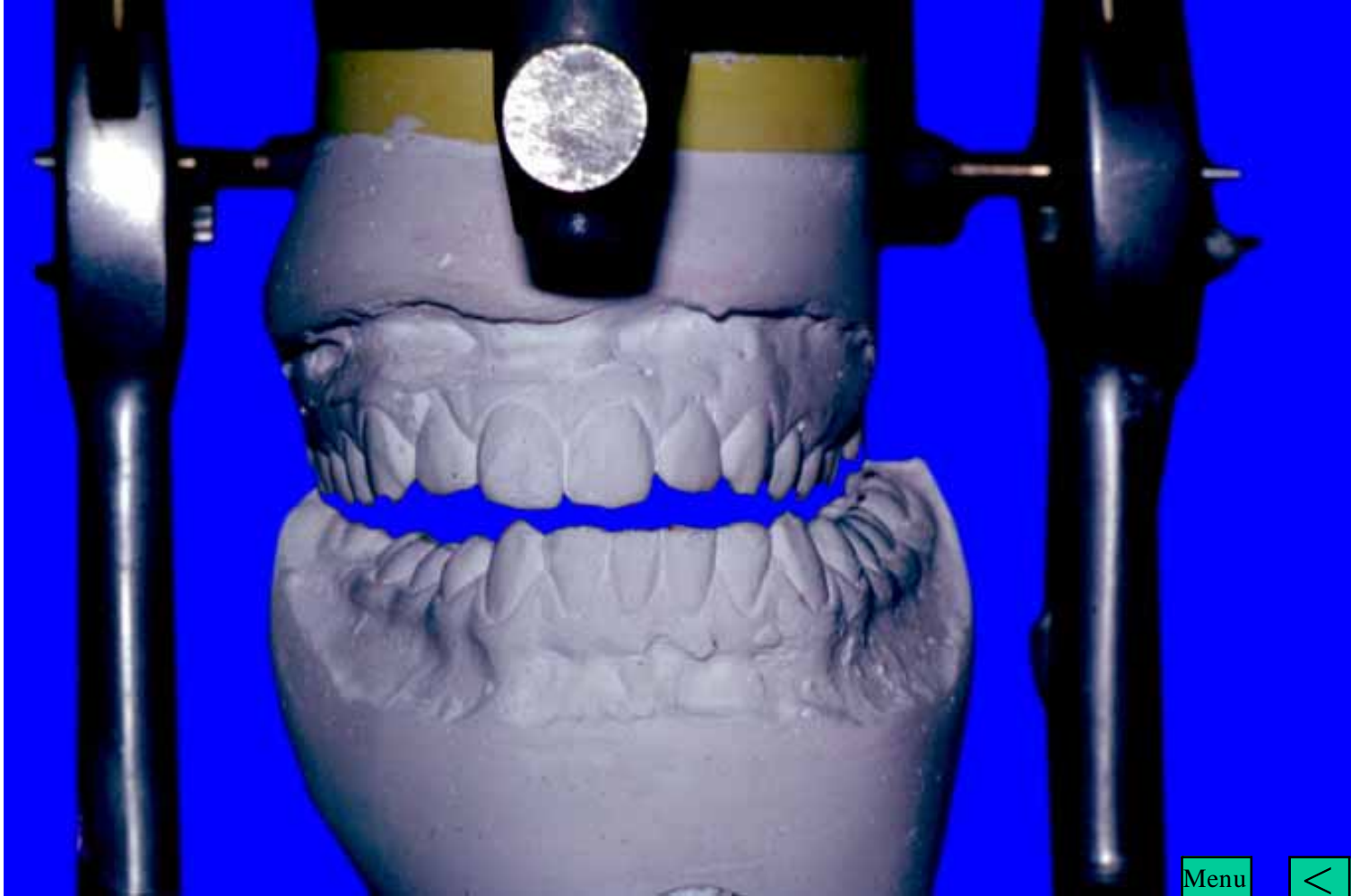


# The Anterior Guidance



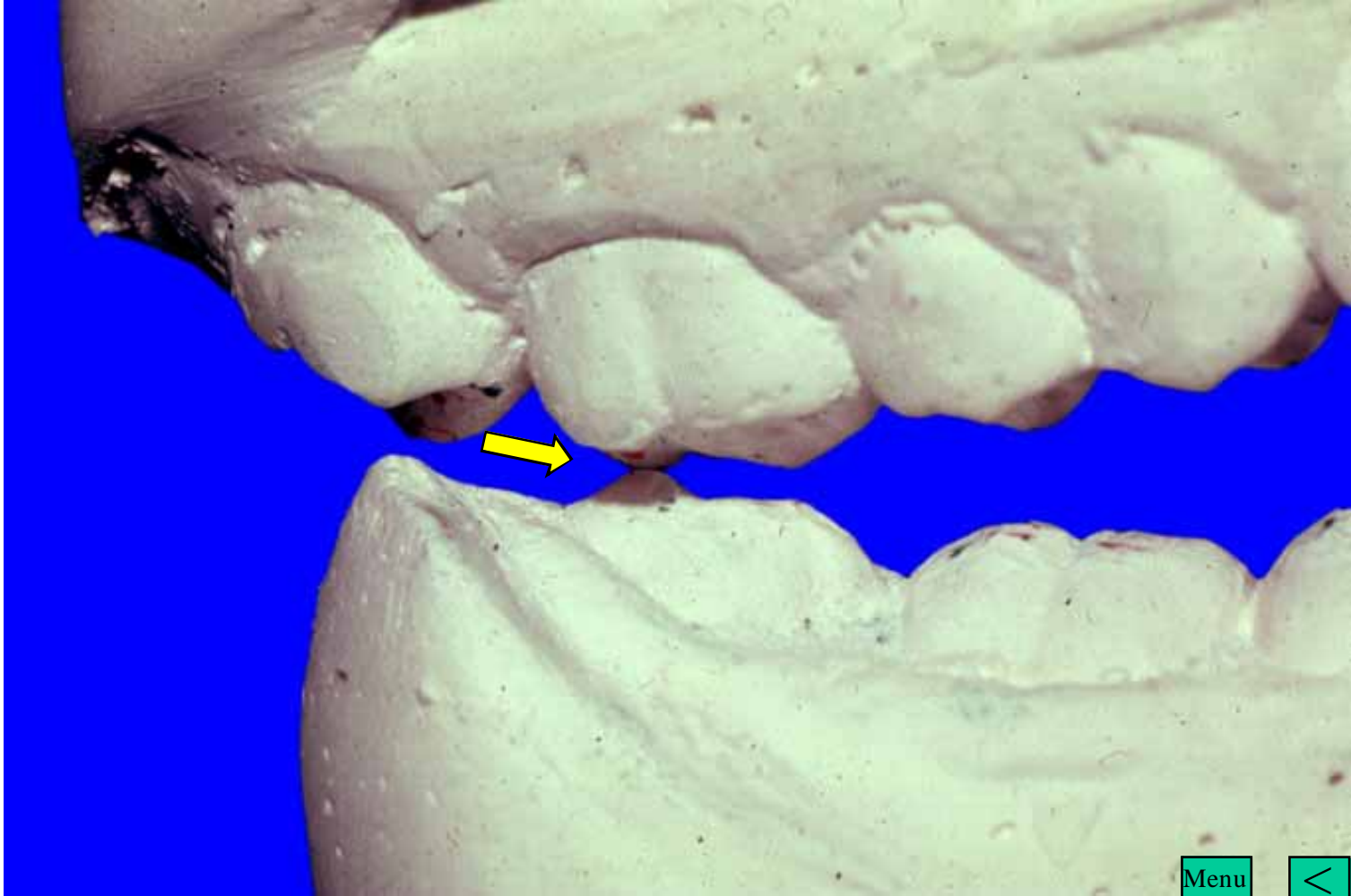
Menu





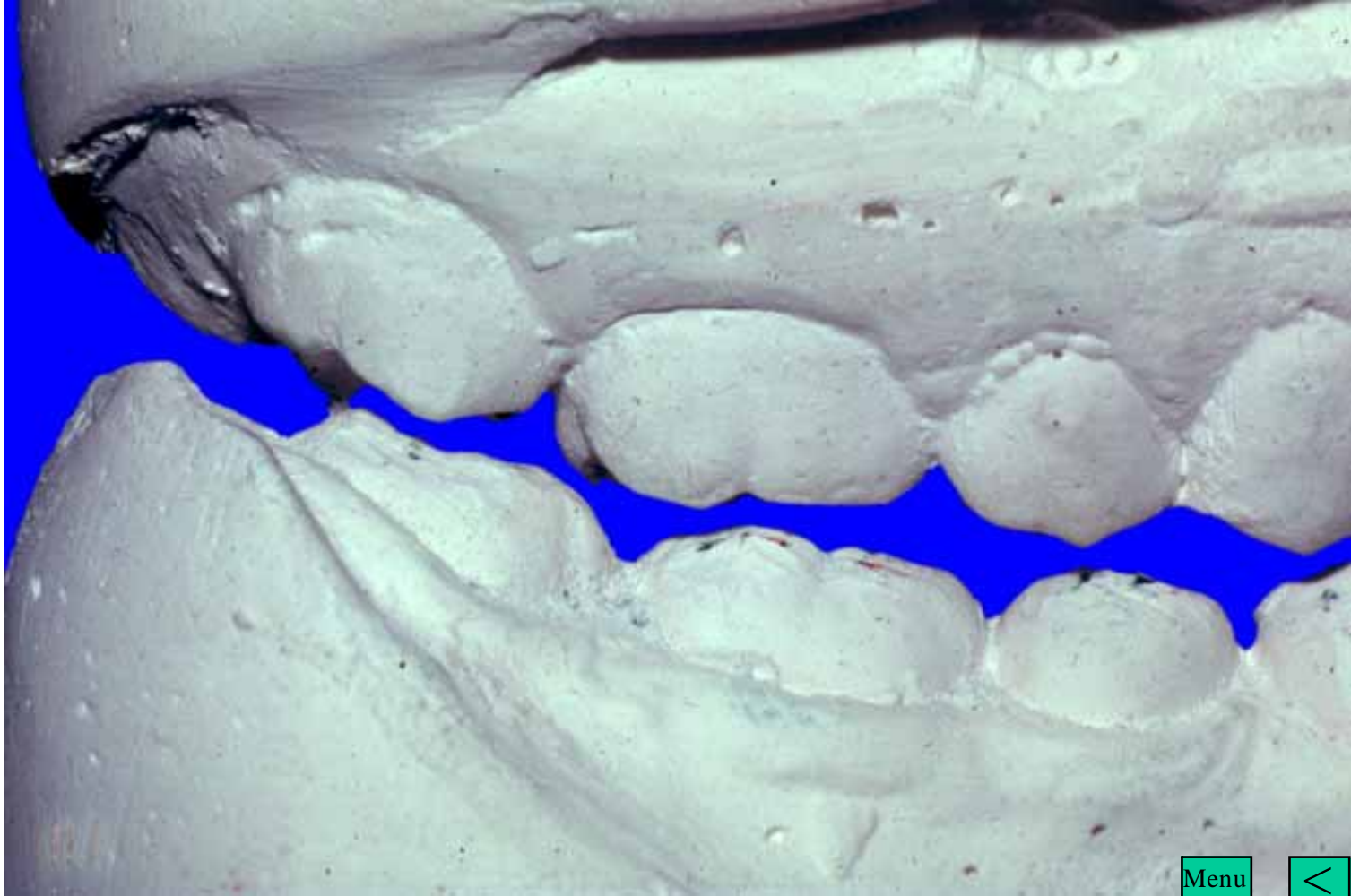
Menu

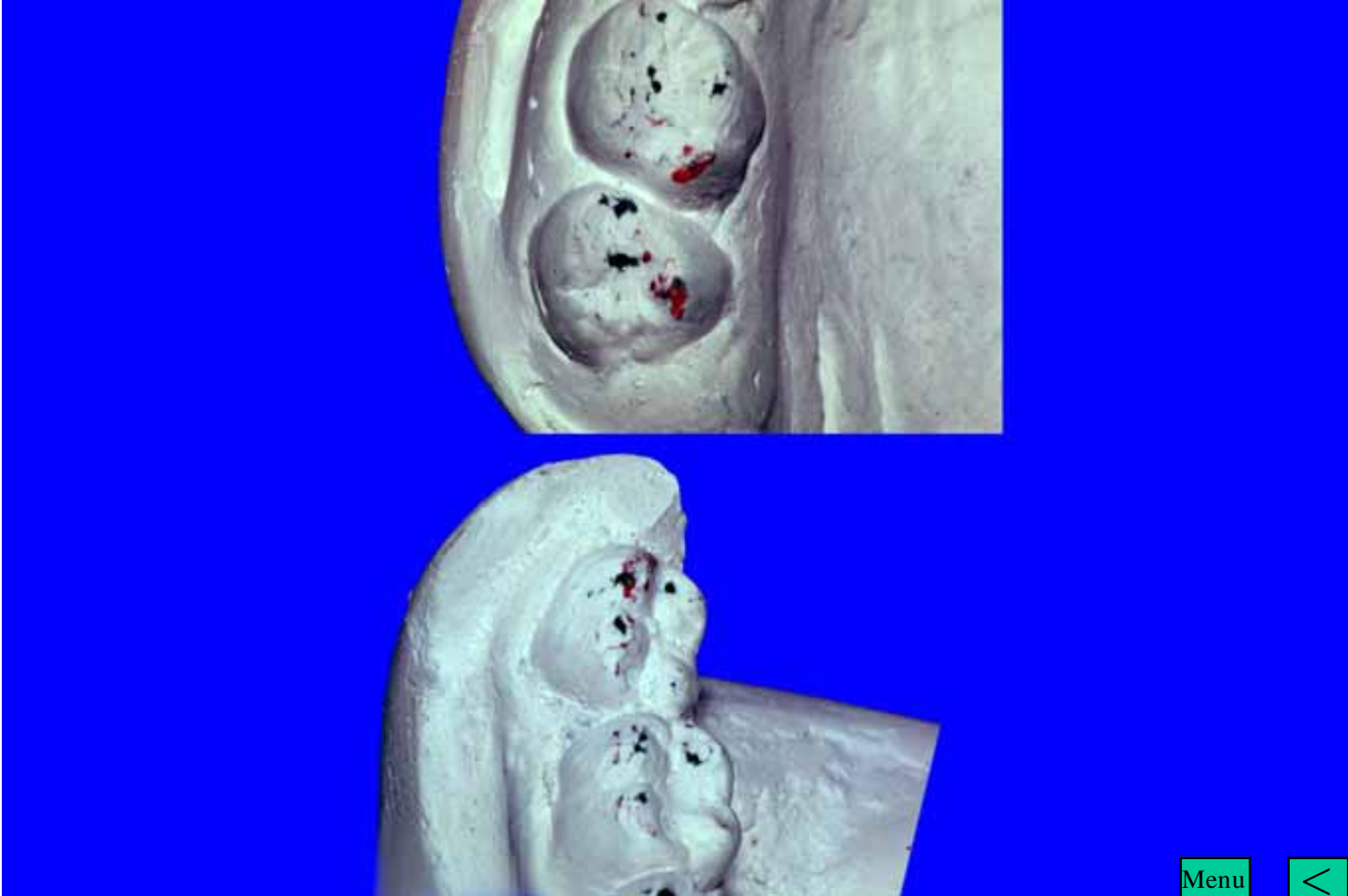


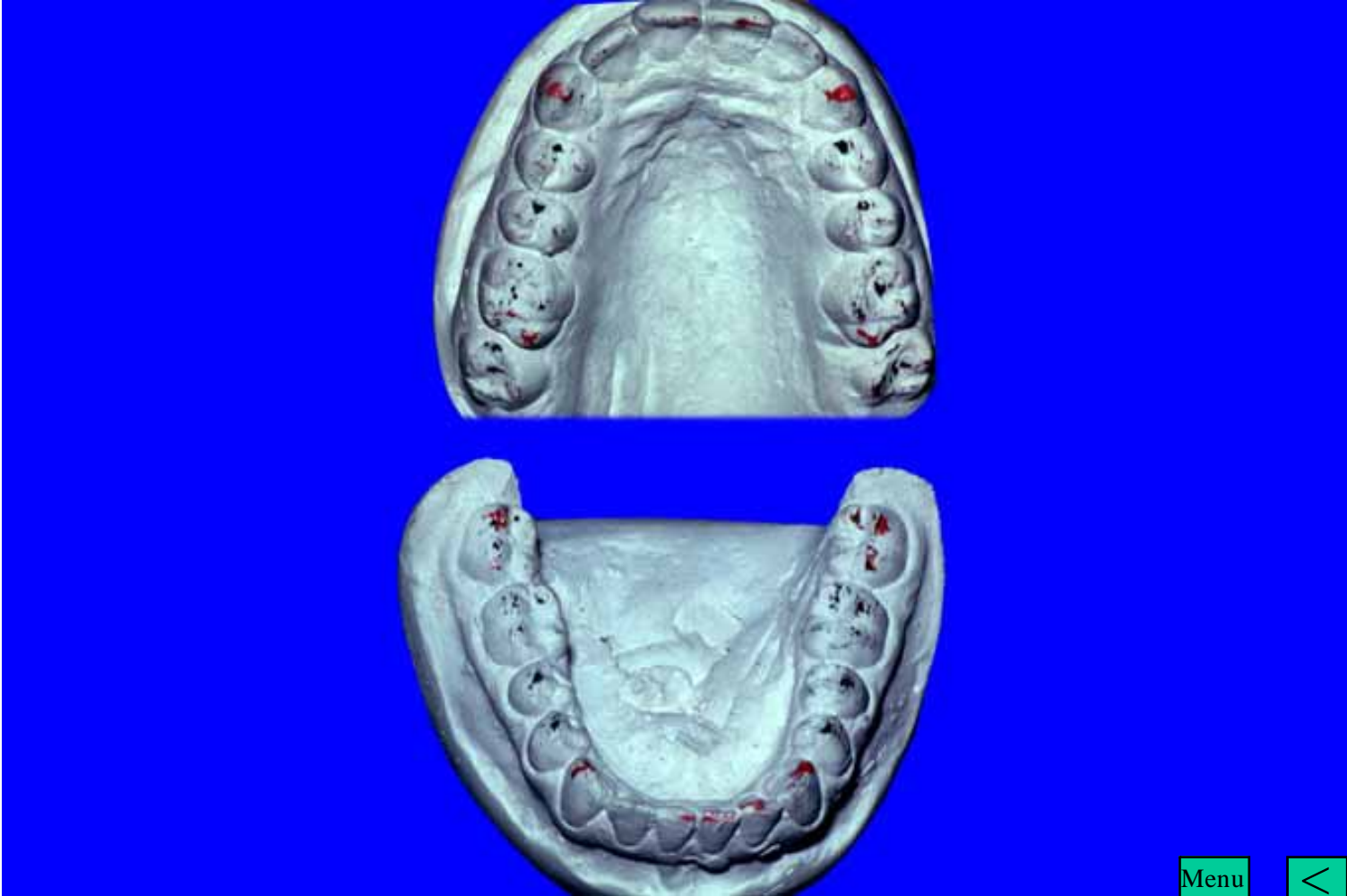

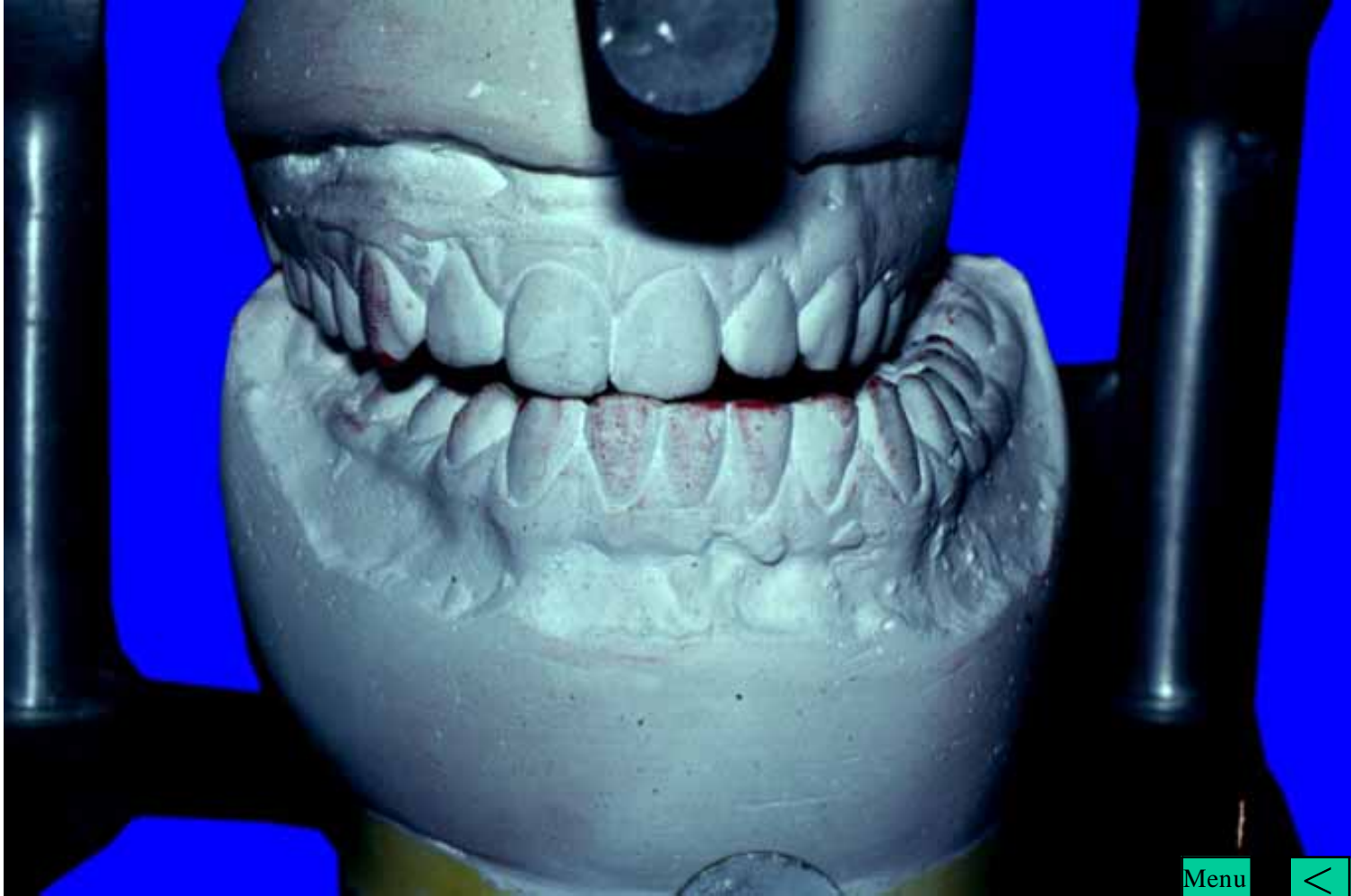
Menu





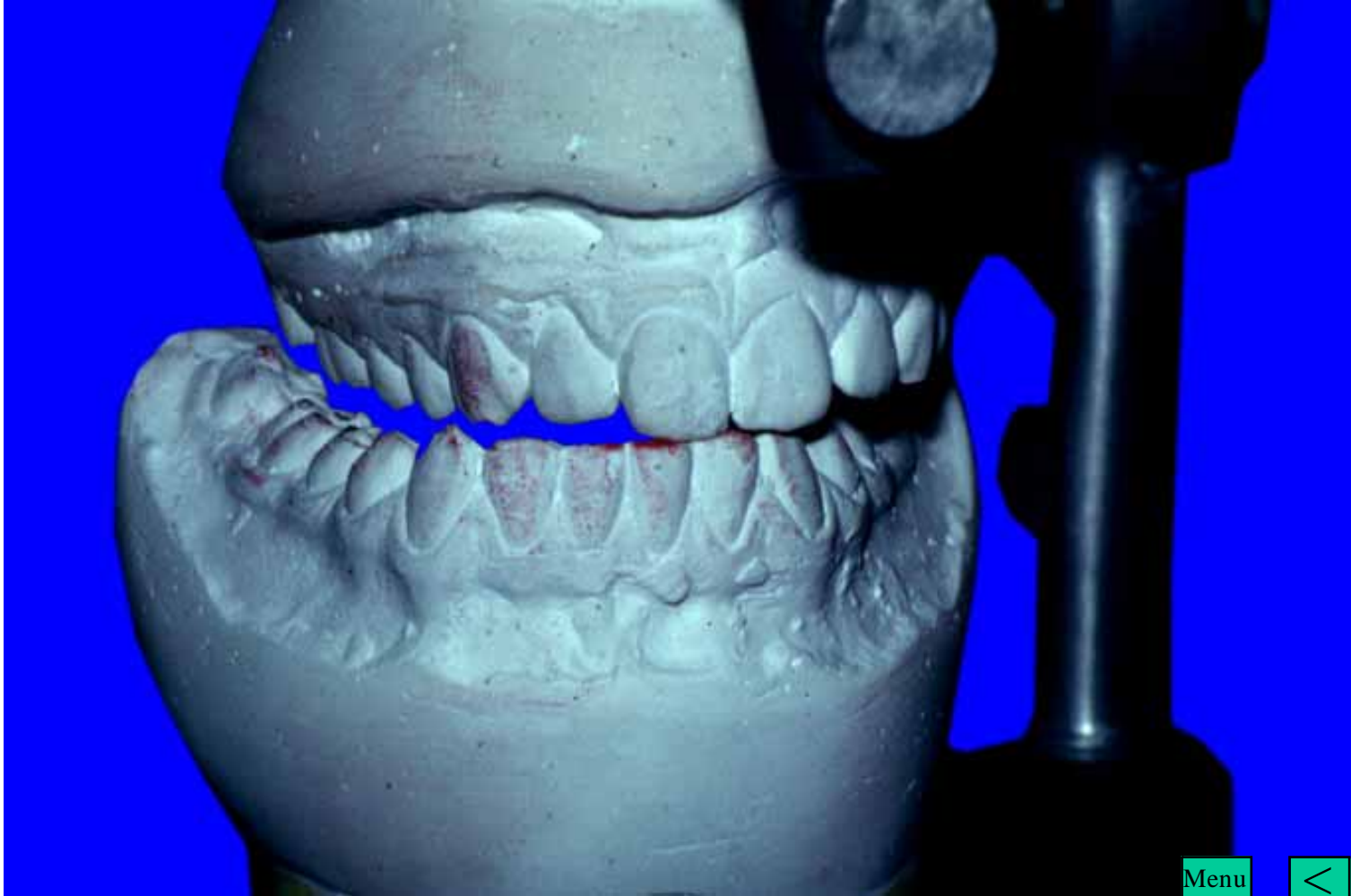






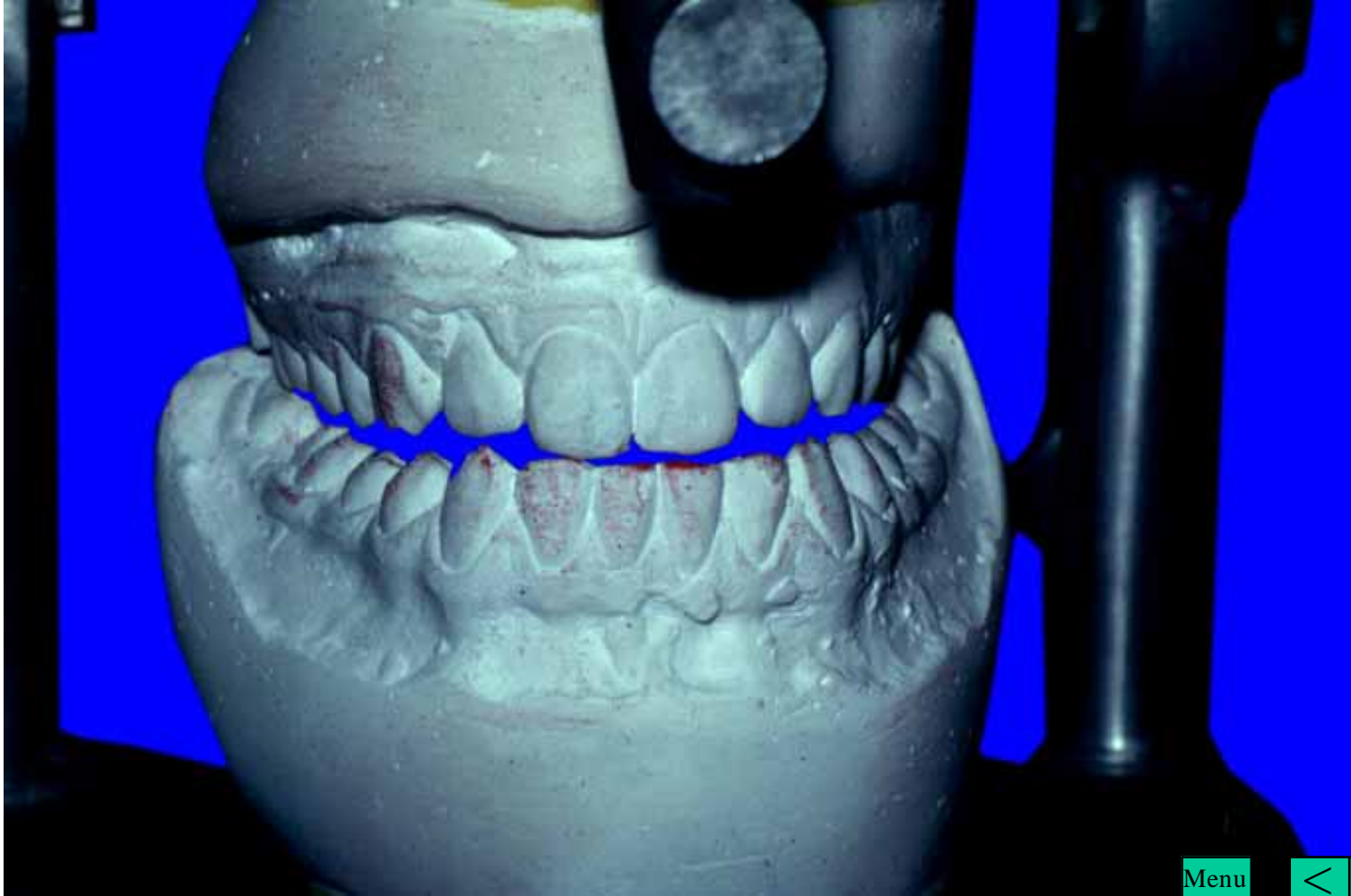
Menu





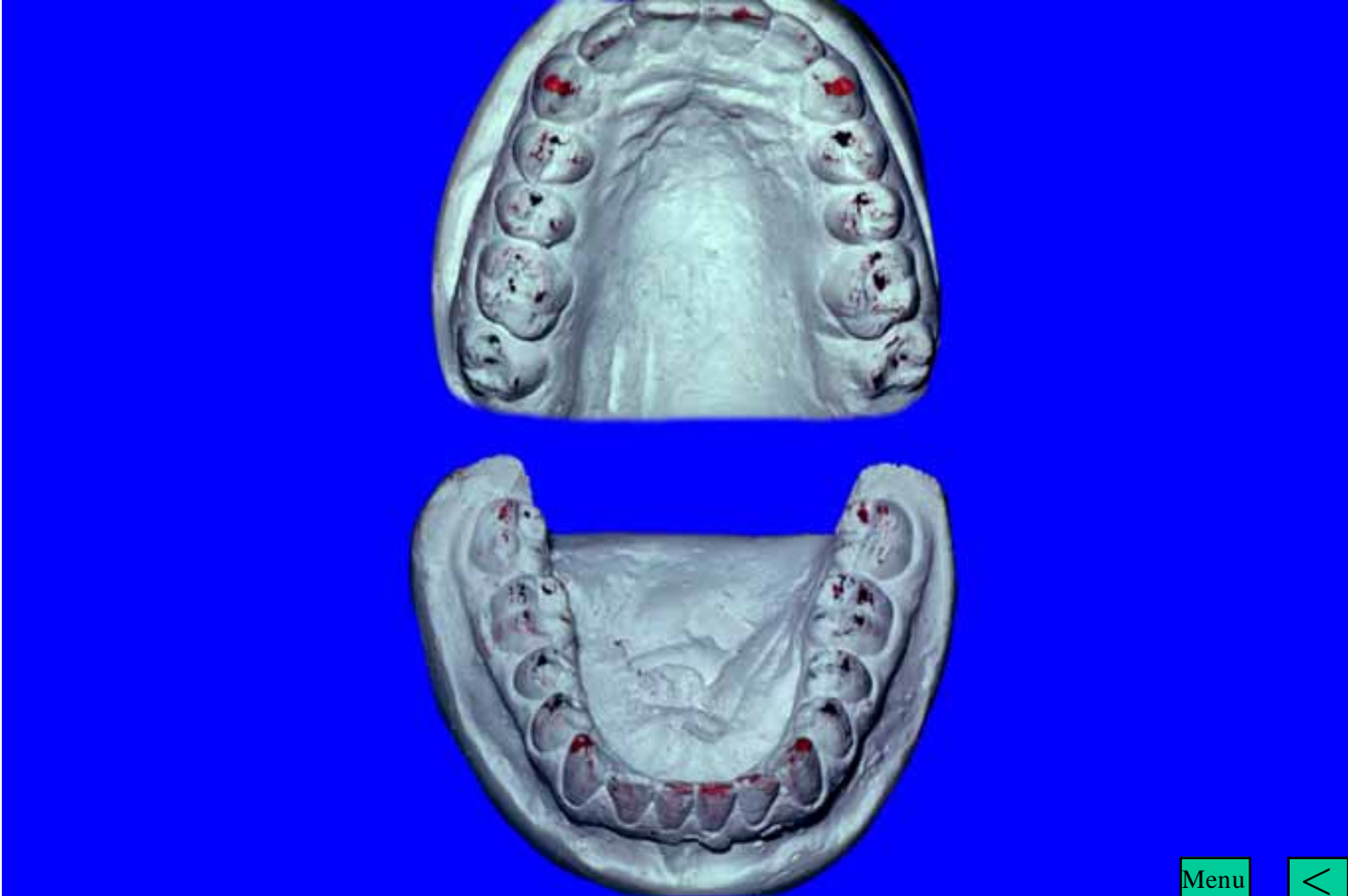
Menu

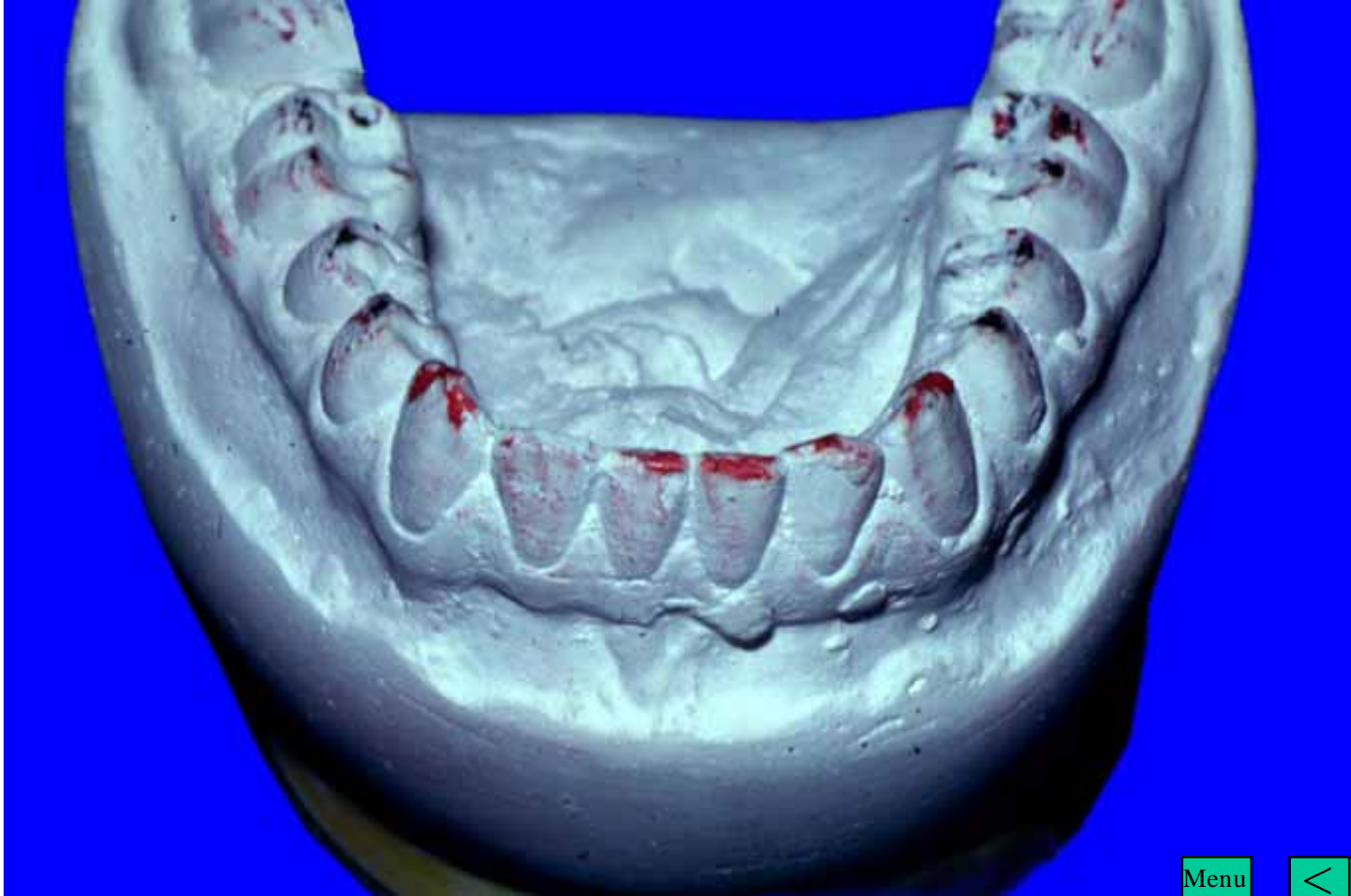



Menu

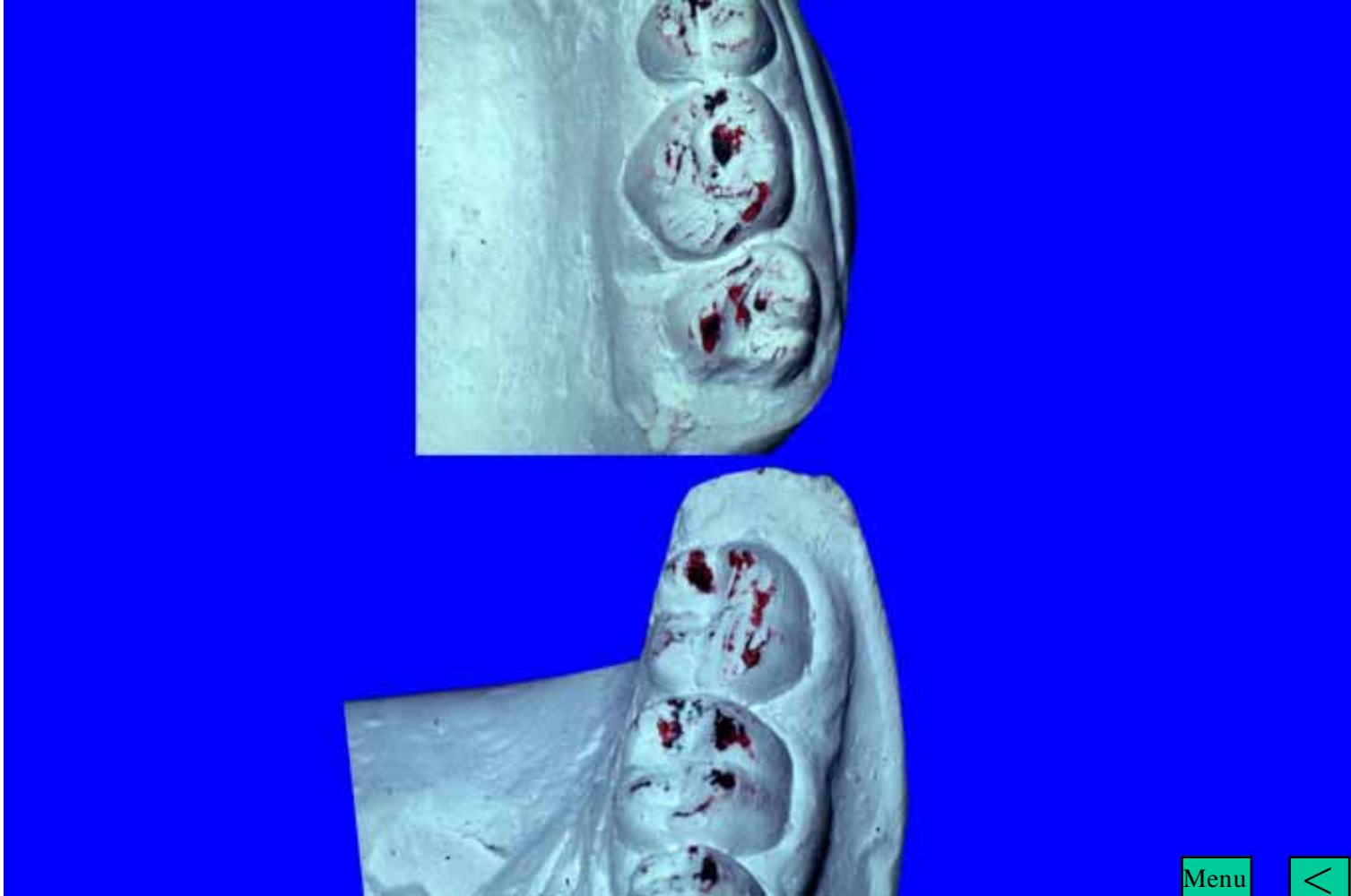






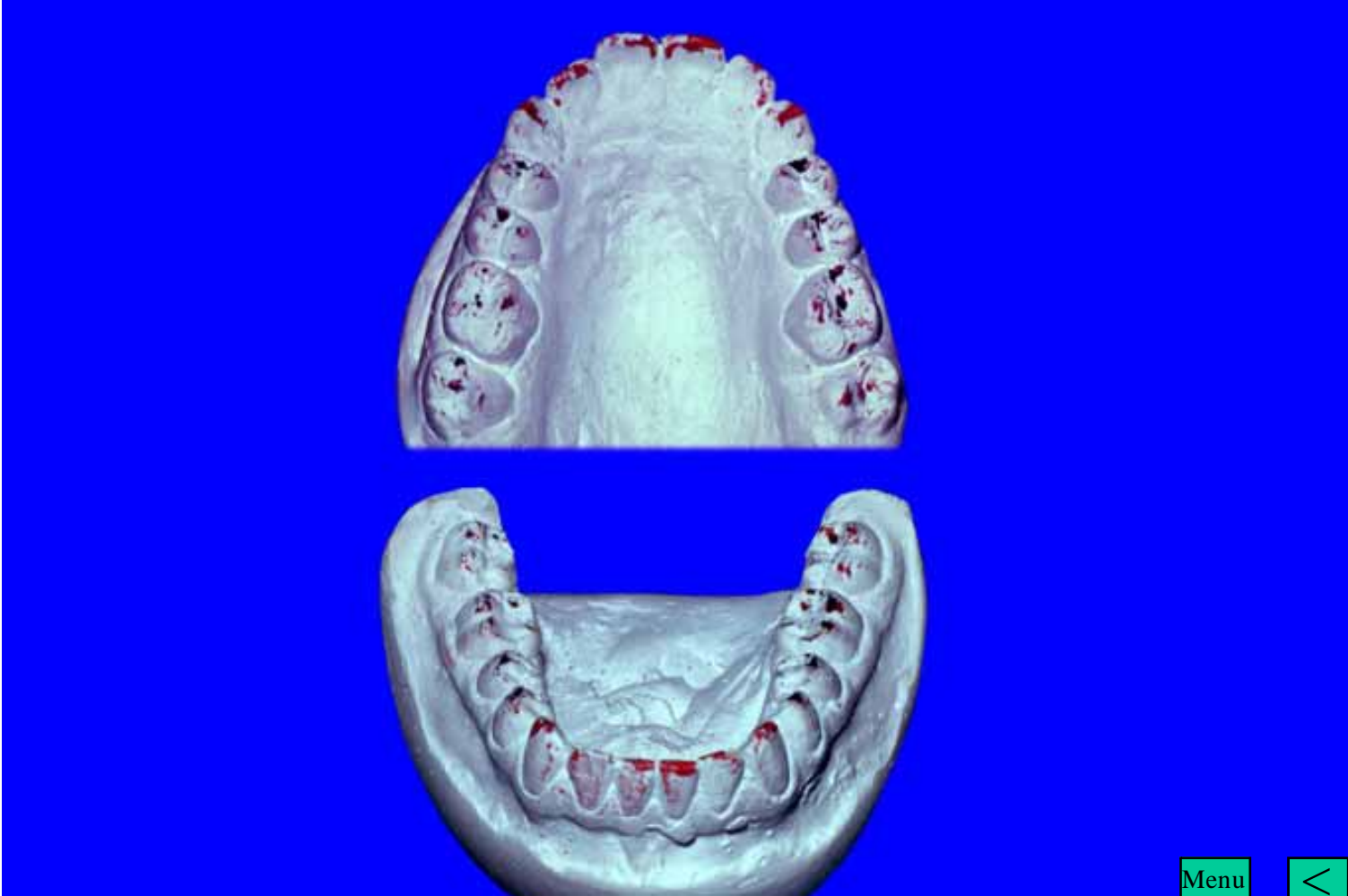
Menu





Menu

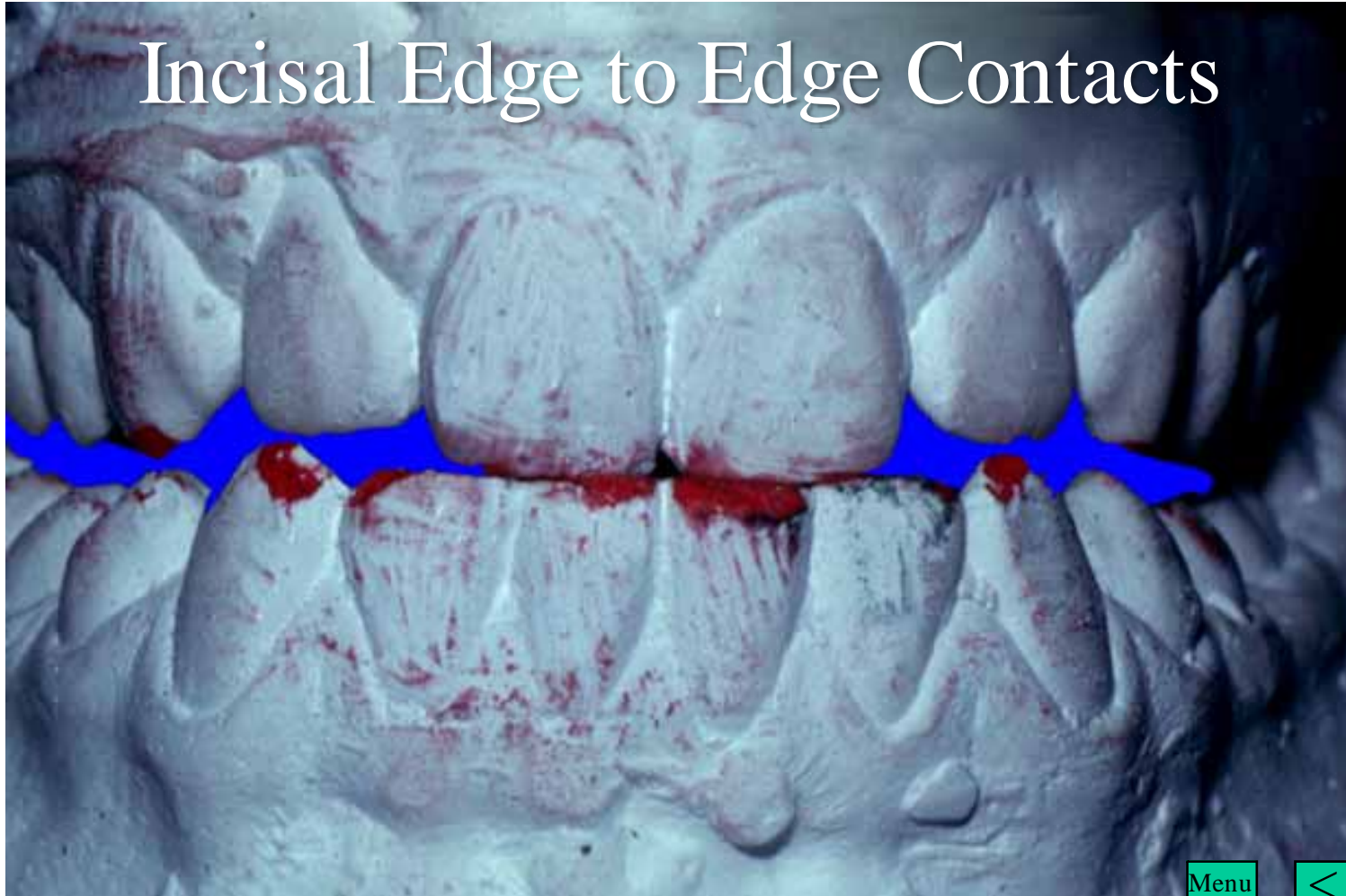




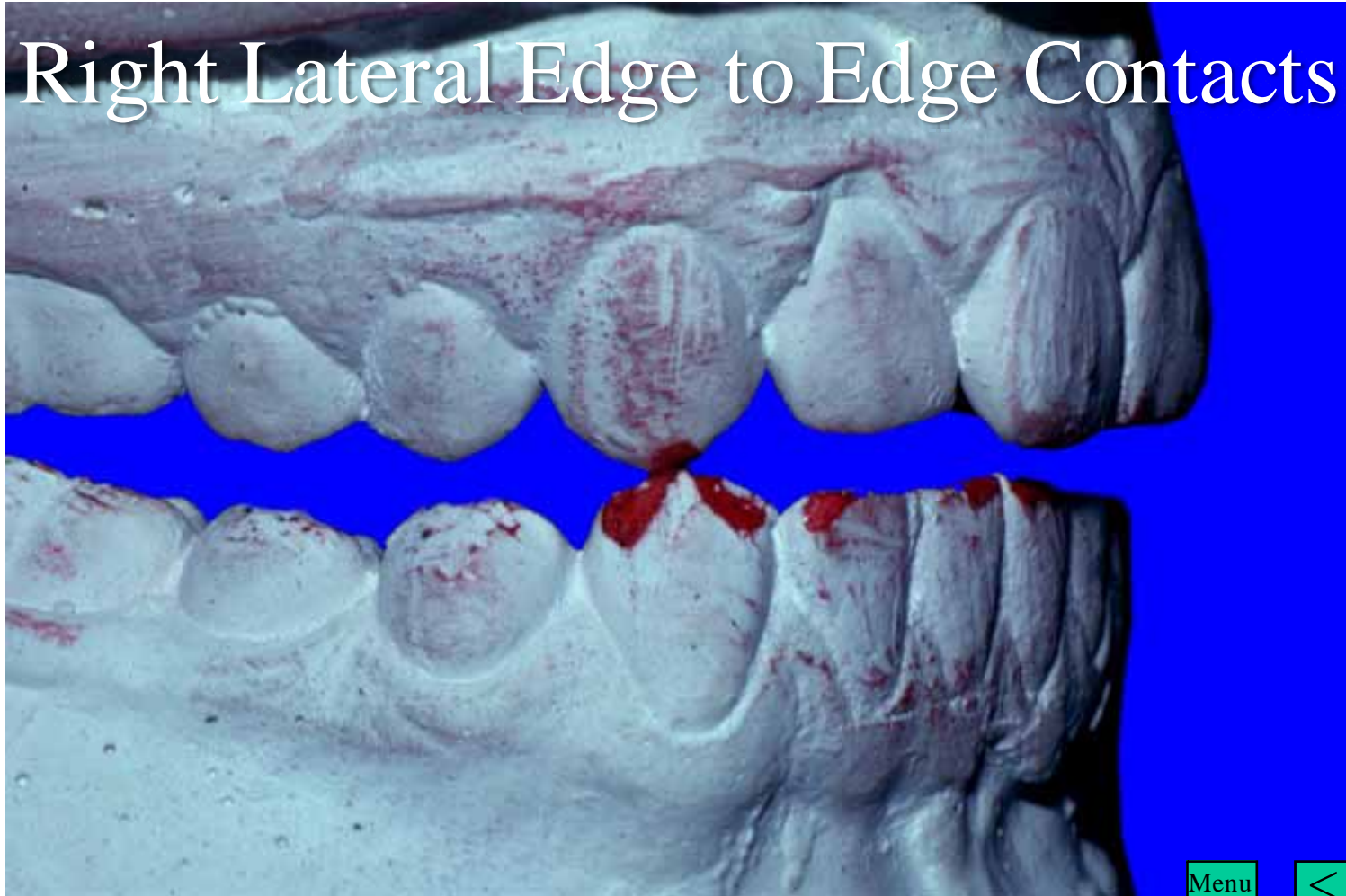
Menu



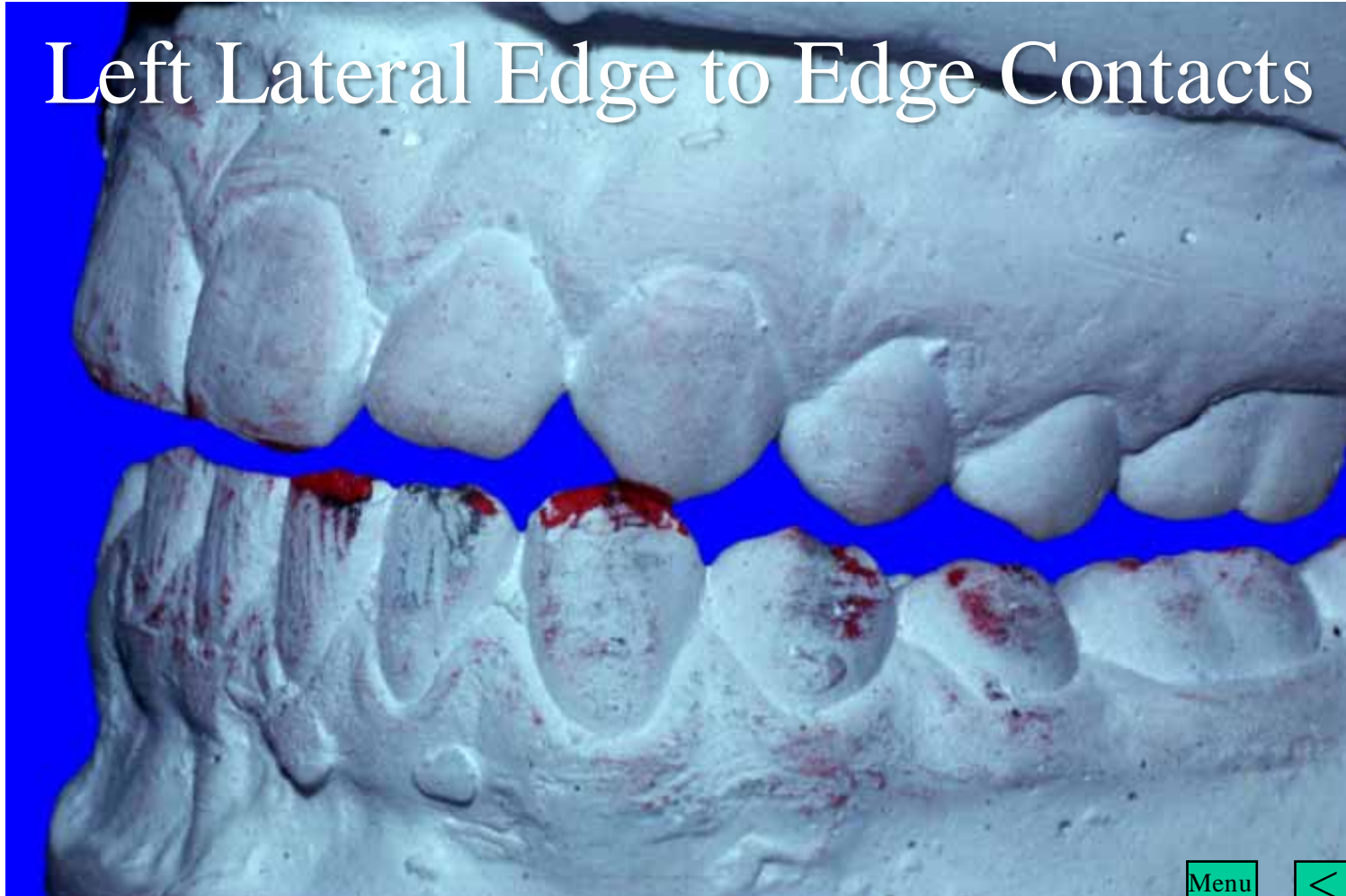
# Incisal Edge to Edge Contacts



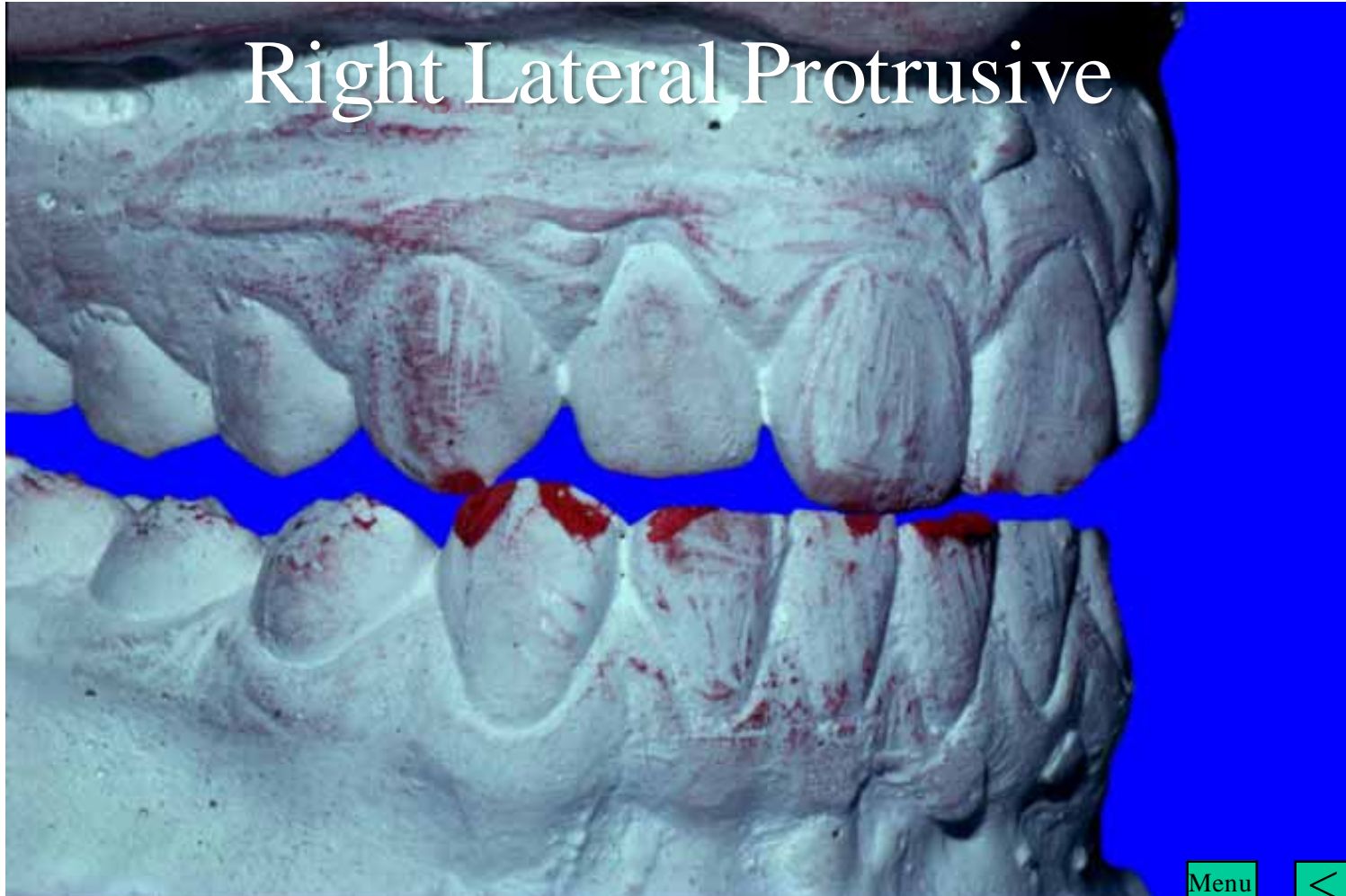
# Right Lateral Edge to Edge Contacts



# Left Lateral Edge to Edge Contacts



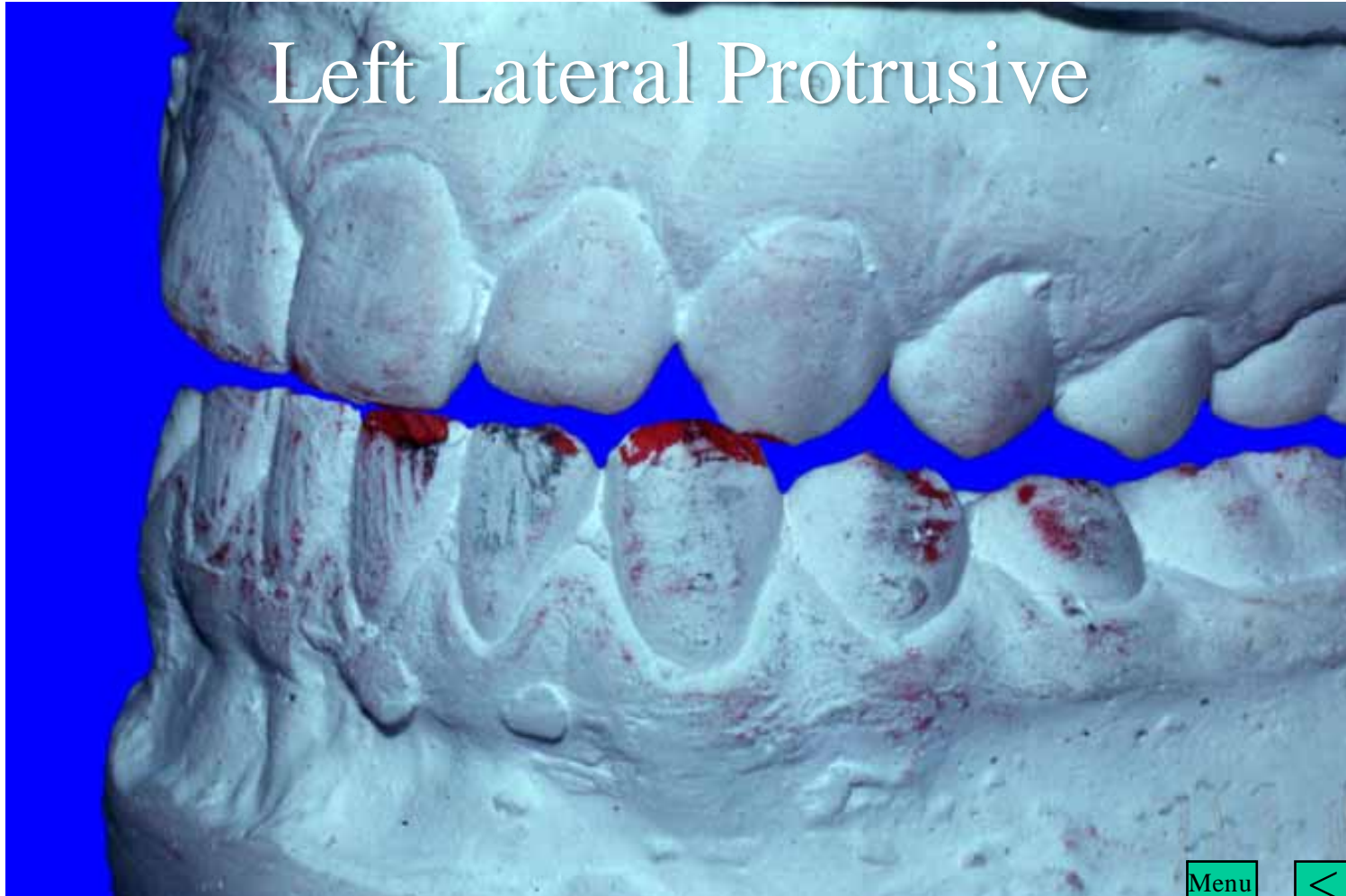
# Right Lateral Protrusive



Menu



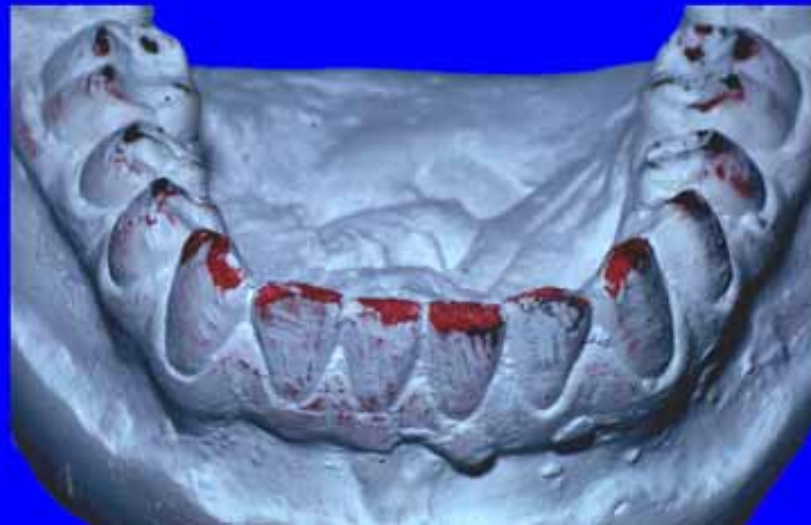# Left Lateral Protrusive



Menu

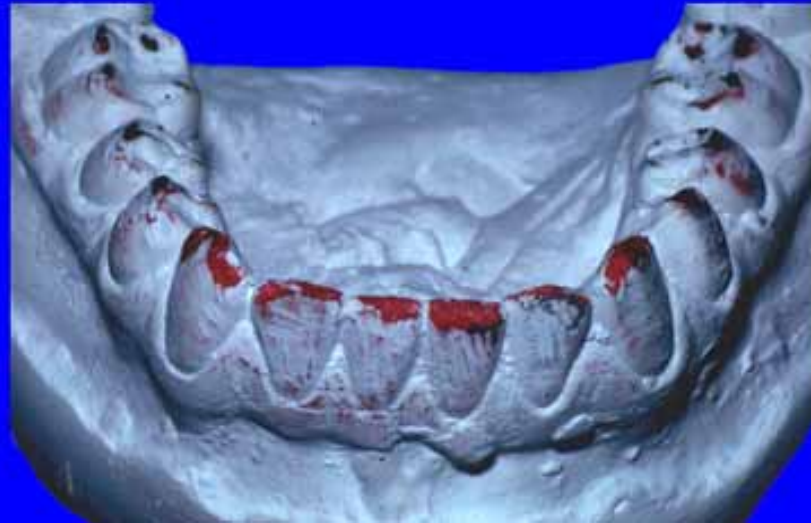

# Incisal Guidance



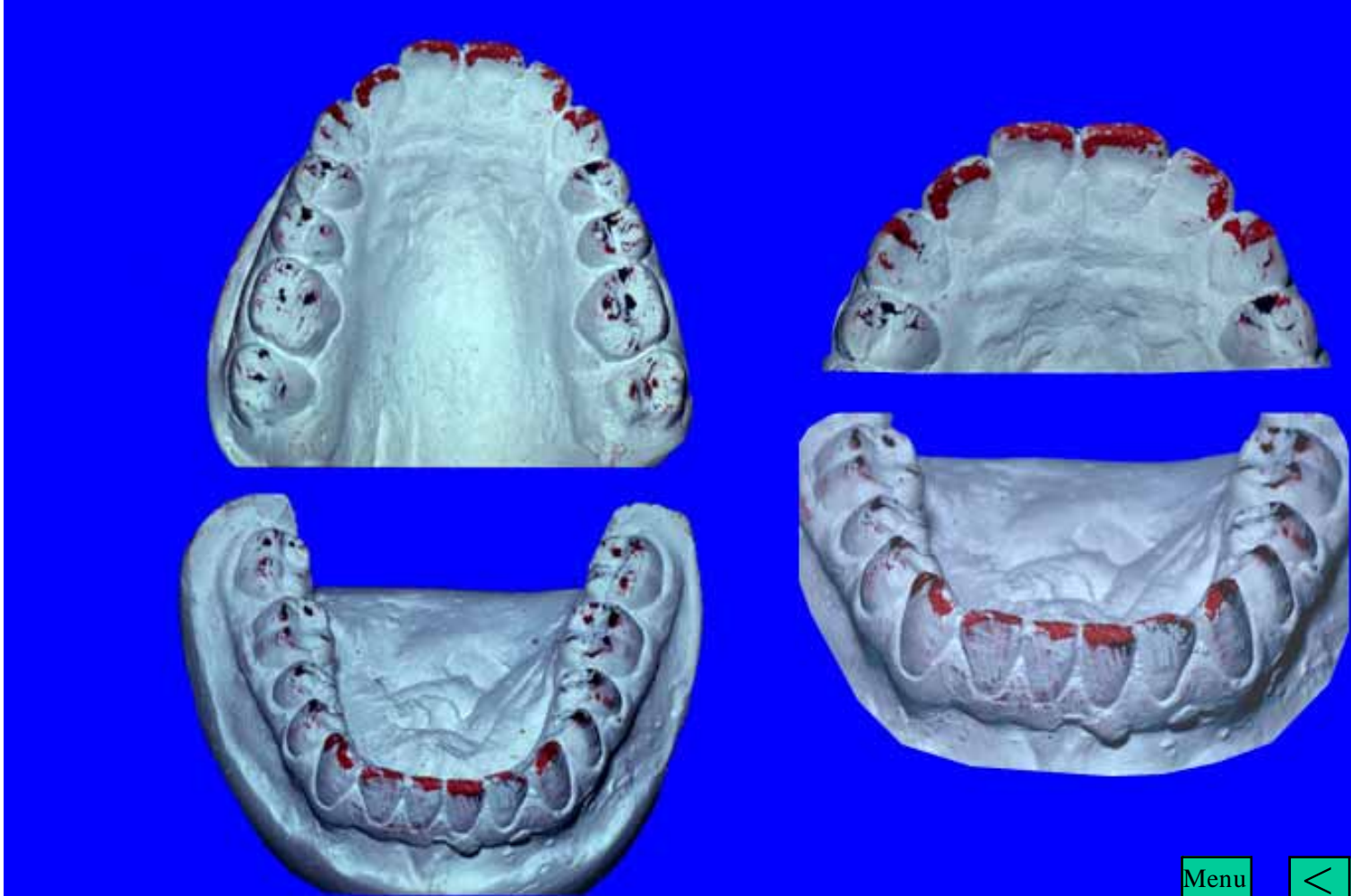
Menu





Menu





Menu



The End