

Occlusion Manual

**Occlusion for all Aspects of Dentistry
Treatment of Headaches
Temporomandibular Joint Problems
and
Appliance Therapy**

Stuart Orton-Jones

33 High Street Harpole Northampton NN7 4DH,
UK

Website sojinstitute.co.uk

Email stuart@sojinstitute.co.uk

Telephone 0044 (0)1604 832399

Fax 0044 (0)1604 832867

Table of Contents

HOW THE JAWS WORK.....	3
THE PRINCIPLES OF OCCLUSION FOR NATURAL AND RESTORED DENTITIONS.....	10
EDGE TO EDGE CONTACTS.....	11
EXCEPTIONS TO THE PRINCIPLES OF OCCLUSION	12
FACEBOW REGISTRATION FOR THE ARTEX SEMI-ADJUSTABLE ARTICULATOR.....	15
MOUNTING LOWER MODELS.....	19
OCCLUSAL EXAMINATION OF STUDY MODELS	22
OCCLUSAL PLANNING.....	26
OCCLUSAL MANAGEMENT	27
GENERAL SCREENING.....	36
CLINICAL OCCLUSAL EVALUATION FORM FOR PATIENTS.....	38
CLINICAL OCCLUSAL ADJUSTMENT PROCEDURE	40
MOUNTING MODELS ON AN ARTICULATOR.....	42
POSSIBLE EFFECTS OF OCCLUSAL DISHARMONY	47
TEMPOROMANDIBULAR JOINT AND OCCLUSAL EXAMINATION SHEET.....	49
ANALYSING AN OCCLUSION.....	50
CLINICAL OCCLUSAL ADJUSTMENT PROCEDURE	57
ANTERIOR REPOSITIONING APPLIANCES.....	59
RECOMMENDED READING.....	60
CRITIQUE FORM.....	61

How the Jaws Work

The Upper and Lower Jaws

The Jaw Joint

The Teeth

The Neuromusculature

Bruxing and Clenching influenced by life stresses

The Anatomical of the Jaws

The jaws are made up of a lower jaw, an upper jaw, and two joints including two articular discs, the ligaments and muscles associated with the jaws and when present teeth attached to the jaws.

The lower jaw is made up of the symphysis at the front, a body of the mandible and an ascending ramus with a Condyle and Coronoid Process each side.

The upper jaw is made up of the premaxilla, the posterior maxilla, and the palate.

The **bony components of the jaw joints** are made up of the heads of the condyles, the fossae and the articular eminences.

The **soft tissues of the joints** are made up of the cartilaginous covering of the head of the condyle, the cartilaginous covering of the fossae and the eminences.

In healthy joints, cartilaginous **articular discs** are present between the heads of the condyle and the fossae and eminences.

At the back the disc is attached to the neck of the condyle below and the edges of the fossae above.

Attached to the Lower jaw and base of the skull are various ligaments.

The purpose of ligaments is to allow two or more bones to move in relation to each other within a certain range.

The jaw muscles are attached to the lower jaw, the articular discs and to the upper jaw and bones of the skull. They move the lower jaw and disc.

The teeth may be present in the upper and lower jaws.

The Movements of the Lower Jaw

The lower jaw is moved by the jaw muscles. The movements of the lower jaw are limited by the anatomy of the jaw joint, the ligaments and the teeth if present.

The shape of the fossae and eminences of the jaw joints affects the direction that the jaw moves. This is known as the condylar path. This affects the degree of

separation of the back teeth if any

Jaw Joint Guidance

The flatter the path that the condyle moves from the fossa down the eminence the lesser the degree of separation, if any, of the back teeth will be.

The steeper path that the condyle moves from the fossa down the eminence the steeper the condylar path will be and the greater the degree of separation, if any, of the back teeth will be.

The presence of teeth restricts the movement of the lower jaw in a vertical, lateral and forwards movement.

The teeth, if present, restrict the movement of the lower jaw in a vertical, lateral and forwards movement.

The True Hinge Position

On opening the jaw the mandible first hinges in the fossa. As the jaw moves forward or to the side, the head of the condyle moves from the hinge position passing down the articular eminence.

When the head of the condyle moves from the fossa and passes down the articular eminence it is said to be translating.

The Clinical Definition of the True Hinge Position.

The true hinge position in a healthy jaw joint in which the head of the condyle hinges, without any translation. If the jaw joint is in a pathological state due to swelling in the joint, damage to the articular disc or damage to the bones around the joint the head of the condyle may not be in the true hinge position.

The hinge position is an unstrained position.

When the head of the condyle is in true hinge position the head of the condyle may be retruded posteriorly. It is then in the most retruded position but no longer in the true hinge position.

When the lower jaw is in the Hinge position, it is considered to be in Centric Relation

When the jaw is closed in the true hinge position one or more teeth may touch before the rest. These contacts are known as Centric Interferences.

The Anatomical Definition of the True Hinge Position.

The relationship of the mandible to the maxilla, when both condyles are in their most superior position in the fossa, irrespective of tooth contacts.

The False Hinge Position

The false hinge position is a pathological state in which the head of the condyle is not in the true hinge position due to pathological conditions such as inflammation of the joint. Swelling in the joint causes the head of the condyle to move downwards out of the fossa. This may result in back teeth coming out of contact.

The mandible may hinge but will not be hinging in the true hinge position. If damage to the posterior attachment of the disc has occurred, the disc may be positioned anteriorly to the head of the condyle when the jaw is closed. The disc will not be in its correct position on top of the head of the condyle. The jaw will be able to hinge but would not be considered to be hinging in the true hinge position.

Uses of the True Hinge Position

- (1) It is reliable reference position depending on the health of the jaw joint.
- (2) It is a starting point for restorative procedures. Observing tooth contacts when the lower jaw is in the true hinge position facilitates a decision as to whether any alterations are required to the tooth contacts before restorative dentistry is performed.

Arch Relationships and their relevant to Tooth Guidance

How the lower arch is positioned in relationship to the upper arch has an influence on which teeth guide the movement of the lower jaw. For reasons of discussion a classification of arch relationships is used. This is helpful as far as an overall discussion is concerned. It is not always helpful when considering individual cases.

A Class 1 molar relationship is considered to be when the mesio-buccal cusp of the upper first molar is in line with the buccal groove of the lower first molar.

A Class 11 molar relationship is when the lower molar is positioned more posteriorly to the upper molar.

When there is an overbite present it is considered to be a Class 11 Division 1 Relationship.

When the upper front teeth are tilted backwards and there is a deep overbite and no overjet it is considered to be a Class 11 Division 2 Relationship

A Class 111 molar relationship is considered to be when the lower first molar is further forward than the upper first molar.

There is a considerable range of possibilities of jaw relationships from an extreme Class 11 to an extreme Class 111. In the middle is the Class 1 relationship. An individual may be anywhere within these extremes.

The concept of Classification of Arch relationships has its uses and also its hazards.

A patient whose mandible is slightly distal to classical Class 1 relationship would be considered to be Class 1. At what point as the lower arch is further and further back is the patient considered Class 11. Alternatively a patient

whose mandible is slightly mesial to classical Class 1 relationship would be considered to be Class 1. At what point as the lower arch is further and further forward is the patient considered Class 111.

The risk is to put people in boxes rather than considering them as individuals.

Front Teeth Relationships

Classification of Front Teeth Relationships

The Problems of Classification of Front Teeth relationships

Maximum Intercuspitation

Maximum Intercuspitation is the relationship of the upper and lower arches when the teeth are in maximum tooth contact irrespective of the jaw relationship.

When the jaws are clenched together moderately firmly the lower teeth will close so that the maximum number of tooth contact.

The lower jaw may or may not be in the true hinge position depending on whether any interferences are present causing the lower jaw to move out of the true hinge position as the teeth slide into maximum intercuspitation.

Centric Relation Occlusion

When the teeth are in Maximum Intercuspitation and the jaws are in the True Hinge Position simultaneously this is known as centric relation occlusion.

Movements of the Lower Jaw away from the True Hinge Position

For discussion purposes there are terminologies that need to be understood. The description of the relevant terminology is as follows.

The Functional Side or Working Side

When the lower jaw moves to one side the side to which the jaw moves is considered to be the Functional Side or Working Side,

If the lower jaw moves to the left, the left side of the arches is considered to be the functional side or working side.

If the lower jaw moves to the right, the right side of the dental arches is considered to be the functional side or working side.

The Non-Functional, Balancing Side, or Non-Working Side)

When the jaw moves to one side, the Non-functional Side, Balancing Side or Non-Working Side, is the side of the dental arches away from which the lower

jaw has moved.

If the lower jaw moves to the left, the right side of the dental arches is the Non-functional Side, Balancing Side or Non-Working Side.

If the lower jaw moves to the right, the left side of the dental arches is the Non-functional Side, Balancing Side or Non-Working Side.

Eccentric Movements

All movements of the lower jaw, when it moves away from the true hinge position.

Eccentric Contacts.

Any contacts of the teeth when the lower jaw moves away from the true hinge position.

The Guidance of the Lower Jaw due to Tooth Contacts

The understanding of the guidance of the movements of the lower jaw due to teeth has been confused by a misunderstanding of the terms used.

The term "Incisal Guidance" used to be used to describe tooth contacts when the lower jaw moves from the true hinge position. This is a limiting term as more teeth than incisors frequently guide movements of the lower jaw.

Depending on the arch relationship of an individual patient, front teeth may not be involved in guiding the lower jaw. The relationship of the upper and lower arches determines which teeth guide the movements of the mandible.

If the lower jaw is further back relative to the upper jaw and the upper front teeth are not tilted backwards, the back teeth will initially guide the movements of the lower jaw when it moves away from the hinge position.

Posterior Guidance

If the term "Anterior Guidance" is to be used then an understanding of Posterior Guidance must first be understood.

Posterior Guidance is the guidance of the lower jaw due to the anatomy of the jaw joints. This determines the degree of angulation of the path that the condyle moves from the true hinge position down to the Articular Eminence and as a consequence determines the degree to which the back teeth separate.

The shallower the angulation of the condylar path the less the back teeth will separate. The steeper the angulation of the condylar path the greater the separation will be.

Anterior Guidance

Anterior Guidance is the guidance of the lower jaw due to the guidance of the teeth.

Which teeth guide the lower jaw will be determined by the relation of the upper and lower arches, the teeth that are present and the positions of the teeth within the arch. As a result of this the guiding teeth may be anywhere in the arches. The guidance may be on the back teeth first and then some teeth further forward may take over the guidance. In some circumstances the guidance may be immediately on the front teeth and in others the guidance may only be on the back teeth.

The guidance may be one upper tooth and one lower tooth. The teeth involved in the guidance of the lower jaw may be upper and lower canines, upper and lower lateral incisors, upper and lower central incisors, upper canines and lower first premolars, first and second premolars or the molar teeth. Many combinations occur.

As the lower jaw moves from the true hinge position the guidance may be on one upper tooth and one lower tooth. Then more teeth may take over the guidance. Then other teeth may take over the guidance.

Alternatively the guidance may start on several teeth then progress onto only a few teeth.

If the lower arch is positioned far back or far forward relative to the upper arch the guidance may only be on back teeth as is the case in Class I and Class II Cases.

The combinations of possible guidances are so numerous each case must be looked at as being very individual.

There can be a problem with the use of the term "Anterior Guidance".

It may be confused by meaning guidance by anterior teeth. In a significant many cases there is no guidance on anterior teeth.

The term "Tooth Guidance" is therefore a more comprehensive term and can be used in all combinations of possible guidances.

To say that anterior guidance can be achieved by two different types of anterior guidance, "Anterior Group Function" or "Canine Guidance" is very simplistic.

If we look at an analogy of people conversing together, two people may be talking to each other. Three people may be talking to each other. Four people may be talking to each other. A small group of people may be talking to each other or a large group of people may be talking to each other. Only to consider two people talking to each other or a group of people talking to each other would be too simplistic.

To start with how many teeth have to contact to constitute “Group Function”, four teeth, six teeth, eight teeth or how many.

When the lower arch is far forwards compared with the upper jaw, several molar teeth will guide the lower jaw. Would this be termed “Posterior Group Function”? If the guidance is on one upper molar tooth and one lower molar tooth is this “Molar Guidance”.

The truth is that the guidance is wherever the guidance is for a particular patient.

Guidance by several teeth is suitable when it is already present and there are no adverse effects present. Guidance by several teeth is advantageous when distribution of excursive stresses is advisable.

In situations where there is loss of bone around some teeth or where there are extensively restored teeth, guidance on several teeth is advantageous.

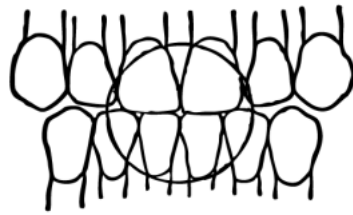
The Principles of Occlusion for Natural and Restored Dentitions

The following principles should be considered when studying each individual case.

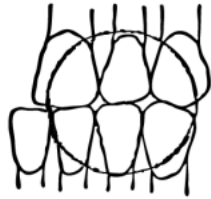
1. The occlusal forces should be directed down the long axis of each posterior tooth.
2. As many posterior teeth as possible should contact in the true hinge position (centric relation), no lateral slide being present when the teeth are clenched together, (a very slight slide forwards is acceptable).
3. The front teeth should separate the back teeth wherever possible
4. If the arch relationships and the angulation of the front teeth allow, when the jaw moves away from the true hinge position, posterior tooth contacts should decrease as the front teeth take over guidance
5. There should be no non-functional, balancing side, contacts.

In severe Class 111 guidance on the non-functional sides are inevitable.

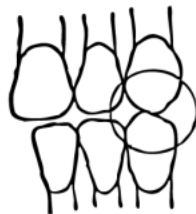Edge to Edge Contacts



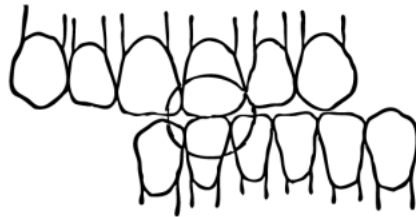
Protrusive



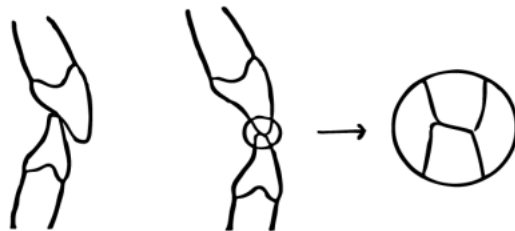
Lateral-Protrusive



Radial Lateral



Crossover



Exceptions to the Principles of Occlusion

1. In moderate and severe periodontal cases where the normal guiding teeth have reduced bony support, on-functional (balancing side) contacts may be required to reduce the stresses on usual guiding teeth on the functional side.
2. In Anterior Open Bite Cases and Severe "Class III" Cases, guidance will be on back teeth often on the non-functional side.

Mounted Study Model Procedure

2 sets of models are set up on two articulators using two centric records. The accuracy of the mounting can be checked by marking the first contacts on each set of models after they are mounted and comparing the two set-ups. If they are the same or very nearly the same then the two sets are mounted accurately. The possibility of setting up two sets of models incorrectly and exactly the same is highly unlikely.

Impressions

Facebow Registration for a Hanau Semi-adjustable articulator

Centric Record Registration

Set-up

- 1) **Metal Tray**
(plastic trays are damaged by the Multiform Paste)
- 2) **Upper and Lower Perforated Alginate Impression Trays**
(Ensure that all the trays in the practice are clean and ready to use) (Anatomical Coe Trays are the best trays to use)
If there are any previous models use them to help select the correct size tray for the patient.
Ensure that the tray extends beyond the back teeth and is not too tight
- 3) **2 Wax Rectangles (7 cm long)**
(Use a fairly soft type of wax. There will be a certain amount of distortion of the centric record when it is taken out of the patient's mouth and during the time before it is used to mount the lower model. When the models are put together with the centric record and gripped together the softer type wax will "distort" back to its original shape.
Hard waxes are unsuitable as they crack when this is done)
- 4) **Multiform Paste measured 1 and 1/2 inches from each tube**
(A type of Zinc Oxide and Eugenol paste which is suitable for making centric records being not too sticky and not too brittle)
- 5) **Vaseline**
(Used to help prevent the paste from sticking to the patient's teeth)

- 6) **4 Bowls of Alginate measured out**
(3 measures for each medium or small tray 3 measures for each large tray Use three scoops if partial dentures are to be made on the models)
- 7) **4 Water Measurers plus water**
- 8) **2 Alginate Spatulae**
- 9) **Facebow with Wax added to the Fork**
- 10) **Tip-a-dilly Aspirator tip**
- 11) **Piece of paper with the patient's name on To identify the case**

Study Model Impressions

The Procedure

1. Nurse chooses the trays by using any previous models of the patient
Otherwise the Dentist chooses correct size of trays
2. Nurse mixes and loads tray (Dentist may prepare wax sheets for the centric records while waiting for the alginate to be mixed)
3. The Nurse places a small amount of alginate onto the pad of the Dentists first finger and holds the Alginate Tray the correct way up and in the right direction to go straight into the patient's mouth
4. The Nurse holds the tray somewhere other than by the handle which should be kept clear for the Dentist to hold
5. The Dentist smears Alginate on the biting surfaces of the teeth (this helps avoid trapping air bubbles)
6. The nurse orientates the tray in the correct direction to go into the patient's mouth
7. The Dentist inserts the tray into the patient's mouth
8. The Nurse mixes for the next impression
9. While the nurse is mixing the Dentist removes the tray when the Alginate is set and aspirates any Alginate left in the Patient's mouth (at the end of all the impression taking the patient is given a thorough rinse)
10. Upper followed by 2 lower impressions are taken one after the other

Care of the Impressions

- a. The impressions should be washed in cold water to remove saliva which would affect the hardness of surface of the model
- b. Vigorously shake the water of the impressions (If left on the impressions the plaster/stone mixture would be diluted on the surface of the model and would be soft when set)
- c. Cover the impression with a tissue and drop several drops of water on it This helps prevent the Alginate drying out
- d. Pour the impression within 15 minutes (after this time the Alginate begins to distort)
- e. Separate the impression from the model after 1 hour

SEPARATE AT LEAST WITHIN 3 HOURS

Facebow Registration for the Artex Semi-adjustable Articulator

Purpose To enable the mounting of the patient's upper model on the articulator in the same relationship to the condyle as the patient's upper arch to their Temporomandibular joint (jaw joint)

The Artex Face Bow Components

1. The bow
2. The bite fork which carries the wax
3. Universal locking joint

Artex transfer items

1. Transfer table
2. Transfer jig

Set-up Facebow Fork Preparation

1. The prongs of the bite fork are covered with wax by the chairside assistant.
2. The bite fork is attached to the face bow
3. The wax is warmed in a bowl of hot water by the assistant ready for the dentist to use.

The Procedure

1. The prepared face bow is held over the patient's mouth by the assistant (using their left hand)
2. The assistant retracts the patient's left cheek using a mirror with their right hand
3. The dentist inserts the bite fork into the patient's mouth
4. The patient is told to bite onto the bite fork
5. The dentist holds onto the ends of the sliding parts of the bite fork (the assistant can now let go of the bite fork)
6. The sliding arms are gently pushed together in line with the ear holes and the patient is asked to push them in and to hold in place
7. The nasal rest is slid onto the nasion and held in place
8. The universal joint is tightened, making sure it is on the patient's left

To remove the face bow

9. Slide nasal rest away and tighten
10. Slide arms out
11. Ask patient to open mouth and remove face bow and hand it over to the assistant

Centric Record Registrations

SET-UP

- () 1) 2 Pink Wax rectangles (7 cm wide)
- () 2) Multi form Paste measured out 4 cm (1 and 1/2 inches) from each tube
- () 3) Water in an eyedropper bottle
- () 4) Cement Mixing Spatula (clean)
- () 5) Vaseline
- () 6) Pointed 5" Curved Scissors

THE PROCEDURE

Initial Planning

- a) Check to see if there are enough teeth opposing each other far enough apart from each other to provide 4 good "stops".
- b) Having put the models together with the centric record between them it must be possible to grip the models together without their relationship to one another changing.

It may be necessary to add a bite block to part of the wax sheet to be used for the centric record where teeth are missing)
- c) Manipulate the patient into Centric Relation using the Dawson Hold and check for: -
 - a) The first contact in Centric Relation
 - b) The amount that the patient's lower jaw moves from this first contact to Maximum Intercuspidation
(The centric relation record should be taken with the patient's teeth sufficiently far apart so that the teeth do not touch. If this should occur the lower jaw may move out of centric relation. It may be necessary to make an Anterior Jig to keep the teeth apart so as to prevent the centric interferences contacting.)
 - d) Decide whether or not to make an Anterior Jig
The wax handle at the front of the centric record may be rolled up so that the patient's front teeth are kept apart by the wax when the patient is closed up onto the centric record. The rolled up part is made thick enough to prevent the first contact of back teeth to occur.
- 2. The Nurse mixes the Multi form paste as soon as possible, as it takes a long time to set.
(ADD 1 DROP of WATER to speed the setting. Adding more water will lengthen the setting time)

Making the Wax Template

- a) The dentist warms the wax between his hands and inserts it into the patient's mouth
- b) The wax is placed on the upper arch and pressed up onto the upper central incisor teeth.

(This helps the relocation of the record in the patient's mouth)

- c) The patient is then asked to bite hard on the wax.
- d) The wax sheet is then removed from the mouth and excess wax cut off using a pair of curved scissors leaving a handle at the front
- e) 4 holes are punched in the wax using the tip of the curved scissors

(The position of each hole is selected where a cusp tip of a tooth closes into an opposing tooth somewhere along a line from one marginal ridge to another.

The holes are best positioned in the first premolar and second or third molar regions whenever possible)

Making the Anterior Jig

- a) Tap the patient in Centric Relation onto their early contact, and decide how much opening is required to prevent these teeth from touching
- b) Roll the Wax Template Handle up to make a jig that will contact the front teeth, and is thick enough to prevent the early contacts from touching
- c) Place the Wax Template into the patient's mouth, on the upper teeth.
- d) Tap the patient into Centric Relation into the Anterior Jig
- e) Check that there is no contact between the early contacts.

Taking the Centric Record

a) Add a small amount of Multiform Paste to each side of each hole and: -
WAIT TILL THE PASTE BEGINS TO BECOME MODERATELY FIRM
(like putty or plasticene) BEFORE PLACING THE RECORD INTO THE PATIENT'S MOUTH

(Prepare the next wax record while the paste is setting)

b) Vaseline the biting surfaces of the patient's teeth

The nurse may mix the Multiform paste for the second record at this stage so that it will be ready to be applied to the second record as soon as the first record has been placed into the patient's mouth

c) Place the record into the patient's mouth using the indentations of the upper incisor teeth to relocate the record.

d) Press the record gently onto the upper back teeth

Occasionally it may be helpful for the nurse to hold the record in place by placing her thumb on the record at the front to hold it against the upper teeth

e) Close the patient's lower jaw into centric relation using the Dawson Hold.

Gently tapping the lower teeth into the Multiform paste produces indentations in the paste.

DO NOT CLOSE THE LOWER JAW SO THAT THE UPPER AND LOWER BACK TEETH COME INTO CONTACT

f) Have the patient open their mouth a little while the paste is setting to prevent the patient biting on the record and distorting it

g) Wait till the paste is set and then remove the record

h) Repeat the procedure for the second centric record

Checking the Centric Record

While the paste is setting check the first record for :-

a) Good cusp tip to tooth " stops "

b) No holes in the multiform paste indicating that the patient's teeth have come into contact

Remove the second record and check it

Mounting Lower Models

On Hanau, Denar, Fagmatic, Artex and Dentatus Articulators

IF MOUNTING STUDY MODELS CHECK THAT THE MODELS ARE MARKED "1" AND "2" (indicating that the models are mounted on articulators "1" and "2")

Do not put the Centric Record on the models till both have been adjusted as described later

Setting Up

1. Put a small amount of water into a plaster bowl
2. Place next to the bowl
 - a) A clean spatula
 - b) A scalpel
 - c) The Centric Records
 - d) The Lower Models
3. Remove Face-bow or mounting jig from the articulator
4. Remove the Upper Model from the articulator
5. Attach a mounting plate to the lower member of the articulator

Articulator Preparation

ARTEX

- a) Check that the Condylar Balls are as far forward as possible
- b) **Check that the Centric Locking Screws are locked**
- c) Stand the articulator upside down on its upper member

(IDEALLY THE DENTIST TAKES THE RESPONSIBILITY FOR MOUNTING THE LOWER MODEL)

- d) **Set the incisal pin on 0, then open pin by 4 mm** to compensate for the

thickness of the centric record

Centric Record and Model Preparation

- a) Check the occlusal surface of the upper and lower models for defects such as bubbles
- b) **Score the base of the lower model**
- c) **Check and adjust the Centric Record for sharp projections** which would prevent the models from seating into the record
- d) Place the Centric Record onto the upper model and check for distortion (it may be necessary to warm the record in warm water to help seating the record if there has been some distortion)
- e) Seat the lower model into the Centric Record and grip the two models tightly together. On releasing the grip, watch for "spring back"

If there is, remove the record, warm it, replace it and grip the models together. If there is still spring back it may be necessary to hold the models together after mounting the lower while the plaster sets
- f) With the two models seated into the centric record attach the Upper model to the upper member of the articulator.

Mounting the Lower Model

- a) Place a **very wet tissue** on the base of the lower model
- b) **Close the articulator and check the space** between the base of the lower model and the mounting plate to determine how much plaster will be needed
- c) Add Plaster to the Mounting Plate and the base of the model
- d) Close the articulator and remove any excess plaster

FINALLY

- e) **Grip the Upper and Lower models together to ensure that the models are seated correctly in the centric record**

DO NOT PLAY WITH PLASTER WHILE IT IS SETTING

Occlusal Examination of Study Models

Name _____

Dynamic Analysis

Set the Condylar Angles to 20 degrees and Bennett Shift to 15 degrees unless otherwise indicated

1) **EARLY CONTACTS** in Centric Relation

- a) Lock the articulator in Centric
- b) Raise the Incisal Pin
- c) Close the articulator and look for any obvious interferences
- d) Open the articulator and place a square of **GREEN** silk over the lower teeth
- e) Close the articulator and tap the models together
- f) Check for early contacts
- g) Record the findings

_____ / _____

2) **PRESENCE of a SLIDE** from Centric Relation to Maximum Intercuspidation

- a) Unlock the centric locking device Check that the Articulator moves freely
- b) Hold the upper Member of the Articulator in the one hand and the Lower Member in the other hand
- c) Holding the Articulator in Centric Relation close the Articulator
- d) After the first contact is reached close the articulator carefully into Maximum Intercuspidation
- e) Observe the direction of any slide from centric relation to Maximum Intercuspidation
- f) Record the findings e.g. short or long slide to the left or right

3) **INTERFERENCES**

IN LEFT LATERAL MOVEMENT

- a) With the centric locking device unlocked close the articulator in to centric relation
- b) Move the lower model to the patients left
- c) Observe whether the front teeth separate indicating a contact posteriorly
- d) Place a square of **RED** silk between the models and repeat the movement
- e) Describe the Interferences e.g. short or long slight or gross

Non-functional (contacts on the right side)

_____/_____
/

Cross-over (after the left canines have crossed over each other

_____/_____
/

Functional (on the left side)

_____/_____
/

IN RIGHT LATERAL

Non-functional (on the left side)

_____/_____
/

Cross-over (after the canines on the right side have crossed over each other

_____/_____
/

Functional (on the right side

_____/_____
/

4) **Tooth Guidance**

a) **EDGE TO EDGE CONTACTS**

Protrusive _____ / _____

Left Lateral _____ / _____

Right Lateral _____ / _____

Left Lateral Protrusive _____ / _____

Right Lateral Protrusive _____ / _____

b) **LEFT LATERAL EXCURSION**

Smoothness of Guidance _____

Steepness of Tooth Guidance _____

Posterior Clearance or presence of Posterior Interferences

Right _____ Left _____

c) **RIGHT LATERAL**

Smoothness of Guidance _____

Steepness of Tooth Guidance _____

Posterior Clearance or presence of Posterior Interferences

Left _____ Right _____

d) **PROTRUSIVE**

Smoothness of Guidance _____

Steepness of Tooth Guidance _____

Posterior Clearance or presence of Posterior Interferences

Right _____ Left _____

e) **LEFT LATERAL PROTRUSIVE** (half way between left lateral and protrusive)

Smoothness of Guidance _____

Steepness of Tooth Guidance _____

Posterior Clearance or presence of Posterior Interferences

Right _____ Left _____

f) **RIGHT LATERAL PROTRUSION** (half way between left lateral and protrusive)

Smoothness of Guidance _____

Steepness of Tooth Guidance _____

Posterior Clearance or presence of Posterior Interferences

Left _____ Right _____

OCCLUSAL PLANNING

Orthodontic Treatment _____

Removal of Teeth _____

Appliance Therapy _____

Posterior Cusp Tip Shortening and Reshaping / Additions to Fossae

Other Occlusal Equilibration Planning _____

Occlusal Correction by Restorative Treatment _____

Occlusal Management

ANALYSING an OCCLUSION

1) **EARLY CONTACTS** in Centric Relation

2) **PRESENCE of a SLIDE** from Centric Relation to Maximum Intercuspitation

Slides in Centric Relation

Describing a slide:

long or short, to the left or right, protrusive, horizontal or vertical

Close gently into centric relation, ask the patient to close into Maximum Intercuspitation

3) **INTERFERENCES**

LEFT LATERAL:

Non-functional (contacts on the right side)

Cross-over (after the left canines have crossed over each other)

Functional (on the left side)

RIGHT LATERAL:

Non-functional (on the left side)

Cross-over (after the right canines have crossed over each other)

Functional (on the right side)

4) **Tooth Guidance**

a) **EDGE TO EDGE CONTACTS:** Protrusive, Left Lateral, Right Lateral,
Left Lateral Protrusive, Right Lateral Protrusive

b) **LEFT LATERAL EXCURSION:** Smoothness of Guidance, Steepness of Tooth Guidance,
Posterior Clearance

c) **RIGHT LATERAL:** Interferences, Smoothness of Guidance, Steepness of Tooth Guidance,
Posterior Clearance

d) **PROTRUSIVE:** Smoothness of Guidance, Steepness of Tooth Guidance, Posterior Clearance

e) **LEFT LATERAL PROTRUSIVE:**
(half way between left lateral and protrusive) Smoothness of Guidance, Steepness of Tooth
Guidance, Posterior Clearance

f) **RIGHT LATERAL PROTRUSIVE:**
(Half way between left lateral and Protrusive) Smoothness of Guidance, Steepness of Tooth
Guidance, Posterior Clearance

The Principles of Occlusion

- 1) The Occlusal Forces should be directed down the long axes of each posterior tooth
- 2) As many posterior teeth as possible should contact in Centric Relation
- 3) There should be no lateral slide from Centric Relation to Maximum Intercuspidation
- 4) As the patient moves away from Centric Relation tooth contacts on back teeth should decrease as the front teeth take over the guidance
- 5) The front teeth should protect the back teeth
- 6) There should be no non-functional (balancing) contacts

Occlusal Adjusting

Objective:

- * To produce as many stable centric stops on posterior teeth as possible
- * To reduce or remove posterior centric interferences
- * To produce a harmonious tooth guidance that reduces the stress on the back teeth as much as is possible in the circumstances and allows smooth gliding guidance in excursive movements

Methods of Altering Occlusions

Remove teeth

Restore teeth

Reposition teeth

Reshape teeth

Occlusal Appliance Therapy

Deciding where to start

- the possibilities are :-

- a) Remove early contacts to establish centric relation occlusion
- b) then remove Non-functional Contacts
- c) Then Improve the Tooth Guidance

d) Or All three at once

When learning the art of equilibration it is easier to adjust in centric relation first and to then adjust the

Non-functional contacts and finally to adjust the Tooth guidance.

At first tackling all three at once is difficult.

As soon as possible, however, begin to look at all three aspects of occlusal adjusting.

a) **Establishing Centric Relation Occlusion**

The Temporomandibular Joint (Jaw Joint) is made up of the following structures :-

1. The Head of the Condyle (the highest point of lower jaw)
2. The Articular Disc
3. The Glenoid Fossa (the depression in the base of the skull into which the Head of the Condyle fits

An objective of occlusal equilibration is to establish stable centric stops, with properly seated Head of the Condyles in the Glenoid Fossa and relaxed muscles.

Mark the Early Contacts using Green Silk on models, Green Silk or Blue articulating paper in the mouth.

Analyze each marking:

1) **Markings on Anterior Teeth:**

Contacts on anterior teeth in centric relation are not advisable unless the teeth are in such an alignment that the forces can be directed down the long axis of the teeth involved.

Lightly remove contacts on anterior teeth in centric relation

As a rule remove markings from front teeth when adjusting in centric relation, unless there are insufficient centric stops on healthy posterior teeth.

Contacts in centric relation occlusion on front teeth are undesirable unless there are few back teeth present i.e. poor posterior support. In this case some help may be required from the front teeth to take the forces of occlusion in centric relation

Occasionally front teeth may be in edge to edge occlusion in which case the forces of occlusion will be directed down the long axes of the teeth. However contacts on front teeth will most often be on slopes which although not ideal is a better situation than having too much force exerted on the few remaining back teeth.

The principles of occlusion are principles not rules and must be adapted to the situation being dealt with

If the front teeth are in an edge to edge relationship, the forces will be directed down the long axis of the teeth, and are acceptable.

2) **Markings on Posterior Teeth:**

a) Markings on slopes

These are unstable and may result in a slide from Centric Relation to Maximum Intercuspitation

Decide the ideal place to move a contact i.e. mesially, distally, lingually, or buccally

Is it going to be possible to produce a stable centric stop in this particular situation?
If not, remove the contact straight away and continue adjusting elsewhere

Stage 1 **Adjust Contacts on Slopes**

" The Occlusal Forces should be directed down the long axes of the teeth "

Remove markings from slopes

When adjusting study models, use the spoon end of the Le Cron carver for adjusting fossae and slopes, and use the blade for adjusting and recontouring cusp tips. In the mouth, use a round diamond bur for adjusting fossae and the short flame diamond bur for cusp tips.

If a tooth becomes sensitive, remove tooth structure from a non sensitive part of the tooth or remove tooth structure from the opposing tooth

Take care when working near cusp tips so that cusp tip is not reduced inadvertently.

When removing a contact from a slope, be careful not to remove anything from the fossa below the slope. If this is done the fossa will become deeper and the centric stop on this tooth may be lost. This may result in difficulty in obtaining a centric stop on that tooth.

Stage 2 **Adjust Centric Stops to bring other potential Centric Stops into contact.**

The objective is to create as many Centric Stops into contact as possible

"As many posterior teeth as possible should contact in Centric Relation "

When a few stable centric stops have been created, they will need to be reduced in order to produce additional stops on other teeth.

Choosing whether to adjust a fossa or a cusp tip

Reducing a fossa just requires producing a flat area for an opposing cusp to occlude. Adjusting cusp tips is more difficult to perform. Once shortened the tip has to be recontoured to produce a point contact. During this process the highest point of the tip may be moved mesially, distally, buccally and lingually. This requires a greater degree of thought and skill than reducing a fossa or marginal ridge. It is more difficult to reshape cusp tips.

In cases of steep anterior guidance where there is no possibility of creating

Non-functional contacts it is easier to adjust the fossa rather than the cusp tip. Where there are non-functional contacts or there is a likelihood of creating non-functional contacts deepening fossae is likely to worsen the situation. It is better to reduce cusp tips in this situation.

Deepening a fossa will allow the opposing cusp tip to occlude deeper into the fossa. This may result in producing or worsening a non functional contact. If this is a likely to occur, adjust the cusp tip.

Keep cusp tips reasonably pointed. This enables point contacts rather than contacts over a larger area. If this were to occur there is likely to be greater wear of the teeth

How much tooth structure to remove ?

This depends on the clinical judgement of the operator taking into account the following factors :-

How gross is the interference? The greater the interference the greater the amount of tooth structure should be removed. When there is only a small interference taking too much tooth structure will result in the loss of a centric stop.

How close is the progress towards an end result?
(The closer to the end result, the less should be removed)

How sensitive are the teeth? If teeth become sensitive during an occlusal adjustment consider stopping and continue the adjustment a few months later.

The effect of removing tooth structure posteriorly

Removing 1 mm at the back of the mouth results in a closure of 3 mm at the front.

From which tooth should the tooth structure be removed?

If the cusp tip is also a non-functional contact, remove from the cusp tip not the fossa
Removing from the fossa allows the cusp tip to be positioned deeper into the opposing tooth and increases the severity of the non-functional contact

Removing from the cusp tip lessens the severity of the non-functional contact

When a non-functional contact on a cusp tip is also a centric stop, it may be necessary to reduce the cusp tip to eliminate the non-functional contact and to thus sacrifice a centric stop. Hopefully there will be another centric stop on the tooth

Adjusting Anterior Teeth

The objectives are to produce a harmonious Tooth Guidance that reduces the stress on the back teeth as much as is possible if the arch relationships allow. Smooth gliding guidance in excursive movements reduces stress on the teeth and reduces grinding of the teeth. If the guidance is not smooth a tooth or several teeth may be traumatized during bruise and may be damaged and/or loosened. If by reducing the contact on a loose front tooth, a non-functional contact is created this may be necessary to improve the prognosis of this tooth.

Transferring guidance onto teeth further forwards is preferable in order to reduce the stresses

on back teeth.

If there is a contact in maximum Intercuspidation between the tip of a lower front tooth and the palatal surface of an upper front tooth, and the tip of the lower front is shortened, the edge-to-edge contacts can be altered. This effectively may allow the back teeth to come into contact. This may not be desirable as it will have created a posterior interference.

A decision has to be made as to which contact to reduce the tip of the lower front tooth or the back of the upper front tooth

As posterior interferences are removed the lower jaw contacts on the upper teeth move forwards. Due to this centric stops may move forwards and be lost off the front of the mesial marginal ridges of the upper teeth, To avoid this it is necessary to reduce the mesial aspect of the tip of the lower tooth. This results in the highest point of the tip being further back

Before beginning an occlusal adjustment, look for deep fossae in fillings. By shortening the opposing cusp tip and adding to the deep fossa of the filling there will be less like lihood of an interference being present.

A cavity is cut in the deep fossa and light cured composite added to the cavity .The patient is asked to close their teeth together and the composite cured from the buccal aspect. The patient then opens and the composite material cured from on top. The composite filling will be too high and will require reducing.

Teeth with large amalgam fillings may have thin and fragile cusps. In this case, ensure that all centric stops are on the amalgam filling, not on the cusp tips as they thin cusps. This may prevent the weak cusp tips fracturing off.

Halos

When nearing the completion of an equilibration it may be possible to hear one tooth is touching before the rest.

At this stage there may be several markings, produced when the teeth are tapped together on articulating paper or the mounted study models are tapped together.

Have the patient then tap together with no articulating paper present.

Check the markings again. Where there is a true contact the ink markings will have been cleared in the centre of a marking. If this is the case, this is the true first contact.

This type of marking is known as a "halo".

Splaying of Front Teeth

Splaying of front teeth in moderate to advanced periodontal cases is often due to the lower teeth hitting in centric relation and sliding forwards into the front teeth. The upper front teeth protrude and gaps may appear between them.

When these cases are equilibrated in centric relation occlusion and the slide eliminated, the front teeth may move back of their own accord, into their original positions. They may require retracting with an orthodontic appliance.

Historic Markings

When a decision has been made to remove tooth structure from only one of two teeth that are contacting the marking on the other tooth still remains.

This is known as a "Historic Marking " and is no longer relevant. The marking ink must be removed from this tooth at the same time as the tooth structure is removed from the opposing tooth. Unless this marking is removed, irrelevant markings will be present causing confusion. Historic markings will be present as well as the true

markings of the real contacts.

Smudge

Occasionally marks may be a smudge and not a true marking. Markings may even be found on unopposed teeth.

When a lot of smudges or markings are present, clean them off with a toothbrush and start again. Alternatively ask the patient to grind on a tissue or piece of gauze held in a pair of articulating paper holders

Protecting Cusp Tips

When adjusting non functional contacts, preserve centric stops where possible. If two cusp tips touch in excursions often non-functional contacts, it may be necessary to lose one or other cusp tip contacts. In these situations it is necessary to sacrifice the stop from a tooth with most stops.

Tooth Guidance

Immediate separation by two teeth is easier to deal with than when more teeth are involved in the guidance.

Guidance by several teeth has the advantage of distributing the forces of occlusion over several teeth

If upper or lower front teeth are to be shortened for aesthetic and functional reasons,, check first to ensure that interferences at the back are not going to be produced. If interferences are produced, decide whether it is still wise to go ahead, or make provision to adjust them later.

Steepness of Tooth Guidance –

General principle - Flattening Tooth guidance seems to decrease TMJ problems

Steep Tooth Guidance in Class 2 division 2 cases produces immediate discussion of the back teeth.

Steepening Tooth guidance, however, can cause Temporomandibular joint problems.

Flattening the Tooth guidance can help Temporomandibular joint problems.

Changing the Angulation of the Tooth Guidance:

1. If the tooth guidance is flattened, interferences may be produced on the back teeth.
2. Flattening the tooth guidance can help in Temporomandibular Joint problems.
3. Steepening the Tooth guidance may help reduce posterior interferences but produce joint problems.

When checking Tooth Guidance:

1. Edge-to-edge position
 - a. protrusive
 - b. left lateral
 - c. right lateral
 - d. left lat protrusive
 - e. right lat protrusive
2. Check left lateral; note guiding teeth & look for non-functional contacts on the right
3. Check right lateral; note guiding teeth & check non-functional contacts the left
4. Protrusion; check guiding teeth & protrusive interferences
5. Left Lateral Protrusive
6. Right Lateral Protrusive

When checking edge-to-edge positions:-

Check for interferences on posterior teeth
Adjusting Edge-to-edge Contacts - Whether to adjust upper or lower front teeth depends on which gives best aesthetics

Adjusting Front Teeth

When adjusting the length of front teeth, always consider the appearance.

The appearance of front teeth is personal to that person. Alterations of the appearance need to be done with the consent of that person. Alterations to the aesthetics need to be done gradually, with the patient watching in a hand mirror. They need to look at the results as the procedure progresses.

STOP adjusting the front teeth when the patient is happy with the appearance.

How to Progress when starting to perform Occlusal Adjustments.

- 1) Start with isolated adjustments that are obviously necessary :-
 - a) Reshaping and shortening opposing cusp tips before restoring a tooth when the cusp tip occludes deep into the occlusal surface of the opposing tooth
 - b) Remove obvious interferences in centric relation
 - c) Remove gross non-functional contacts
 - d) Recontour anterior teeth that are over-erupted where there is no chance of creating non-functional contacts by doing so
- 2)
 - a) Take two sets of study models of patients who you consider would benefit from alterations in their occlusion
 - b) Adjust one set and record any particularly significant changes you think

should be made to the patient
c) Equilibrate the patient

3) Equilibrate the study models at the same time as you equilibrate i.e. adjust the models a little and then adjust the patient and repeat the process

The advantages are :-

a) The patient sees the work you are doing on their behalf (charging the patient for the adjustment of their models when they are not present is fully justified Seeing the adjustment being performed may help them rationalize the fee)

b) The adjustment made on the model is fresh in your mind when you are adjusting in the mouth

4) When in doubt fit an appliance before equilibrating

5) Stop if the patient experiences pain

6) At first

a) do not treat patients who are particularly neurotic

b) do not overly persuade patients to have an Occlusal adjustment. Choose patients who are enthusiastic and good patients

Appointing Patients for an Occlusal Adjustment.

It is not possible to predict exactly how long an equilibration will take

Book patients for an initial appointment with the understanding that further appointments may be necessary

Relate the length of an appointment to the patient's ability to pay
i.e. arrange shorter appointments for patients who need to spread out the payments.

Be flexible

General Screening

NAME: _____ DATE: ____/____/____

Initial Requests _____

- | | | |
|--|---|-------------------------------------|
| <input type="checkbox"/> General Health | <input type="checkbox"/> Recent Visit to Doctor | <input type="checkbox"/> Allergies |
| <input type="checkbox"/> Serious Illnesses | <input type="checkbox"/> Bleeding Problems | <input type="checkbox"/> Medication |
| <input type="checkbox"/> Rheumatic Fever | <input type="checkbox"/> Blood Pressure | <input type="checkbox"/> Diabetes |
| <input type="checkbox"/> Heart Problems | <input type="checkbox"/> Arthritis | |
| <input type="checkbox"/> Headaches | <input type="checkbox"/> Migraine | |

Any Dental Problems? _____

Comfortable Bite _____

Sensitive Teeth _____

Grinding _____

Jaw Joint Pain Noises (Clicking, Popping, Grating)

Difficulty in Moving Jaw Pain on Moving Jaw

Sinuses _____

Ears _____

CLINICAL EXAMINATION

Soft Tissues _____ Preauricular Palpitation _____

Lat. Ext. Aud. Meatus _____ Tap, Tap, Tap Test _____

Early Contacts (EC) Test _____ Presence of Slide (CR-CO) _____

Non Functional Contacts (NFC) _____

Tooth Charting _____ Vitality _____

Stuart Orton-Jones Institute
33, High Street, Harpole, Northampton. NN7 4DH
Telephone: 01604 832399
Email stuart@sojinstitute.co.uk www.sojinstitute.co.uk

Looseness Gum Check

Stuart Orton-Jones Institute
33, High Street, Harpole, Northampton. NN7 4DH
Telephone: 01604 832399
Email stuart@sojinstitute.co.uk www.sojinstitute.co.uk

Clinical Occlusal Evaluation Form for Patients

Name _____

1) **EARLY CONTACTS** in Centric Relation

(Using the Dawson Hold close the patient until you feel the first tooth contact
Then ask the patient if they notice any tooth touching before any other
Record their reply e.g. left or right side near the front or back)

2) **PRESENCE of a SLIDE** from Centric Relation to Maximum Intercuspitation

(Close the patient into centric relation using the Bimanual manipulation (the Dawson Hold)
After first contact is reached ask the patient to close tight
Observe the direction of any slide from centric relation to Maximum Intercuspitation
Record the findings e.g. short or long slide to the left or right)

3) **INTERFERENCES**

(put finger on left canine, ask patient to slide towards it
Observe whether the front teeth separate indicating a contact posteriorly If there is no
apparent separation place some articulating silk between the posterior teeth on the right side and
repeat the exercise pulling on the articulating paper holders
Describe the Interference e.g. short or long slight or gross

Non-functional (contacts on the right side) _____

Cross-over (after the left canines have crossed over each other)

Functional (on the left side) _____

LEFT LATERAL

RIGHT LATERAL

Non-functional, on the left side _____

Cross-over (after the canines on the right side have crossed over each other)

Functional (on the right side) _____

Stuart Orton-Jones Institute
33, High Street, Harpole, Northampton. NN7 4DH
Telephone: 01604 832399
Email stuart@sojinstitute.co.uk www.sojinstitute.co.uk

4) Anterior Guidance

a) **EDGE TO EDGE CONTACTS**, (put a finger on central incisors & ask patient to slide towards it)

Protrusive _____

Left Lateral _____

Right Lateral _____

Left Lateral Protrusive _____

Right Lateral Protrusive _____

b) **LEFT LATERAL EXCURSION**

Smoothness of Guidance _____

Steepness of Tooth Guidance _____

Posterior Right _____ Left _____

Clearance

c) **RIGHT LATERAL**

Smoothness of Guidance _____

Steepness of Tooth Guidance _____

Posterior

Clearance Left _____ Right _____

d) **PROTRUSIVE**

Smoothness of Guidance _____

Steepness of Tooth Guidance _____

Posterior Right _____ Left _____

Clearance

e) **LEFT LATERAL PROTRUSIVE** (half way between left lateral and protrusive.
put finger on lateral incisor and ask patient to slide towards it)

Smoothness of Guidance _____

Steepness of Tooth Guidance _____

Posterior Right _____ Left _____

Clearance

f) **RIGHT LATERAL PROTRUSION** (half way between left lateral and protrusive)

Smoothness of Guidance _____

Steepness of Tooth Guidance _____

Posterior Clearance Left _____ Right _____

Stuart Orton-Jones Institute

33, High Street, Harpole, Northampton. NN7 4DH

Telephone: 01604 832399

Email stuart@sojinstitute.co.uk www.sojinstitute.co.uk

Clinical Occlusal Adjustment Procedure

Items required for the Occlusal Adjustment Procedure

STORAGE TRAY

1. 1 Tupperware Container 15 cm x 18 cm containing
 - a) Pre-cut Red Silk
 - b) 2 x Articulating Paper Holders set up with Red Silk ready to use
2. 4 or more Articulating Paper Holders set up with BLACK foil
3. 1 Suture box containing pre-cut Black Foil
4. 1 Box Shimstock pre-cut to 1/2 inches, 4 cm or the width of a small post-it
5. Horseshoe Articulating Paper (for denture adjustments)

The Black foil and the Red silk should be cut neatly to the length of a large post-it with a pair of straight scissors

The Red Silk dries out if left out and does not mark the occlusal contacts

Burs

- Short Flame Diamond (Intensive 255 from Metrodent)
- Round Diamond Horico 001025 Glover Dental
- Long Flame Diamond F.G.563 (for aesthetic adjustment)
 - or Intensive 311 from Metrodent

Other items

Plastic Salivary Ejectors, CUT IN HALF

This item is extremely useful in salivary control when held by the chairside assistant and used as the dentist dries the teeth with the 3-in-1 syringe

SET-UP

- Plastic Tray,
- Storage tray,
- Mouth mirror,
- 4 or more pairs of Articulating paper holders plus black foil,
(ensure that all the other free Articulating paper Holders are set up with black foil)
- 2 pairs of articulating holders plus red silk
- Large round in No 1 handpiece,
- Short flame diamond in No 2 handpiece,
- Tweezers plus a Cotton Pellet, (for removal of individual unwanted markings)
- A Toothbrush, (for brushing of old markings)
- Tip-a-dilly plus a shortened plastic salivary ejector,

Stuart Orton-Jones Institute

33, High Street, Harpole, Northampton. NN7 4DH

Telephone: 01604 832399

Email stuart@sojinstitute.co.uk www.sojinstitute.co.uk

THE PROCEDURE

In order for the dentist to manipulate the Jaw into Centric Relation both his hands are required It is therefore necessary to have effective chairside support from a dental assistant

The dental assistant should aspirate and place the Articulating Foil or Silk in to the patients mouth while the Dentist dries the teeth and manipulates the Jaw The dental assistant should dry the foil or silk thoroughly after each time they are used using a tissue otherwise they will not mark the teeth The assisting needs to be fast and accurate as the procedure is repetitive and requires good coordination between the dentist and the assistant It is important that the assistant keeps ahead or at least up with the dentist As soon as the dentist moves his hand towards the 3-in-1 syringe the assistant should place the aspirator into the mouth The dentist dries the teeth with the 3-in-1 Syringe as the dental assistant aspirates with her left hand at the back of the patient's mouth on the side that the dentist is drying The dental assistant holds the Articulating paperholders in her right hand ready to place in the patient's mouth as the dentist removes the 3-in-1 Syringe from the patients mouth The dental assistant clearly knows which side to place the articulating paperholders having observed which teeth the dentist has dried

The articulating paper holders must be placed in the mouth at the same time as the aspirator is removed in order to prevent saliva wetting the foil or silk unnecessarily The articulating paper holders should be held against the upper teeth as this jaw does not move while the lower does move.

There is not enough time to change hands during the procedure so it is necessary for the assistant to develop the use of her right hand to place the articulating paper into the left and right hand sides of the patients mouth When the procedure is actively in progress the Articulating Paper Holders should be held up near the mouth ready to place in the mouth The Articulating Paper Holders need to be placed in the mouth as the Dentist removes the 3-in-1 syringe, otherwise there is a risk of the teeth becoming wet with saliva Constantly dry the Red silk during the procedure otherwise it will not mark the teeth The dentist will indicate when the black foil or the red silk is to be used

Preserving markings

If the teeth have been marked and for some reason the dentist is not ready to make the necessary adjustments the patient must be prevented from closing This may well cause the markings to be rubbed off To prevent this happening the assistant should rest the aspirator tip or the tip of a finger on the tips of the lower front teeth to discourage the patient from closing

Placing the Articulating paper holders into the patient's mouth

- 1) Which side to place it
(This will be indicated by the dentist as it will be the side that he dries with the 3-in-1 syringe)
- 2) Hold the Holders ready in the direction that they will be placed into the patient's mouth
- 3) Aim the holders up towards the patient's palate almost touching it Then move it using a finger movement between the teeth ensuring that it is in the line of the arch and in the region which the dentist dried the teeth Placing the articulating paper holders accurately this way will help prevent the foil or silk being folded over by the patient's tongue
- 4) Move the Foil around a little while the patient's teeth are being tapped together in order to ensure better markings By doing this a fresh area of foil is ready to mark the teeth

Stuart Orton-Jones Institute
33, High Street, Harpole, Northampton. NN7 4DH
Telephone: 01604 832399
Email stuart@sojinstitute.co.uk www.sojinstitute.co.uk

Tips

- 1) To help detect first contacts tap the patient into Centric Relation using the Dawson Hold and ask the patient to put their finger on the tooth that touches first
- 2) If a patient experiences difficulty in moving their jaw in the correct direction sometimes the cause can be that only one pair of articulating forceps have been put into the patient's mouth. By placing two in the patient's one each side may overcome this problem
- 3) The Quick Method of Occlusal Adjusting
 - a) Have the patient grind around on some red silk.
 - b) Look at the markings and decide on the markings where contact is definitely not needed or wanted.
 - c) Remove these markings.
- 4) Decide on the amount of tooth structure that needs to be removed

Early in the procedure more may be removed whereas later only a minute amount may need to be removed
The bur being used should be applied to the tooth using a light brush stroke Post Treatment Presentation

Explain the following things to the patient

1. They may find that their teeth feel rough for several days
2. Their symptoms get worse for a few days This is not a bad sign It is due to the patient being more aware of their bite having had it altered Their symptoms will settle down after a few days
4. They may feel hot and cold pain for a few days

Mounting Models on an Articulator

The reason for mounting models on an articulator is to enable a patient's upper and lower models to be related to one another in the same way as the patient's upper and lower dental arches

The different types of articulators may be divided into three groups

- 1) The simple hinge types
- 2) The semi-adjustable types
- 3) The fully adjustable types

The Temporomandibular joint is represented in the simple hinge articulator by a simple hinge This type of articulator will only reproduce opening and closing movements in a vertical plane

Fully adjustable articulators have condylar assemblies programmable to simulate the patient's temporomandibular joint movements and will reproduce the movements of the mandible

Between these two extremes there is a whole range of articulators which will reproduce the movements to a greater or lesser degree These are known as semi-adjustable articulators The condylar pathways are usually represented by a movement in a straight line on the articulator whereas the human

Stuart Orton-Jones Institute

33, High Street, Harpole, Northampton. NN7 4DH

Telephone: 01604 832399

Email stuart@sojinstitute.co.uk www.sojinstitute.co.uk

Temporomandibular joint does not Some articulators have curved pathways that can to a degree simulate human paths of condylar movement

The accuracy to which the movements are simulated will depend on the accuracy of the mounting procedures and the complexity of the articulator used Total accuracy can never be achieved

Ultimately the patient is the most accurate “articulator”

THE CHOICE OF WHICH TYPE OF ARTICULATOR TO USE

The choice of which articulator to use will be dictated by the needs of each particular case being treated and depends on what movements are required to be simulated

For example:-

In a severe class II division 2 case the posterior teeth are immediately separated in excursive movements due to the lower front teeth gliding down the palatal surfaces of the upper front teeth The guidance at the front is so steep that there is little possibility of building interferences into crown and bridge cases

In this case only a simple hinge movement is required for posterior tooth restorations This however assumes a basic understanding of the fundamentals of occlusion on behalf of the dentist and technician

In a severe class II division 1 case the separation of the back teeth by the front teeth is minimal if at all The guidance, being almost flat, considerably increases the possibility of building interferences into a crown and bridge work The movements of the mandible must be reproduced accurately A semi-adjustable or fully adjustable articulator is required in these cases Even then minor adjustments may need to be performed in the mouth

Semi-adjustable articulators are required for anterior crown and bridgework in order to establish or copy a predetermined tooth guidance It may be necessary to use a custom anterior guide table when the tooth guidance has already been established

The Choice of which Articulator to buy

The first essential is an understanding of the fundamentals of occlusion resulting in the ability to make a decision on the best way to approach case a decision on the mechanical equipment to be used in the execution of the diagnosis and restorative work necessary can then be made

Semi-adjustable Articulators

All the articulators in this group produce similar movements and each has minor advantages and disadvantages

They can be used for simply reproducing a hinge movement as well as being able to be moved in excursive movements Due to the relatively crude condylar assemblies the simulation is not highly accurate They can however be used very successfully even when average values are used

The following are desired characteristics of a good semi-adjustable articulator: -

- 1) It should be possible to lock the condylar assembly so that only a simple hinge movement can be made In situations when it is desirable to mount models accurately in centric relation this is a very important characteristic A positive centric latch or locking screw is required
- 2) When the condylar assembly is locked, it should not become unlocked unintentionally
- 3) It should sufficiently robust and durable

Stuart Orton-Jones Institute

33, High Street, Harpole, Northampton. NN7 4DH

Telephone: 01604 832399

Email stuart@sojinstitute.co.uk www.sojinstitute.co.uk

- 4) It is helpful if the upper member of the articulator can be separated from the lower This is a characteristic particularly helpful to technicians It should not be possible for separation of the upper and lower members to occur unintentionally
- 5) It should not be unduly expensive
- 6) It should be easy to use
- 7) It should have sufficient room between the upper and lower members of the articulator to allow the mounting of pinned working models

METHODS OF MOUNTING MODELS

1) Using a facebow

The advantages of using a facebow registration are:-

- a) It provides a convenient place to locate the upper model when mounting it on an articulator
- b) The upper model can be mounted at approximately the same distance from the hinge of the articulator as the patient's upper arch is to the Temporomandibular joint

This means that the model will move in the same arc when being closed up after a centric record has been removed when the models are moved in lateral excursions they will also move in a similar arc to the patient's dental arches when the mandible is moved laterally

2) Hand mounting without a facebow

For single crowns on posterior teeth when there is steep guidance by the anterior teeth in excursive movements it may be acceptable to hand mount models without using a centric record

METHODS OF MOUNTING LOWER MODELS

1) Using some type of interocclusal record

The taking of accurate centric records and the subsequent mounting of models in centric relation on an articulator requires a high degree of skill and should only be performed when the situation merits it Use a centric record for mounting study models and full dentures

When a centric record is used,

- a) it may be inaccurate
- b) the articulator must be closed after the record is removed in order to achieve tooth contact
The arc of closure of the articulator may not be the same as that of the patient even if a facebow is used

2) Hand mounting with plaster to plaster contact without a full interocclusal record.

Hand mounting of accurate models with plaster to plaster contact is the most accurate way of mounting models

There is also the advantage that the models are mounted at the same vertical dimension that restorative work will be constructed

Use for mounting all crown and bridge cases

Where an occlusal adjustment has been performed to eliminate interferences in centric relation and in excursive movements Maximum Intercuspitation will be in centric relation Hand mounting models will result in the models being mounted in centric relation and in Maximum Intercuspitation

If Maximum Intercuspitation and centric relation do not coincide and an occlusal adjustment is not to be performed then there is no point in mounting models in centric relation

Stuart Orton-Jones Institute
33, High Street, Harpole, Northampton. NN7 4DH
Telephone: 01604 832399
Email stuart@sojinstitute.co.uk www.sojinstitute.co.uk

When hand mounting it may be necessary to take a sectional record of the area where teeth have been prepared, with the teeth in Maximum Intercuspitation, in order to relate the models together in a stable way

It is better not to involve the teeth either side of the prepared teeth in the record as the resistance of the material can lead to the patient sliding into an incorrect occlusal relationship.

WHEN TO MOUNT MODELS IN CENTRIC RELATION

- 1) Study models to be used for the analysis of a patient's occlusion
(a centric record must be used)
- 2) Full upper and full lower denture cases (unless the condition of the temporomandibular joint indicates otherwise)
- 3) All crown and bridge cases when the patient is in centric relation and Maximum Intercuspitation simultaneously (unless the condition of the Temporomandibular joint indicates otherwise)

These cases are best hand mounted.

If it is considered necessary to perform an occlusal equilibration this should be carried out before any crown and bridge work is performed

WHEN NOT TO MOUNT MODELS IN CENTRIC RELATION

If centric relation and Maximum Intercuspitation are not coincident and an equilibration is not to be performed then there is no point in mounting models in centric relation

They are best hand mounted in Maximum Intercuspitation i.e. maximum intercuspitation

SETTING THE CONDYLAR ASSEMBLIES

The Simple Hinge Articulator solves the problem by having no possibility of any adjustments due to the fact that only a simple hinge movement is possible

Semi-adjustable articulators may be adjusted in several ways Owing to the relative simplicity of these types of the articulator the movements of the human temporomandibular joint are not reproduced with great accuracy

Their advantages lie in their relatively lower cost compared to the fully adjustable articulator and the relative ease with which they can be used

METHODS OF SETTING CONDYLAR ANGLES

on semi-adjustable articulators:-

- 1) After mounting the models on the articulator have the patient move in a lateral direction
Observe the degree of separation of the backteeth, if any, and alter the condylar angle to reproduce the same separation on the articulator
Repeat the same exercise in protrusive Choose the shallower of the angles for restorative cases
There is less likelihood of building non-functional Interferences by doing this
This method of setting condylar angles of semi-adjustable articulators is probably the most accurate
- 2) Have the patient close into some soft wax with the jaw in a protrusive position Place this record between the mounted models of the patient
Having unlocked the centric locking mechanism Adjust the condylar articulator so that The models seat

Stuart Orton-Jones Institute

33, High Street, Harpole, Northampton. NN7 4DH

Telephone: 01604 832399

Email stuart@sojinstitute.co.uk www.sojinstitute.co.uk

into the wax record

Fully adjustable articulators are programmed after complex records have been taken of the patient using an elaborate facebow type structure known as a pantograph

Generally speaking semi-adjustable articulators will reproduce most of the movements necessary for diagnostic analysis, crown and bridgework and prosthetic procedures

Stuart Orton-Jones Institute

33, High Street, Harpole, Northampton. NN7 4DH

Telephone: 01604 832399

Email stuart@sojinstitute.co.uk www.sojinstitute.co.uk

Possible Effects of Occlusal Disharmony

Occlusal Disharmony

Adaptation

Lack of Adaptation

Asymptomatic Occlusion

Symptomatic Occlusion

Local Symptoms

Peripheral Symptoms

Oral Symptoms

LOCAL SYMPTOMS

1. Clicking & Crepitus
2. Pain on Movement
3. Decreased Mobility
4. Fatigue
5. Tenderness to Palpation
6. Trismus
7. Hypemobility

PERIPHERAL SYMPTOMS

1. Headache
2. Vertigo
3. Burning Sensation in the Tongue & Ears
4. Mild Catarrhal Deafness
5. Tinnitus
6. Pain In and Around the Ears
7. Dryness of the Mouth
8. Painful Muscles of Neck & Back
9. Tenderness to Palpation

ORAL SYMPTOMS

1. Bruxism
2. Clenching
3. Periodontal Breakdown
4. Tooth Facets
5. Tooth Fracture
6. Tooth Mobility
7. Hypersensitivity
8. Awareness of Occlusion

Stuart Orton-Jones Institute

33, High Street, Harpole, Northampton. NN7 4DH
Telephone: 01604 832399

Email stuart@sojinstitute.co.uk www.sojinstitute.co.uk

General Screening

NAME: _____ DATE: ____ / ____ / ____

Initial Requests _____

General Health Recent Visit to Doctor Allergies Serious Illnesses Bleeding Problems

Medication Rheumatic Fever Blood Pressure Diabetes Thyroid Problems

Heart Problems Arthritis Headaches Migraine

Any Dental Problems? _____

Comfortable Bite _____

Sensitive Teeth _____

Grinding _____

Jaw Joint Pain Noises (Clicking, Popping, Grating)

Difficulty in Moving Jaw Pain on Moving Jaw

Sinuses _____

Ears _____

CLINICAL EXAMINATION

Soft Tissues _____ Preauricular Palpitation _____

Lat. Ext. Aud. Meatus _____ Tap, Tap, Tap Test _____

Early Contacts (EC) Test _____ Presence of Slide (CR-CO) _____

Non Functional Contacts (NFC) _____

Tooth Charting _____ Vitality _____

Looseness _____ Gum Check _____

Stuart Orton-Jones Institute
33, High Street, Harpole, Northampton. NN7 4DH
Telephone: 01604 832399
Email stuart@sojinstitute.co.uk www.sojinstitute.co.uk

Temporomandibular Joint and Occlusal Examination Sheet

Name _____

Preauricular Palpation At Rest _____

Opening _____

Closing _____

To the Left _____

From the Left _____

To the Right _____

From the Right _____

Forwards _____

Back _____

Lateral External Auditory Meatus Palpation

At Rest _____

Opening _____

Closing _____

To the Left _____

From the Left _____

To the Right _____

From the Right _____

Forwards _____

Back _____

Occlusal Evaluation Early Contacts _____

Slide from Centric Relation to Maximum Intercuspitation _____

Non-functional Contacts on Left _____

Non-functional Contacts on Right _____

Protrusive Edge to Edge _____

Left Lateral Edge to Edge _____

Right Lateral Edge to Edge _____

Left Lateral Protrusive Edge to Edge _____

Right Lateral Protrusive Edge to Edge _____

Stuart Orton-Jones Institute
33, High Street, Harpole, Northampton. NN7 4DH
Telephone: 01604 832399
Email stuart@sojinstitute.co.uk www.sojinstitute.co.uk

Analysing an Occlusion

- 1) **EARLY CONTACTS** in Centric Relation
- 2) **PRESENCE of a SLIDE** from Centric Relation to Maximum Intercuspitation

Slides in Centric Relation

Describing a slide:

long or short, to the left or right, protrusive, horizontal or vertical

Close gently into centric relation, ask the patient to close into Maximum Intercuspitation

- 3) **INTERFERENCES**

LEFT LATERAL:

Non-functional (contacts on the right side)

Cross-over (after the left canines have crossed over each other)

Functional (on the left side)

RIGHT LATERAL:

Non-functional (on the left side)

Cross-over (after the right canines have crossed over each other)

Functional (on the right side)

4) **Tooth Guidance**

- a) **EDGE TO EDGE CONTACTS:** Protrusive, Left Lateral, Right Lateral,
Left Lateral Protrusive, Right Lateral Protrusive
- b) **LEFT LATERAL EXCURSION:** Smoothness of Guidance, Steepness of Tooth Guidance, Posterior Clearance
- c) **RIGHT LATERAL:** Interferences, Smoothness of Guidance, Steepness of Tooth Guidance, Posterior Clearance
- d) **PROTRUSIVE:** Smoothness of Guidance, Steepness of Tooth Guidance, Posterior Clearance
- e) **LEFT LATERAL PROTRUSIVE:**
(half way between left lateral and protrusive) Smoothness of Guidance, Steepness of Tooth Guidance, Posterior Clearance
- f) **RIGHT LATERAL PROTRUSIVE:**
(Half way between left lateral and Protrusive) Smoothness of Guidance, Steepness of Tooth Guidance, Posterior Clearance

The Principles of Occlusion

- 1) The Occlusal Forces should be directed down the long axes of each posterior tooth
- 2) As many posterior teeth as possible should contact in Centric Relation
- 3) There should be no lateral slide from Centric Relation to Maximum Intercuspitation
- 4) As the patient moves away from Centric Relation tooth contacts on back teeth should decrease as the front teeth take over the guidance

Stuart Orton-Jones Institute

33, High Street, Harpole, Northampton. NN7 4DH

Telephone: 01604 832399

Email stuart@sojinstitute.co.uk www.sojinstitute.co.uk

5) The front teeth should protect the back teeth

6) There should be no non-functional (balancing) contacts

Occlusal Adjusting

Objective:

* To produce as many stable centric stops on posterior teeth as possible

* To reduce or remove posterior interferences

* To produce a harmonious Tooth Guidance that reduces the stress on the back teeth as much as is possible in the circumstances and allows smooth gliding guidance in excursive movements

Methods of Altering Occlusions

The relevance and order varies with each patient

Remove

Restore

Reposition

Reshape

Appliance Therapy

DECIDE WHERE TO START

- the possibilities are :-

a) Remove early contacts to establish centric relation occlusion

b) Remove Non-functional Contacts

c) Improve the Tooth Guidance

d) All three at once

At first tackling all three at once is difficult. When learning the art of equilibration it is easier to adjust in centric relation first and to then adjust the Non-functional contacts and finally to adjust the tooth guidance.

As soon as possible, however, begin to look at all three aspects of occlusal adjusting.

Stuart Orton-Jones Institute
33, High Street, Harpole, Northampton. NN7 4DH
Telephone: 01604 832399
Email stuart@sojinstitute.co.uk www.sojinstitute.co.uk

a) Establishing Centric Relation Occlusion

The Temporomandibular Joint (Jaw Joint) is made up of the following structures :-

1. The Head of the Condyle (the highest point of lower jaw)
2. The Articular Disc
3. The Glenoid Fossa (the depression in the base of the skull into which the Head of the Condyle fits)

One of the objectives of occlusal equilibration is to establish stable centric stops, with properly seated Head of the Condyles in the Glenoid Fossa and relaxed muscles.

Mark the Early Contacts using Green Silk on models, Red Silk in the mouth.

Analyze each marking:

1) Markings on Anterior Teeth:

Contacts on anterior teeth in centric relation are not wanted unless the teeth are in such an alignment that the forces can be directed down the long axis of the teeth involved. Lightly remove contacts on anterior teeth in centric relation

As a rule remove markings from front teeth when adjusting in centric relation, unless there are insufficient centric stops on healthy posterior teeth.

Contacts in centric relation occlusion on front teeth are undesirable unless there are few back teeth present i.e. poor posterior support. In this case some help may be required from the front teeth to take the forces of occlusion in centric relation. Occasionally front teeth may be in edge to edge occlusion in which case the forces of occlusion will be directed down the long axes of the teeth. However contacts on front teeth will most often be on slopes which although not ideal is a better situation than having too much force exerted on the few remaining back teeth. The principles of occlusion are principles not rules and must be adapted to the situation being dealt with. If the front teeth are in an edge to edge relationship, the forces will be directed down the long axis of the teeth, and are acceptable.

2) Markings on Posterior Teeth:

a) Markings on slopes

These are unstable and may result in a slide from Centric Relation to Maximum Intercuspitation

Decide the ideal place to move a contact i.e. mesially, distally, lingually, or buccally

Is it going to be possible to produce a stable centric stop in this particular situation?

If not, remove the contact straight away and continue adjusting elsewhere

Stage 1 **Adjust Contacts on Slopes**

" The Occlusal Forces should be directed down the long axes of the teeth "

Remove markings from slopes

When adjusting study models, use the spoon end of the Le Cron carver for adjusting fossae and slopes, and use the blade for adjusting and recontouring cusp tips. In the mouth, use a round diamond for the fossae and the short flame diamond for cusp tips.

If cusp tip or fossa becomes sensitive, remove tooth structure from the non sensitive part.

Take care when working near cusp tips so that cusp tip is not reduced inadvertently.

When removing a contact from a slope, be careful not to remove anything from the fossa below the slope, as the fossa will become deeper. This may result in it being difficult to obtain a centric stop on that tooth.

Stage 2 **Adjust Centric Stops to bring other potential Centric Stops into contact.**

The objective is to bring as many Centric Stops into contact as possible

"As many posterior teeth as possible should contact in Centric Relation "

Stuart Orton-Jones Institute

33, High Street, Harpole, Northampton. NN7 4DH

Telephone: 01604 832399

Email stuart@sojinstitute.co.uk www.sojinstitute.co.uk

When a few stable centric stops have been created, they will need to be reduced in order to produce additional stops on other teeth.

Deepening a fossa will allow the opposing cusp tip to occlude deeper into the fossa. This may result in producing or worsening a non-functional contact. If this is a danger, adjust the cusp tip. Keep cusp tips reasonably pointed.

How much to remove ?

This depends on the clinical judgement of the operator taking into account the following factors :-

How gross is the interference?

The relationship between the importance of the problem to be solved, the importance of the result to be achieved and the amount of tooth structure to be removed. In some situations the amount of tooth reduction may not be merited as the problem being solved is very minor whereas in other situations it may be necessary to make gross reductions in tooth structure or even the extraction of a tooth in order to solve a gross problem.

How close is the progress towards an end result?

(The closer to the end result, the less should be removed)

How sensitive are the teeth?

Removing 1 mm at the back of the mouth results in a closure of 3 mm at the front.

From which tooth should the removal be made?

- * If the cusp tip is also a non-functional contact, remove from the cusp tip not the fossa
- * Removing from the fossa allows the cusp tip to be positioned deeper into the opposing tooth and increases the severity of the non-functional contact
- * Removing from the cusp tip lessens the severity of the non-functional contact

Adjusting Anterior Teeth

The objectives are to produce a harmonious Tooth Guidance that reduces the stress on the back teeth as much as is possible in the circumstances and allows smooth gliding guidance in excursive movements. If the guidance is not smooth a tooth or several teeth may be traumatized during bruxism and may be damaged and/or loosened. If by reducing the contact on a loose front tooth, a non-functional contact is created this may be necessary to prolong the life of this tooth. If it is possible to transfer the guidance onto teeth further forwards, this is preferable.

If there is a contact between the tip of a lower front tooth and the palatal surface of an upper tooth, and the tip is shortened, the edge-to-edge contacts can be altered, and back teeth may be brought into contact. A decision has to be made as to which contact to reduce. Reducing the tip may lead to posterior interferences.

Beware of losing centric stops from the mesial marginal ridges of the upper teeth, and from the distal marginal ridges in the lower.

Before beginning an occlusal adjustment, look for deep fossae where it is possible to add to the filling (or tooth) and shorten the opposing cusp tip to return the tooth to its original form. Light cured composite should be used as it can be adjusted when set - cut a small cavity in the amalgam filling after adjusting the opposing cusp, insert some composite and close the patient into the composite. Open and set the composite.

Teeth that have large amalgam fillings may have thin and fragile cusps. In this case, ensure that all centric stops are on the amalgam filling. **DO NOT** have any centric stops or contacts on the cusp tips as the cusps will fracture.

When nearing the completion of an equilibration and you can hear that one tooth is touching before the rest, but you have several markings, tap the patient (or models) together in centric relation with articulating foil or silk and then tap together without.

Then check to see whether any of the ink markings have been cleared in the centre of the marking. If this is the case, then this is the first contact. This type of marking is known as a "hab".

Stuart Orton-Jones Institute
33, High Street, Harpole, Northampton. NN7 4DH
Telephone: 01604 832399
Email stuart@sojinstitute.co.uk www.sojinstitute.co.uk

Splaying of Front Teeth

Splaying of front teeth in moderate to advanced periodontal cases is often due to the lower teeth hitting in centric relation and sliding forwards into the front teeth. When these cases are equilibrated in centric relation and the slide eliminated there may well be a space between the upper and lower front teeth when the teeth are in centric relation occlusion. The front teeth may move back of their own accord, into their original positions or may need to be retracted orthodontically.

Historic Markings

When a decision has been made to remove tooth structure from only one of two teeth that are contacting the marking on the other tooth still remains.

This is known as a "Historic Marking" and is no longer relevant. The marking ink must be removed from this tooth at the same time as the tooth structure is removed from the opposing tooth. Unless this is done, irrelevant markings may remain and cause confusion later on. Occasionally a mark may be a smudge and not a true marking. Watch out for this.

When a non-functional contact on a cusp tip is also a centric stop, it may be necessary to reduce the cusp tip to eliminate the non-functional contact and to thus sacrifice a centric stop. Hopefully there will be another centric stop on the tooth.

When a lot of smudges or markings present, clean them off with a toothbrush and start again, or ask the patient to grind on a tissue or piece of gauze held in a pair of articulating paper holders.

Protecting a cusp tip

When adjusting non-functional contacts, preserve centric stops where possible. If two cusp tips touch in excursions i.e. non-functional contacts it may be necessary to lose one or other. Sacrifice the stop from tooth with most stops.

Tooth Guidance

Canine guidance is easier to deal with than Group Function as all the other teeth separate due to the discluding effect of the canines.

Group Function has the advantage of distributing the forces of occlusion over several teeth.

Adjusting contacts on front teeth which are contacting in centric relation:

If upper or lower front teeth are to be shortened, check first to ensure that interferences at the back are not going to be produced. If interferences are produced, decide whether it is still wise to go ahead, or make provision to adjust them later.

In cases of steep tooth guidance where there is no possibility of creating non-functional contacts it is easier to adjust the fossa rather than the cusp tip. It is more difficult to reshape cusp tips.

Steepness of Tooth Guidance -

General principle - flattening the Tooth guidance decreases TMJ problems

Steep Tooth Guidance i.e. in Class 2 division 2 cases produces immediate disclusion. Steep Tooth guidance however, can be a problem for the Temporomandibular joint.

Flattening the Tooth guidance can help Temporomandibular joint problems.

Changing the Angulation of the Tooth Guidance:

1. If the tooth guidance is flattened, interferences may be produced on the back teeth.
2. Flattening the tooth guidance can help in Temporomandibular Joint problems.
3. Steepening the tooth guidance may help reduce posterior interferences but produce joint problems.

When checking Tooth Guidance:

1. Edge-to-edge position
 - a. protrusive
 - b. left lateral

Stuart Orton-Jones Institute

33, High Street, Harpole, Northampton. NN7 4DH

Telephone: 01604 832399

Email stuart@sojinstitute.co.uk www.sojinstitute.co.uk

- c. right lateral
- d. left lat protrusive
- e. right lat protrusive

2. Check left lateral; note guiding teeth & look for non-functional contacts on the right
3. Check right lateral; note guiding teeth & check non-functional contacts the left
4. Protrusion; check guiding teeth & protrusive interferences
5. Left Lateral Protrusive
6. Right Lateral Protrusive

When checking edge-to-edge positions:-

Check for interferences on posterior teeth

Adjusting Edge-to-edge Contacts - Whether to adjust upper or lower front teeth depends on which gives best aesthetics

Adjusting front teeth

When adjusting the length of front teeth, always consider the appearance.

The appearance of front teeth is personal to that person. Alterations of the appearance need to be done with the consent of that person. Alterations to the aesthetics need to be done gradually, with the patient watching in a hand mirror, or looking at the results as the procedure progresses.

STOP adjusting the front teeth when the patient is happy with the appearance.

How to Progress

- 1) Start with isolated adjustments that are obviously necessary : -
 - a) Reshaping opposing cusp tips before restoring a tooth when the cusp tip occludes deep into the occlusal surface of the opposing tooth
 - b) Remove obvious interferences in centric relation
 - c) Remove gross non-functional contacts
 - d) Recontour anterior teeth that are over-erupted where there is no chance of creating non-functional contacts by doing so
- 2)
 - a) Take two sets of study models of patients who you consider would benefit from alterations in their occlusion
 - b) Adjust one set and record any particularly significant changes you think should be made to the patient
 - c) Equilibrate the patient
- 3) Equilibrate the study models at the same time as you equilibrate i.e. adjust the models a little and then adjust the patient and repeat the process

The advantages are :-

- a) The patient sees the work you are doing on their behalf (charging the patient for the adjustment of their models when they are not present is fully justified Seeing the adjustment being performed may help them rationalize the fee)
- b) The adjustment made on the model is fresh in your mind when you are adjusting in the mouth
- 4) **When in doubt fit an appliance before equilibrating**
- 5) Stop if the patient experiences pain
- 6) At first do not
 - a) treat patients who are particularly neurotic

Stuart Orton-Jones Institute

33, High Street, Harpole, Northampton. NN7 4DH

Telephone: 01604 832399

Email stuart@sojinstitute.co.uk www.sojinstitute.co.uk

b) overly persuade patients to have an equilibration Choose patients who are enthusiastic and good patients

Appointing Patients for Occlusal Equilibration Appointments

It is not possible to predict exactly how long an equilibration will take

Book patients for an initial appointment with the understanding that further appointments may be necessary

Relate the length of an appointment to the patient's ability to pay

i.e. Arrange shorter appointments for patients who need to spread out the payments.

Be flexible

Stuart Orton-Jones Institute

33, High Street, Harpole, Northampton. NN7 4DH

Telephone: 01604 832399

Email stuart@sojinstitute.co.uk www.sojinstitute.co.uk

Clinical Occlusal Adjustment Procedure

Items required for the Occlusal Adjustment Procedure

STORAGE TRAY

1. 1 Tupperware Container 15 cm x 18 cm containing
 - a) Pre-cut Red Silk
 - b) 2 x Articulating Paper Holders set up with Red Silk ready to use
2. 4 or more Articulating Paper Holders set up with BLACK foil
3. 1 Suture box containing pre-cut Black Foil
4. 1 Box Shimstock pre-cut to 1/2 inches, 4 cm or the width of a small post-it
5. Horseshoe Articulating Paper (for denture adjustments)

The Black foil and the Red silk should be cut neatly to the length of a large post-it with a pair of straight scissors
The Red Silk dries out if left out and does not mark the occlusal contacts

Burs

Short Flame Diamond (Intensive 255 from Metrodent)
Round Diamond Horico 001025 Glover Dental
Long Flame Diamond F.G.563 (for aesthetic adjustment)
or Intensiv 311 from Metrodent

other items

Plastic Salivary Ejectors, CUT IN HALF
This item is extremely useful in salivary control when held by the chairside assistant and used as the dentist dries the teeth with the 3-in 1 syringe

SET-UP

Plastic Tray,
Storage tray,
Mouth mirror,
4 or more pairs of Articulating paper holders plus black foil,
(ensure that all the other free Articulating paper Holders are set up with black foil)
2 pairs of articulating holders plus red silk,
Large round in No 1 handpiece,
Short flame diamond in No 2 handpiece,
Tweezers plus a Cotton Pellet, (for removal of individual unwanted markings)
A Toothbrush, (for brushing of old markings)
Tip-a-dilly plus a shortened plastic salivary ejector,

THE PROCEDURE

In order for the dentist to manipulate the Jaw into Centric Relation both his hands are required It is therefore necessary to have effective chairside support from a dental assistant

The dental assistant should aspirate and place the Articulating Foil or Silk into the patients mouth while the Dentist dries the teeth and manipulates the Jaw The dental assistant should dry the foil or silk thoroughly after each time they are used using a tissue otherwise they will not mark the teeth The assisting needs to be fast and accurate as the procedure is repetitive and requires good coordination between the dentist and the assistant It is important that the assistant keeps ahead or at least up

Stuart Orton-Jones Institute

33, High Street, Harpole, Northampton. NN7 4DH

Telephone: 01604 832399

Email stuart@sojinstitute.co.uk www.sojinstitute.co.uk

with the dentist. As soon as the dentist moves his hand towards the 3-in-1 syringe the assistant should place the aspirator into the mouth. The dentist dries the teeth with the 3-in-1 Syringe as the dental assistant aspirates with her left hand at the back of the patient's mouth on the side that the dentist is drying. The dental assistant holds the Articulating paper holders in her right hand ready to place in the patient's mouth as the dentist removes the 3-in-1 Syringe from the patient's mouth. The dental assistant clearly knows which side to place the articulating paper holders having observed which teeth the dentist has dried.

The articulating paper holders must be placed in the mouth at the same time as the aspirator is removed in order to prevent saliva wetting the foil or silk unnecessarily. The articulating paper holders should be held against the upper teeth as this jaw does not move while the lower does move. There is not enough time to change hands during the procedure so it is necessary for the assistant to develop the use of her right hand to place the articulating paper into the left and right hand sides of the patient's mouth. When the procedure is actively in progress the Articulating Paper Holders should be held up near the mouth ready to place in the mouth. The Articulating Paper Holders need to be placed in the mouth as the Dentist removes the 3-in-1 syringe, otherwise there is a risk of the teeth becoming wet with saliva. Constantly dry the Red silk during the procedure otherwise it will not mark the teeth. The dentist will indicate when the black foil or the red silk is to be used.

Preserving markings

If the teeth have been marked and for some reason the dentist is not ready to make the necessary adjustments the patient must be prevented from closing. This may well cause the markings to be rubbed off. To prevent this happening the assistant should rest the aspirator tip or the tip of a finger on the tips of the lower front teeth to discourage the patient from closing.

Placing the Articulating paper holders into the patient's mouth

- 1) Which side to place it
(This will be indicated by the dentist as it will be the side that he dries with the 3-in-1 syringe)
- 2) Hold the Holders ready in the direction that they will be placed into the patient's mouth
- 3) Aim the holders up towards the patient's palate almost touching it. Then move it using a finger movement between the teeth ensuring that it is in the line of the arch and in the region which the dentist dried the teeth. Placing the articulating paper holders accurately this way will help prevent the foil or silk being folded over by the patient's tongue.
- 4) Move the Foil around a little while the patient's teeth are being tapped together in order to ensure better markings. By doing this a fresh area of foil is ready to mark the teeth.

532-90 Tips

- 1) To help detect first contacts tap the patient into Centric Relation using the Dawson Hold and ask the patient to put their finger on the tooth that touches first.
- 2) If a patient experiences difficulty in moving their jaw in the correct direction sometimes the cause can be that only one pair of articulating forceps have been put into the patient's mouth. By placing two in the patient's one each side may overcome this problem.
- 3) The Quick Method of Occlusal Adjusting
 - a) Have the patient grind around on some red silk.
 - b) Look at the markings and decide on the markings where contact is definitely not needed or wanted.
 - c) Remove these markings.
- 4) Decide on the amount of tooth structure that needs to be removed.

Early in the procedure more may be removed whereas later only a minute amount may need to be removed. The bur being used should be applied to the tooth using a light brush stroke.

Stuart Orton-Jones Institute
33, High Street, Harpole, Northampton. NN7 4DH
Telephone: 01604 832399
Email stuart@sojinstitute.co.uk www.sojinstitute.co.uk

Post Treatment Presentation

Explain the following things to the patient

1. They may find that their teeth feel rough for several days
2. Their symptoms get worse for a few days. This is not a bad sign. It is due to the patient being more aware of their bite having had it altered. Their symptoms will settle down after a few days.
 3. They may feel hot and cold pain for a few days
 4. They may be more aware of their bite for a few days

Anterior Repositioning Appliances

1. Construct Tanner Appliance shell
2. Reline Tanner shell in the mouth
3. Ask the patient to:-
 - a) open until the first click
 - b) protrude the jaw, closing forwards
 - c) retrace to just before the second click
4. Practice the above.
5. Place a small amount of warm compound on the appliance in the 2nd premolar / 1st molar region on both sides. Insert the appliance and have the patient to:-
 - a) open until the first click
 - b) protrude the jaw
 - c) then close into the compound just before the second click

Allow the compound to cool.

Check that the click has disappeared when the patient

opens and closes.

If the click on closing is still present, replace the compound and have the patient close a little further forward.

7. Reline the occlusal surface of the appliance with acrylic anterior and posterior to the compound.
8. Insert the appliance and guide the patient into the compound registration. Allow to set.
9. Remove compound and add more acrylic.
10. Shade the guiding planes with pencil.

Stuart Orton-Jones Institute
33, High Street, Harpole, Northampton. NN7 4DH
Telephone: 01604 832399
Email stuart@sojinstitute.co.uk www.sojinstitute.co.uk

11. Trim off the buccal flash and any excess but leaving the guiding surfaces of acrylic.
12. Fit the appliance and check that the click has disappeared.

RECOMMENDED READING

Communication and Psychology

Games People Play by Eric Berne published by:-
Happiness and Fulfilment in Dentistry

**Penguin
Quintessence Publishing Co Ltd**

I'm O.K. You're O.K. by Harris
Staying O.K. by Harris

Occlusion

Diagnosis and Treatment Planning of Occlusal Problems
by Peter Dawson published by Mosby from:-

**The L.D.Pankey Institute
(Bookstore)**

(order using VISA or MASTERCARD. If you order by Fax,
give complete card number & expiry date.) FAX 010-1-305-361-6534 or Phone 010-1-305-361-5433
(Florida is 6 hours behind us)

Occlusion and Function by Peter Neff from:-

Stuart Orton-Jones

Restorative Dentistry

Fundamentals of Fixed Prosthodontics
by Shillingbug Hobo and Whitsell from:-

Quintessence

Restoration of Endodontically Treated Teeth
by Shillingbug and Kessler from:-

Quintessence

Stuart Orton-Jones Institute
33, High Street, Harpole, Northampton. NN7 4DH
Telephone: 01604 832399
Email stuart@sojinstitute.co.uk www.sojinstitute.co.uk

Critique Form

Stuart Orton-Jones Institute

Course _____

Date _____ Name _____

Course Evaluation

The presenter of this course would be grateful if you would complete this questionnaire.
This form is continued overleaf.

Course Content _____

Lecture Sessions _____

Audio Visual Aids _____

Practical Sessions _____

Course Presenter _____

Course Assistants _____

Course Facilities _____

Course Food _____

Hotel Facilities _____

General Comments and Suggestions

Stuart Orton-Jones Institute

33, High Street, Harpole, Northampton. NN7 4DH

Telephone: 01604 832399

Email stuart@orton-jones.telinco.co.uk www.sojinstitute.co.uk

Do you think that the course was sufficiently advertised ? _____

How did you hear about the course ? _____

If a journal which one ? _____

Future Courses

What subjects would you be interested in ? _____

If you were to attend another course would you prefer the presentation to be more or less intensive ? More / Less

Thank you for completing this questionnaire.

If you would like to visit my practice to watch me work, please fill out the following page.

Stuart Orton-Jones Institute
33, High Street, Harpole, Northampton. NN7 4DH
Telephone: 01604 832399
Email stuart@orton-jones.telinco.co.uk www.sojinstitute.co.uk